

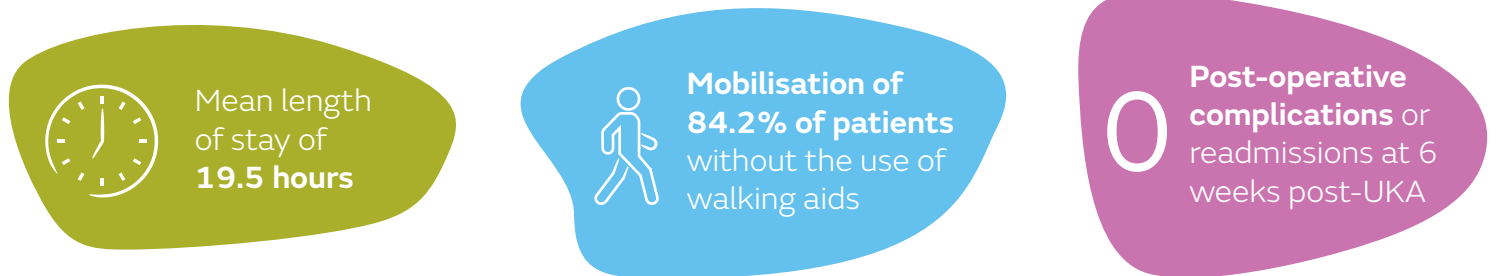
## + Evidence in focus

Publication summary: Sephton BM, et al. *J Orthop* (2020)\*

## NAVIO<sup>◇</sup> Surgical System unicompartamental knee arthroplasty (UKA) patients may be safely discharged within 24 hours with appropriate patient selection and education

### + Plus points

NAVIO UKA patients safely discharged within 24 hours (n=19 of 71) demonstrated:



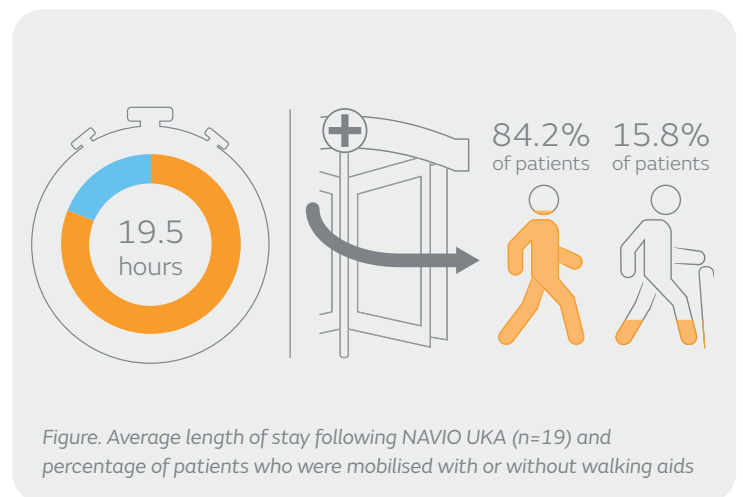
### Overview

- Single surgeon, retrospective analysis of 71 NAVIO UKA patients, from which 19 patients were discharged within 24 hours between June 2017 and October 2019 (mean age, 66.8 years; percentage of females, 47.7%)
- All 71 patients were assessed clinically pre-UKA and were offered pre-UKA education sessions from a multidisciplinary team

### Results

Of the 19 NAVIO UKA patients discharged within 24 hours:

- Mean operative time was 92.6mins (range: 64-132mins)
- Average length of stay was 19.5 hours (range: 6-23 hours; Figure)
- No complications or readmissions within 6 weeks post-UKA
- Sixteen (84.2%) patients were mobilised without walking aids; three (15.8%) with the use of a single walking stick (Figure)
- Safe mobilisation on the ward was necessary prior to discharge:
  - Fifteen patients were mobilised with an average of two physiotherapy sessions
  - Four patients were mobilised without post-UKA physiotherapy
- Mean range of motion at 6 weeks was 105.8°
- Mean Oxford Knee Score increased from 24.5 pre-surgery (n=19) to 44 at 6 months post-UKA (n=16)



### Conclusions

With appropriate patient selection and education, NAVIO UKA patients may be safely discharged within 24 hours of their operation. Reduced length of stay is associated with reduced peri-operative complications, improved clinical outcomes and potential cost savings for health care providers.

### Citation

\*Sephton BM, De la Cruz N, Shearman A, Nathwani D. Achieving discharge within 24 h of robotic unicompartamental knee arthroplasty may be possible with appropriate patient selection and a multi-disciplinary team approach. *J Orthop*. 2020;19:223-228.

Available at: [Journal of Orthopaedics](https://doi.org/10.1177/0954579420954579)