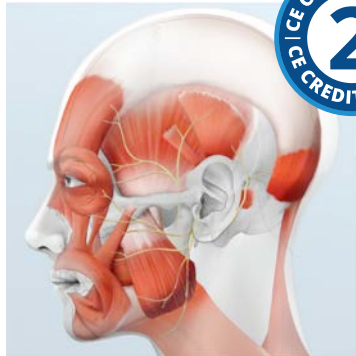

Head and Neck Anatomy: Part II – Musculature



Course Author(s): Larry LoPresti, DMD

CE Credits: 2 hours

Intended Audience: Dentists, Dental Hygienists, Dental Assistants, Dental Students, Dental Hygiene Students, Dental Assistant Students

Date Course Online: 04/04/2022

Last Revision Date: N/A

Course Expiration Date: 04/03/2025

Cost: Free

Method: Self-instructional

AGD Subject Code(s): 10

Online Course: www.dentalcare.com/en-us/ce-courses/ce597

Disclaimers:

- P&G is providing these resource materials to dental professionals. We do not own this content nor are we responsible for any material herein.
- Participants must always be aware of the hazards of using limited knowledge in integrating new techniques or procedures into their practice. Only sound evidence-based dentistry should be used in patient therapy.

Conflict of Interest Disclosure Statement

- Dr. LoPresti reports no conflicts of interest associated with this course. He has no relevant financial relationships to disclose.

Introduction

This course presents an overview of the important muscles of the head and neck including the location, attachments and actions of each. It is essential for the dental professional to understand the normal appearance and function of the musculature of this area as muscles are often sources of pain and dysfunction. Knowing normal anatomy and function will help identify the origin of the patient's complaint. The course will also cover how the musculature of the presented works in mastication and swallowing.

Please note this is Part II of a three-part series. To gain the full benefit of the concepts covered in this course, be sure to read [Head and Neck Anatomy: Part I – Bony Structures \(CE591\)](#) and Part III – Cranial Nerves (CE598)

Course Contents

- Overview
- Learning Objectives
- Glossary of Directional Terms
- Muscle Nomenclature
- Basic Muscle Structure
- Muscles
 - Muscles of Mastication
 - Masseter
 - Temporalis
 - Medial Pterygoid
 - Lateral Pterygoid
 - Muscles of Facial Expression
 - Orbicularis Oris
 - Buccinator
 - Risorius
 - Zygomaticus Major
 - Zygomaticus Minor
 - Levator Labii Superioris
 - Levator Labii Superioris Alaeque Nasi
 - Levator Anguli Oris
 - Depressor Anguli Oris
 - Depressor Labii Inferioris
 - Mentalis
 - Platysma
 - Orbicularis Oculi
 - Occipitofrontalis
 - Suprahyoid Muscles
 - Stylohyoid
 - Digastric
 - Mylohyoid
 - Geniohyoid
 - Infrahyoid Muscles
 - Mastication
 - Muscles of the Palate and Pharynx
 - Muscles of the Tongue
 - Intrinsic Muscles
 - Extrinsic Muscles
 - Cervical Muscles
- Swallowing
- Summary
- Appendices
- Course Test
- References / Additional Resources
- About the Author

Overview

This three-part course presents basic facts and concepts of head and neck anatomy. The course is not intended to replace in-depth studying of anatomy but is a guide to review the basics of anatomy as it relates

to the dental field. It is essential for all dental professionals to recognize the normal appearance and functions of the structures found in the head and neck. Beyond the teeth, muscles and neurological factors can play a role in symptoms that exist. Various medical conditions first present in the head and neck as deviations of normal. Understanding important landmarks and anatomy are key to providing proper care and diagnosis.

A note to the student – The study of head and neck anatomy is not a romantic tale of love lost, won and lost again. It is full of terminology and should not be read as one would read a novel. It is easy to conflate the information if read all at once. You should take breaks on occasion to allow what you have read to sink in before attacking yet another set of structures.

As the muscles discussed are all anchored to bones you should be familiar with the bony structures of the head covered in [Head and Neck Anatomy: Part I – Bony Structures \(CE591\)](#) prior to studying the muscles.

[Download Practice Diagrams](#)

Learning Objectives

Upon completion of this course, the dental professional should be able to:

- Understand the basic structure of muscles and how they function.
- Possess foundational knowledge of the muscles of the head and neck.
- Identify the muscles of the head and neck.
- Identify the origin and insertion of each muscle in the head and neck.
- Identify the function of each muscle group and the individual muscles within it.

Glossary of Directional Terms

Movement Terms

abduction – Movement away from the midline in the frontal plane.

adduction – Movement towards the midline in the frontal plane.

depression – Movement inferiorly.

elevation – Movement superiorly.

extension – Increasing the angle of a joint (straightening the joint).

flexion – Decreasing the angle of a joint.

hyperextension – Increasing the angle of a joint past straight.

lateral rotation – Rotation around an axis in the lateral direction.

medial rotation – Rotation around an axis in the medial direction.

protract – Movement anteriorly in a horizontal plane.

retract – Movement posteriorly in a horizontal plane.

Other Terms

action – The movement created when a muscle moves (see movement terms above).

agonist – The muscle that is performing the action.

antagonist – The muscle that opposes the movement created by the agonist.

insertion – The moving end of the muscle.

origin – The stationary end of the muscle.

synergist – A muscle with an action not being performed but involved in making the movement more efficient. These muscles are usually a pair of muscles that are antagonists that when contracted stabilize the origin of the prime mover.

Muscle Nomenclature

Muscle names are often based on anatomic characteristics which give the student trying to learn all the muscles, origins, insertions and actions a small help. Thankfully, few seem to

be named at random. Let's look at some names of muscles we will see in this lesson to illustrate the various conventions used.

Basic Muscle Structure

Knowing the microscopic structure of a muscle helps understand the macroscopic structures we are going to talk about in the following sections. There are 3 types of muscle found in the body: skeletal, cardiac, and smooth. Cardiac muscle is only found in the muscular wall of the heart; while smooth muscle is present in the head and neck surrounding the blood vessels and within the eyes, the focus of this course will only be on skeletal muscles.

One important property that sets skeletal muscle apart from the other two types is that it is voluntary which means that you have conscious control of it. Consequently, every muscle fiber in the body must have a nerve fiber attached to it in order for it to function. Some things we do automatically are skeletal muscle mediated reflexes in the body. For example, if someone asks you to take a breath or swallow you can do that because the muscles performing those actions are voluntary. So, while some skeletal muscles seem to act outside of your conscious control, they are actually voluntary muscle, controlled by reflexes in the central nervous system. It also means that any disturbance in the nerve connection to a particular fiber will render it unusable.

A second thing that sets skeletal muscle apart is that the functional unit is not, as in most tissues, a cell, but rather is referred to as a fiber as it is composed of numerous cells that fuse together to form a single membrane bound, multi-nucleated entity during the embryonic stage of development. These fibers run the entire length of a muscle. The center is filled with structures known as a **myofibril** composed of repeating units known as **sarcomeres**. Each sarcomere consists of myosin and actin molecules layered in such a way that so that surrounding every **myosin molecule** are **actin molecules** in such a way that each actin molecule is between three myosin molecules and each myosin is surrounded by six actin molecules. The actin molecules are attached to the actin molecules in the adjacent sarcomere at a structure known as the **Z**.

Origin/Insertion or Both	<p>Example: Sternocleidomastoid muscle</p> <p>This muscle has two origins: on the sternum (sterno); the clavicle (cleido); and inserts on the mastoid process of the temporal bone (mastoid). Knowing this along with fact that the insertion generally moves towards the origin you can also figure out that this muscle pulls the mastoid process towards the clavicle and sternum rotating and tilting the head.</p>
Action	<p>Example: Depressor anguli oris</p> <p>This muscle depresses (depressor) the angle (anguli) of the mouth (oris).</p>
Size	<p>Example: Zygomaticus major/minor</p> <p>These muscles apply two rules for naming. Both are named for their origin (zygomatic arch) but rather than putting in the insertion they are ranked by size with the zygomaticus major being the larger of the two.</p>
Shape	<p>Example: Trapezius</p> <p>While this name tells nothing about the origin, insertion, size or action it does tell its shape which is roughly trapezoidal.</p>
Location	<p>Example: Orbicularis oris</p> <p>Orbicularis refers to its circular shape, so this applies to two conventions also. The oris locates it around the mouth. There is also a circular muscle around the eye called the orbicularis oculi.</p>
Relative Position	<p>Example: Lateral/medial pterygoids</p> <p>This one gives the origin on a pterygoid plate but confusingly there are two pterygoid plates named the medial and lateral. This causes some confusion as the lateral and medial refer to the position of the two muscles relative to one another rather than referring to their origins which in both cases is mainly on the lateral pterygoid plate of the sphenoid bone.</p>

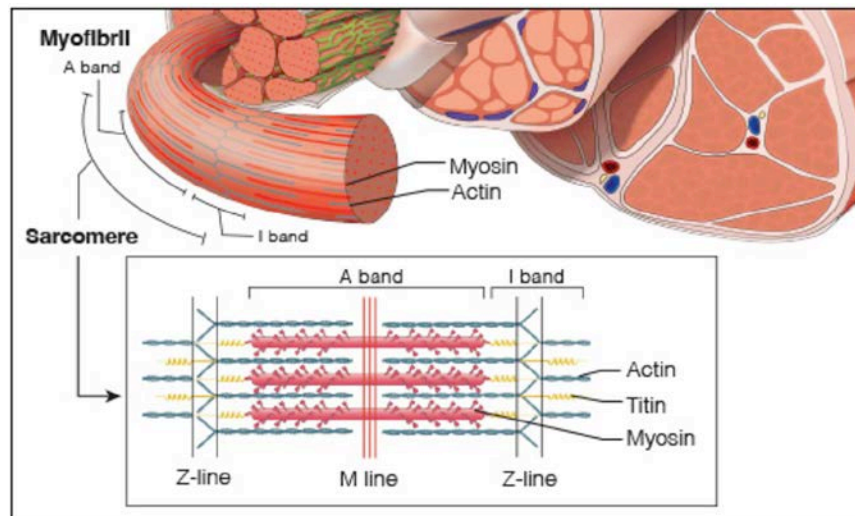


Figure 1. Muscle Fiber (close-up on myofibril).

Under nervous stimulation a series of changes in the cell cause the actin molecules to ratchet towards each other along the myosin molecule. As the actin molecules come closer together the sarcomere shortens and while each shortening is microscopic the huge number of these small movements becomes macroscopic shortening of the muscle. The last important piece of the puzzle is a protein known as **titin** which is an elastic protein that both limits stretch and keeps all the parts in the proper alignment.

The regular arrangement of molecules in the muscle fiber resulting in dark bands denoting the position of the thicker myosin molecules. This is known as the **A band** and does not change in size during contraction. There is a lighter band on the borders of the sarcomere where there are only actin molecules known as the **I band**. As there is more substance in areas where the actin and myosin overlap there is a lighter area in the center of the sarcomere where the actin molecules are not overlapping the myosin ones. This is known as the **M line** and this area as well as the I band will get smaller as the muscle contracts and larger as it lengthens. It must be noted that muscles only exert force as the sarcomeres shorten. They only return to a longer state by the action of muscles that have the opposite action. For this reason, each joint must have muscles that have opposing actions.

Each fiber has a layer of supporting and nourishing connective tissue surrounding it. This layer is known as the **endomysium**. Numerous fibers are bundled into groups of fibers known as **fascicles**. These have a connective tissue sheath known as the **perimysium**. It is the fascicle organization you see in meat as the “grain” of the muscle. Surrounding the entire belly of the muscle is another layer of connective tissue known as the **epimysium**. Each layer has fibers that tie it to the larger layer. The epimysium at the ends of the belly is continuous with the tendons that connect the muscle to the areas of origin and insertion.

Each muscle fiber has a single nerve fiber that innervates it, but each nerve fiber attaches to a number of muscle fibers. The attachment point of the nerve to the fiber is known as the motor end plate. When a nerve fiber fires every muscle fiber connected to it will contract maximally. This group of fibers connected to the same nerve fiber will contract simultaneously and are known as a motor unit. This means that the degree of movement is related to the number of motor units that are stimulated not a graded response within the fibers.

Muscles

Muscles of Mastication

The muscles of mastication are so named because these four muscles are the ones that

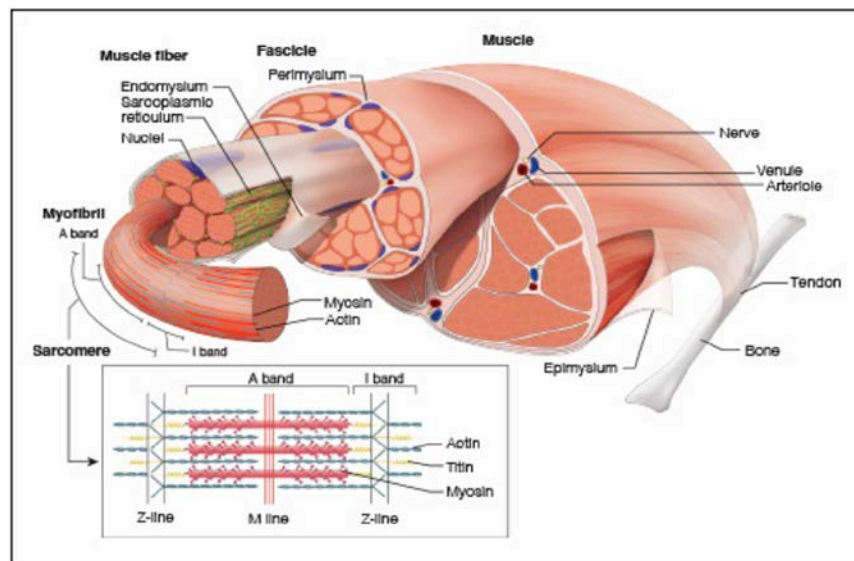


Figure 2. Muscle Fiber.

are the prime movers in chewing movements. They have more than that in common as they all are innervated by branches of the mandibular nerve also known as the third division of the trigeminal nerve (Cranial nerve V) and all supplied with arterial blood by branches of the maxillary artery. In order to move the mandible, they all insert on the mandible though one of them as we shall see also has an insertion on the articular disc of the TMJ. Now let us look at them individually.

Masseter

The **masseter** is a large muscle with two heads (although some researcher recently described a third, small head this will need to be vetted before it is accepted) that originate from the zygomatic arch and the adjacent maxillary process of the zygomatic bone. It inserts along the lateral border of the mandible in the area of the angle and up the ramus. Its main action is to elevate the mandible and it is capable of exerting great force doing this. The two heads run in slightly different directions. The smaller superficial head arises more anteriorly and is oriented so that it angles posteriorly as it descends. Given this angle this superficial head is capable of assisting in mandibular protrusion in addition to its role in elevation. The deep head is larger and oriented more vertically so is confined to elevating the mandible. As both heads of the muscle are superficial to the mandible, it is easy to place your fingers on the

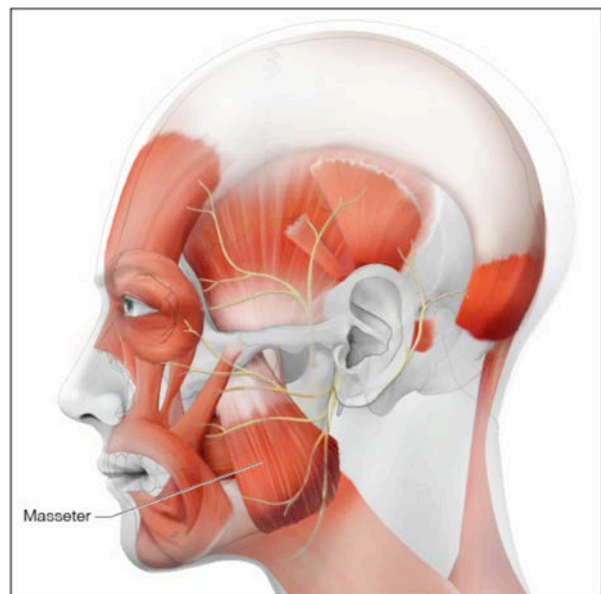


Figure 3.

masseter and feel it tense as one does either of those movements. If you compare the tension of the muscle when clenching or chewing you will find that the pattern is different in protrusion due to the inactivity of the deep head in protrusion.

Temporalis

The **temporalis** does not have the quadrilateral shape of the masseter but rather is shaped like a fan. The origin is very long, starting at the sphenoid bone and extending along the

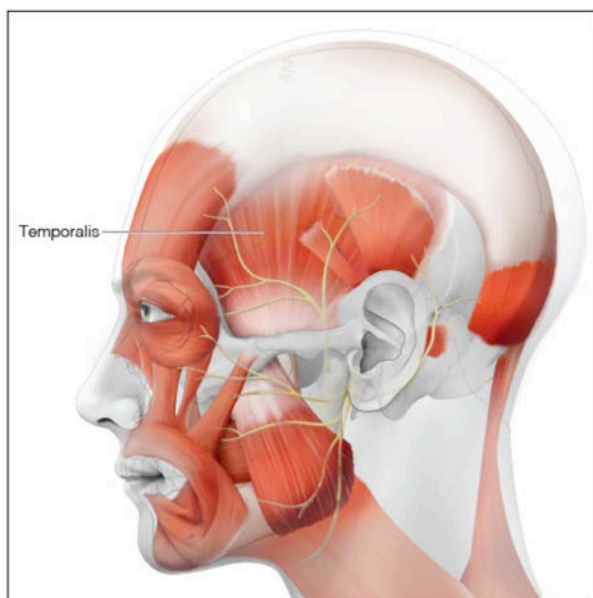


Figure 4.

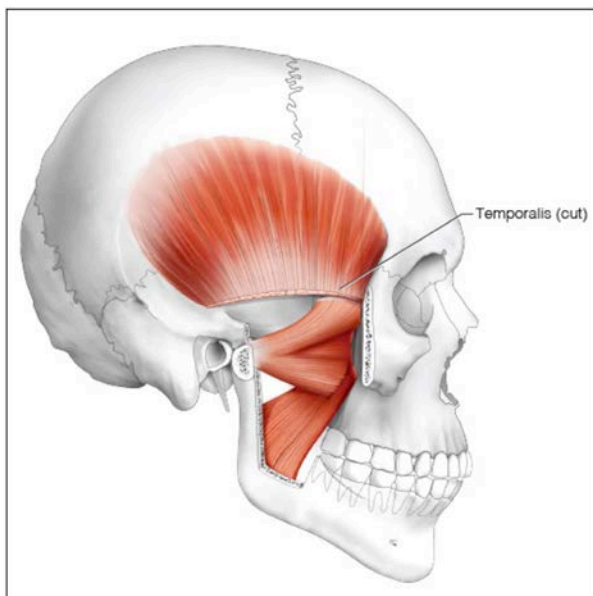


Figure 5.

frontal, parietal and temporal bones between the superior and inferior temporal lines. The most anterior fibers descend vertically deep to the zygomatic arch to attach along the entire anterior portion of the coronoid process. The majority of the fibers travel anteriorly as they descend and join a large tendon that passes deep to the zygomatic arch to insert on the coronoid process. The large number of fibers makes this a powerful muscle even though it is not as thick as the masseter. This muscle

is involved in forcibly elevating the mandible and the posteriorly placed fibers act to retract the mandible. The temporalis is unique in the muscle of mastication in that it is the only one that is the prime mover for retraction. Like the masseter this muscle is superficial and can be felt tensing when clenching or moving the mandible posteriorly.

Medial Pterygoid

The **medial pterygoid** mirrors the masseter on the deep side of the mandible. It also has two heads. The superficial head originates on maxillary tuberosity and the adjacent sphenoid bone. It runs vertically to insert on the inner surface of the angle and ramus of the mandible. This part is mainly involved with elevating the mandible. The deep part originates on the medial surface of the lateral pterygoid plate and inserts in the same area of the mandible. This origin is medial to the insertion so can contribute to rotating the mandible causing some side-to-side movement. Both heads originate anterior to the insertions so like the superficial head of the masseter it is involved in protruding the mandible. This muscle is in close proximity to the area where inferior alveolar nerve blocks are given and if injured during the injection is the main reason for post-injection limitation in the mandibular range of movement known as trismus.

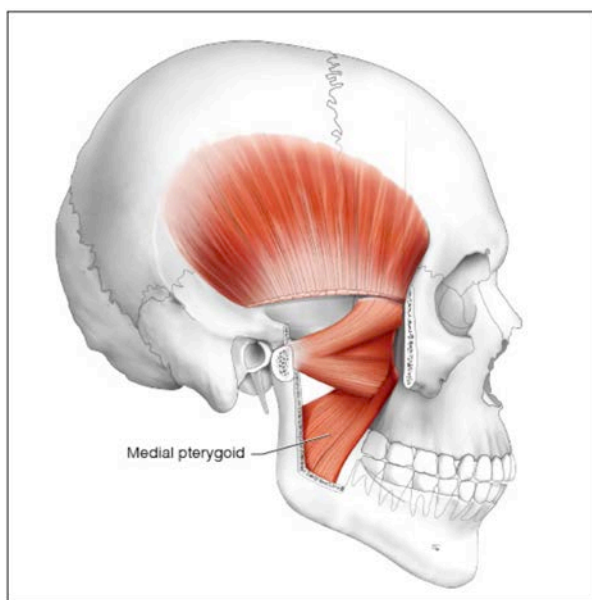


Figure 6.

Lateral Pterygoid

The **lateral pterygoid** is the big exception in this muscle group in that its fibers run horizontally rather than vertically and one of the two heads of the muscle, does not insert into bone, but rather inserts into the articular cartilage of the TMJ. Like the medial pterygoid and the masseter, it has two heads. The **superior head** originates on the sphenoid bone facing the infratemporal fossa and inserts in the articular cartilage of the temporomandibular joint. Its action is to pull the cartilage so that it stays atop the condylar head as the mandible is protruded. The **inferior head** originates on the lateral pterygoid plate and inserts into a hollow immediately inferior to the condylar head. The action of this muscle is to move the mandible anteriorly protruding it but because the gliding motion of the mandible is down the articular eminence the ultimate motion is depressing the mandible as it opens wider as it moves anteriorly. Unilateral contractions of the lateral pterygoids will move that side anteriorly but also cause rotation of the mandible in the contralateral joint.

Muscles of Facial Expression

The muscles of facial expression are unique among all muscles in the human body in that they are the only muscles that do not insert into hard tissue but rather insert into the

connective tissue underlying the skin of the head and neck. This means that when they contract, they do not move a joint, but rather move soft tissue, allowing the large range of facial expressions that our species uses to show emotions. Although they are found throughout the head and neck all of these muscles are innervated by branches of the facial nerve, cranial nerve VII (Appendix G). As these muscles are numerous, we will be ignoring the minor ones and mainly concentrating on the ones that affect the oral cavity in order to keep this section to a manageable amount of material. Other than the orbicularis oris all of these muscles are paired with one on the left and one on the right side.

Orbicularis Oris

The **orbicularis oris** is found in the lips. It is interesting in that it incorporates the fibers of the numerous muscles that insert into it as it encircles the mouth within the upper and lower lips. This complicated collection of muscle fibers running in various directions, connected to different muscles and in different layers allows the orbicularis oris complex to contort the lips into a wide variety of shapes making the playing of everything from oboes to tubas possible. More importantly for daily life the lips act to keep food in the mouth when chewing

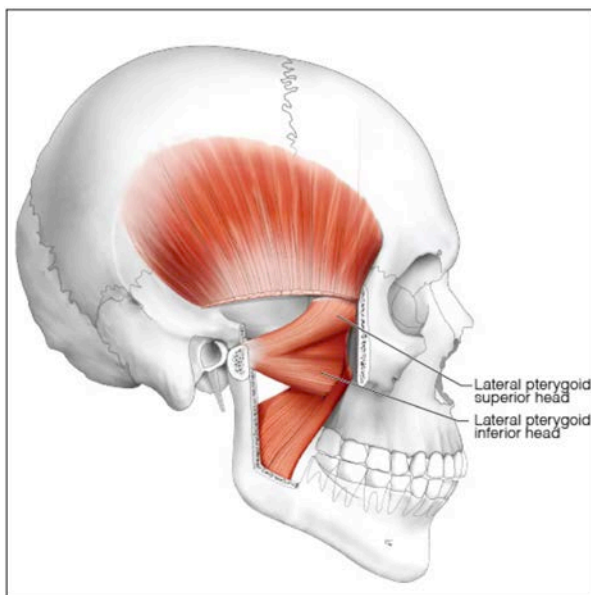


Figure 7.

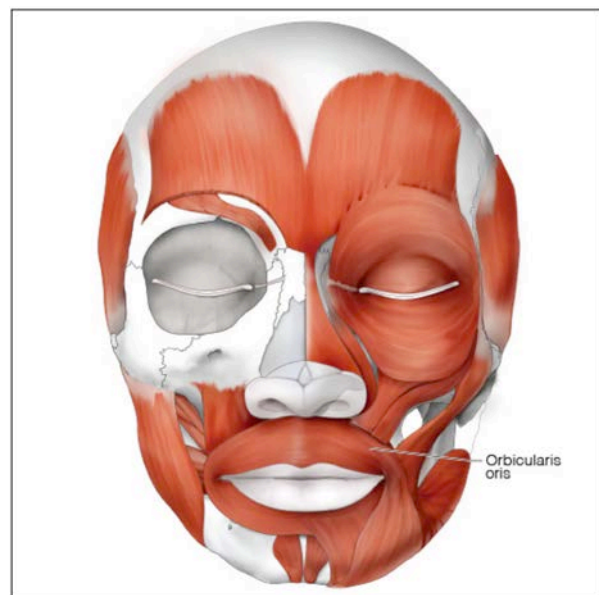

Figure 8.

without getting bitten and produce the proper shape to help speak the dozens of phonemes that humans use to communicate.

Buccinator

The **buccinator** originates from a line starting along the alveolar process of the maxilla down the pterygomandibular raphe to the buccinator ridge of the mandible. This thin muscle inserts by merging in the complex of muscles surrounding the mouth as discussed under the orbicular oris. Its main function is to compress the cheeks, a skill that is seen when one blows up balloons. Like the orbicularis oris it is very important in chewing to keep the food on the occlusal table as we chew.

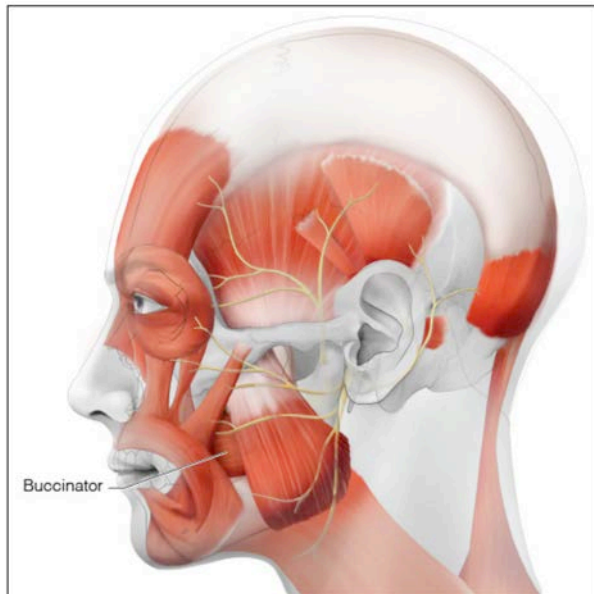


Figure 9.

Risorius

The **risorius** is a small trapezoidal muscle which is broadest at its origin in the fascia covering the parotid gland in the cheek and inserts at the corner of the mouth in concert with the buccinator along with other muscles which we will cover later at the corner of the mouth. This pulls the corner of the mouth laterally and posteriorly. This is a component of a smile. As we go through the other muscles of facial expression pay attention to how many are involved in smiling as that expression, "It takes more muscles to frown than smile," will prove to be wrong.

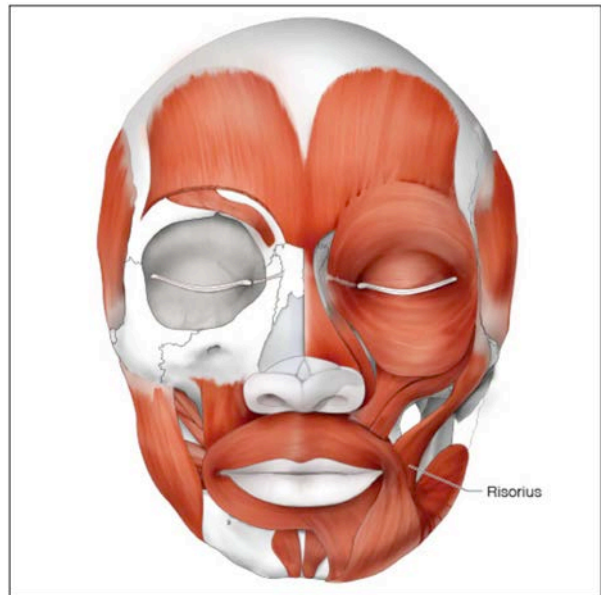


Figure 10.

Zygomaticus Major

The **zygomaticus major** is yet another muscle that inserts into the corner of the mouth. It originates, as its name implies, from the zygomatic bone. As it runs diagonally it pulls the corner of the mouth superiorly in addition to laterally. This muscle is important in that a smile that just involves the risorius looks unnatural while genuine smiles involve the zygomaticus muscles.

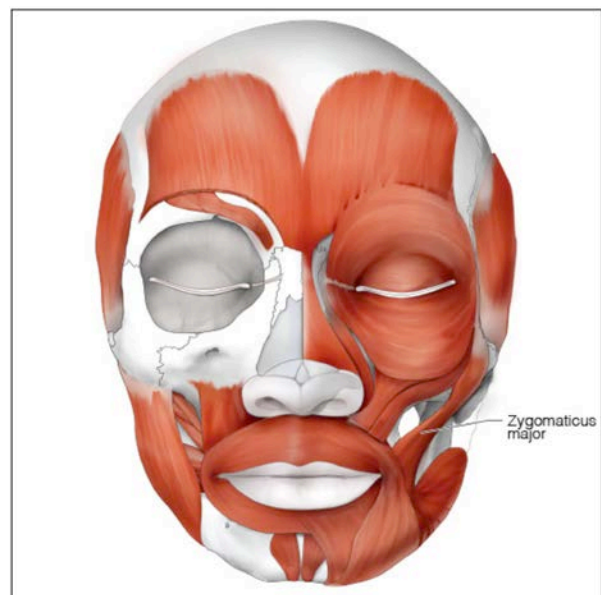

Figure 11.

Zygomaticus Minor

The **zygomaticus minor** is yet another muscle that inserts into the corner of the mouth. Its origin, is from the zygomatic bone but at that end it also mixes with the orbicularis oculi which surrounds the eye and is immediately adjacent to the levator labii superioris muscle. Like the zygomaticus major it pulls the corner of the mouth superiorly in addition to laterally but also changes the shape of the skin around the eyes contributing to the essential components of a natural smile and is what allows one to see that a person is smiling behind their surgical mask.

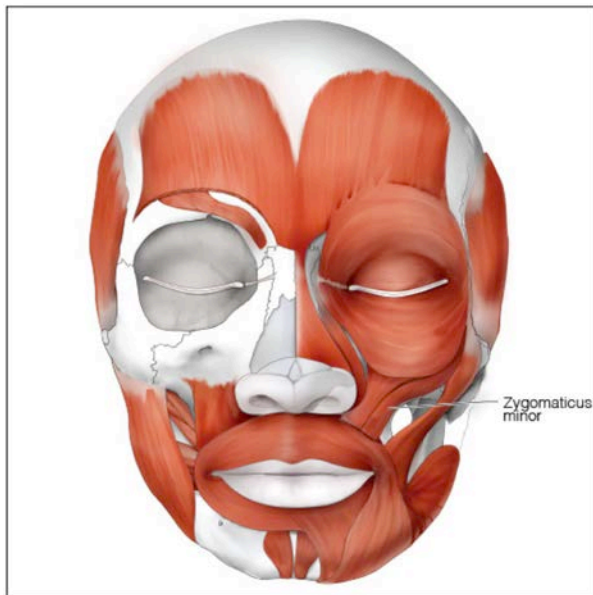

Figure 12.

Levator Labii Superioris

The **levator labii superioris** originates along a broad area along the lower orbital rim and inserts in the upper lip complex medial to the corner of the mouth. This muscle has a broad insertion that acts to lift the upper lip baring the upper teeth. This muscle along with the next one that will be discussed, the levator labii superioris alaeque nasi, is used to snarl indicting aggression which is more effective in animals that have more imposing canines than humans do but can be used alone to lift the lip and to show off your new veneers.

Levator Labii Superioris Alaeque Nasi

The levator labii superioris alaeque nasi muscle originates near the medial corner of the eye

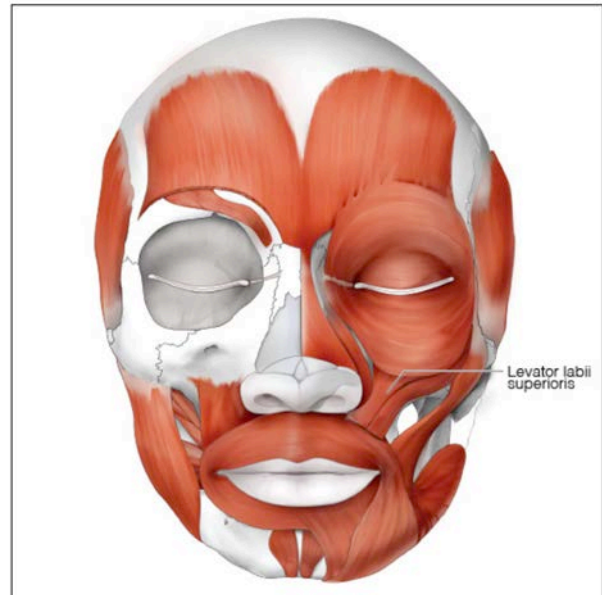


Figure 13.

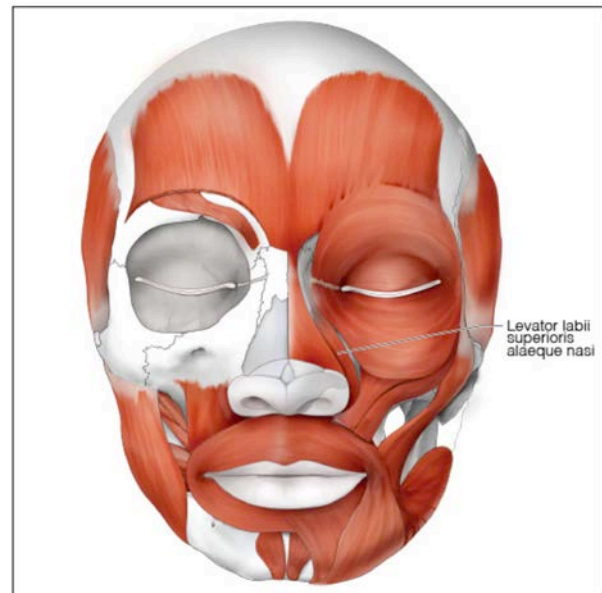


Figure 14.

on the maxillary process of the maxilla. It then passes inferiorly and insert both into the upper lip and the alar of the nose. It both elevates the upper lip but in addition widens the nostril and raises the corner of the nose.

Levator Anguli Oris

The levator anguli oris lies deep to the other muscles we have discussed so far. It originates on the maxilla directly below the infraorbital foramen and inserts at the corner of the mouth. Unlike the zygomaticus muscles it

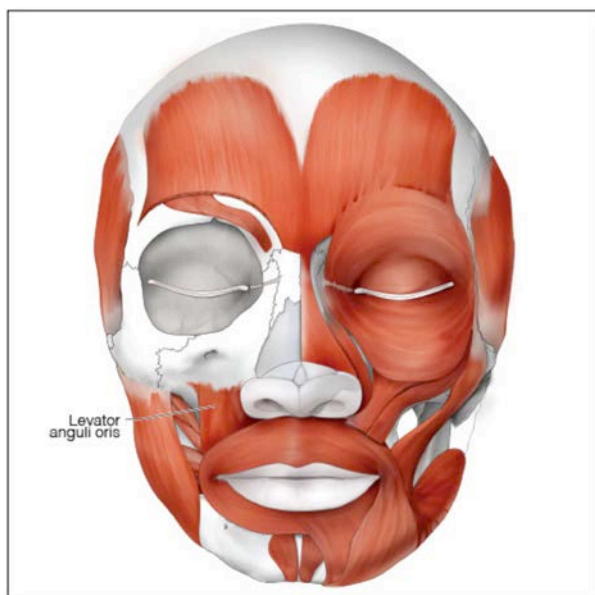


Figure 15.

angles distally to attach at the corner of the mouth so rather than drawing the corner of the mouth upwards and laterally it draws it upwards and medially.

Depressor Anguli Oris

With the **depressor anguli oris** we finally have a muscle that is involved in frowning. This muscle originates along the inferior border of the mandible and inserts at the corner of the mouth. Unlike the other muscles we have

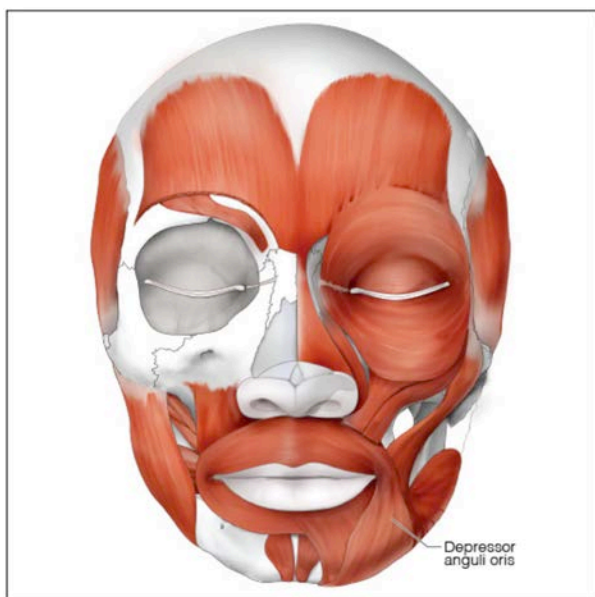


Figure 16.

discussed that insert at that spot this one is attached inferiorly so depresses the corner of the mouth resulting in a frown rather than a smile.

Depressor Labii Inferioris

Like many of the muscles of facial expression the **depressor labii inferioris** does exactly what its name says it should. It acts to depress the lower lip which is the Latin translation of its name. It originates in the anterior mandible along the oblique line. It inserts into the muscular complex of the orbicularis oris on the lower lip.

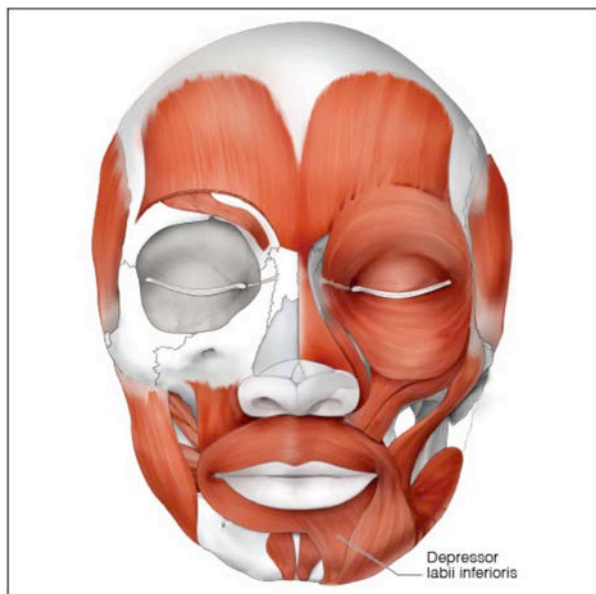


Figure 17.

Mentalis

The **mentalis** muscles are a pair of muscles located centrally in the lower jaw. The origin attaches to the inferior border of mandible on either side of the midline. The insertion is into the skin of the chin below the lower lip. Its action is hard to understand but basically raises the skin over the chin and elevates central portion of the lower lip. It also pulls the tissue under the lip causing protrusion of the lip as in a pout.

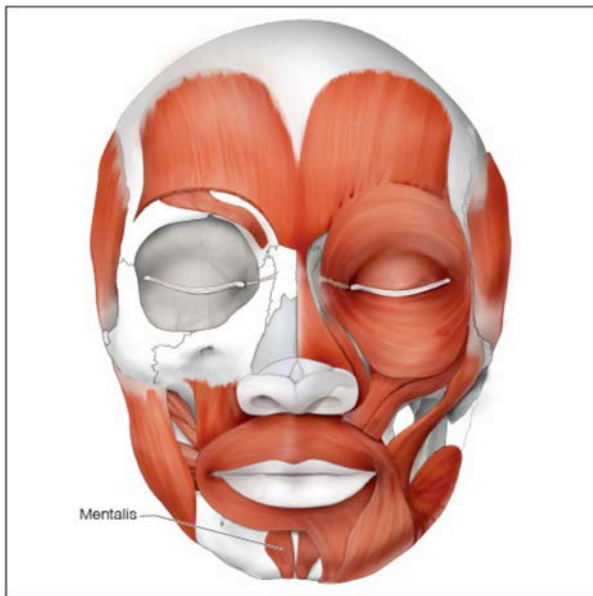


Figure 18.

Platysma

The **platysma** is a broad muscle that originates in the tissue overlying the clavicle. It is a thin broad sheet of superficial muscle that inserts into the mandible from the midline to the angle and has some fibers that insert into the corner of the lip. It acts somewhat to pull down the corners of the mouth and lower lip plus can help depress the mandible. However, it is not a major player in either of those actions

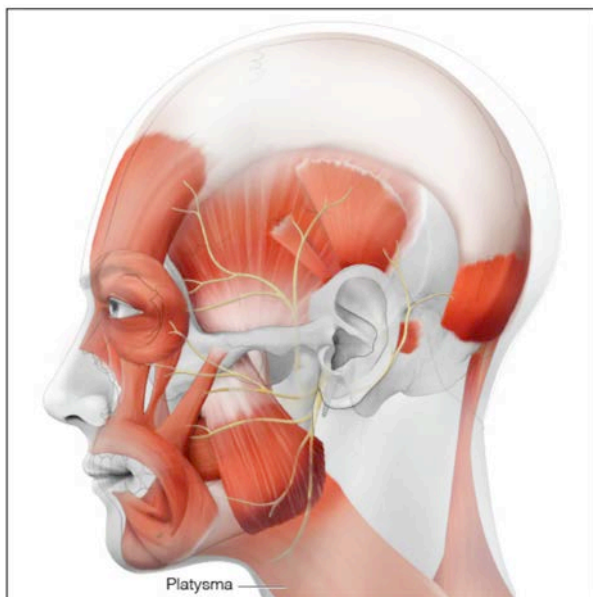


Figure 19.

but is usually contracted when the mandible is clenched which protrudes the overlying skin of the neck. This action is usually interpreted as fear or exasperation depending on the other muscles of the face that are activated simultaneously.

Orbicularis Oculi

While we have tried to limit the number of muscles of facial expression in this lesson to the ones most important to the oral practitioner there are a couple of other muscles that are important even if they have no effect on the oral cavity. The first of these is the **orbicularis oculi**. While this muscle shares a first name with the orbicularis oris it is a much simpler muscle in form. It has an origin and insertion at the medial corner of the eye so acts like a sphincter squeezing the eye shut. It does have two parts though as the muscle in the eyelids are considered part of this muscle in addition to the circular fibers that surround the eye.

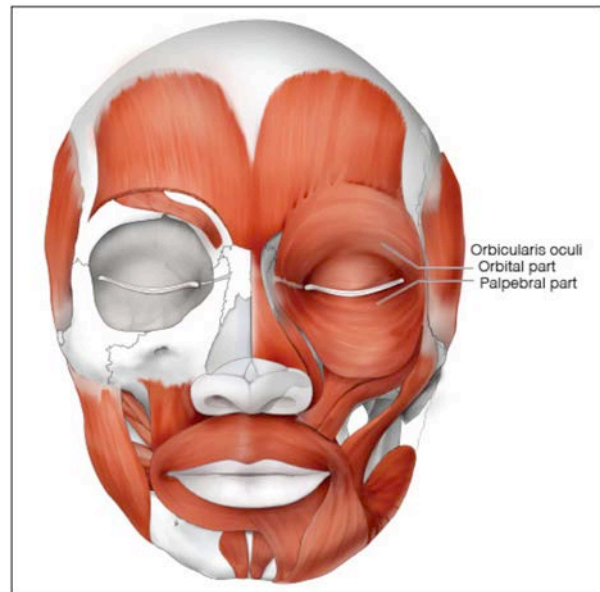


Figure 20.

Occipitofrontalis

The occipitofrontalis is also known by the name epicranium. Both names are descriptive of the muscle which is actually two muscles joined by a band of connective tissue, the epicranial aponeurosis, that extends over the cranium. The occipitalis portion of the muscle originates at the superior nuchal line of the occipital bone

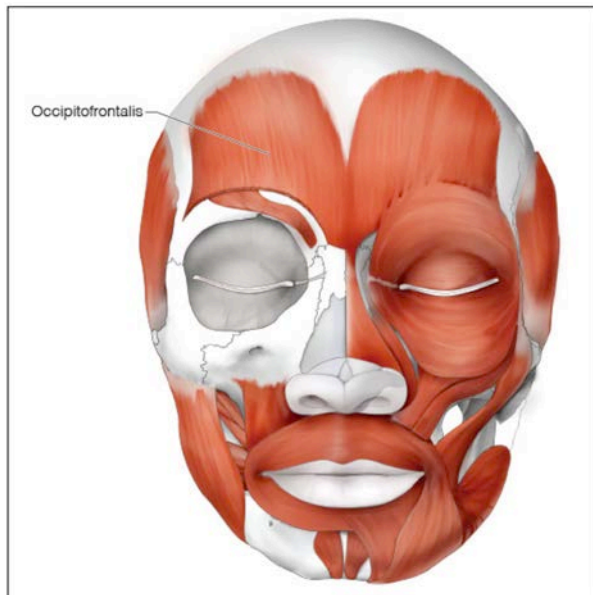


Figure 21.

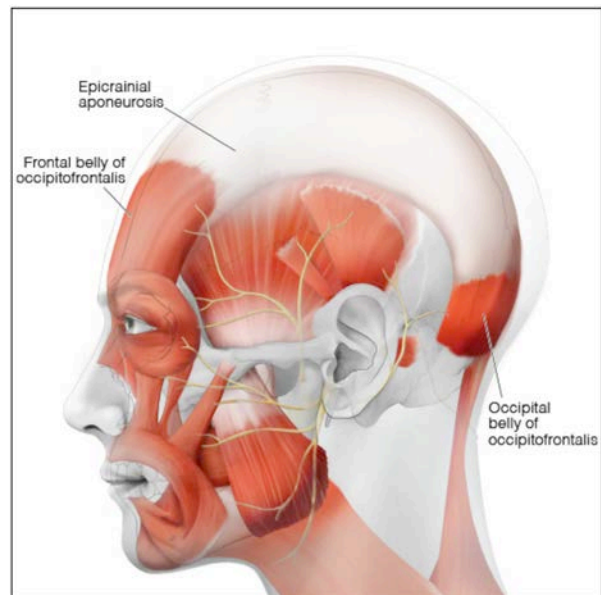


Figure 23.

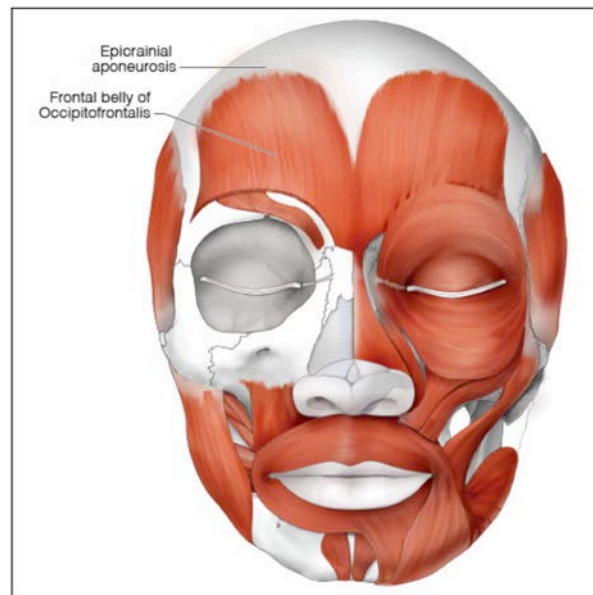


Figure 22.

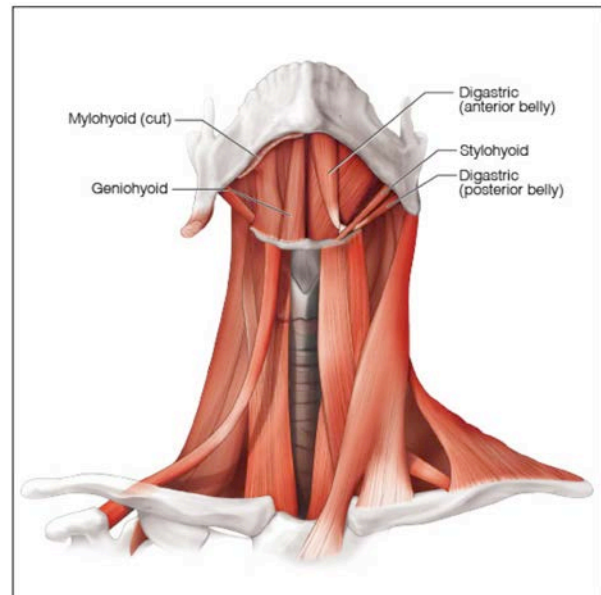


Figure 24.

and the mastoid process of the temporal bone. It inserts into the epicranial aponeurosis that traverses the skull cap and then acts as the origin of the frontalis portion which then inserts into the skin above the orbits. Contracting this muscle elevates the skin of the forehead causing the forehead to wrinkle and the eyebrows to raise.

Suprahyoid Muscles

The hyoid bone is unique in the human body in that it is not attached to any other bone.

That makes it possible to move the entire bone in the anterior/posterior directions and the superior/inferior directions. As the hyoid acts as a base for the muscles that form most of the tongue the movements of that organ are dictated by the position of the hyoid bone. The bone's location is primarily controlled by muscles. These muscles are divided into two major groups depending on whether they originate superior to the hyoid or inferior to it. The group that we will study first are the ones that originate superior to the hyoid. These

four paired muscles are referred to as the suprahyoid muscles. These muscles in general elevate the hyoid but also have other actions depending on the muscle. Unfortunately, unlike the previous two groups of muscles, these muscles do not have single nerve that controls all of them.

Stylohyoid

The **stylohyoid** is a narrow band of muscle extending diagonally from its origin on the styloid process of the temporal bone to the hyoid bone. It is innervated by a branch of cranial nerve VII (facial nerve). As the origin is superior and posterior to the insertion the stylohyoid acts to pull the hyoid bone superiorly and posteriorly. This moves the tongue in the same direction and is used in swallowing.

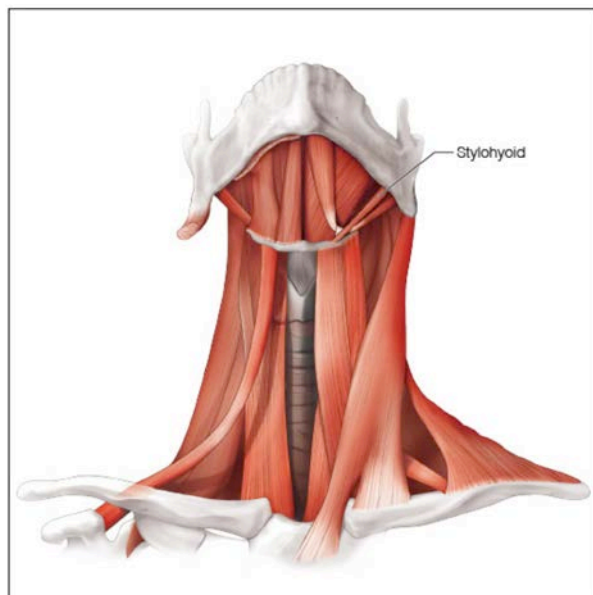


Figure 25.

Digastric

Gaster means belly and *di* means two so naturally the **digastric** muscle is composed of two groups of muscle fibers connected by a central tendon. Unlike the occipitofrontalis which has somewhat the same structure this tendon, called the intermediate tendon, is round in cross section rather than flat. It passes through a loop of connective tissue attached to the hyoid bone. It does not actually insert into the hyoid. The **posterior belly** originates just anterior to the mastoid process

and the **anterior belly** inserts into the inferior border of the mandible near the midline. The action of the muscle depends on the action of other muscles. If the elevators of the mandible contract the action will be to shorten the muscle which will result in the intermediate tendon moving the hyoid posteriorly and superiorly, so like the stylohyoid this muscle is involved in swallowing. However, if the infrahyoids contract to stabilize the hyoid the action will be to depress the mandible. As it has two bellies and two actions naturally to make things difficult for the learner it has two separate nerves enervating it. The **anterior belly** is innervated by branches of cranial nerve V3 (trigeminal nerve – third division, the mandibular nerve) and the **posterior belly** is innervated by branches of cranial nerve VII (facial nerve).

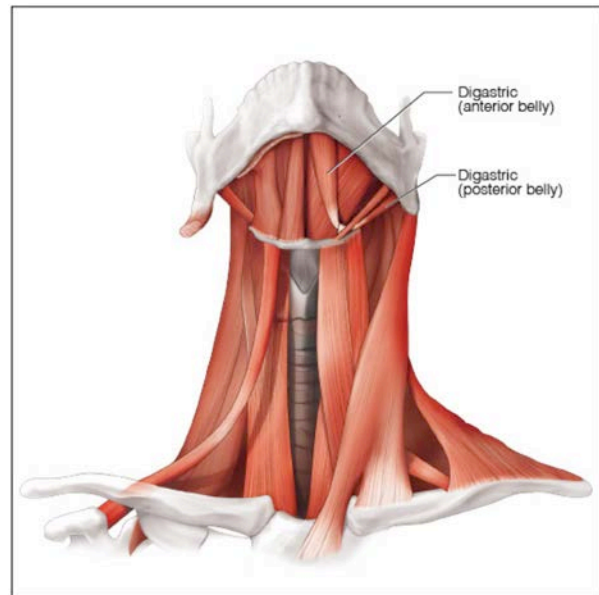


Figure 26.

Mylohyoid

The **mylohyoid** muscle has a long origin along the mylohyoid line of the mandible. As such it forms the muscular floor of the oral cavity. It inserts at the body of the hyoid and into the contralateral mylohyoid. It is innervated by a branch of cranial nerve V3 (trigeminal nerve – third division, mandibular nerve). Like the digastric it is capable of elevating the hyoid when swallowing if the mouth is closed. This is why the patients always want to close to swallow, usually at an inconvenient time.

Though swallowing is possible with the mouth open it is much less effective. The mylohyoid also acts to depress the mandible if the infrahyoids are activated. The other effect one can easily demonstrate is that it raises the floor of the mouth. Just placing a finger behind the chin as one swallows will prove this.

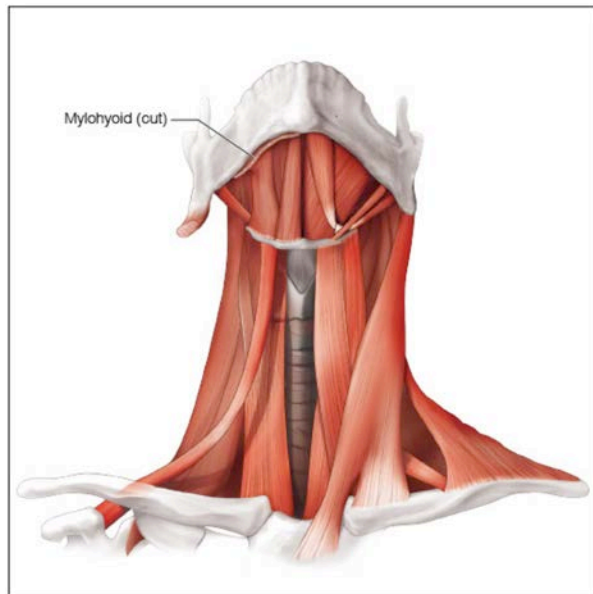


Figure 27.

Geniohyoid

The **geniohyoids** originate at the genial tubercles which are in the midline of the mandible at the near inferior edge. They run deep to the mylohyoid muscle. As they are anterior and superior to the hyoid bone, they will result in the hyoid bone moving superiorly and anteriorly if the mandible's position is fixed. Of course, like other suprahyoids connected to the mandible if the infrahyoids fix the hyoid in place this muscle can also help open the mandible. It is innervated by fibers that originate in C1 (the first cervical nerve) but travel with Cranial nerve XII (the hypoglossal nerve).

Infrahyoid Muscles

We have discovered muscles that elevate the hyoid bone and now will look at the muscles that perform the antagonistic function. These are known as the infrahyoid muscles. Unlike the suprahyoid muscles that used hyo- as a prefix, these can be distinguished by using

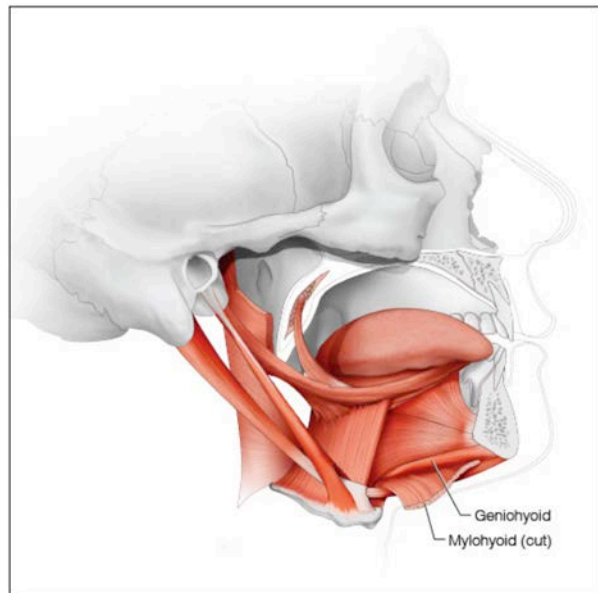


Figure 28.

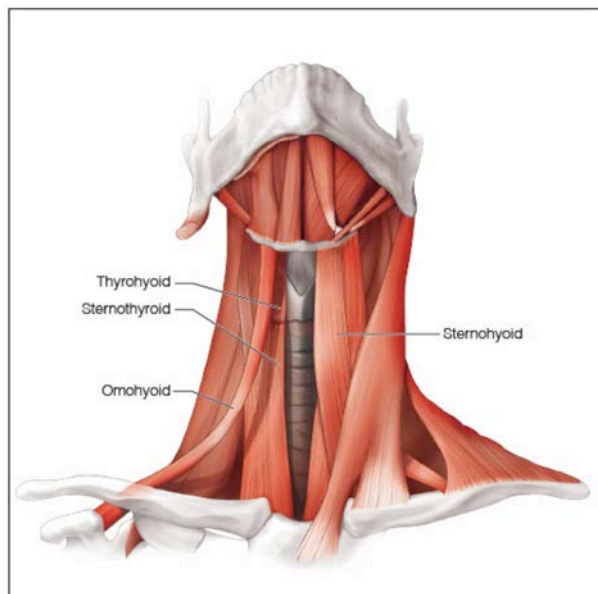


Figure 29.

hyoid as the suffix though like the suprahyoids one of them does not follow that rule. With one variation we will note they are all innervated by branches from the ansa cervicalis which has contributions from the first three cervical nerves.

Omohyoid

The **omohyoid** is constructed like the digastric muscle with two bellies separated by an intermediate tendon. In the case of the

omohyoid the central tendon is anchored in place on the superior surface of the clavicle. It originates on the superior surface of the scapula and inserts laterally on the inferior surface of the hyoid. It acts predictably to depress the hyoid.

Sternohyoid

As indicated by the name the **sternohyoid** connects the origin on the sternum to the hyoid bone. This strap like muscle when contracted will depress the hyoid bone which is necessary to complete the cycle of muscle movements involved in swallowing.

Thyrohyoid

The **thyrohyoid** extends between its origin on the thyroid cartilage to insert into the hyoid. As the thyroid cartilage is not fixed in place, contraction of this muscle draws the hyoid and larynx together. If the thyroid is fixed this will result in depression of the hyoid bone and conversely if the hyoid is fixed in place, it will elevate the larynx. This is the one muscle not innervated by the ansa cervicalis as it mirrors the innervation of the geniohyoid having fibers that originate in the first cervical nerve but travel on the hypoglossal nerve.

Sternothyroid

While the **sternothyroid** muscle does not directly connect to the hyoid bone it is included in this group of muscle because it influences the movement of hyoid bone and works in concert with the other muscles in this group. It originates on the sternum and inserts into the thyroid cartilage. It will, when contracted, depress the thyroid cartilage which is the main cartilage of the larynx. The cartilage is connected to the hyoid by the thyrohyoid muscle. This is the muscle working with the thyrohyoid will depress the hyoid bone.

Mastication

Now that we have studied both the bones of the skull and the muscles, we can look at the interaction between them as we use our mouths to process our food to make it easier to swallow and digest. While you may have been told that humans are omnivores in reality, we are fructivores although both have similar dentitions. Fructivores have canines that do not

interfere with side-to-side motion of the jaw but do have some cusps to allow cutting and tearing which is necessary as many foods we eat have a hard to penetrate covering over the softer, more delicious inner portion. Humans use both vertical movements to cut and tear and horizontal movement to grind.

With that introduction we can look at both cases. The easier case is the cutting and tearing motions, in general we use the anterior teeth for this function. The first movement then is to position the lower jaw so that the incisors will align which is protrusion assuming normal tooth relationships and the jaw in resting position which is slightly open. People with open bites or with Class III malocclusion are anatomically prohibited from having the incisors become edge to edge and people with very deep bites will have to open the mouth far beyond normal rest position prior to protruding the mandible. The lateral pterygoids generally both contract to move the mandibular condyle and articular cartilage anteriorly down the articular eminence. This will increase the space between the upper and lower teeth. If that increase is not enough to fit around the object, we are stuffing into our mouths, other muscles come into play to rotate the TMJ without the translation of the lateral pterygoids. These are mostly in the suprahyoid group and include the digastric, mylohyoid and geniohyoid muscles directly and the infrahyoids indirectly to fix the hyoid in place so these muscles work on the mandible rather than the hyoid. Once we are lined up the mandibular elevators take the lead as the masseter, temporalis and medial pterygoid go into action and forcibly close the teeth on the object while the suprahyoids relax. The lateral pterygoids will stay involved though to stabilize the mandible in a slightly protruded position so that the incisal edges line up. Tearing with the canines sometimes is done just by putting the food into the mouth at an angle and sometimes, if it looks like you need to be canine tip to tip one pterygoid will predominate and the mandible will deviate towards that side enough to get the food directly between the sharp cusps of the canines.

Grinding will follow biting in order to increase the surface area of the food, soften it with

the addition of saliva and thus prepare it to be swallowed. This requires coordination of a number of muscles. The tongue will take the food that sits in the anterior part of the mouth and by tilting move it onto the occlusal surfaces of the posterior teeth. Obviously, all the muscles of mastication are involved in the chewing stroke but at different times. The three elevators are all used to create force on the food as the lateral pterygoids take turns protracting the jaw on one side and then the other to create a side-to-side chewing motion. This motion is also aided by contractions of the posterior portion of the temporalis muscle that retracts the jaw. You can feel the actions of the temporalis and masseter by placing fingers on them as you chew but the action of the pterygoids is not discernible in this fashion as they are deep to the ramus. The force of the contractions and the direction of the lateral movements are controlled by feedback from pressure receptors in the periodontal ligament (PDL) surrounding the tooth roots that sense the force put on the teeth and by proprioceptive receptors in the muscles and their associated tendons themselves which can tell the length of the muscle and the amount of tension it is creating. Greater forces will be applied if the muscle does not shorten and less pressure will be applied if the sensors in PDL reveal that the teeth are being over stressed.

The role of the PDL sensors cannot be overemphasized as the amount of force on the teeth changes the speed and strength of the contraction which is what makes popcorn such a dangerous food. As the majority of popcorn is soft and requires considerable muscular pressure to break up but is soft so cushions the force on the teeth meaning the muscles contract hard and they increase the lateral movement of the jaw to work through the fibers. Insert an un-popped kernel into this equation and the great force is no longer cushioned and the tooth is overstressed which can easily result in tooth fractures or damage to the PDL.

In addition, the buccinator and the muscles of the tongue work in concert with them to force the food to stay on the occlusal surfaces of the teeth. Lateral movements are guided by

the anatomy of the posterior teeth. In addition to the jaw movements the hyoid and the soft palate move in concert with the chewing stroke to control the placement of the food being chewed so that it stays in the oral cavity and on the back teeth.

Feedback from the PDL indicating interfering cusps will change the contractions of the lateral pterygoids to avoid hitting them. This is why many malocclusions overstress the lateral pterygoids leading to TMD. Like most repeated motions in the body chewing becomes a patterned motion based in the cerebellum. This makes it similar to a golf or tennis swing in that it is fairly consistent over time unless consciously worked on to change. In the rare instances where these carefully coordinated feedback loops are disrupted damage can result to the teeth, the cheek, or the tongue. Dental work that changes the height or position of the cusps or the vertical dimension of occlusion will often result in damage as the habitual pattern of the muscles when chewing is disrupted. Like changing your golf swing, (If you don't play golf ask a golfer about this) it takes time and much training. During that retraining period things often go awry, cusps can be broken, teeth can become mobile, the muscles can get sore and, in some cases, the TMJ itself sustains damage. None of these are a good outcome to an avoidable situation.

Muscles of the Palate and Pharynx

While these muscles cover a large area, and they grouped together as they are important in swallowing. They do not make movements that are readily visible as they are mostly involved in swallowing and swallowing is best accomplished with the mouth closed. Many of them are used in the doctor's office when one says, "Ah" so they can look at your posterior pharyngeal wall. They have a variety of nerves that innervate them all of which have to be coordinated to swallow effectively.

Tensor Veli Palatini

This paired muscle, the **tensor veli palatini** originates over an area that includes the medial pterygoid plate of the sphenoid, the spine of the sphenoid and importantly on the lateral surface of the cartilage that forms the eustachian

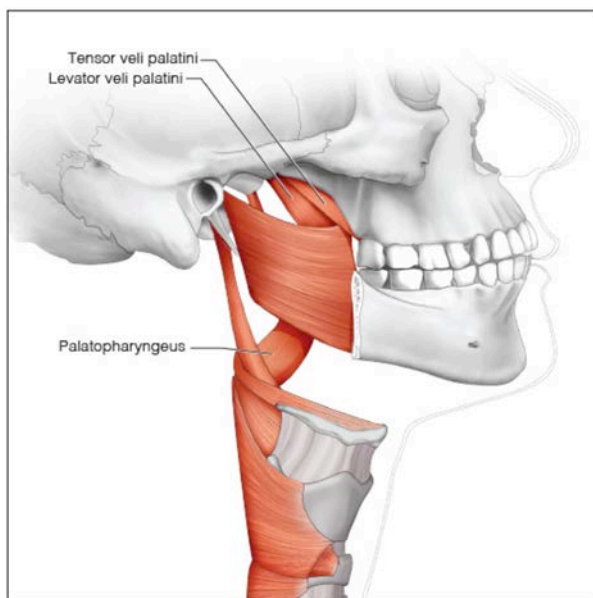


Figure 30.

(auditory) tube. It inserts on a band of connective tissue that runs along the posterior edge of the hard palate. When contracted it has two effects: it tenses the palatal aponeurosis which anchors other muscles, so it acts as a synergist to their actions and importantly also helps open the eustachian tube to equalize the pressure in the middle ear. It is activated when swallowing which is why swallowing helps relieve the pressure buildup in the ear when changing altitude especially noticeable when flying. It is innervated by a branch of the nerve to the medial pterygoid which one should remember is a muscle of mastication and therefore originates from the third division of the trigeminal nerve (cranial nerve V3 – cranial nerve V - 3rd division). It is the only palatal muscle not innervated by the vagus (cranial nerve X).

Levator Veli Palatini

Another small, paired muscle found in the soft palate is the **levator veli palatini**. It originates on the petrous portion of the temporal bone and like the tensor veli palatini also from the eustachian tube though on the medial side rather than the lateral side. Its insertion is on the palatine aponeurosis. When contracted it helps open the eustachian tube but as indicated by its name it elevates the palate also. It is innervated by nerves that originate in the vagus nerve (cranial nerve X).

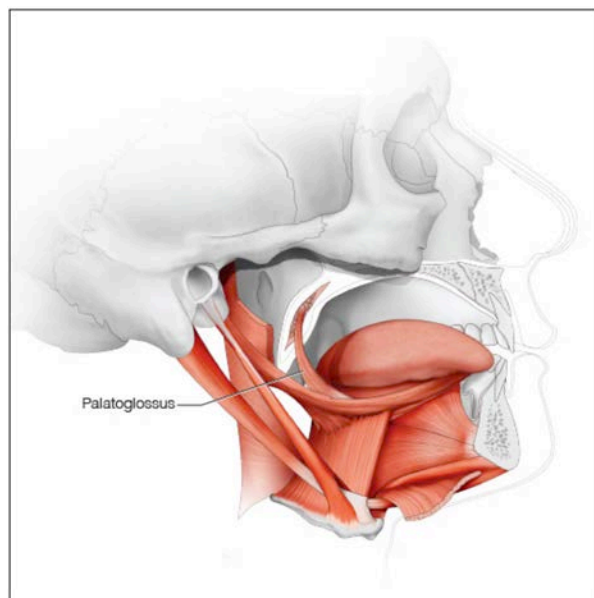


Figure 31.

Palatopharyngeus

The left and right **palatopharyngeus** muscles actually underlie a structure you can see in your own mouth, if your palatine tonsils are either missing or small enough, as it lies directly behind the palatine tonsil on both sides of the mouth. These bilateral structures are referred to as the posterior tonsillar pillars. They are formed as the muscle goes from its origin in the palatal aponeurosis and adjacent hard palate and its insertion in the thyroid cartilage. It will elevate the thyroid cartilage when contracted which by extension raises the larynx and pharynx. It, like the levator veli palatini, is innervated by fibers from the vagus nerve.

Palatoglossus

The **palatoglossus** muscles form the anterior tonsillar pillars which lie anterior to the palatine tonsils so are easily visualized by looking in a properly illuminated throat. As they run from their origin in the palatine aponeurosis to the insertion in the tongue it forms a curtain of tissue which as a continuation from the posterior border of the soft palate defines the posterior extent of the oral cavity. This muscle acts to lift the tongue towards the palate while simultaneously lowering the soft palate towards the tongue. This is important to help force food into the pharynx. Because it is also a tongue muscle

it is often grouped with them also but here to lessen redundancy we will assume you will remember that and we will not cover it again. Like all of the other palatal muscles except the tensor veli palatini it is innervated by branches of the vagus nerve found in the pharyngeal plexus. One reason to put it here is that its innervation follows palatal patterns while all the other tongue muscles in that group are innervated by the hypoglossal nerve (cranial nerve XII).

Muscle of the Uvula

Despite the way the name sounds the muscle of the uvula is a pair of muscles that originate in the posterior hard palate and insert in the palatine aponeurosis and the soft tissue of the uvula. The uvula can be shortened by contracting the pair or deviated to one side or the other by contracting just one of them. It is innervated by the pharyngeal plexus of nerves.

Superior Pharyngeal Constrictor

The **superior pharyngeal constrictor** muscle is broad muscle with a long origin that runs from the mandible inferiorly up the pterygomandibular raphe to the pterygoid hamulus of the sphenoid bone. The raphe is visible as a tissue fold in the mouth that runs from the distal part of the maxillary tuberosity to the mandibular mylohyoid ridge. It inserts into a raphe posteriorly that connects the two pharyngeal constrictors to each other known as the pharyngeal raphe. This band of tissue runs in the posterior wall of the pharynx. As the muscle contracts then it constricts the pharynx as the muscle pulls against itself. This acts to force food down the pharynx. It also innervated by the pharyngeal plexus.

Middle Pharyngeal Constrictor

The **middle pharyngeal constrictor** muscle is also a broad muscle with an origin that extends from the hyoid bone and then up the stylohyoid ligament that extends from the hyoid bone to the styloid process of the temporal bone. It inserts into the pharyngeal raphe inferior to the superior pharyngeal constrictor. Like the superior constrictor it acts to force food down the pharynx and is innervated by the pharyngeal plexus.

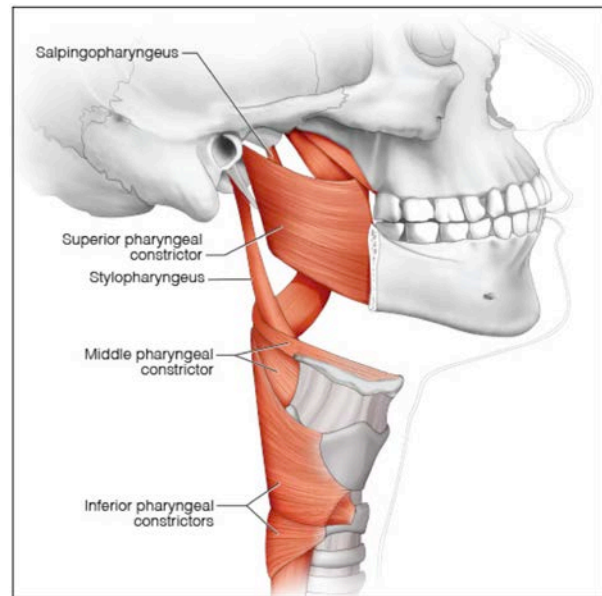


Figure 32.

Inferior Pharyngeal Constrictor

The **inferior constrictor muscle**, as expected by its name is the most inferior of the three constrictors. It originates as separate bellies on the cricoid and thyroid cartilages of the larynx. Like the other two constrictors it also inserts into the pharyngeal raphe and constricts to collapse the pharynx but unlike the other two it is generally contracted to keep air from getting into the esophagus during breathing. It is this muscle that kids learn to relax to be able to burp at will to impress their friends. It is also used by post-laryngectomy patients to enable them to speak. Given good enough control they use them as substitute for surgically removed vocal folds. While both bellies are innervated by the vagus nerve (cranial nerve X) not all the fibers come from the pharyngeal plexus as the cricoid part often has branches feeding it from laryngeal branches of the vagus.

Stylopharyngeus

The **stylopharyngeus** muscle originates at the styloid process of the temporal bone but the insertion is not so clear cut as it merges into various muscles as it comes into proximity with them. Some fibers end up joining the superior and middle pharyngeal constrictors but the majority join with the salpingopharyngeus (Figure 3) muscle discussed below and insert

into the thyroid cartilage. The position of the origin relative to the insertion means that it will elevate the larynx when contracted. This muscle is the exception in the pharyngeal muscles and is innervated by branches of the glossopharyngeal nerve (cranial nerve IX).

Salpingopharyngeus Muscle

The **salpingopharyngeus** muscle originates at the base of the eustachian tube. As mentioned in the discussion of the stylopharyngeus muscle the fibers of the two muscles merge and insert into the thyroid cartilage. Both ends of this muscle are attached to movable tissue so when it contracts it opens the auditory tube orifice in the pharynx and along with the two veli palatini muscles allows the middle ear pressure to equalize with the ambient air pressure while also elevating the larynx. It is, like all but one of the pharyngeal muscles, innervated by the vagus nerve through the pharyngeal plexus.

Muscles of the Tongue

The tongue itself is a very mobile muscle surrounded by soft tissue. As everyone knows this is important to both speech and swallowing but as important it is also involved in keeping food on the teeth so it can be chewed properly. We divide this group of muscles into two categories: ones that are encased only in the tongue itself which we term the intrinsic muscles and ones that extend to other structures outside the tongue itself termed the extrinsic muscles. It is also important to remember that the tongue is anchored to the hyoid bone which in turn is connected to muscles that move it and therefore affect the tongue position. All of the muscles of the tongue mentioned below are innervated by branches the hypoglossal nerve (cranial nerve XII). The palatoglossus muscle which we covered with the palatal muscles is an exception being innervated by branches of cranial nerve IX but will not be covered again.

Intrinsic Muscles

The intrinsic muscles of the tongue are contained completely within the tongue and act to change the shape of the tongue. There are four muscles that are found in relatively distinct layers which will be described starting

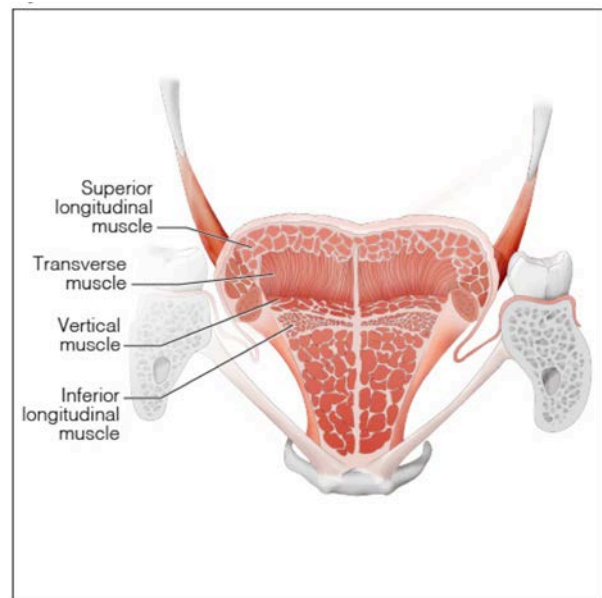


Figure 33.

at the most superior layer and working down to the most inferior layer. The descriptions will be brief as whoever named them made it easy to figure out which direction the fibers are running and therefore what the action is. Remember from above these are all innervated by the hypoglossal nerve.

Superior Longitudinal Muscle

The **superior longitudinal** runs from the distal and a septum in the center of the tongue called the median septum and inserts in the outer portion of the tongue. It acts to mainly both curl the tip of the tongue and lateral surfaces of the tongue superiorly and shorten the tongue if used with the inferior longitudinal muscle.

Transverse Muscle

The **transverse muscle** proceeds from an origin along the median septum out to the lateral borders of the tongue. This muscle acts to narrow the tongue which in effect lengthens and helps protrude it.

Vertical Muscle

The **vertical muscle** fibers intertwine in the intermediate muscle layer of the tongue with the fibers of the transverse muscle. They run vertically within the tongue and when contracted will flatten it and by doing that will effectively also widen the tongue.

Inferior Longitudinal Muscle

The **inferior longitudinal** runs parallel to the superior longitudinal intrinsic muscle from the base of the tongue to the tip. It acts to mainly both curl the tip of the tongue and lateral surfaces inferiorly and shorten the tongue if used with the superior longitudinal muscle.

Extrinsic Muscles

These muscles which are all named for their origins and insertions all end in -glossus which means they all insert into the tongue. These muscles do not change the shape of the tongue like the intrinsic muscle but instead change its position. These muscles like the rest of the tongue muscles discussed in this section are innervated by fibers derived from the hypoglossal nerve (cranial nerve XII). Remember we already discussed one of the muscles, the palatoglossus with the muscles of the palate and will not discuss it here but one should understand that it is considered one the extrinsic muscles of the tongue too.

Genioglossus

The **genioglossus** starts at the genial tubercles which are found centrally in the inferior portion of the deep surface of the mandible. It inserts into the hyoid bone and fans out to insert along the base of the tongue. As the insertion is over a long area and the relationship of the hyoid to the genial tubercle varies over that area, the action depends on which area of the muscle is contracted. Contracting the superior portion will bring the tip of the tongue towards the floor of the mouth in an inferior and posterior direction. The middle fibers will depress the entire tongue and the inferior fibers which are attached mainly to the hyoid bone will draw the hyoid anteriorly and in consequence will protrude the tongue.

Hyoglossus

The **hyoglossus** muscle originates along the anterior portion of the hyoid bone from the greater cornu to the midline. The insertion which unlike the genioglossus is similar in length to the origin is along the lateral portion of the tongue. It acts to depress and retract the tongue. This is the main connection between the hyoid bone and the tongue.

Styloglossus

As I am sure you expect by now the **styloglossus** muscle originates at the styloid process and inserts in the tongue. In fact, its fibers join the inferior longitudinal muscle and the hyoglossus muscle. This muscle will, due to its position, elevate and retract the tongue which is important in moving the bolus of food into the esophagus.

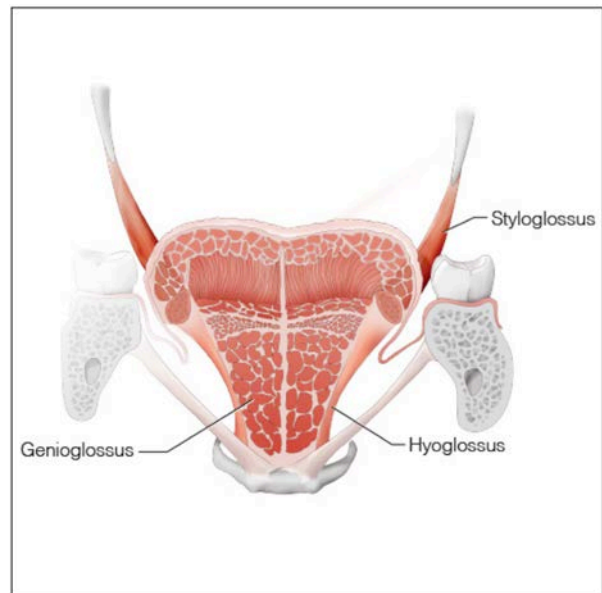


Figure 34.

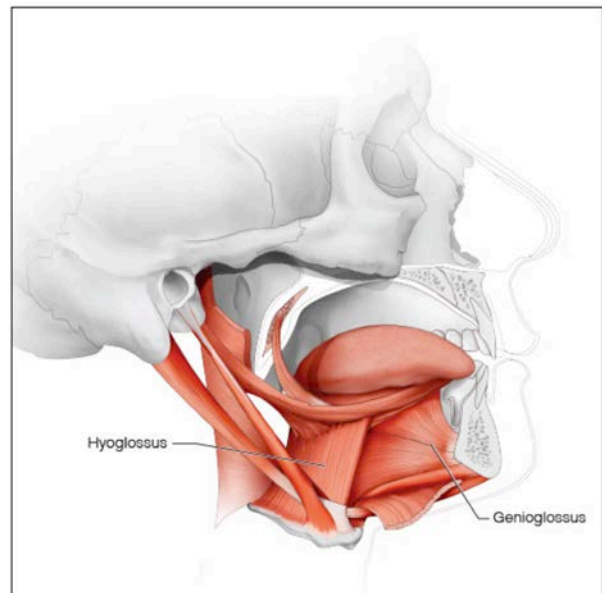


Figure 35.

Cervical Muscles

While there are many cervical muscles this area is not as important to dental professionals, for this reason the list has been narrowed to the two largest and most important muscles. The sternocleidomastoid and trapezius, both of which are innervated by nerve fibers originating in the spinal accessory nerve (cranial nerve XI).

Sternocleidomastoid

The **sternocleidomastoid** muscle has a belly that originates from the superior portion of the sternum known as the manubrium and another belly that originates on the medial portion of the clavicle. Both heads merge to insert on the posterior portion of the mastoid process and the adjacent superior nuchal line. This muscle is prominent in the neck and used as a landmark in examinations as it defines the anterior triangle and posterior triangles of the neck. It is a prime mover of the head as it is capable of rotating and flexing the head but also laterally flexing it. It is the muscle that allows us to indicate we agree by nodding by bringing our chin downwards, disagree by rotating it to say no or tilt the head which can mean anything from, "I don't believe you," to "I don't understand."

Trapezius

While the sternocleidomastoid angles towards the posterior and can bring the head forward it must be opposed to lift the chin superiorly. This is the job of the **trapezius** muscle along with other muscles we will not be discussing. The trapezius is a large muscle that can be seen in the back of the neck and is the muscle that people love to have massaged. The large base of the trapezoid is the origin which extends from the superior nuchal line on the occipital bone, down the nuchal line and then continues attaching to the spinous processes of the cervical and thoracic vertebrae. It inserts on the lateral end of the clavicle and along the scapular spine to the acromion process. As this muscle's insertion is superior to the inferior border of the muscle but inferior to the superior border of the muscle it can have opposing actions depending on whether the superior or inferior section is contracted. The superior fibers can elevate and rotate the

scapula to help abduct the arm and the inferior fibers can depress the scapula and rotate the scapula to help adduct the arm. The middle section of the muscle draws the scapula medially towards the spine although the upper and lower fibers can also perform this action if coordinated. So far, no mention is made of the head movement discussed at the beginning of this section. The trapezius can draw its origin on the occipital bone towards the scapula if it contracts while the scapula is fixed in place by

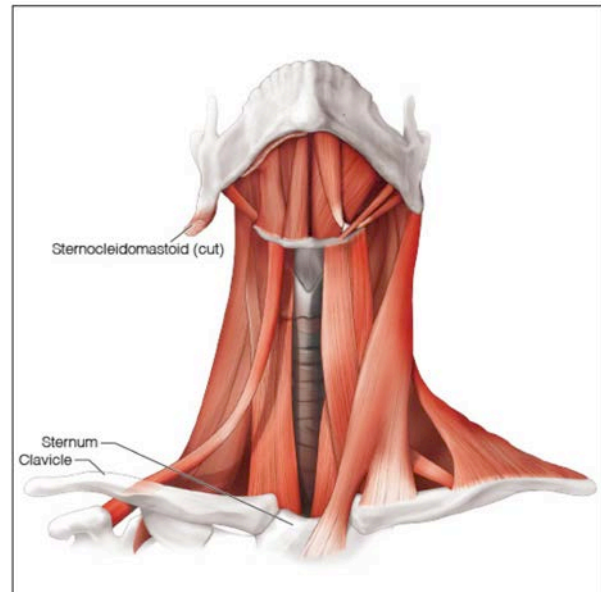


Figure 36.

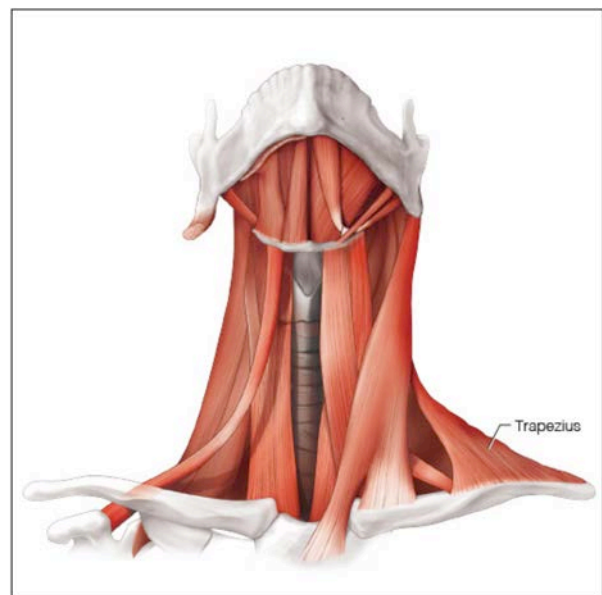


Figure 37.

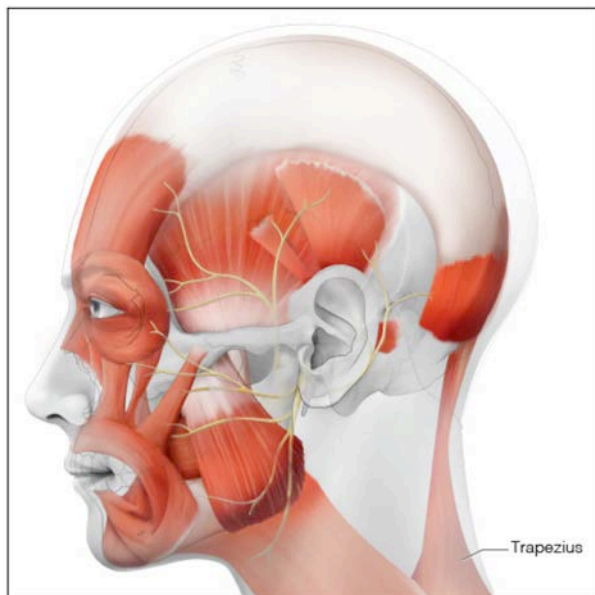


Figure 38.

other muscles. This will extend or hyperextend the head on the neck. Keeping the scapula fixed and contracting the portion of the muscle attached to the cervical vertebra will extend the neck. Using just one side of the muscle with the scapula fixed can, like the sternocleidomastoid tilt the head laterally. The innervation of this muscle while having components from the spinal accessory nerve (cranial nerve XI) also gets fibers that originate from the 2nd and 3rd cervical spinal nerves which join the spinal accessory nerve to form a continuous nerve loop in the neck.

Swallowing

Now that we have covered all the muscles of importance to dentistry in the head and neck, we can look at how they work together to perform swallowing. Once the food is chewed to break it up and moistened with saliva it is ready to be swallowed. This masticated mass is no longer regarded as food and if someone shows you this you generally are disgusted by it. This unattractive mass of chewed and moistened food is known as a bolus and it is now ready to be sent to the digestive system. Swallowing consists of a number of coordinated steps that bring the bolus to the center of the tongue, pushes it distally and propels it from the oral cavity into the pharynx. Once in the pharynx it is diverted away from

the respiratory passages into the esophagus. Similar to most other routine muscle actions in the body, like breathing, this is performed in a reflexive manner. While you do not have to think about it the muscles involved are voluntary. As the pharynx in humans is shared by both the respiratory and digestive systems coordination is vital to avoid choking. Alcohol and some drugs lessen the ability to coordinate these movements and often enough after a couple of drinks at dinner one becomes too uncoordinated to swallow properly resulting in choking with sometimes disastrous results. Because of the connection of drinking and choking these events thus have been given the moniker “café coronaries” though they can occur anywhere. We do have a built-in defense mechanism for this event in the form of the dental professional's least favorite reflex, gagging. It is generally a combination of the poor swallowing coordination and depression of the gag reflex that result in the need for the Heimlich maneuver.

With that introduction let us now look at the muscles involved in the process of swallowing. Once some food is ready to be swallowed the tongue lifts anteriorly first pressing the chewed food against the hard palate. This starts anteriorly and then continues posteriorly. As this occurs some or all of the food passes into the pharynx.

While this chewed food may take some time to get into the pharynx the rest of the process must occur quickly as breathing uses the same passages and occurs every 4-5 seconds so the food must be cleared out completely in that time frame to avoid aspirating. At this point the soft palate elevates so that it contacts the posterior pharyngeal wall protecting the nasal passages from the food. The tongue then retracts and as the pharyngeal portion of the tongue is vertical it pushes the food against the pharyngeal walls that surround it. Once the bolus is in that area the pharyngeal constrictor muscles contract in a coordinated fashion from superior to inferior forcing the food towards the esophagus.

To protect the larynx from the food several mechanisms are employed as this is a mission

critical step. It is one thing to get a pea into your nasal cavity but a very different matter to have one lodged in a bronchus. One of the mechanisms is that as posterior part of the tongue retracts it now covers the area where the larynx is. While the tongue is moving back the larynx is moving superiorly and anteriorly under the pull of the suprahyoids and one result of all of these simultaneous movement is the epiglottis, which is attached to the hyoid bone, tilts over the laryngeal opening. Finally, some muscles we have not discussed within the larynx itself, close the vocal folds against one another to seal the passage completely.

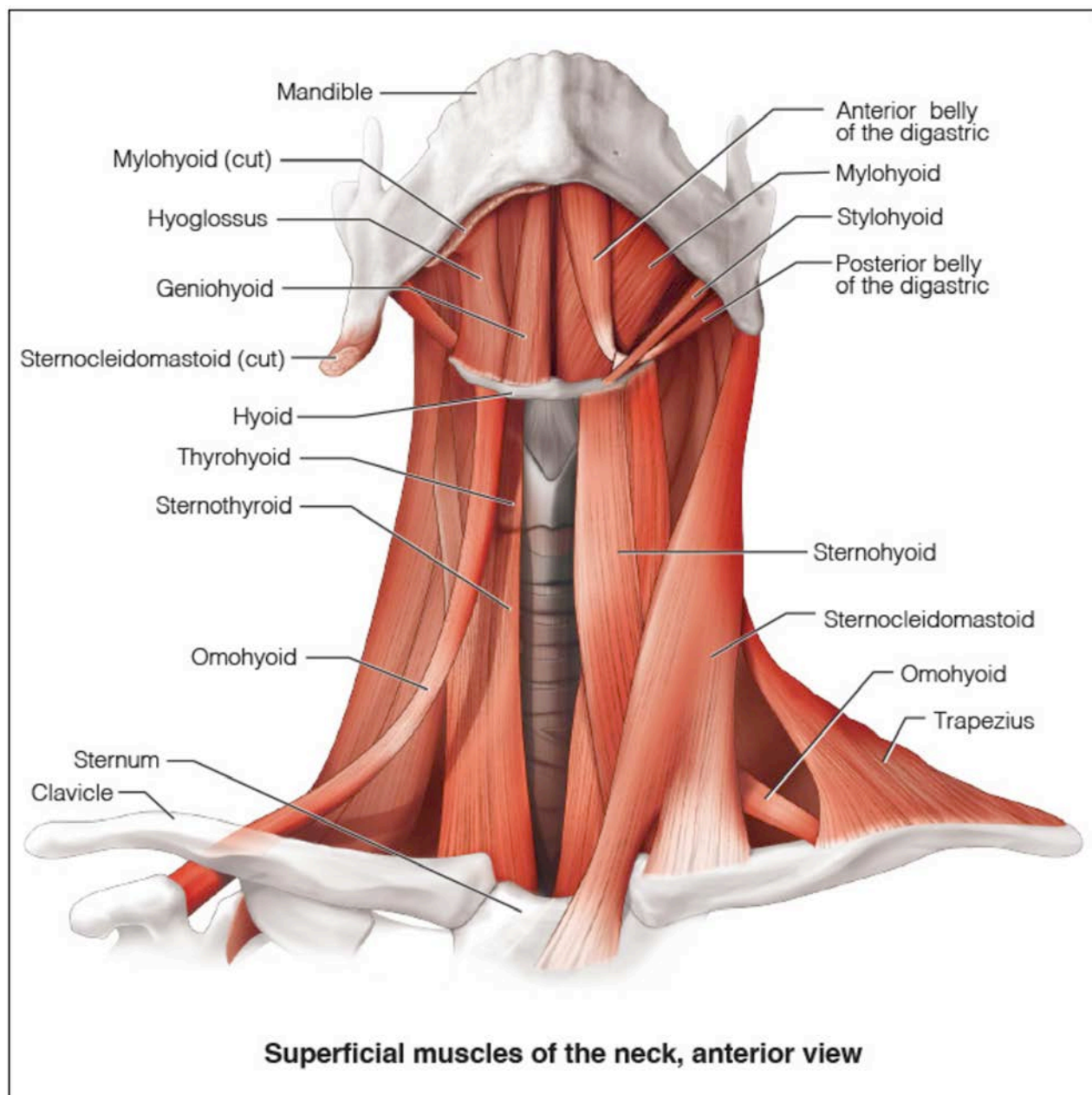
However normally, as mentioned in the discussion of the inferior pharyngeal sphincter, the esophageal opening is sealed to prevent air from entering the digestive system. The muscle fibers closing the sphincter have to relax but in addition to that the movement of the hyoid bone anteriorly and superiorly pulls the soft tissue open. The bolus which is being squeezed into the area also helps push the tissues open so the food can enter the esophagus which is normally collapsed.

Everything mentioned in the last three paragraphs takes about a second in real time. Swallowing liquids is slightly different in that the tongue does not have to gather and squeeze the liquid but rather the tongue and palate are brought together to hold the liquid in the mouth and then the tongue rises, like it does when swallowing solids, to the anterior palate but rather than squeezing the posterior portion of the tongue drops inferiorly and away from the palate essentially pouring the liquid into the pharynx.

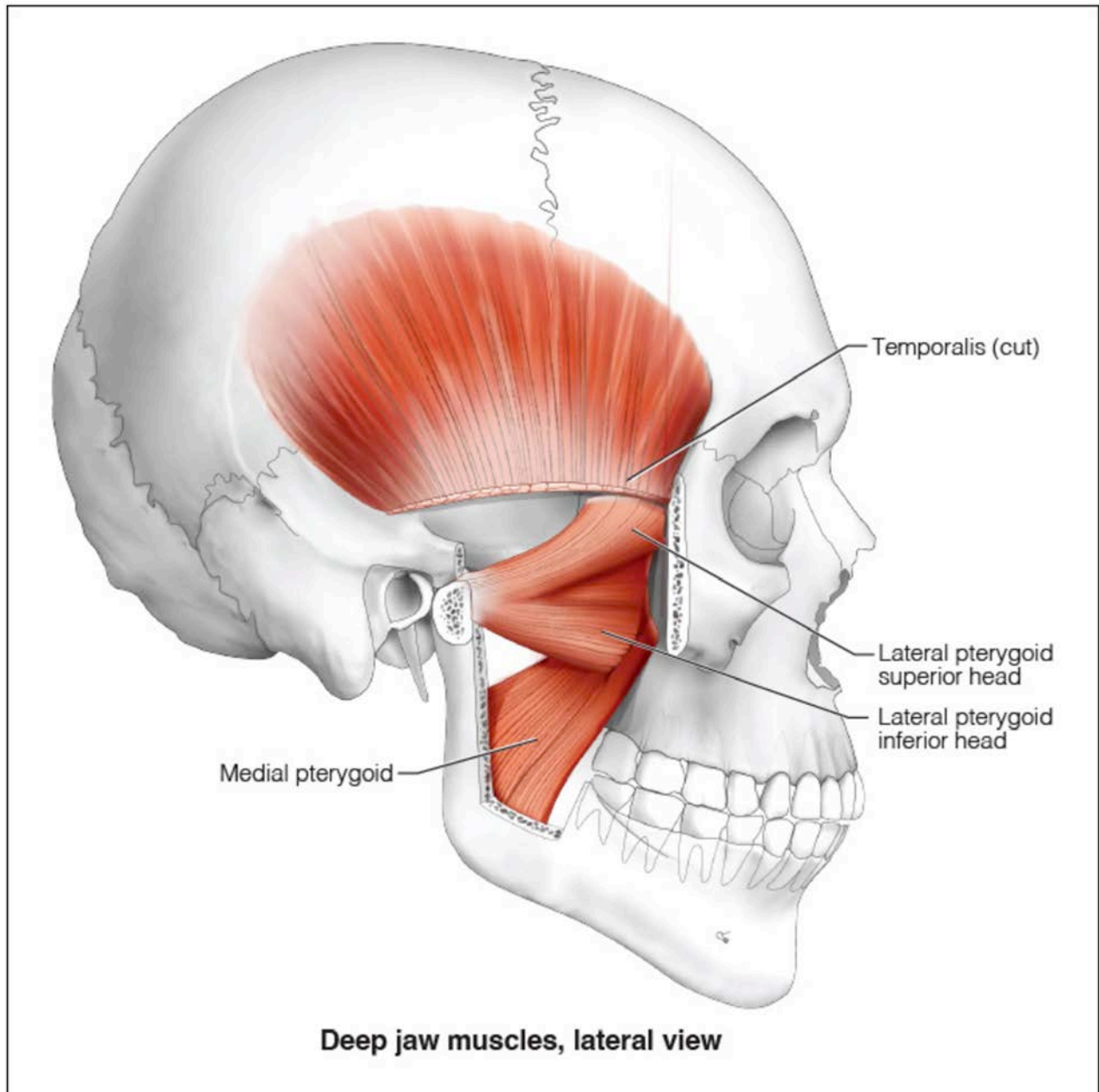
Summary

We have studied the major muscles of the head and neck in this course. Many problems encountered by patients are be related to the muscular system. Of course, the muscles do not exist in a vacuum. They are generally connected to bones and each skeletal muscle fiber relies on a nerve fiber to signal the proper time to contract so the nervous system is an important player also. Therefore, the nerves and attachment points of each muscle are important in the understanding of the skeletal muscles of the head and neck.

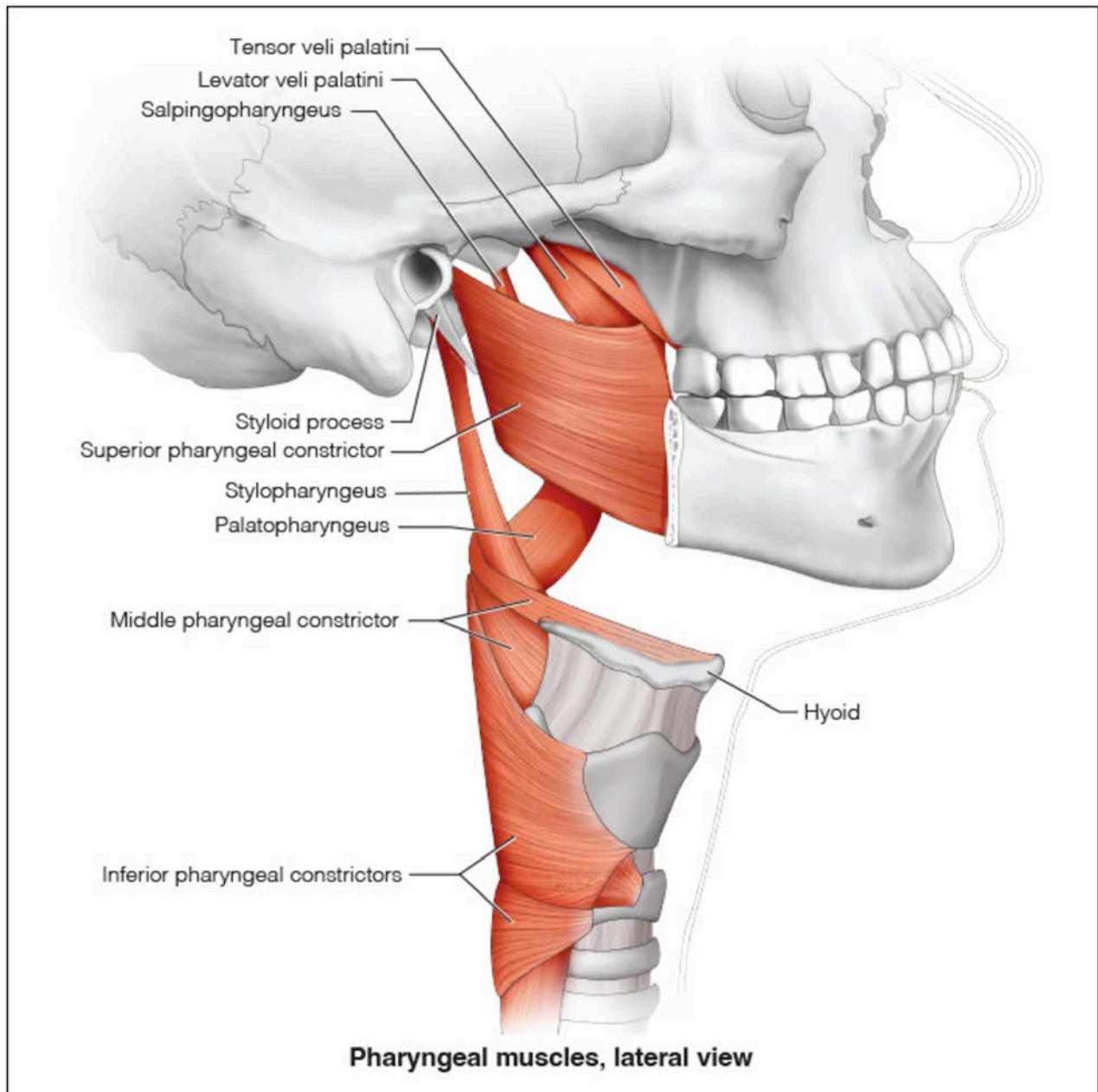
Appendix A



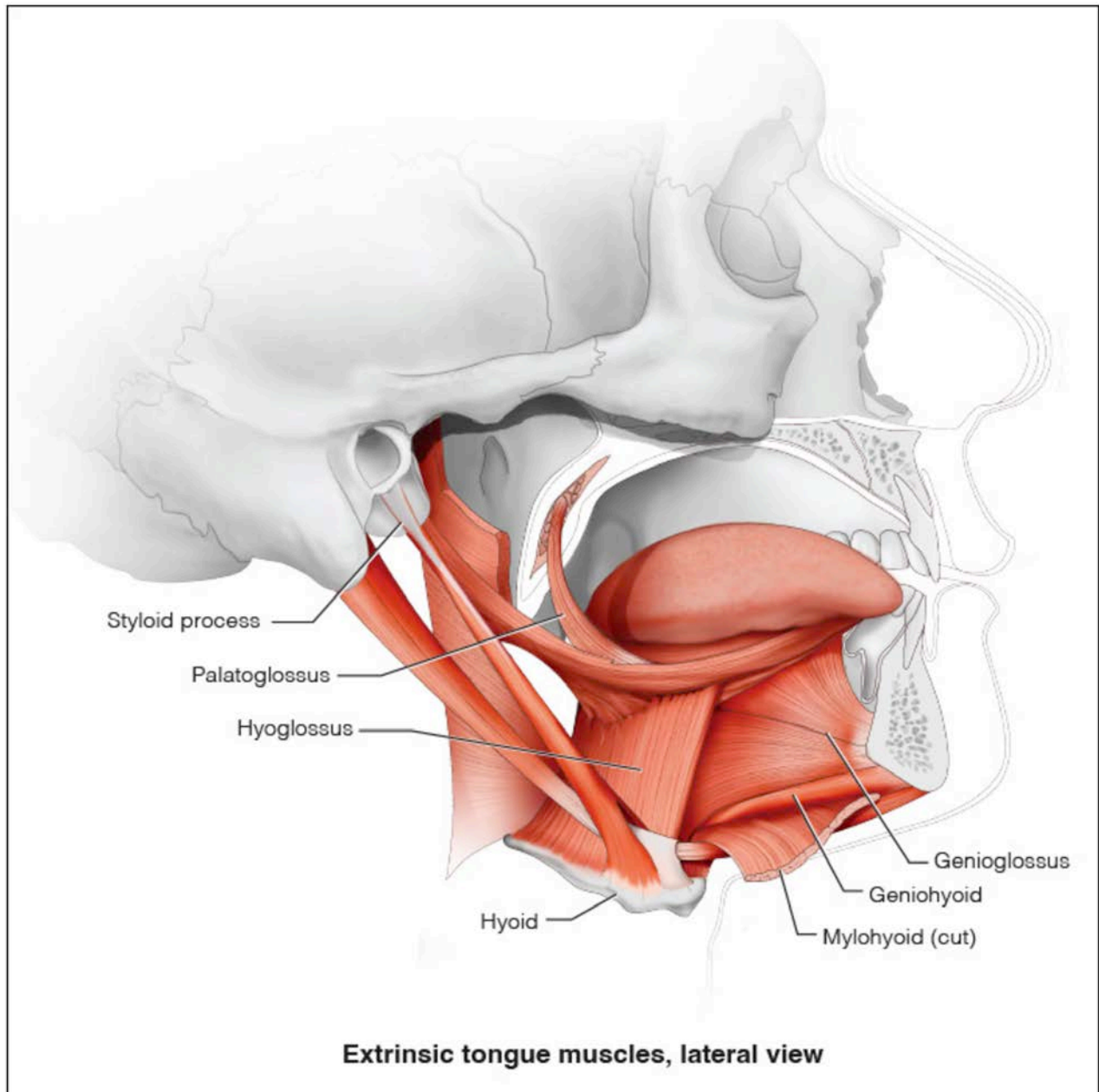
Appendix B



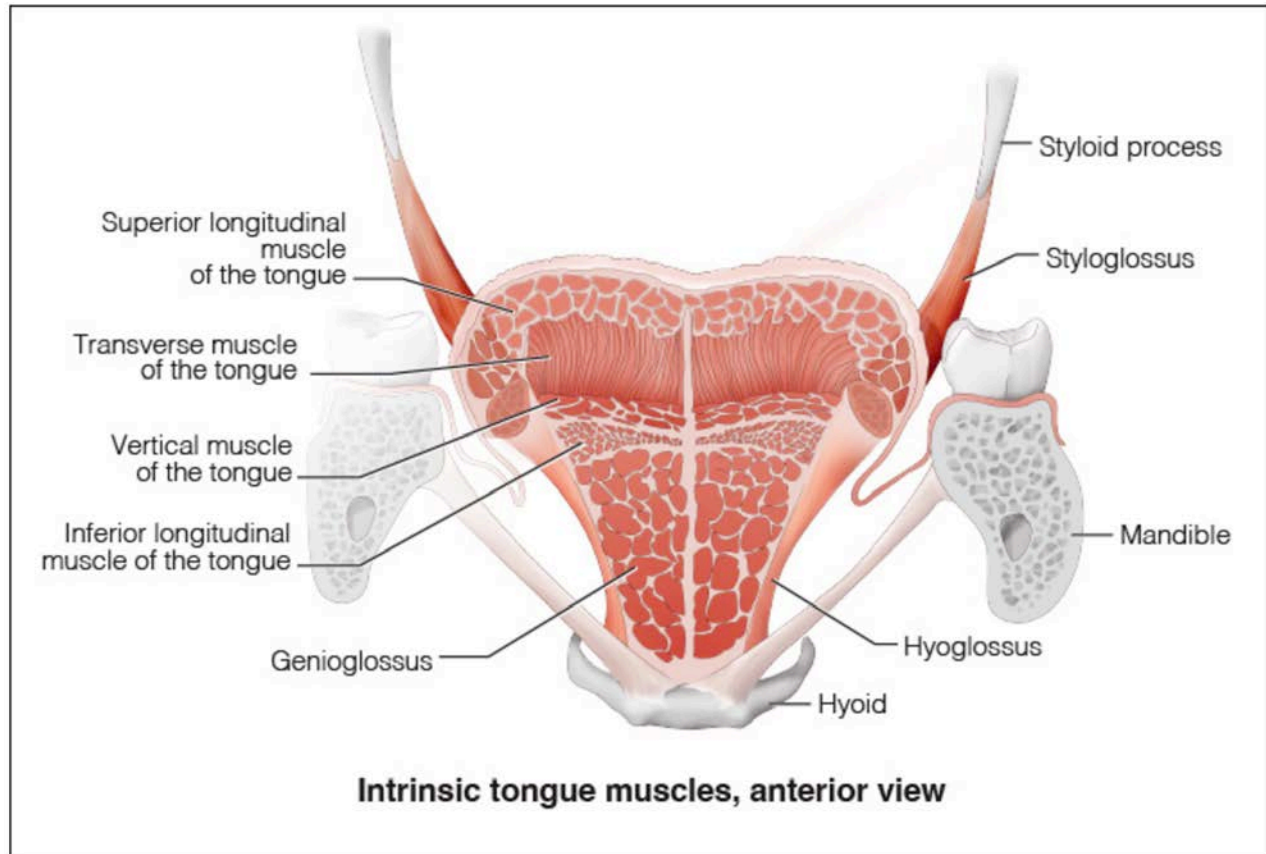
Appendix C



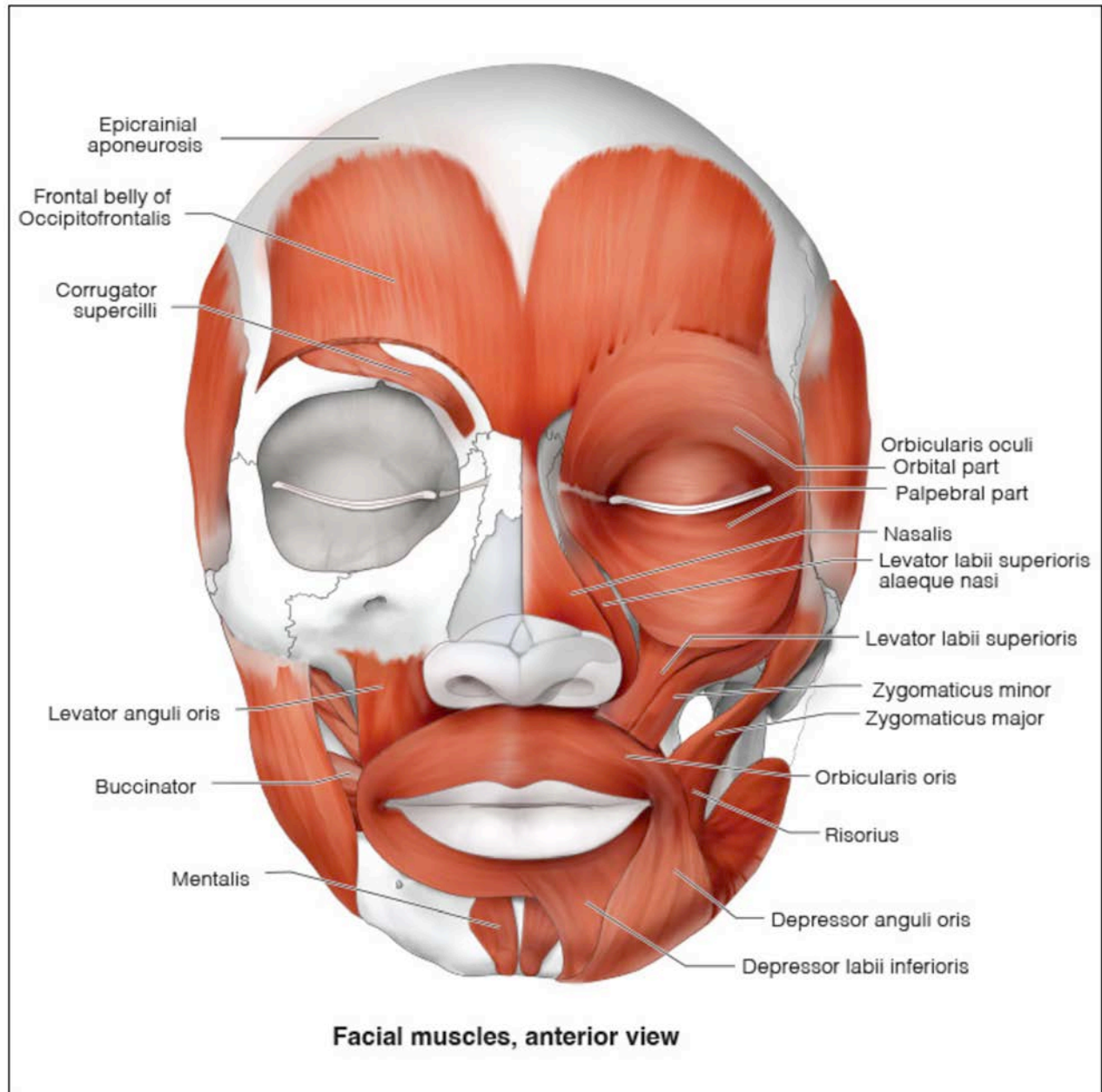
Appendix D



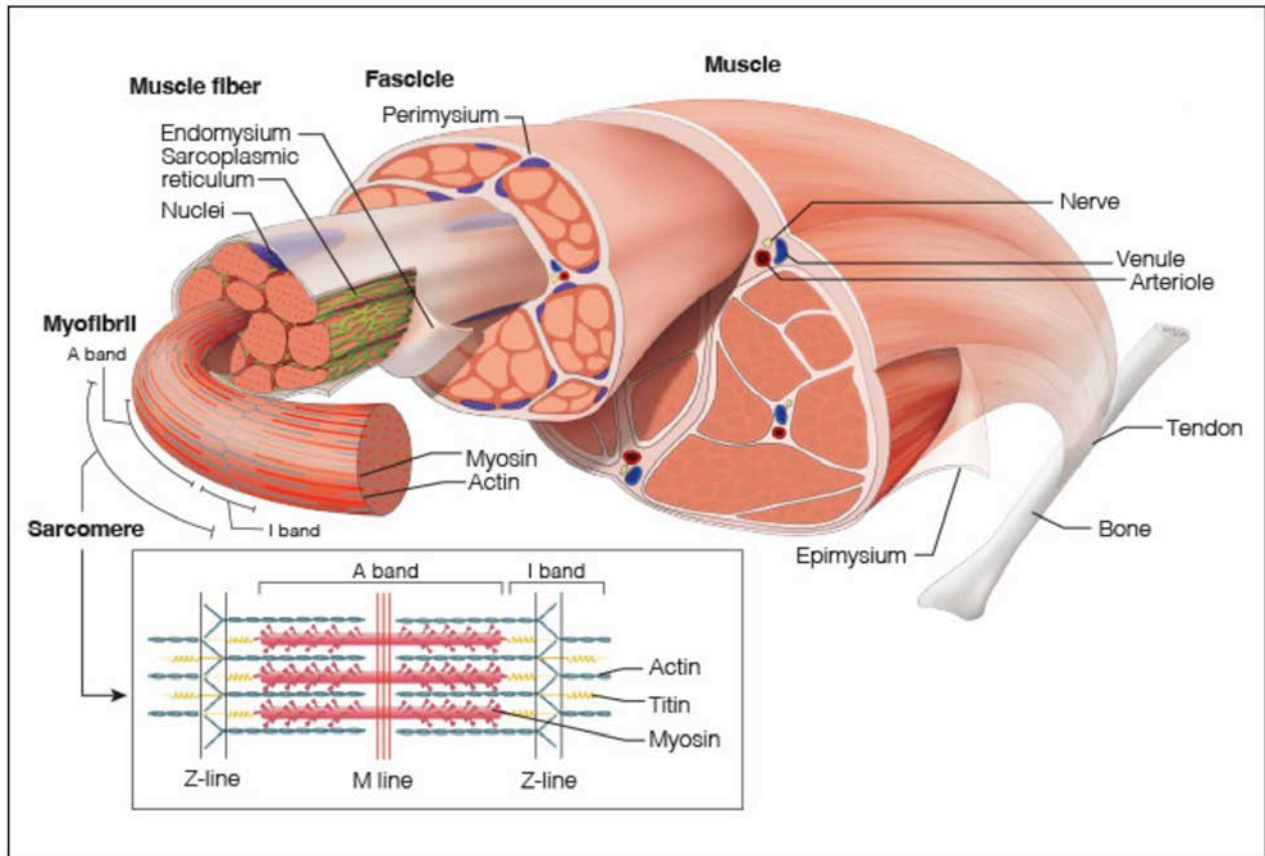
Appendix E



Appendix F



Appendix G



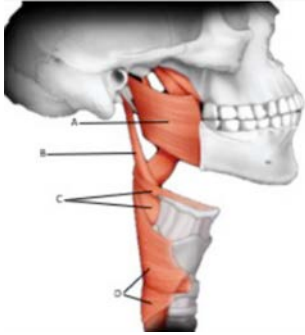
Course Test Preview

To receive Continuing Education credit for this course, you must complete the online test. Please go to: www.dentalcare.com/en-us/professional-education/ce-courses/ce597/test

- 1. It is useful to organize muscles into groups with similar properties. Which of the following muscle group would be most likely to elevate the hyoid bone?**
 - A. infrahyoids
 - B. muscles of facial expression
 - C. muscles of mastication
 - D. suprahyoids
- 2. All skeletal muscles have nerve fibers that control contraction. Which of the following muscles is innervated by the trigeminal nerve (cranial nerve V)?**
 - A. masseter
 - B. omohyoid
 - C. orbicularis oris
 - D. thyroglossus
- 3. Facial expressions are important social clues in humans. Of the following muscles which of them is involved in frowning?**
 - A. depressor anguli oris
 - B. masseter
 - C. occipitofrontalis
 - D. zygomaticus major
- 4. Muscles that move joints all have antagonists; muscles whose action opposes its action. Which of the following is most likely an antagonist to the masseter?**
 - A. buccinator
 - B. digastric
 - C. medial pterygoid
 - D. mentalis
- 5. Muscles are involved in many facial expressions. Which of the following muscles is involved in creating a smile?**
 - A. lateral pterygoid
 - B. mentalis
 - C. occipitofrontalis
 - D. zygomaticus major
- 6. Bell's palsy results in drooping of the affected side of the face and is due to damage to the facial nerve. Which group of muscles are not functioning in this condition?**
 - A. infrahyoid muscles
 - B. muscles of facial expression
 - C. muscles of mastication
 - D. suprahyoid muscles

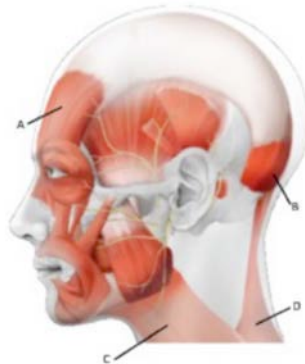
7. **The strength of a muscle is directly related to how many fibers it contains. Having a triangular shape with a broad origin allows for more fibers to concentrate force on the insertion. Which of the following muscles fits the description of having a triangular shape?**
- A. digastric
 - B. orbicularis oris
 - C. sternohyoid
 - D. temporalis
8. **Muscles connected to the hyoid that depress the mandible need other muscles to fix the hyoid solidly in place so they work. If these muscles do not contract when the geniohyoid does what action will be seen?**
- A. The hyoid will be depressed and move anteriorly.
 - B. The hyoid will be depressed and move posteriorly.
 - C. The hyoid will be elevated and move anteriorly.
 - D. The hyoid will be elevated and move posteriorly.
9. **Most muscles in the body originate from a strong bony platform. One of these areas in the skull is the zygomatic process. Which of the following muscles originates from the zygomatic arch?**
- A. masseter
 - B. medial pterygoid
 - C. temporalis
 - D. All of the above.
10. **Some muscles have no bony attachments. The intrinsic muscles of the tongue match this description. Which intrinsic tongue muscle acts to flatten and widen the tongue?**
- A. inferior longitudinal
 - B. superior longitudinal
 - C. transverse
 - D. vertical
11. **Which if the following muscles is the main muscle used to protrude the mandible?**
- A. geniohyoid
 - B. lateral pterygoid
 - C. sternocleidomastoid
 - D. temporalis
12. **What muscle forms the muscular floor of the mouth?**
- A. digastric
 - B. mylohyoid
 - C. omohyoic
 - D. vertical muscle of the tongue

13. Which letter in the figure identifies the superior pharyngeal muscle?



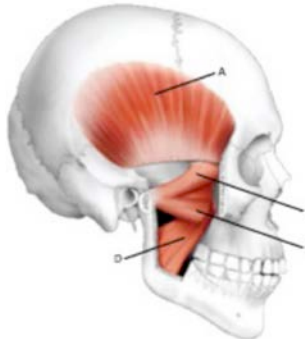
- A. A
- B. B
- C. C
- D. D

14. Which letter in the figure identifies the platysma?



- A. A
- B. B
- C. C
- D. D

15. Which letter in the figure identifies the medial pterygoid?



- A. A
- B. B
- C. C
- D. D

References

1. Brand RW, Isselhard DE. Anatomy of orofacial structures: a comprehensive approach, 7th ed. St. Louis, MO. Mosby Elsevier, 2014.
2. Fehrenbach MJ, Herring SW. Illustrated anatomy of the head and neck, 7th ed. Philadelphia, PA. W.B. Saunders Company, 1996.
3. Hiatt JL, Gartner LP, Gadd JL. Textbook of head and neck anatomy, 4th ed. Philadelphia, PA. Lippincott William & Wilkins, 2010.
4. Scheid RC, Weiß G, Woelfel JB. Woelfel's dental anatomy its relevance to dentistry, 8th ed. Philadelphia, PA. Lippincott William & Wilkins, 2012.
5. Baker EW, Schulte E, Schuenke M, Schumacher U. Head and neck anatomy for dental medicine. New York, NY. Thieme Medical Publishers Inc, 2010.
6. Weaker F. Structures of the Head and Neck. Philadelphia, PA. F.A. Davis Company, 2103.
7. Radiopedia.org. Accessed March 24, 2022.
8. NCBI. Bookshelf. Various Articles. Accessed March 24, 2022.
9. Matsuo K, Palmer JB. Anatomy and physiology of feeding and swallowing: normal and abnormal. Phys Med Rehabil Clin N Am. 2008 Nov;19(4):691-707, vii. doi: 10.1016/j.pmr.2008.06.001.

About the Author

Larry LoPresti, DMD



Dr. LoPresti has a BA from Amherst College and a DMD from Boston University Henry M. Goldman School of Dental Medicine. He has been an adjunct Professor teaching anatomy for over 20 years and is currently employed by MCPHS University Forsyth School of Dental Hygiene. In addition, he has practiced general dentistry both in private practice and FQHC dental centers. Most interestingly, he is the consulting dentist for the Roger Williams Park Zoo in Providence, RI. For the past 6 years, Dr. LoPresti has been a CODA site visitor for allied health.

Email: laurence.lopresti@mcphs.edu