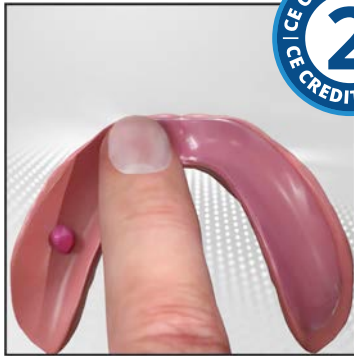

Prosthesis Retention and Effective Use of Denture Adhesive in Complete Denture Therapy



Course Author(s): Joseph J. Massad, DDS; David R. Cagna, DMD, MS

CE Credits: 2 hours

Intended Audience: Dentists, Dental Hygienists, Dental Assistants, Dental Students, Dental Hygiene Students, Dental Assistant Students

Date Course Online: 03/06/2010

Last Revision Date: 07/01/2021

Course Expiration Date: 06/30/2024

Cost: Free

Method: Self-instructional

AGD Subject Code(s): 670

Online Course: www.dentalcare.com/en-us/professional-education/ce-courses/ce360

Disclaimers:

- P&G is providing these resource materials to dental professionals. We do not own this content nor are we responsible for any material herein.
- Participants must always be aware of the hazards of using limited knowledge in integrating new techniques or procedures into their practice. Only sound evidence-based dentistry should be used in patient therapy.

Conflict of Interest Disclosure Statement

- Dr. Joseph J. Massad has done consulting work for P&G. He has no relevant financial relationships to disclose.
- Dr. David R. Cagna reports no conflicts of interest associated with this course.

Introduction

This continuing education course will review epidemiologic data on the growing older adult population and its impact on the need for complete denture therapy today and in the future. The challenges faced by the profession with respect to managing edentulism in this older adult population will also be considered. Finally, the therapeutic utility of denture adhesives, appropriate adhesive application to denture bases, and recommendations for denture and oral hygiene will be discussed and illustrated.

Course Contents

- Overview
- Learning Objectives
- Edentulism
- Complete Denture Stability and Retention
- Adhesives in Complete Denture Therapy
 - Appropriate Application of Denture Adhesive
 - Technique for Denture Adhesive Removal
- Conclusion
- Course Test
- References / Additional Resources
- About the Authors

Overview

With an ever-increasing elderly edentulous population, the dental profession is tasked to become more proficient in providing complete denture therapy, even in the face of significant residual ridge resorption. Once optimal complete denture fabrication has been achieved, the prescription of conservative and appropriate denture adhesive application can substantially aid prosthesis retention and stability, as well as facilitate patient psychological well-being. This course presents epidemiologic information detailing this needy patient population, the biomechanical phenomena of complete denture stability and retention, and the prescription and management of denture adhesive to supplement stability and retention in well-fabricated complete dentures.

Learning Objectives

Upon completion of this course, the dental professional should be able to:

- Explain the impact of a growing elderly edentulous population on the day-to-day practice of dentistry.
- Explain objectives of complete denture therapy for patients affected by progressive resorption of edentulous ridges.
- Summarize expected changes in edentulous soft and hard tissues over time.
- Summarize the complex biophysical processes involved in complete denture retention and stability.
- Explain basic comprehension of improved complete denture retention and stability associated with the proper use of denture adhesives.
- Explain appropriate methods for conservatively applying adhesive and placing complete dentures to achieve optimal adhesive performance.
- Explain the recommended methods for cleaning adhesive from complete denture upon removal from the mouth.
- Illustrate appropriate methods for accomplishing personal oral hygiene before and following removal of adhesive assisted complete dentures.
- Develop the ability to improve peripheral seal, thereby mitigating food particles creeping into the denture borders.
- Explain how malodors can be reduced with a proper seal.
- Develop the confidence to prescribe adhesive with confidence versus embarrassment.

Edentulism

The number of people in the United States requiring removable prosthodontic therapy has increased dramatically over the past twenty years.¹⁻³ Current predictions suggest that over the next two decades, the declining incidence of edentulism^{4,5} will be more than compensated by a 79% increase in adults over 55 years of age.⁶ Demographic trends for adults 80 years and older suggest an increase from 9.3 million in 2000 to 19.5 million in 2030.⁷ Though only 10% of adults 18 years and older are edentulous, this rate increases to approximately 33% for adults 65 years and older.⁸ In the United States alone, the number of adults requiring complete denture therapy is expected to increase from 33.6 million in 1991 to 37.9 million in 2020.⁶ Considering a projected decrease in edentulism, an expected increase in the number of older individuals, and the need for complete denture therapy by many patients, it has been estimated the 56.5 million complete dentures made in the United States in 2000 will increase to more than 61 million complete dentures in 2020.⁶ With the 2020 Pandemic and the fear of a financial downfall, we can conjecture patients opting for full dentures instead of implant retained dentures. This is due to the increased cost factor leading to the need to explain the adhesives and the proper usage for partial and complete dentures.

Marked atrophy of alveolar bone following tooth loss⁹⁻¹¹ complicates prosthodontic rehabilitation. This phenomenon has been termed “reduction of residual ridges” by Atwood,⁹ who considered it a major oral disease entity. Resorptive changes in residual edentulous ridges appear to be influenced by a multitude of poorly defined factors and the volume and rate of osseous changes vary dramatically between patients. Although consensus regarding etiology is lacking,¹²⁻¹⁸ alveolar bone and oral soft tissue changes observed in denture wearers may be an inevitable consequence of the loss of natural teeth, tissue remodeling, occlusal factors, and/or prolonged denture wear.¹⁸⁻²⁸ Alveolar bone loss subsequent to long-term edentulism may be severe and the process may progress throughout life.^{21,22,27,29,30} Although generally more pronounced in the mandible and characterized by individual variability in volume and rate,^{9,17,22,23,26,28,31,32} advanced residual ridge resorption presents a significant prosthodontic challenge. This oral condition complicates both the dentists’ ability to fabricate adequate complete dentures, and the patients’ ability to successfully manage their dental prostheses. In the authors’ experience, after 5 to 7 years of clinical service, a significant percentage of conventional complete dentures require re-adaptation to the denture bearing tissues using standard relines or remake procedures.

Over 50 years ago it was suggested local factors are primarily responsible for edentulous ridge resorption. Schlosser³³ implicated ill-fitting dentures and the associated trauma to oral tissues as the primary causes of rapid deterioration of the denture bearing structures. He lists faulty impressions, excessive occlusal vertical dimension, inaccurate centric jaw relationships, and occlusal disharmony as major contributing factors. Lammie³⁴ suggested a detrimental external molding force may adversely impact the residual bony ridges as overlying oral soft tissues contract or atrophy with time. This molding force may, in turn, accelerate resorption of the edentulous ridges.

In a review of 18 complete denture patients, Atwood³⁵ remarked the deterioration of

edentulous ridges is a complex biophysical process involving functional factors (i.e., the intensity and duration of applied forces), prosthetic factors (i.e., techniques and materials used in denture construction), and metabolic factors (i.e., systemic influences on bone formation and resorption). For example, occlusal parafunction may adversely affect the denture bearing tissues. It is likely many complete denture wearers limit both separation of the denture teeth and mandibular movement in order to avoid unintentional prosthesis movement or dislodgement.³⁶ If this habit occurs over extended periods of time and with sufficient force, damage to the denture bearing hard and soft tissues may result.

Others^{37,38} support Atwood’s conclusions suggesting that despite careful prosthodontic management and apparent short-term success, aggressive reduction of residual edentulous ridges may still occur. Consequently, the impact of systemic factors must be considered when deciphering the etiology of alveolar resorption. Though difficult to substantiate, an association may exist between residual ridge reduction and osteoporosis.^{9,39-41}

Complete Denture Stability and Retention

For edentulous patients, successful denture therapy is influenced by the biomechanical phenomena of support, stability, and retention.⁴²⁻⁴⁴ Retention, or the resistance to movement of the denture away from the supporting tissues, is critical. Unfortunately, the physical, physiologic, and mechanical factors associated with denture retention are not completely understood. Physical forces influencing denture retention are believed to include adhesion, cohesion, capillary attraction, surface tension, fluid viscosity, atmospheric pressure, and external forces imparted to the prostheses by oral-facial musculature.⁴⁵⁻⁵¹ Of these, interfacial surface tension associated with the saliva layer between the denture base and supporting soft tissues is quite important. This is particularly true for maxillary prostheses. Retention is realized as this saliva layer maximizes contact with approximating prosthetic and mucosal surfaces. Therefore,

xerostomic patients who experience a quantitative or qualitative reduction in saliva may have reduced complete denture retention due to decreased interfacial surface tension.⁵²⁻⁵⁴

In the maxilla, alveolar resorption may obscure anatomic landmarks required to identify an effective postpalatal seal area. An ineffective or improperly located postpalatal seal may compromise denture retention.⁵⁵ Therefore, reduced vertical alveolar height in a severely atrophic edentulous maxilla may result in poor denture stability and inadequate denture retention.^{56,57}

The typical pattern of residual ridge resorption results in the medial-lateral and anterior-posterior narrowing the maxillary denture foundation and a perceived widening of the mandibular denture foundation.⁵⁸⁻⁶² Resultant changes in horizontal maxillomandibular ridge crest relationships may necessitate setting posterior denture teeth in cross-bite. This arrangement may complicate force distribution to the denture bearing tissues. If cross-bite posterior denture occlusion is not carefully developed and managed in patients with severe residual ridge resorption, denture instability may result.⁶³

The objective of complete denture therapy for patients with severe reduction of residual ridges is not solely the replacement of missing teeth. Rather, complete dentures must be designed to replace both the missing dentition and associated supporting tissues. In doing so, the denture base may occupy a substantial volume. Since denture base coverage of the hard palate is necessary to satisfy mechanical requirements of the prosthesis, and not to replace missing anatomic structures, care must be taken to limit denture base thickness in this area. In addition to replacing missing oral tissues, complete dentures structurally redefine potential spaces within the oral cavity. Inappropriate denture tooth positioning and physiologically unacceptable denture base contour or volume may result in compromised phonetics,⁶⁴ inefficient tongue posture and function,^{59,65} and hyperactive gagging.⁶⁶⁻⁶⁹ Carefully designed external denture contours (i.e., cameo or polished denture surfaces)

may contribute substantially to prosthesis stability and retention.⁷⁰ Successful denture wearers master patterns of oral-facial muscular activity serve to retain, rather than displace, their prostheses. When optimally contoured, complete dentures occupy space in the oral cavity defined by the physiologic limits of acceptable muscular function, thus acquiring stability and retention during mastication, deglutition, and phonation.^{71,72} Conversely, poorly designed prostheses that do not accommodate anticipated muscular function may yield compromised denture stability and reduced retention.

Complete denture retention is, in part, influenced by denture occlusion. Most denture wearers consciously or subconsciously perform random, empty-mouth occlusal contacts throughout the day.⁷³ These contacts may result from functional activity (e.g., swallowing) or parafunction (e.g., bruxism or clenching). A bilaterally balanced denture occlusion is intended to minimize the adverse consequences of functional and parafunctional empty-mouth loading by widely distributing these forces to the denture bearing structures.⁷⁴ Therefore, a properly balanced denture occlusion may serve to dampen potentially detrimental occlusal forces acting to disrupt denture stability. A balanced occlusion is dependent on effective clinical and laboratory procedures. Accurate and precise registration of maxillomandibular relationships, meticulous articulation of master casts, careful positioning of denture teeth, and correct processing of denture bases must be accomplished. Both laboratory and clinical remount procedures are essential if optimal occlusal balance is to be achieved prior to delivery of the prostheses. Finally, periodic recall of all edentulous patients allows reevaluation of the denture occlusion; a clinical remount can be performed when correction is indicated.

Complete maxillary and mandibular dentures have long been considered the standard of care for treating edentulous patients. While most edentulous patients express relative satisfaction with their maxillary complete dentures, many do not enjoy equally successful

mandibular denture comfort and function.^{75,76} The use of endosseous dental implants to assist in the support, stability, and retention of removable prostheses is now considered an effective treatment modality for the edentulous patient. Individuals wearing implant-assisted overdentures typically report improved oral comfort and function when compared to conventional, mucosa-supported prostheses.⁷⁷⁻⁸² Except when contraindicated due to financial or surgical considerations, implant-assisted overdentures are usually the treatment of choice. A symposium held at McGill University addressed the efficacy of implant-assisted overdentures for treatment of edentulism. After thorough review of existing information, the following consensus statement was formulated:

“The evidence currently available suggests that the restoration of the edentulous mandible with a conventional denture is no longer the most appropriate first choice prosthodontic treatment. There is now overwhelming evidence that a two-implant overdenture should become the first choice of treatment for the edentulous mandible.”⁸³ However, the placement of only 2 implants is crucial as to proper spread, and the shape of the ridge to be effective in retention without anterior posterior rocking.

A *poorly constructed* denture that requires adhesive usage does not follow the intent of this course’s purpose. The intent is that if a denture is properly fabricated according to the best practice procedures, then dental adhesive usage cited in this course will be benefited and the practitioner should not be embarrassed in recommending its usage.

Adhesives in Complete Denture Therapy

Successful complete denture therapy must involve both technical excellence during prosthesis fabrication and effective patient management prior to and following complete denture placement. Satisfying the expectations of all patients for optimal denture retention and stability is often beyond the technical skills

of even the most accomplished practitioners. A substantial number of complete denture wearers remedy perceived inadequacies in denture retention and stability with denture adhesives.⁸⁴ Discussing and implementing the judicious use of denture adhesives may help to satisfy the expectations of specific patients and achieve their intended treatment goals.

It is appropriate to prescribe a denture adhesive to augment retention and stability of conventional complete dentures.⁸⁵⁻⁹⁴ Adhesives are indicated for routine use when appropriately fabricated complete dentures do not satisfy stability and retention expectations of the patient.⁵¹ Denture adhesives may also prove psychologically beneficial^{95,96} when the patient requires supplemental retention and stability, particularly during times of public interaction. Denture adhesives are not indicated to provide retention for ill-fitting prostheses, nor are excessive amounts of adhesive indicated under any circumstances.⁹⁷

When properly managed, adhesives enhance the interfacial surface tension between the denture base and supporting soft tissues by:

1. improving the adhesive, cohesive, and viscosity characteristics of the interfacial film layer, particularly in saliva-deficient patients, and
2. eliminating voids occurring in the interfacial space due to inaccurate adaptation of the denture base to the denture-bearing tissues.⁵¹

In addition to improved retention and stability, denture adhesives have been shown to reduce mucosal irritation, reduce food debris accumulation beneath the denture base, decrease excess food particles, decrease mal odors, improve chewing efficiency, increase bite force, improve functional load distribution across the denture-bearing tissues, and facilitate the psychological well-being of the patient.^{51,95,99-103} For patients with xerostomia, the use of a well-hydrated denture adhesive provides a cushioning or lubricating effect, reducing frictional irritation of the supporting soft tissues and preventing further tissue dehydration.^{54,104}

The composition of most modern denture adhesives includes constituents that promote bioadhesion via carboxyl groups once the adhesive is hydrated. Two commonly employed active ingredients in denture adhesives are poly [vinyl methyl ether maleate] and carboxymethylcellulose. The physical chemistry of these adhesive constituents is discussed in detail elsewhere.^{51,95,105} Once placed on the intaglio surface of the denture, the adhesive material must be substantially hydrated in order to achieve optimal performance.

Following complete denture fabrication and prior to definitive placement of the prostheses, it is prudent to reemphasize to the patient the anticipated outcome of therapy. For patients with favorable anatomic, physiologic, and psychological factors, including extensive denture wearing experience, the anticipated outcome of complete denture therapy may be favorable. Conversely, for individuals who display compromised anatomic oral conditions, poor muscular control, psychological indifference, or a lack of successful denture experience, a fair or guarded prognosis is likely more realistic. Discussing reasonable expectations with the patient prior to placing complete dentures may prepare them for an otherwise disappointing experience.

It is appropriate to prescribe adhesive to augment retention and stability of conventional complete dentures. Anticipating suboptimal

stability and retention in the presence of compromised patient factors, e.g., xerostomia, is justified. Informing patients the proper use of a limited amount of denture adhesive can supplement existing denture stability and retention is both clinically acceptable and a prudent patient management technique. The need for denture adhesive is not necessarily an indication of suboptimal therapy, or admission of failure by either the dentist or patient.

Most denture wearers, at one time or another, have attempted to use adhesive to facilitate comfortable denture wear and function. Unfortunately, the concept that “more is better” does not hold true for denture adhesives. Table 1 presents an approach to appropriate denture adhesive application and prosthesis placement the authors find useful. It is equally important to educate patients regarding an effective method for adhesive removal from denture surfaces and oral tissues on a regular basis. Appropriate denture and oral hygiene should be accomplished by edentulous patients at least two times each day, as described and illustrated in Table 2.

Immediately prior to the daily adhesive application it is suggested that the patient massage all the oral tissues with a oscillating rotating electric toothbrush with water in the mouth to promote hydration and increase oxygen levels into the tissues creating the optimal tissue environment (Figure 11).

Appropriate Application of Denture Adhesive

Table 1. Appropriate Application of Denture Adhesive.

1. Inform the patient that, due to existing conditions, achieving optimal complete denture retention and stability may not be possible. Also suggest the proper use of denture adhesive is an acceptable means of augmenting the stability and retention of a new prosthesis. Honest and realistic communication of the anticipated results of therapy may ease future patient management problems.
2. The use of small amounts of hydrated paste adhesives works well due to favorable adhesive, cohesive, and viscosity characteristics (Figure 1).

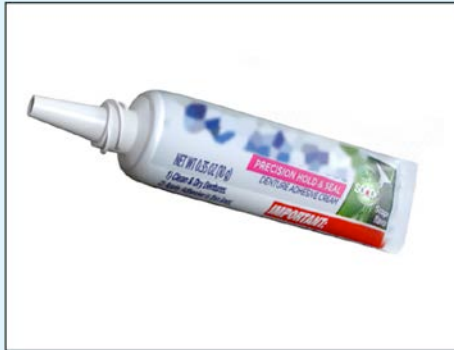


Figure 1. Small dispensing nozzle tube supports use of minimal adhesive.

3. A small amount of the paste should be dispensed onto the clean and dry (Figure 2) intaglio surface of the denture. The use of excessive adhesive will likely interfere with proper placement of the denture on the bearing tissues. For the maxillary denture, adhesive should be dispensed in the midpalatal region, while for the mandibular denture very small amounts can be placed in two or three locations along the ridge crest (Figure 3).




Figure 2. Thoroughly dry denture.



Figure 3. Adhesive application to mandibular denture.

4. Once dispensed onto the dentures, the patient should evenly disperse the paste over the entire intaglio surface of the prosthesis with a clean, dry finger (Figure 4). This will result in a thin, even layer of adhesive.

Table 1. Continued.

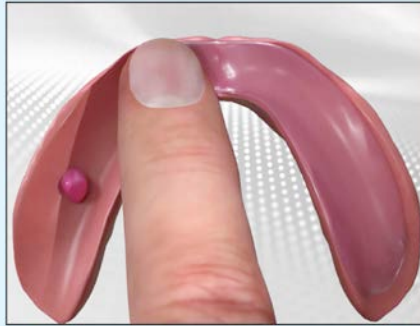


Figure 4. Adhesive dispersed over intaglio surface making a thin layer.

5. The denture is submersed in a container of cool water for only a few seconds to maximally hydrate the adhesive (Figure 5). The denture should remain submersed in water for approximately 2 to 3 seconds.



Figure 5. Denture submersed in cool water to hydrate adhesive.

6. The denture is then placed in the mouth and firmly seated with finger pressure for approximately 10 seconds (Figure 6). Maintenance of seating pressure will cause the adhesive to flow throughout the interfacial space between the denture base and the denture bearing soft tissues.

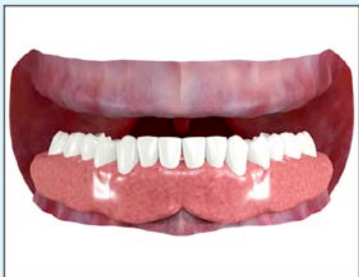

Figure 6A. Denture placed and firmly seated.

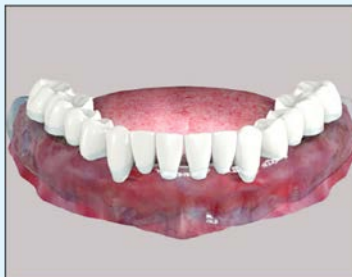

Figure 6B. Seat with figure pressure.

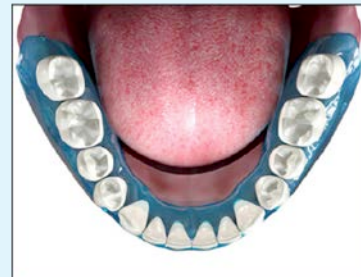

Figure 6C. Adhesive spreads evenly.

7. The patient may be provided with the sample container of adhesive used during the demonstration. Suggesting local stores that carry this product will emphasize that adhesive use is a component of regular denture use. The patient should be told that the use of excessive adhesive may indicate an inadequate fit, necessitating denture reline or remake procedures.

Technique for Denture Adhesive Removal

Table 2. Technique for Denture Adhesive Removal.

1. Use of an electric toothbrush can enhance thorough cleaning of both denture surfaces and denture bearing oral tissues (Figure 7). Reasonably priced electric brushes are now widely available to consumers. A small amount of toothpaste on the electric toothbrush will serve to freshen the patient's breath and improved taste (Figure 8).

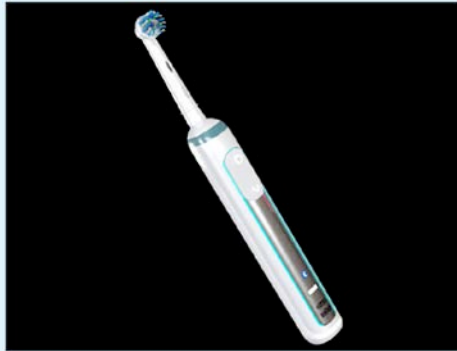


Figure 7. Electric powered toothbrush.

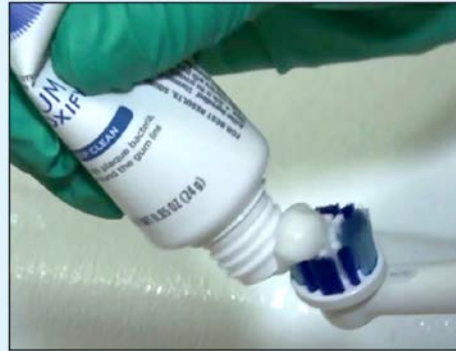

Figure 8. Small amount of toothpaste dispensed onto toothbrush.

2. Remove the denture from the mouth and hold submerged in a container of warm water and simultaneously scrubbed using the electric toothbrush (Figure 9). Firm pressure should be applied to the brush in order to eliminate adhesive from the denture surface. Particles or clumps of adhesive material will be seen rising to the surface of the water. This submerged water decouples the cellulose by over saturation, thereby decoupling the adhesive (Figure 10). This procedure is continued until the entire denture surface is free of residual adhesive.



Figure 9. Final scrubbing with denture submerged in warm water.

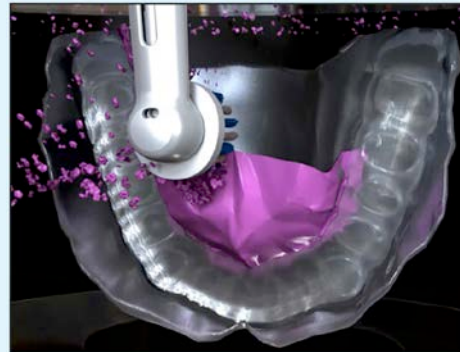


Figure 10. Particulate debris removed from denture is seen rising to surface of warm water.

3. To clean and stimulate the oral tissues, the electric toothbrush may again be used. A small amount of toothpaste is applied to the brush. All denture bearing soft tissues and tissues that contact the cameo surfaces of the dentures, including the tongue, are gently massaged (Figure 11). At first, this may cause a tingling sensation for the patient. This sensation will disappear with repeated use.

Table 2. Continued.

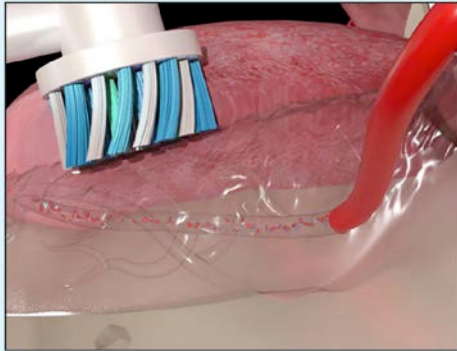



Figure 11. Initial massaging of oral tissues with an electric toothbrush with water in mouth while pursing lips together to allow improved hydration and accelerate red blood cells to release O₂ into the tissues.



4. Following thorough massaging of the oral soft tissues, warm water is introduced into the patient's mouth (Figure 12). Holding this water in the mouth, the electric toothbrush is again used to massage all oral soft tissues (Figure 13). The patient is then instructed to expectorate the water and residual debris into a sink, leaving the oral tissue free of adhesive.

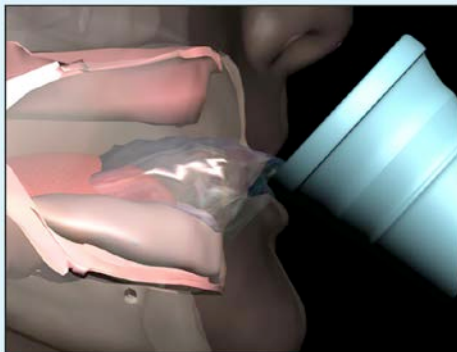


Figure 12. Introduction of warm water into patient's mouth.

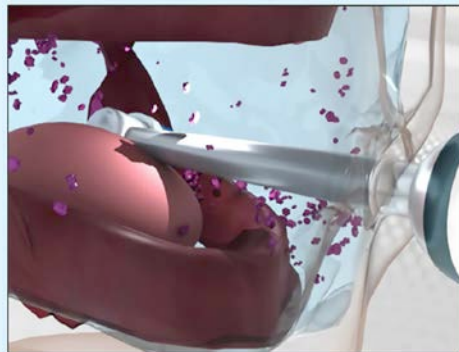


Figure 13. With warm water in mouth, patient continues oral tissue massage until adhesive elimination is complete.

Conclusion

The phenomenon of residual ridge reduction following the loss of natural teeth, and its impact on successful complete denture therapy, have been reviewed. Anatomic, physiologic, and biomechanical factors associated with the stability and retention of complete dentures impact optimal therapeutic results. The proper use of denture adhesive to supplement, not substitute for, sound complete denture therapy should be carefully and thoroughly presented to patients prior

to placement of new prostheses. Denture adhesives can be effectively used to augment denture stability and retention in well-fitting complete dentures leading to improved denture performance, patient comfort, and patient satisfaction while improving tissue health. Inappropriate use of denture adhesive, outside the recommendations provided here, may adversely impact denture performance, patient health and overall treatment satisfaction.

Course Test Preview

To receive Continuing Education credit for this course, you must complete the online test. Please go to: www.dentalcare.com/en-us/professional-education/ce-courses/ce360/test

- 1. Over the past 26 years, what change has occurred in the number of people in the United States requiring removable prosthodontics therapy?**
 - A. The number has basically stayed the same.
 - B. The number has declined slightly.
 - C. The number has increased dramatically.
 - D. Data are unavailable to answer this question.
- 2. Over the next two decades, what is projected with respect to the incidence of edentulism?**
 - A. The incidence is expected to increase significantly.
 - B. The incidence is expected to decline.
 - C. The incidence may increase but data are unavailable to support any conclusions.
 - D. The incidence will likely remain unchanged.
- 3. What was the phrase proposed by Douglas Atwood (1971) to describe marked atrophy of alveolar bone following tooth loss?**
 - A. Residual ridge resorption
 - B. Ridge atrophy
 - C. Alveolar bone atrophy
 - D. Reduction of residual ridges
- 4. Although consensus regarding etiology is lacking, alveolar bone and soft tissue changes observed in complete denture wearers over time may be associated with all of the following EXCEPT:**
 - A. Bisphosphonate related osteonecrosis of bone
 - B. Tissue remodeling
 - C. Inevitable consequence of natural teeth loss
 - D. Occlusal factors
- 5. In 1962, Dr. Atwood reported on factors that likely contributed to the complex biophysical deterioration of edentulous ridges over time. Which of the following factors did Dr. Atwood not discuss?**
 - A. Functional factors
 - B. Prosthetic factors
 - C. Metabolic factors
 - D. Environmental factors
- 6. The biomechanical phenomena that substantially influence complete denture success include all of the following EXCEPT:**
 - A. Support
 - B. Leverage
 - C. Stability
 - D. Retention
- 7. Physical forces influencing complete denture retention are believed to include all of the following EXCEPT:**
 - A. Cohesion and capillary attraction
 - B. Adhesion and surface tension
 - C. Fluid viscosity and atmospheric pressure
 - D. Preload and wear resistance

- 8. Inappropriate denture tooth positioning and physiologically unacceptable denture base contour or volume may result in all of the following EXCEPT:**
- A. Sleep apnea
 - B. Hyperactive gag reflex
 - C. Compromised phonetics
 - D. Inefficient tongue posture and function
- 9. What is the primary intended benefit of bilaterally balanced occlusion in complete dentures?**
- A. Maximize the esthetic outcome of complete denture therapy during smile analysis.
 - B. Improve oropharyngeal opening to minimize sleep apnea.
 - C. Minimize adverse consequences related to functional and parafunction, empty-mouth, occlusal contacts.
 - D. Reduce adverse biocompatibility issues with denture tooth resins.
- 10. When properly managed, adhesives satisfy all of the following EXCEPT:**
- A. Enhanced interfacial surface tension between the denture base and supporting soft tissue.
 - B. Improved adhesive, cohesive, and viscosity characteristic of the interfacial film layer.
 - C. Elimination of voids occurring in the interfacial space due to inaccurate intaglio surface contact.
 - D. Chemical alteration of the polymeric nature of the denture resin to foster better adaptation.
- 11. Which of the following benefits are not associated with the use of denture adhesive?**
- A. Reduce food debris accumulation beneath the denture base
 - B. Improved chewing efficiency
 - C. Improved coloration of the denture base material
 - D. Reduced mucosal irritation
- 12. What are the advantages of prescribing well-hydrated denture adhesive for xerostomic complete denture patients?**
- A. Facilitates clean ability of the denture.
 - B. Increases frictional stability of the prosthesis.
 - C. Improves the tissue volume creating cushioning and lubricating effect.
 - D. Permits ease of prosthesis placement and removal.
- 13. Which of the following constituents are commonly found in most modern denture adhesives?**
- A. Silicone
 - B. Carboxymethylcellulose
 - C. Polysulfide
 - D. Polyvinyl Siloxane
- 14. Given which of the following circumstances would unsuccessful complete denture therapy be anticipated?**
- A. Favorable physiologic factors.
 - B. Extensive denture wearing experience.
 - C. Favorable anatomic factors.
 - D. Unrealistic patient expectation.

- 15. Once dispensed onto the denture's intaglio surface, how should the adhesive be manipulated?**
- A. Simply seat the denture using heavy pressure.
 - B. Allow time for the adhesive to warm on the denture surface to facilitate adhesion.
 - C. Evenly disperse the adhesive over the entire intaglio surface with a clean, dry finger.
 - D. No additional manipulation is necessary.
- 16. With regard to appropriate denture hygiene, which of the following represents a step in the recommended process?**
- A. Use an electric toothbrush to enhance thorough cleaning of all denture surfaces.
 - B. Apply a highly abrasive cleanser to a stiff bristle brush and scrub the denture thoroughly.
 - C. Mechanical cleaning of the denture is not recommended.
 - D. Using a water-picking devices four times daily.
- 17. With regards to appropriate dental hygiene of the edentulous patient, massaging the oral tissues while water is in the mouth will promote which of the following?**
- A. Increase tissue hydration.
 - B. Create abrasion of the tissues.
 - C. Decreases bacteria.
 - D. Damages tissue.
- 18. With regards to oral hygiene, what is the benefit of using an electric toothbrush to massage all of the oral tissues?**
- A. No appreciable benefit is accomplished.
 - B. Oral tissues become more rigid.
 - C. Infuse the oral tissues with additional oxygen.
 - D. There is no benefit in using an electric toothbrush.
- 19. In regard to the method of removing dental adhesive from the patient's tissues, what is the best procedure to follow?**
- A. Take a wet 2 x 2 gauze and rub the adhesive off the tissue.
 - B. Rent the oral cavity with an alcohol containing oral rinse.
 - C. With the use of an electric toothbrush with warm water into the mouth and massage the tissues.
 - D. Use a Waterpik to remove adhesive.
- 20. In regard to removing adhesive from a denture, what is the best method to use?**
- A. Use a washcloth and rub it until it is gone.
 - B. Use a hard toothbrush and scrub it.
 - C. Put the denture appliance in a bowl of warm water and then use an electric toothbrush to rub over all surfaces where there is adhesive.
 - D. Place in a cup of ice to harden then pick off the adhesive.
- 21. Which of the following is NOT a result of the use of denture adhesive?**
- A. Reduced mouth odor.
 - B. Reduced food impactment around the border.
 - C. Patient confidence is improved.
 - D. The patients who use more adhesive are happier.

- 22. With regard to personal oral hygiene for complete denture patients, which of the following represents a step in the recommended process?**
- A. Edentulous patients do not need hygiene since they do not have teeth.
 - B. Use cold water to rinse residual adhesive from the oral tissues.
 - C. Use a cold, wet face cloth to wipe residual adhesive from the denture bearing soft tissues.
 - D. Use an electric tooth brush to clean all oral cavity.
- 23. When are adhesives indicated for routine use by complete denture patients?**
- A. When reline or rebase procedures are otherwise required.
 - B. When the complete dentures have been appropriately fabricated.
 - C. When the prostheses are worn out and are loose and rocking.
 - D. When the patient is confident that retention is adequate for public speaking engagements.
- 24. After applying adhesive to the denture's intaglio surface and immediately prior to placing the denture in the mouth, what step(s) should be accomplished?**
- A. When reline or rebase procedures are otherwise required.
 - B. When the complete dentures have been appropriately fabricated.
 - C. When the prostheses are worn out and are loose and rocking.
 - D. When the patient is confident that retention is adequate for public speaking engagements.
- 25. Once dispensed onto the denture's intaglio surface, how should the adhesive be manipulated?**
- A. Simply seat the denture using heavy pressure.
 - B. Allow time for the adhesive to warm on the denture surface to facilitate adhesion.
 - C. Evenly disperse an even thin layer of adhesive over the entire intaglio surface with a clean, dry finger.
 - D. No additional manipulation is necessary.
- 26. An appropriate technique for applying denture adhesive to the intaglio surface of a denture includes which of the following actions?**
- A. Thoroughly hydrate the denture base resin.
 - B. Start with a denture surface that is completely clean and very dry.
 - C. In the maxillary denture dispense a large amount of adhesive along the ridge crest area.
 - D. Limit adhesive application to the anterior aspect of the mandibular denture.

References

1. Kapur KK. Management of the edentulous elderly patient. *Gerodontology*. 1987 Feb;3(1):51-4.
2. Douglass CW, Gammon MD, Atwood DA. Need and effective demand for prosthodontic treatment. A report: Part one. *Oral Health*. 1988 Nov;78(11):11-7, 21-3.
3. Douglass CW, Gammon MD, Atwood DA. Need and effective demand for prosthodontic treatment. *J Prosthet Dent*. 1988 Jan;59(1):94-104. doi: 10.1016/0022-3913(88)90117-5.
4. Weintraub JA, Burt BA. Oral health status in the United States: tooth loss and edentulism. *J Dent Educ*. 1985 Jun;49(6):368-78.
5. Marcus SE, Drury TF, Brown LJ, Zion GR. Tooth retention and tooth loss in the permanent dentition of adults: United States, 1988-1991. *J Dent Res*. 1996 Feb;75 Spec No:684-95. doi: 10.1177/002203459607502508.
6. Douglass CW, Shih A, Ostry L. Will there be a need for complete dentures in the United States in 2020? *J Prosthet Dent*. 2002 Jan;87(1):5-8. doi: 10.1067/mpr.2002.121203.
7. Centers for Disease Control and Prevention (CDC). Trends in aging--United States and worldwide. *MMWR Morb Mortal Wkly Rep*. 2003 Feb 14;52(6):101-4, 106.
8. NIH. National Institute of Dental and Craniofacial Research. Oral Health in America: A Report of the Surgeon General-- Executive Summary. 2000 Jul, 66-67. Accessed May 24, 2021.
9. Atwood DA. Reduction of residual ridges: a major oral disease entity. *J Prosthet Dent*. 1971 Sep;26(3):266-79. doi: 10.1016/0022-3913(71)90069-2.
10. Cawood JI, Howell RA. A classification of the edentulous jaws. *Int J Oral Maxillofac Surg*. 1988 Aug;17(4):232-6. doi: 10.1016/s0901-5027(88)80047-x.
11. Cawood JI, Howell RA. Reconstructive preprosthetic surgery. I. Anatomical considerations. *Int J Oral Maxillofac Surg*. 1991 Apr;20(2):75-82. doi: 10.1016/s0901-5027(05)80711-8.
12. Ortman HR. Factors of Bone Resorption of the Residual Ridge. *J Prosthet Dent*. 1962 May;12(3):429-40. doi: 10.1016/0022-3913(62)90124-5. Accessed May 24, 2021.
13. Carlsson GE, Ragnarson N, Astrand P. Changes in height of the alveolar process in edentulous segments. A longitudinal clinical and radiographic study of full upper denture cases with residual lower anteriors. *Odontol Tidskr*. 1967 Jun;75(3):193-208.
14. Baxter JC. Relationship of osteoporosis to excessive residual ridge resorption. *J Prosthet Dent*. 1981 Aug;46(2):123-5. doi: 10.1016/0022-3913(81)90292-4.
15. Devlin H, Ferguson MW. Alveolar ridge resorption and mandibular atrophy. A review of the role of local and systemic factors. *Br Dent J*. 1991 Feb 9;170(3):101-4. doi: 10.1038/sj.bdj.4807427.
16. Klemetti E. A review of residual ridge resorption and bone density. *J Prosthet Dent*. 1996 May;75(5):512-4. doi: 10.1016/s0022-3913(96)90455-2.
17. Jahangiri L, Devlin H, Ting K, Nishimura I. Current perspectives in residual ridge remodeling and its clinical implications: a review. *J Prosthet Dent*. 1998 Aug;80(2):224-37. doi: 10.1016/s0022-3913(98)70116-7.
18. Kelly E. Changes caused by a mandibular removable partial denture opposing a maxillary complete denture. *J Prosthet Dent*. 1972 Feb;27(2):140-50. doi: 10.1016/0022-3913(72)90190-4.
19. Campbell RL. A comparative study of the resorption of the alveolar ridges in denture-wearers and non-denture-wearers. *J Am Dent Assoc*. 1960 Feb;60:143-53. doi: 10.14219/jada.archive.1960.0031.
20. Smith DE, Kydd WL, Wykhuis WA, et al. The Mobility of Artificial Dentures During Communion. *J Prosthet Dent*. 1963 Sep;13(5):839-56. doi: 10.1016/0022-3913(63)90228-2. Accessed May 24, 2021.
21. Carlsson GE, Bergman B, Hedegård B. Changes in contour of the maxillary alveolar process under immediate dentures. A longitudinal clinical and x-ray cephalometric study covering 5 years. *Acta Odontol Scand*. 1967 Jun;25(1):45-75. doi: 10.3109/00016356709072522.
22. Atwood DA, Coy WA. Clinical, cephalometric, and densitometric study of reduction of residual ridges. *J Prosthet Dent*. 1971 Sep;26(3):280-95. doi: 10.1016/0022-3913(71)90070-9.
23. Tallgren A. The continuing reduction of the residual alveolar ridges in complete denture wearers: a mixed-longitudinal study covering 25 years. *J Prosthet Dent*. 1972 Feb;27(2):120-32. doi: 10.1016/0022-3913(72)90188-6.

24. Lang BR, Kelsey CC. International prosthodontic workshop on complete denture occlusion. Ann Arbor, MI. The University of Michigan School of Dentistry. 1973:1-50.
25. Saunders TR, Gillis RE Jr, Desjardins RP. The maxillary complete denture opposing the mandibular bilateral distal-extension partial denture: treatment considerations. *J Prosthet Dent.* 1979 Feb;41(2):124-8. doi: 10.1016/0022-3913(79)90292-0.
26. Tallgren A, Lang BR, Walker GF, Ash MM Jr. Roentgen cephalometric analysis of ridge resorption and changes in jaw and occlusal relationships in immediate complete denture wearers. *J Oral Rehabil.* 1980 Jan;7(1):77-94. doi: 10.1111/j.1365-2842.1980.tb01466.x.
27. Kalk W, de Baat C. Some factors connected with alveolar bone resorption. *J Dent.* 1989 Aug;17(4):162-5. doi: 10.1016/0300-5712(89)90068-7.
28. Wyatt CC. The effect of prosthodontic treatment on alveolar bone loss: a review of the literature. *J Prosthet Dent.* 1998 Sep;80(3):362-6. doi: 10.1016/s0022-3913(98)70138-6.
29. Tallgren A. Alveolar bone loss in denture wearers as related to facial morphology. *Acta Odontol Scand.* 1970 May;28(2):251-70. doi: 10.3109/00016357009032033.
30. Bairam LR, Miller WA. Mandible bone resorption as determined from panoramic radiographs in edentulous male individuals ages 25-80 years. *Gerodontology.* 1994 Dec;11(2):80-5. doi: 10.1111/j.1741-2358.1994.tb00112.x.
31. Tallgren A. Positional changes of complete dentures. A 7-year longitudinal study. *Acta Odontol Scand.* 1969 Oct;27(5):539-61. doi: 10.3109/00016356908994049.
32. Xie Q, Närhi TO, Nevalainen JM, Wolf J, Ainamo A. Oral status and prosthetic factors related to residual ridge resorption in elderly subjects. *Acta Odontol Scand.* 1997 Oct;55(5):306-13. doi: 10.3109/00016359709114969.
33. Schlosser RO. Basic factors retarding resorptive changes of residual ridges under complete denture prosthesis. *J Am Dent Assoc.* 1950 Jan;40(1):12-9. doi: 10.14219/jada.archive.1950.0020.
34. Lammie GA. The reduction of the edentulous ridges. *J Prosthet Dent.* 1960 Jul;10(4):605-11. doi: 10.1016/0022-3913(60)90239-0. Accessed May 24, 2021.
35. Atwood DA. Some clinical factors related to rate of resorption of residual ridges. 1962. *J Prosthet Dent.* 2001 Aug;86(2):119-25. doi: 10.1067/mpr.2001.117609.
36. MacEntee MI. The impact of edentulism on function and quality of life. In: *Implant Overdentures - The Standard of Care for Edentulous Patients.* Feine JS (ed.) Chicago, IL. Quintessence Publishing Company, Inc. 2003:23-28.
37. Hobkirk JA. The management of gross alveolar resorption. *J Prosthet Dent.* 1973 Apr;29(4):397-404. doi: 10.1016/s0022-3913(73)80016-2.
38. Wical KE, Swoope CC. Studies of residual ridge resorption. II. The relationship of dietary calcium and phosphorus to residual ridge resorption. *J Prosthet Dent.* 1974 Jul;32(1):13-22. doi: 10.1016/0022-3913(74)90094-8.
39. Kribbs PJ, Smith DE, Chesnut CH 3rd. Oral findings in osteoporosis. Part II: Relationship between residual ridge and alveolar bone resorption and generalized skeletal osteopenia. *J Prosthet Dent.* 1983 Nov;50(5):719-24. doi: 10.1016/0022-3913(83)90215-9.
40. Razmazzoto LJ, Curro FA, Gates PE, Paterson PE. Calcium Nutrition and the Aging Process: A Review. *Gerodontology.* 1986 DEc;5:159-168. doi: 10.1111/j.1741-2358.1986.tb00063.x. Accessed May 24, 2021.
41. Kribbs PJ, Chesnut CH 3rd, Ott SM, Kilcoyne RF. Relationships between mandibular and skeletal bone in an osteoporotic population. *J Prosthet Dent.* 1989 Dec;62(6):703-7. doi: 10.1016/0022-3913(89)90596-9.
42. Jacobson TE, Krol AJ. A contemporary review of the factors involved in complete denture retention, stability, and support. Part I: retention. *J Prosthet Dent.* 1983 Jan;49(1):5-15. doi: 10.1016/0022-3913(83)90228-7.
43. Jacobson TE, Krol AJ. A contemporary review of the factors involved in complete dentures. Part II: stability. *J Prosthet Dent.* 1983 Feb;49(2):165-72. doi: 10.1016/0022-3913(83)90494-8.
44. Jacobson TE, Krol AJ. A contemporary review of the factors involved in complete dentures. Part III: support. *J Prosthet Dent.* 1983 Mar;49(3):306-13. doi: 10.1016/0022-3913(83)90267-6.

45. Hardy IR, Kapur KK. Posterior border seal—Its rationale and importance. *J Prosthet Dent.* 1958 May;8(3):386-97. doi: 10.1016/0022-3913(58)90064-7. Accessed May 24, 2021.
46. Murray MD, Darvell BW. Reappraisal of the physics of denture retention. *Int J Prosthodont.* 1989 May-Jun;2(3):234-42.
47. Murray MD, Darvell BW. The evolution of the complete denture base. Theories of complete denture retention—a review. Part 4. *Aust Dent J.* 1993 Dec;38(6):450-5. doi: 10.1111/j.1834-7819.1993.tb04760.x
48. Murray MD, Darvell BW. The evolution of the complete denture base. Theories of complete denture retention—a review. Part 2. *Aust Dent J.* 1993 Aug;38(4):299-305. doi: 10.1111/j.1834-7819.1993.tb05502.x.
49. Murray MD, Darvell BW. The evolution of the complete denture base. Theories of complete denture retention—a review. Part 3. *Aust Dent J.* 1993 Oct;38(5):389-93. doi: 10.1111/j.1834-7819.1993.tb05521.x.
50. Murray MD, Darvell BW. The evolution of the complete denture base. Theories of complete denture retention—a review. Part 1. *Aust Dent J.* 1993 Jun;38(3):216-9. doi: 10.1111/j.1834-7819.1993.tb03067.x.
51. Shay K. The retention of complete dentures. In: Boucher's Prosthodontic Treatment for Edentulous Patients, 11th Edition. Zarb EA. St. Louis, MO. Mosby. 1997:400-411.
52. Chen MS, Daly TE. Xerostomia and complete denture retention. *Tex Dent J.* 1979 Sep;97(9):6-9.
53. Edgerton M, Tabak LA, Levine MJ. Saliva: a significant factor in removable prosthodontic treatment. *J Prosthet Dent.* 1987 Jan;57(1):57-66. doi: 10.1016/0022-3913(87)90117-x.
54. Turner M, Jahangiri L, Ship JA. Hyposalivation, xerostomia and the complete denture: a systematic review. *J Am Dent Assoc.* 2008 Feb;139(2):146-50. doi: 10.14219/jada.archive.2008.0129.
55. Martone AL. Clinical applications of concepts of functional anatomy and speech science to complete denture prosthodontics: Part VI. The diagnostic phase. *J Prosthet Dent.* 1962 Sep;12(5):817-34. doi: 10.1016/0022-3913(62)90035-5. Accessed May 24, 2021.
56. Boucher CO. Complete denture impressions based upon the anatomy of the mouth. *JADA.* 1944 Sep;31(17):1174-81. doi: 10.14219/jada.archive.1944.0262. Accessed May 24, 2021.
57. Tyson KW. Physical factors in retention of complete upper dentures. *J Prosthet Dent.* 1967 Aug;18(2):90-7. doi.org.10.1016/S0022-3913(67)80049-0. Accessed May 24, 2021.
58. Gysi A. Occlusion and the cross-bite set-up. In: *Prosthetic Dentistry - An Encyclopedia of Full and Partial Denture Prosthesis.* IG Nichols (ed.). St. Louis, MO. The C.V. Mosby Company. 1930:337-42.
59. Pound E. Lost - Fine arts in the fallacy of the ridges. *J Prosthet Dent.* 1954 Jan;4(1):6-16. doi: 10.1016/0022-3913(54)90060-8. Accessed May 24, 2021.
60. Boucher CO. *Swenson's Complete Dentures, 5th Edition.* St. Louis, MO. The C.V. Mosby Company. 1964:215-86.
61. Sicher H. *Oral Anatomy, 4th Ed.* St. Louis, MO. The C.V. Mosby Company. 1965:201.
62. Davis DM. Developing an analogue/substitute for mandibular denture-bearing area. In: *Boucher's Prosthodontic Treatment for Edentulous Patients, 11th Edition.* Zarb GA, Bolender CL, Carlsson GE (ed.). St. Louis, MO. Mosby, Inc. 1997. 162-81.
63. LaVere AM, Freda AL. Artificial tooth arrangement for prognathic patients. *J Prosthet Dent.* 1972 Dec;28(6):650-4. doi: 10.1016/0022-3913(72)90117-5.
64. Martone AL, Black JW. The phenomenon of function in complete denture prosthodontics. An approach to prosthodontics through speech science. Part V. Speech science research or prosthodontic significance. *J Prosthet Dent.* 1962 Jul;12(4):629-36. doi: 10.1016/0022-3913(62)90091-4. Accessed May 24, 2021.
65. Wright CR, Swartz WH, Godwin WC. Mandibular Denture Stability - A New Concept. *Ann Arbor, MI. Overbeck.* 1961:29-31.
66. Schole ML. Management of the gagging patient. *J Prosthet Dent.* 1959 Jul;9(4):578-83. doi.org/10.1016/0022-3913(59)90126-X. Accessed May 24, 2021.

67. Morstad AT, Peterson AD. Postinsertion denture problems. *J Prosthet Dent.* 1968 Feb;19(2):126-32. doi: 10.1016/0022-3913(68)90153-4. Accessed May 24, 2021.
68. Means CR, Flenniken IE. Gagging—a problem in prosthetic dentistry. *J Prosthet Dent.* 1970 Jun;23(6):614-20. doi: 10.1016/0022-3913(70)90224-6.
69. Kuebker WA. Denture problems: causes, diagnostic procedures, and clinical treatment. III/IV. Gagging problems and speech problems. *Quintessence Int Dent Dig.* 1984 Dec;15(12):1231-8.
70. Cagna DR, Massad JJ, Schiesser FJ. The neutral zone revisited: from historical concepts to modern application. *J Prosthet Dent.* 2009 Jun;101(6):405-12. doi: 10.1016/S0022-3913(09)60087-1.
71. Schiesser FJ. The neutral zone and polished surfaces in complete dentures. *J Prosthet Dent.* 1964 Sep;14(5):854-65. doi: 10.1016/0022-3913(64)90014-9. Accessed May 24, 2021.
72. Beresin VE, Schiesser FJ. The neutral zone in complete dentures. *J Prosthet Dent.* 1976 Oct;36(4):356-67. doi: 10.1016/0022-3913(76)90155-4.
73. Brewer AA. Prosthodontic research in progress at the School of Aerospace Medicine. *J Prosthet Dent.* 1963 Jan;13(1):49-69. doi: 10.1016/0022-3913(63)90197-5. Accessed May 24, 2021.
74. Lang BR. Complete denture occlusion. *Dent Clin North Am.* 1996 Jan;40(1):85-101.
75. Berg E. The influence of some anamnestic, demographic, and clinical variables on patient acceptance of new complete dentures. *Acta Odontol Scand.* 1984 Apr;42(2):119-27. doi: 10.3109/00016358409035249.
76. Pietrokovski J, Harfin J, Mostavoy R, Levy F. Oral findings in elderly nursing home residents in selected countries: quality of and satisfaction with complete dentures. *J Prosthet Dent.* 1995 Feb;73(2):132-5. doi: 10.1016/s0022-3913(05)80151-9.
77. Geertman ME, Boerrigter EM, Van't Hof MA, Van Waas MA, van Oort RP, Boering G, Kalk W. Two-center clinical trial of implant-retained mandibular overdentures versus complete dentures—chewing ability. *Community Dent Oral Epidemiol.* 1996 Feb;24(1):79-84. doi: 10.1111/j.1600-0528.1996.tb00818.x.
78. Geertman ME, van Waas MA, van 't Hof MA, Kalk W. Denture satisfaction in a comparative study of implant-retained mandibular overdentures: a randomized clinical trial. *Int J Oral Maxillofac Implants.* 1996 Mar-Apr;11(2):194-200.
79. Kapur KK, Garrett NR, Hamada MO, et al. Randomized clinical trial comparing the efficacy of mandibular implant-supported overdentures and conventional dentures in diabetic patients. Part III: comparisons of patient satisfaction. *J Prosthet Dent.* 1999 Oct;82(4):416-27. doi: 10.1016/s0022-3913(99)70028-4.
80. Raghoobar GM, Meijer HJ, Stegenga B, van't Hof MA, van Oort RP, Vissink A. Effectiveness of three treatment modalities for the edentulous mandible. A five-year randomized clinical trial. *Clin Oral Implants Res.* 2000 Jun;11(3):195-201. doi: 10.1034/j.1600-0501.2000.011003195.x.
81. Awad MA, Lund JP, Dufresne E, Feine JS. Comparing the efficacy of mandibular implant-retained overdentures and conventional dentures among middle-aged edentulous patients: satisfaction and functional assessment. *Int J Prosthodont.* 2003 Mar-Apr;16(2):117-22.
82. Awad MA, Lund JP, Shapiro SH, Locker D, Klemetti E, Chehade A, Savard A, Feine JS. Oral health status and treatment satisfaction with mandibular implant overdentures and conventional dentures: a randomized clinical trial in a senior population. *Int J Prosthodont.* 2003 Jul-Aug;16(4):390-6.
83. Feine JS, Carlsson GE. *Implant Overdentures - The Standard of Care for Edentulous Patients.* Chicago, IL. Quintessence Publishing Company, Inc. 2003:155.
84. Coates AJ. Usage of denture adhesives. *J Dent.* 2000 Feb;28(2):137-40. doi: 10.1016/s0300-5712(99)00046-9.
85. Tarbet WJ, Boone M, Schmidt NF. Effect of a denture adhesive on complete denture dislodgement during mastication. *J Prosthet Dent.* 1980 Oct;44(4):374-8. doi: 10.1016/0022-3913(80)90092-x.
86. Karlsson S, Swartz B. Denture adhesives - their effect on the mobility of full upper dentures during chewing. A cineradiographic study. *Swed Dent J.* 1981;5(5-6):207-11.


87. Chew CL, Boone ME, Swartz ML, Phillips RW. Denture adhesives: their effects on denture retention and stability. *J Dent.* 1985 Jun;13(2):152-9. doi: 10.1016/0300-5712(85)90089-2.
88. Karlsson S, Swartz B. Effect of a denture adhesive on mandibular denture dislodgment. *Quintessence Int.* 1990 Aug;21(8):625-7.
89. Grasso JE, Rendell J, Gay T. Effect of denture adhesive on the retention and stability of maxillary dentures. *J Prosthet Dent.* 1994 Oct;72(4):399-405. doi: 10.1016/0022-3913(94)90560-6.
90. Hasegawa S, Sekita T, Hayakawa I. Effect of denture adhesive on stability of complete dentures and the masticatory function. *J Med Dent Sci.* 2003 Dec;50(4):239-47.
91. Psillakis JJ, Wright RF, Grbic JT, Lamster IB. In practice evaluation of a denture adhesive using a gnathometer. *J Prosthodont.* 2004 Dec;13(4):244-50. doi: 10.1111/j.1532-849X.2004.04040.x.
92. Ozcan M, Kulak Y, de Baat C, Arikan A, Ucankale M. The effect of a new denture adhesive on bite force until denture dislodgement. *J Prosthodont.* 2005 Jun;14(2):122-6. doi: 10.1111/j.1532-849X.2005.00020.x.
93. Kulak Y, Ozcan M, Arikan A. Subjective assessment by patients of the efficiency of two denture adhesive pastes. *J Prosthodont.* 2005 Dec;14(4):248-52. doi: 10.1111/j.1532-849X.2005.00049.x.
94. Pradés G, Sanz I, Evans O, Martinez F, Sanz M. Clinical study comparing the efficacy of two denture adhesives in complete denture patients. *Int J Prosthodont.* 2009 Jul-Aug;22(4):361-7.
95. Shay K. Denture adhesives. Choosing the right powders and pastes. *J Am Dent Assoc.* 1991 Jan;122(1):70-6.
96. Slaughter A, Katz RV, Grasso JE. Professional attitudes toward denture adhesives: A Delphi technique survey of academic prosthodontists. *J Prosthet Dent.* 1999 Jul;82(1):80-9. doi: 10.1016/s0022-3913(99)70131-9.
97. Nations SP, Boyer PJ, Love LA, Burritt MF, Butz JA, Wolfe GI, Hynan LS, Reisch J, Trivedi JR. Denture cream: an unusual source of excess zinc, leading to hypocupremia and neurologic disease. *Neurology.* 2008 Aug 26;71(9):639-43. doi: 10.1212/01.wnl.0000312375.79881.94. Epub 2008 Jun 4.
98. Spinazzi M, Armani M. Denture cream: an unusual source of excess zinc, leading to hypocupremia and neurologic disease. *Neurology.* 2009 Jul 7;73(1):76. doi: 10.1212/01.wnl.0000349696.89948.b7.
99. Tarbet WJ, Grossman E. Observations of denture-supporting tissue during six months of denture adhesive wearing. *J Am Dent Assoc.* 1980 Nov;101(5):789-91. doi: 10.14219/jada.archive.1980.0434.
100. Tarbet WJ, Silverman G, Schmidt NF. Maximum incisal biting force in denture wearers as influenced by adequacy of denture-bearing tissues and the use of an adhesive. *J Dent Res.* 1981 Feb;60(2):115-9. doi: 10.1177/00220345810600020301.
101. Polyzois GL. An update on denture fixatives. *Dent Update.* 1983 Oct;10(9):579-80, 582-3.
102. Adisman IK. The use of denture adhesives as an aid to denture treatment. *J Prosthet Dent.* 1989 Dec;62(6):711-5. doi: 10.1016/0022-3913(89)90598-2.
103. DeVengencie J, Ng MC, Ford P, Iacopino AM. In vitro evaluation of denture adhesives: possible efficacy of complex carbohydrates. *Int J Prosthodont.* 1997 Jan-Feb;10(1):61-72.
104. Sipahi C, Beyzadeoglu M, Demirtas S, Ozen J. Effect of different mucosal and acrylic resin surface treatments in a denture retention model for patients with radiotherapy-induced xerostomia. *Int J Prosthodont.* 2007 Jul-Aug;20(4):405-8.
105. Grasso JE. Denture adhesives: changing attitudes. *J Am Dent Assoc.* 1996 Jan;127(1):90-6. doi: 10.14219/jada.archive.1996.0036.

Additional Resources

- No Additional Resources Available

About the Authors

Joseph J. Massad, DDS



Private practice, Tulsa, OK

Associate Professor, Department of Prosthodontics, University of Tennessee Health Center, Memphis, Tennessee, School of Dentistry, Memphis TN

Adjunct Associate Professor, Department of Prosthodontics and Operative Dentistry, Tufts University School of Dental Medicine, Boston MA

Adjunct Associate Professor, Department of Comprehensive Dentistry, University of Texas Health Science Center, School of Dentistry, San Antonio TX

Adjunct Associate Professor, Department of Restorative Dentistry, Loma Linda University School of Dentistry, Loma Linda CA

Clinical Assistant Professor, University of Oklahoma College of Dentistry, Oklahoma City OK

Website: joemassad.com

Email: joe@joemassad.com

David R. Cagna, DMD, MS



University of Tennessee Health Science Center, College of Dentistry, Memphis TN

Professor, Department of Prosthodontics

Associate Dean, Postgraduate Affairs

Director, Advanced Prosthodontics Program

Diplomate & Director, American Board of Prosthodontics

Fellow, American College of Prosthodontists

Email: dcagna@uthsc.edu