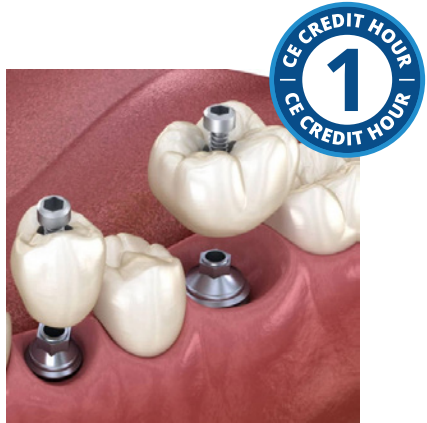

Biologically Contoured Esthetic Implant Restorations



Course Author(s): Swati Ahuja, BDS, MDS

CE Credits: 1 hours

Intended Audience: Dentists, Dental Hygienists, Dental Assistants, Dental Students, Dental Hygiene Students, Dental Assisting Students, Office Managers, Dental Educators

Date Course Online: 07/15/2024

Last Revision Date: NA

Course Expiration Date: 07/14/2027

Cost: Free

Method: Self-instructional

AGD Subject Code(s): 690

Online Course: www.dentalcare.com/en-us/ce-courses/ce684

Disclaimers:

- P&G is providing these resource materials to dental professionals. We do not own this content nor are we responsible for any material herein.
- Participants must always be aware of the hazards of using limited knowledge in integrating new techniques or procedures into their practice. Only sound evidence-based dentistry should be used in patient therapy.

Conflict of Interest Disclosure Statement

- Dr. Ahuja reports no conflicts of interest associated with this course. She has no relevant financial relationships to disclose.

Short Description

Dental professionals are often times fixated on the idea that toothpaste abrasiveness is the key factor in tooth wear. This course will review the history of RDA and modern erosive tooth wear; which will demonstrate that acid-mediated tooth wear, so-called erosive tooth wear, is the dominant process for tooth loss. The course will also focus on prevention strategies to reduce the risk of erosive tooth wear.

Course Contents

- Introduction
- Dental Trauma Prevalence
- Sports Dentistry
- Oral and Dental Injuries
- Prevention Levels
- Mouthguards
- Face Shields
- ToothSOS app
- Save Your Tooth Poster
- Save a Tooth Kit
- IADT Guidelines for Treatment of Traumatic Dental Injuries
- Dental Trauma Guide (DTG)
- Conclusion
- References / Additional Resources

Overview

One of the most significant challenges in implant therapy involves optimally managing the transition of the restoration from the implant body through the soft tissues. This course will detail the importance of various factors affecting the diagnosis and treatment planning of biologically contoured implant restorations including the assessment of hard and soft tissues, peri-implant mucosal phenotype, restorative space, crown morphology, three dimensional (3D) and restoratively driven implant planning, developing consensus for ideal surgical implant position and placement of well-contoured provisional restorations or custom healing abutments. This course will also describe various techniques for fabricating customized healing abutments and the techniques for capturing tissue architecture in the definitive restoration.

Learning Objectives

Upon completion of this course, the dental professional should be able to:

- Define emergence profile and list considerations for creating an optimum emergence profile.
- Identify the factors affecting the diagnosis and treatment planning of biologically contoured implant restorations.
- List the importance of the fabrication of provisional restoration.
- Describe the importance and the procedures for fabricating a customized healing abutment.

- Use the cervical contouring concept, ready-made molds, or CAD-CAM technology for optimally conditioning the soft tissues.
- Describe the techniques for capturing tissue architecture in the definitive restoration.
- Develop the clinical workflow for fabricating implant restorations (emphasizing the creation of biologically contoured restorations).

Introduction

An implant-supported restoration is considered successful when it provides comparable esthetics and function as the natural tooth it is replacing.^{1,2} Esthetics of an implant restoration is not only associated with the visible portion of the prosthesis but also the surrounding peri-implant soft tissue architecture.³⁻⁶ By comparison, implants have a narrower diameter platform and circular diameter as opposed to the wider and broader cervical anatomy observed in most natural teeth to be replaced.^{1,4} Proper transition from the small, rounded implant platform to the ideal restorative cervical contour is critical for developing an optimal soft tissue architecture.^{1,4,7} The desired transition involving the peri-implant mucosa is predicated on the development of an appropriate restorative emergence profile.^{1,4,7}

Emergence Profile

Emergence profile is defined as the contour of a restoration as it relates to its emergence from the circumscribed soft tissues.^{8,9} It specifically represents the restoration region located between the implant platform and the soft tissue cervical margin (Figure 1).^{4,7} The emergence profile allows a transition from the narrow diameter cylindrical implant platform to the visibly wider cervical portion of the restoration.¹ Ideally, the transition from the implant platform to the cervical margin of the restoration should be smooth and gradual. However, correct three-dimensional surgical implant positioning and sufficient tissue volume are required to achieve optimal emergence profile.^{4,6,7} The emergence profile has implications in esthetics as well as in maintaining the peri-implant soft tissue health.^{7,10} A restoration with an optimal, biologically contoured emergence profile provides support to the perimucosal tissues around the implant restoration, hence, it

is rarely associated with the formation of proximal and/or buccal/lingual food traps.¹¹ Developing a restorative contour of optimal emergence profile, is one of the most significant challenges in implant therapy.¹²

Based on the response of the peri-implant mucosal tissues to abutment/crown contour modifications the emergence profile is further divided into two regions: the superficial/critical contour and the deep/subcritical contour (Figure 2).⁷ The critical contour is associated with the cervical margin of the restoration.⁷ It dictates the mucosal margin level, architecture, and shape of the tooth in the cervical region.⁷ The subcritical contour is located immediately coronal to the implant platform and extends coronally to the critical contour.⁷ It helps volumetrically support the drape of the peri-implant mucosa and harbors the supracrestal tissue attachments.⁷ The deep/subcritical contour should help facilitate a gradual and harmonious transition from the implant platform to the critical contour.⁷ However, this can only be appropriately facilitated when the implant is positioned at an optimal apical-coronal depth at the time of surgical placement.⁷ The critical and subcritical contours can help alter the soft tissue architecture.^{1,7} These contours can be customized and thoughtfully modified as needed during the healing/

transitional phase to maintain/recreate the soft tissue form.^{1,3,7} The critical and subcritical contours may be concave, flat, or convex.⁴ The facial critical contour affects the zenith, the position of the labial mucosal margin, and the apparent length of the clinical crown whereas the *interproximal* critical contour affects the apparent shape of the clinical crown (triangular or square).⁷ A convex facial critical contour is planned (to support the marginal tissues) when the implant is positioned lingually or when there is a need to transpose the peri-implant mucosal margin apically.⁴ Conversely, a flat or concave facial critical contour is designed for implants that are positioned labially or when there is a need to transpose the peri-implant mucosal margin coronally.⁴

The subcritical *facial* contour is usually concave or flat in shape and helps support the tissues in their existing position.^{4,6} However, a convex subcritical contour may be designed on the facial aspect, when the soft tissue form appears deficient facially.^{4,6} Subcritical contour in the interproximal region is usually concave or straight in esthetic areas and straight in posterior sites; it is planned to be convex only when tissue support is necessary or when there is a slight deficiency.^{4,6} A concave subcritical contour in the midfacial and interproximal areas helps facilitate soft-tissue ingrowth.⁶

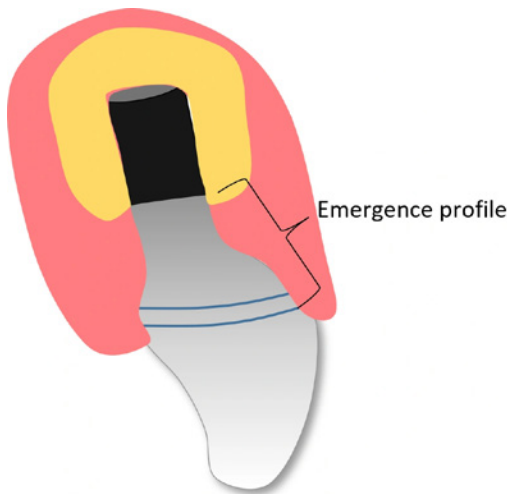


Figure 1. Emergence Profile

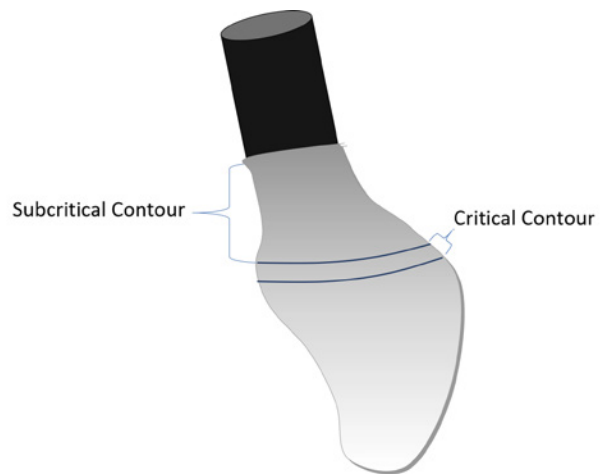


Figure 2. Critical and Subcritical Contours of a Restoration

Diagnosing and Treatment Planning Biologically Contoured Implant Restorations

A restoration that provides optimal support to the peri-implant mucosal tissues and prevents them from injury is termed a biologically contoured restoration. The various factors that should be taken into consideration while treatment planning biologically contoured implant restorations include the following:

1. Assessment of the hard and soft tissues
2. Determination of peri-implant mucosal phenotype
3. Assessment of the form of adjacent teeth
4. Assessment of the restorative space
5. 3D and restoratively driven implant planning
6. Establishing the implant surgical positioning that is prosthetically and biologically optimal. Interdisciplinary communication between restorative, surgical, and laboratory teams is critical to a well-planned implant position especially when implant placement and restoration are not going to be performed by the same practitioner.
7. Placement of a well-contoured provisional restoration or custom healing abutment

Assessment of the Hard and Soft Tissues

Prior to the placement of an implant, it is important to evaluate the existing hard and soft tissues associated with the proposed implant site (Figure 3).¹³ It is reported that at least 2mm of keratinized tissue should be present to maintain the long-term health of the implant.¹⁴ Likenvicius et al., have reported that the peri-implant crestal mucosal thickness of 2.0 mm or less may predispose to crestal bone loss regardless of supracrestal position of the implant-abutment interface or platform switching.^{15,16} In addition to the thickness of peri-implant mucosal tissues, history of periodontal disease which affects the presence/absence of a buccal plate and the interproximal bone should also be reviewed.¹⁴

When the bone volume is adequate but there is a buccal plate deficiency, implant placement may be more palatal compared to the optimal position thereby resulting in a ridge lap restoration which may be difficult to clean and maintain.¹⁷ Also, interproximal bone loss is associated with the loss of papilla thereby resulting in compromised esthetics and cleansibility of the restoration.¹³ When the patient has hard and/or soft tissue deficiencies they need to be informed regarding the challenges and augmentation procedures that are necessitated to help improve the overall outcome.¹³

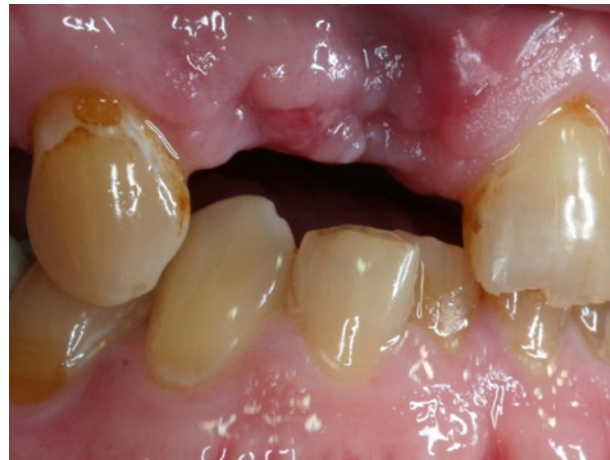

Figure 3. Deficient Hard and Soft Tissues

Determination of Peri-implant Mucosal Phenotype

The term periodontal biotype was introduced by Seibert and Lindhe.¹⁸ As per their classification, the gingiva may be categorized into “thick-flat” or “thin-scalloped” biotypes and is currently referred to as “periodontal/peri-implant phenotype”.¹⁸ When the peri-implant mucosal thickness is 2mm or more, it is classified as a thick peri-implant mucosal phenotype whereas a mucosal thickness of 1.5mm or less is characterized as a thin phenotype.¹⁸ The thick peri-implant mucosal phenotype is characterized by the presence of a wide band of keratinized tissue, flat bony architecture, thick marginal bone, broad contact areas, and square-shaped anatomic crowns.^{13,18} The thin peri-implant mucosal phenotype is characterized by a narrow zone

of keratinized tissue, pronounced scalloping of the tissue, thin marginal bone, narrow proximal contact areas, triangular crown morphology, and reduced quantity and quality of keratinized tissues.¹⁸ A site with a thin peri-implant mucosal phenotype has an increased risk of marginal and papillary recession and bony dehiscence and fenestration. Therefore, such tissues must be handled carefully during surgery, making of impressions, and restorative procedures.¹³ Surgical implant placement in thin phenotype patients should be performed more palatally, and slightly deeper to mask the visibility of titanium and facilitate the development of a proper emergence profile.¹³ Further, phenotype modification procedures must be considered to enhance implant soft tissue stability and esthetics.¹⁹

Assessment of the Form of Adjacent Teeth

It is important to match the shape of the implant restoration with the shape of the adjacent teeth, as it affects its appearance and final esthetic outcome.¹³ The dental crown morphology may be classified as square or triangular (Figures 4 & 5).²⁰ In teeth with a square-shaped crown morphology, the “black triangle” open embrasure created due to the loss of papilla is relatively inconspicuous.^{20,21} This is associated with broad interproximal contact areas that are located close to the cervical aspect of the tooth crown.²¹ However,

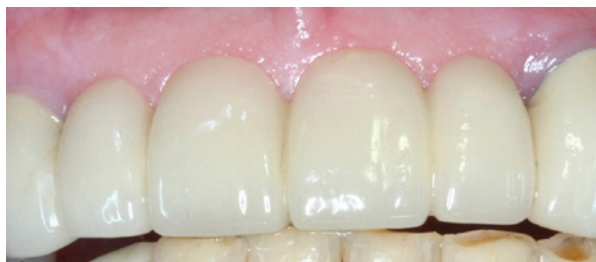

Figure 4. Square-shaped Crown Morphology

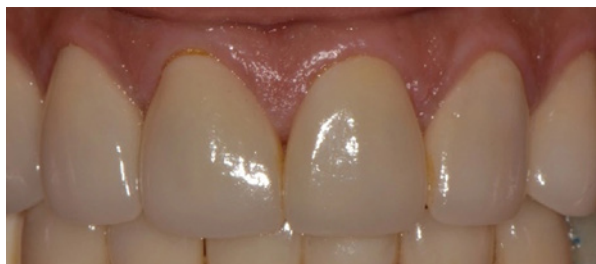

Figure 5. Triangular Crown Morphology

in teeth with a triangular-shaped crown morphology, the black triangle embrasure space created due to the loss of papilla is distinctly visible.²¹ This is associated with narrow interproximal contact areas that are located close to the incisal aspect of the tooth crown.²¹ Teeth with a triangular crown morphology are also associated with a thin peri-implant mucosal phenotype.²¹

Assessment of the Restorative Space

Restorative space is the 3-dimensional oral space available to receive the proposed prosthodontic restoration.²² It may be measured conventionally using mounted casts on an articulator (Figure 6) or digitally during implant planning (Figure 7).²² Misch suggests that at least 7-8mm of vertical restorative space (dimension between the implant platform and the occlusal plane) should be available for restoring a single implant crown esthetically and functionally.²³ Inadequate restorative space leads to the development of restorations with suboptimal contours (ball on a stick appearance).²² However, excessive vertical restorative space results in an increased vertical cantilever and ultimately a magnified, off-axis load on the implant.²⁴ In the mesiodistal dimension, at least 7mm of restorative space is necessary for optimal restoration of a single implant.²⁵ Restoring implants with excess space in the mesiodistal dimension also results in a horizontal cantilever and consequently magnified, off-axis forces that can overload the implant-restoration system.²⁶ It has also been noted that an emergence angle of > 30 degrees is associated with an increased risk for peri-implantitis and limited restorative space may also result in increasingly high emergence angle.²⁷

3-D (3-dimensional) and Restoratively Driven Implant Planning

A prosthetic wax-up is critical in the implant treatment planning process to help assess tissue deficiencies and the final restorative position.¹³ Cone-beam computerized tomography (CBCT) scans in conjunction with intraoral scans are routinely used for implant planning in partially edentulous patients.^{28,29} The data obtained from the CBCT scans,

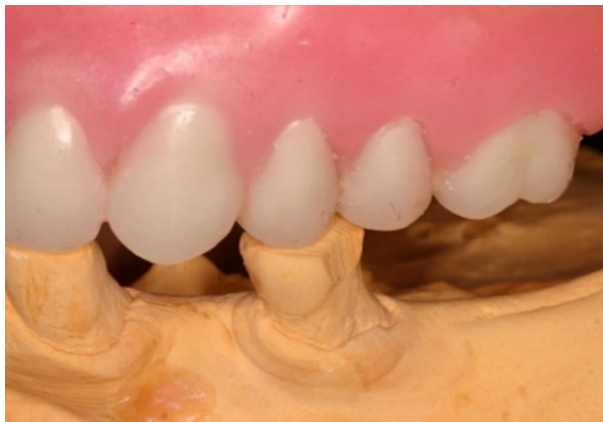

Figure 6. Restorative space assessed on an articulator using a clinically approved wax-up.

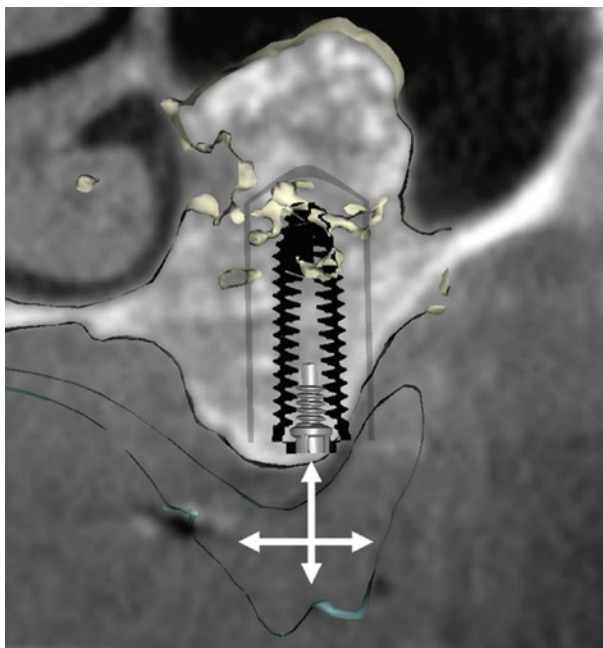


Figure 7. Restorative space measured digitally during implant planning.

intraoral scans, and the prosthetic wax-up is combined and used for 3D implant planning in dedicated software.²⁹ 3D implant planning helps assess the 3 dimensional bone volume of the edentulous site and the health of adjacent teeth.³⁰ It also aids in determining the optimal restorative implant position with respect to the bony architecture.²⁹ It is also critical to decide the type and design of the restoration (screw or cement retention) at this point in the planning process to ensure a restoration with hygienically cleansable contours.

Establishing Proper Communication with the Implant Surgeon and Determining Ideal Implant Position

During implant planning, communication among all members of the implant treatment team is required to ensure ideal implant surgical position. Once the implant is placed, its position cannot be altered! The restorative dentist and the implant surgeon can collaboratively decide on the ideal implant angulation and bodily position based on the prosthetic position and the type of the implant restoration desired.³¹ In addition, the surgeon should be specifically informed regarding the desired cervico-enamel junction (CEJ) level and the timing of provisional restoration placement. A 3D surgical guide that is based upon careful implant planning and is stable intersurgically should be provided to the surgeon for the implant placement procedure.³¹

Ideal implant body position

The correct three-dimensional implant position (interproximal, bucco-lingual, inciso-apical, and axial inclination) is a fundamental factor in providing a natural-looking final restoration.^{4,7} Mesio-distally, the implant should be centered in the missing tooth space with at least 1.5mm space between the implant platform and adjacent tooth CEJ to provide optimal tissue contours and appropriately distribute the forces.³² It has been reported that maintaining the minimum 1.5mm distance ensures that the potential vertical defect associated with the implant (smooth collared implants) will not affect the bone of the adjacent natural tooth and thus help in maintaining the interdental papilla.³³ Faciopalatally, the implant should be positioned 2mm from the buccal plate at the crest and 1.5mm or more from the palatal bone.^{34,35} Implants planned in the anterior region of the jaw should have a cingulum/ incisal sagittal angulation. Posterior implants should be positioned such that their long axes are perpendicular to the occlusal plane.^{36,37} Incisoapically, implants planned in the anterior and the posterior regions of the jaw should be placed 3-4mm and 2-3mm respectively below the ideal prospective zenith of the planned restoration.⁴ Implant placement that is too apical may predispose the implant to peri-implantitis and adversely affect the bone

levels around the implant. Shallow implant placement (with a standard-diameter implant) leads to insufficient crown-height restorative space, and consequently the development of an abrupt flare in the emergence of the restoration (Figure 8).^{4,38} Osteoplasty may be performed in such situations to permit implant placement at the ideal restorative depth. This will allow the development of a gradual flare in the emergence of the restoration.

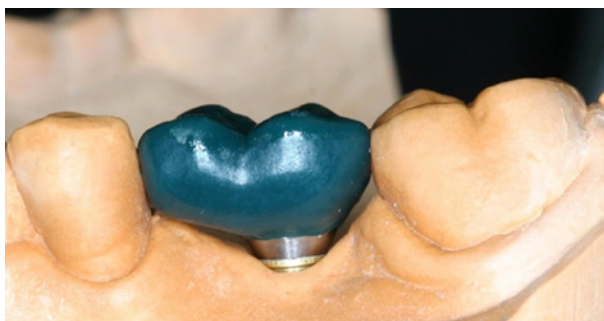

Figure 8. Suboptimal emergence profile associated with shallow and off-centered implant placement and/or improper implant diameter.

Placement of a Well-contoured Provisional Restoration/Custom Healing Abutment

Traditionally, stock healing abutments are attached to the implant at the time of implant placement or second-stage surgery to promote healing of the peri-implant soft tissues.³⁹ However, their rounded configuration creates a circular soft-tissue contour that typically does not replicate the original soft tissue architecture of the tooth being replaced. This consequently results in the fabrication of an unesthetic final restoration with contours that are difficult for the patient to maintain hygienically.^{39,40}

Provisional restorations are widely used in the anterior esthetic zone (after implant placement or the second stage surgery) for immediate restoration of esthetics and function.⁴¹ In the anterior regions of the mouth, the extracted tooth/crown may be modified and used as a provisional restoration to maintain the soft tissue architecture.⁴²

Immediately placed implants in conjunction with immediate provisional restorations help maintain and preserve the soft tissue height and gingival profile established by natural teeth.^{36,43,44} However, when implant placement is delayed, ridge resorption leads to the loss of osseous structures, overlying mucosal tissues, and contour

of the edentulous area.⁴⁵ In such situations, a provisional restoration may be utilized to condition the mucosal tissues around the implant so that an ideal emergence profile can be achieved in the final restoration.⁴⁶ Conditioning, or shaping, of the soft tissues is a gradual and time-consuming process necessitating multiple appointments. At these visits the transmucosal contour of the provisional restoration is modified using flowable composite resin or acrylic resin to reshape the peri-implant tissues and sculpt the desired morphology (Figures 9, 10 & 11).⁴⁶⁻⁴⁸

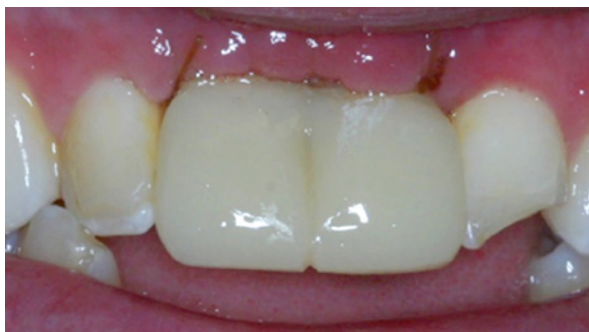

Figure 9. Provisional restoration placed for conditioning tissues.

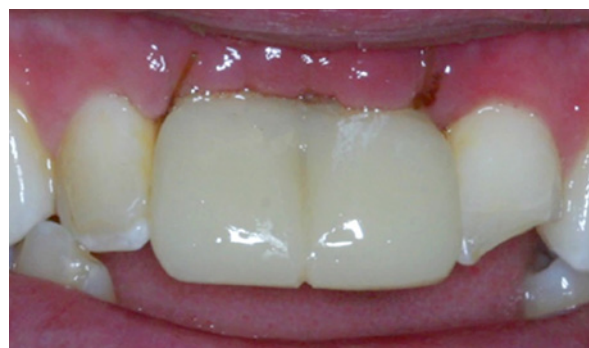

Figure 10. Improvement in soft tissue contours (occlusal view) observed after removal of the provisional restoration.

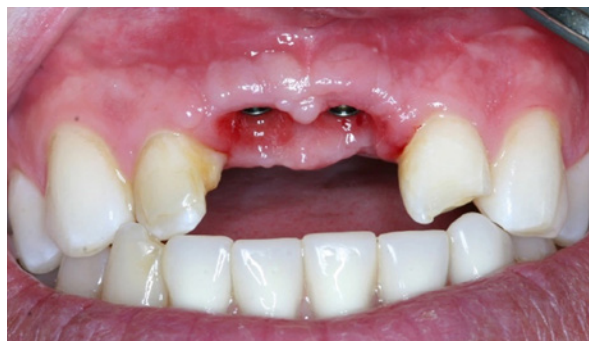

Figure 11. Improvement in soft tissue contours (Facial view) observed after removal of the provisional restoration.

The contour of the provisional restoration crown also helps determine the contact-point position with the adjacent teeth. The proper positioning of the contact area is critical to positively affect the development or maintenance of the interproximal papilla.⁴⁹ To maintain the interproximal papilla/facilitate its growth, the distance from the interproximal bone crest (of the adjacent tooth) to the apical extent of the contact point (established by the provisional restoration) should be less than or equal to 5 mm.^{49,50}

A well-contoured provisional restoration not only helps the mucosal tissue grow and develop optimally but it also serves as a template for the final restoration.⁵¹ In addition, the provisional restoration helps in assessment and understanding the patient's expectations which are also critical to the success and acceptance of the final clinical outcome.⁵¹ The disadvantages of provisional restorations include the need for extra time, materials, components, technical skill, and added financial liability.⁴¹ Further, minimal implant stability at the time of surgical implant placement is required to ensure stability for immediate provisionization.

The placement of an overcontoured provisional restoration may result in excessive pressure on the mucosa thereby leading to transient ischemia, tissue inflammation, and/or necrosis.⁴⁶ This may be clinically visible as blanching of the peri-implant tissues during seating of the provisional restoration.⁴⁸ If the blanching persists for more than 10 minutes, the provisional restoration crown should be removed and its critical and subcritical contours should be evaluated and adjusted/reduced as necessary.

Placement of a Customized Healing Abutment

Immediate provisional restorations may be contraindicated in the posterior quadrants of the oral cavity (as increased masticatory forces adversely affect osseointegration of the implant during the healing phase) and in implants with suboptimal primary stability.^{41,47,}

⁵⁰ They are also avoided in patients exhibiting a deep anterior bite, signs of bruxism, and/or malocclusion.⁵⁰ In such situations, a customized healing abutment may be utilized for soft tissue conditioning.⁵⁰ The submucosal portion of the customized healing abutment is essentially the same as a provisional restoration, however, it lacks occlusal contact (Figures 12 & 13).⁵⁰

A customized healing abutment may be placed at the time of implant placement or the second-stage surgery.⁵³ When placed at the time of implant surgery, it conditions the soft tissues,⁴⁷ contains bone graft materials,⁵³ covers the surgical site (without the need for an invasive procedure),⁵⁴ maintains the alveolar bone contour,⁵³ prevents food lodgment,⁵³ and eliminates the need for a second-stage surgery and placement of a provisional restoration.^{52,53} The custom healing abutment aims to reproduce the natural cervical contours of the extracted tooth thereby maintaining the soft tissue architecture during osseointegration and/or healing of the peri-implant mucosa (Figure 14).⁵⁵ Its contours may be gradually modified until the desired soft tissue form is achieved. However, its fabrication is time-consuming and requires multiple steps both chairside and in the dental laboratory.⁵⁶ Also, if the resin is incompletely polymerized it may cause soft tissue irritation in some patients.⁵⁶

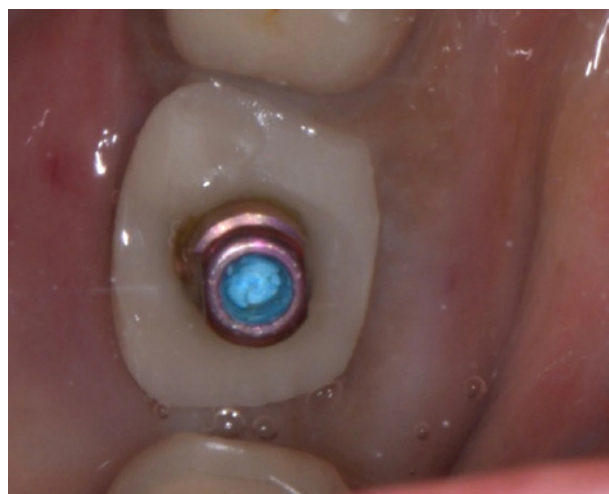

Figure 12. Custom healing abutment attached to the implant (occlusal view).

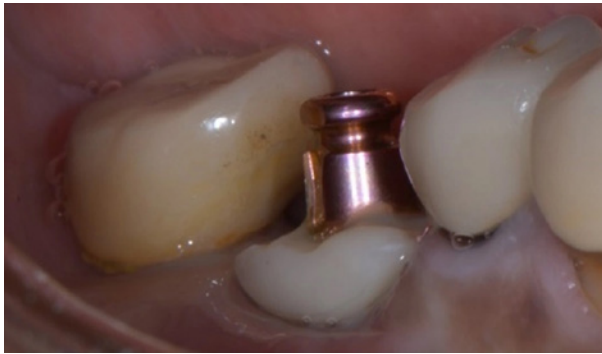

Figure 13. Custom healing abutment attached to the implant (buccal view).

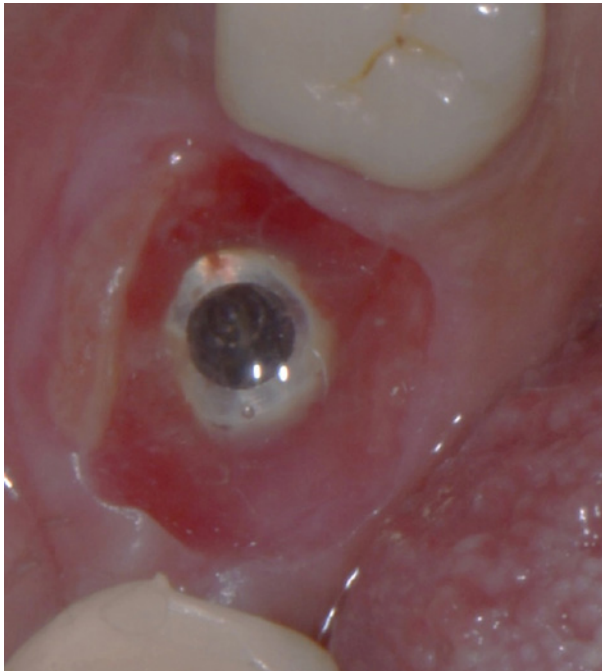


Figure 14. Maintenance of soft tissue formed by the custom healing abutment.

Techniques for Fabricating Custom Healing Abutments

The concept of customizing the standard healing abutment was first described by Pow and McMillan.⁵⁷ This was accomplished by altering the size and transmucosal shape of a stock healing abutment.⁵⁷ Customized healing abutments can be fabricated using different materials and various techniques depending on the timing of implant placement.

Immediate Implant Placement with Immediate Custom Healing Abutment Placement

Immediate implants and immediate custom healing abutments (or provisional restorations)

help maintain and preserve the soft tissue height and profile from the time of extraction.^{36,43} The custom healing abutment is attached to the implant (immediately following its placement) and left in place until osseointegration and tissue maturation are achieved. After the completion of the healing phase, the preserved soft tissue contour is replicated in the definitive restoration.⁴¹ Customized healing abutments may be fabricated using the direct or indirect method.

Direct Method

The direct method involves selecting and preparing a temporary abutment extraorally by adding a light polymerized flowable composite resin.⁵⁰ The abutment is placed intraorally, and additional composite resin is added to fill the space between the temporary abutment and the soft tissue margin (established by the natural tooth that was extracted).⁵⁰ The addition of composite resin should be performed incrementally and with caution to prevent the resin material from flowing over the implant surface.⁵⁰ The abutment is then taken out of the mouth and attached to an implant analog. Composite resin is added to the assembly to fill in voids and develop a proper emergence profile.⁵⁰ The custom-healing abutment is tried in intraorally to ensure the achievement of optimal soft tissue support.⁵⁰ Once contour is finalized, it is finished, and polished. The supramucosal extension of the temporary abutment is cut at the coronal aspect to the level of the composite resin. This technique should be implemented prior to the placement of bone graft material. Next, graft material may be placed (if necessary) and the custom healing abutment is attached to the implant. A radiograph is taken to ensure intimate seating and appropriate orientation.

Indirect Method

The indirect method involves making a conventional implant-level impression or digitally recording the implant position immediately after tooth extraction and implant placement and fabricating the custom healing abutment on the cast or with computer-aided design-computer-aided manufacturing (CAD-CAM) techniques. In addition, digital and CAD-CAM technology may be utilized to prefabricate a customized healing abutment prior to the implant placement procedure.⁴⁷

Delayed Implant Placement with Immediate/ Delayed Custom Healing Abutment Placement

When implant placement is delayed, ridge resorption leads to the loss of osseous structures, overlying mucosal tissues, and contour of the edentulous area.⁴⁵ Conditioning of the peri-implant mucosal tissues is required so that an ideal emergence profile can be achieved in the final restoration.^{43,58} This may be accomplished using a custom healing abutment. In these cases, the custom healing abutment may be fabricated:

Chairside Fabrication of Custom Healing Abutments

Various cervical formers (templates) (Figure 15) are available to help with the chair-side fabrication of custom healing abutments. Some manufacturers also sell pre-fabricated formers, similar to prefabricated polycarbonate provisional crown shells, that may be used for ease of creation of custom healing abutments. The procedural steps are shown in the following **Table 1:**




Figure 14. Maintenance of soft tissue formed by the custom healing abutment.

Conventional Laboratory Fabrication of Custom Healing Abutments

Bichacho introduced the cervical contouring concept for developing soft tissue architecture with a main focus on the marginal soft tissue level and the facial zenith position.^{59,60} The cervical contouring concept involves modifying the implant level cast (through conventional sculpting of the sub-mucosal contour) and then using it for the fabrication of custom healing abutment.⁶⁰

The procedural steps for fabricating a custom healing abutment using the cervical contouring concept are shown in the following **Table 2:**⁶⁰

CAD-CAM Fabrication of Custom Healing Abutments

Currently, CAD-CAM technology is being commonly used for the fabrication of custom healing abutments.^{61,62} The data obtained from intraoral and cone beam computerized tomography scans is imported into the CAD software and used for designing the custom healing abutment. The individual emergence profile of the custom healing may be designed by mirror flipping the emergence profile of the contralateral tooth or by using the CBCT measurements of human teeth crosssections.^{40,61,63} The custom healing abutment is then milled using CAM technology.

Clinical Workflow for Fabricating Biologically Contoured Restorations

The soft tissue form established by the provisional restoration/custom healing abutment should be recorded while transitioning from provisional restoration to definitive restoration.^{10,41,64,65} It may be recorded digitally using an intraoral scanner or conventionally by making an implant-level impression with a custom impression coping to avoid tissue collapse.^{10,64,66}

Custom Impression Coping

A custom-made impression coping should mimic the exact submucosal emergence profile of the provisional restoration or the custom healing abutment (Figure 27).

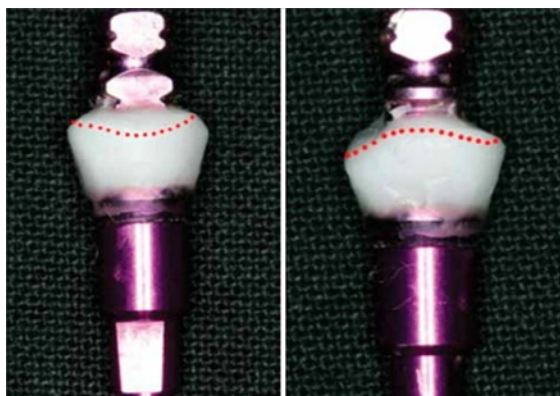


Figure 27. Custom Impression Coping (Picture provided by Dr. Russell Wicks)

Table 1. Steps for Chairside Fabrication of Custom Healing Abutments⁵⁸

1. An engaging temporary abutment (titanium or PEEK) is attached to the implant in the patient's mouth and its buccal surface is marked.

2. The temporary abutment is removed from the mouth, attached to the implant analog, oriented appropriately, and placed in the predetermined mold (selected based on the mesiodistal width of the missing tooth) on the template. The vertical position may be adjusted by moving the implant analog vertically.

3. Temporary abutment is then placed in the predetermined mold and flowable composite resin material is introduced in the space between the mold and the temporary abutment (Figure 16) until the space is filled. The composite is polymerized using a curing light for 20 seconds.



Figure 16.

4. The customized healing abutment is then removed from the template and is light-polymerized for an additional 20 seconds.

5. The intaglio surface is examined for voids which are filled with resin material (Figure 17).




Figure 17.

Table 1 Cont.


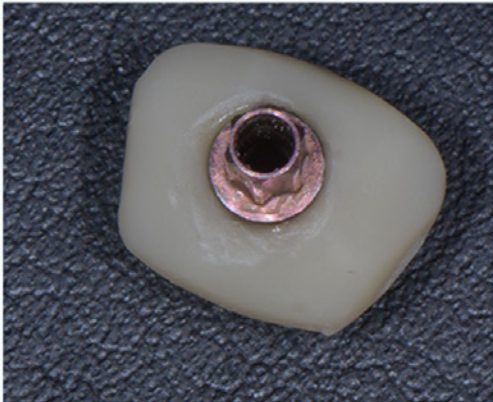
| | |
|----|--|
| 6. | <p>The intaglio surface is adjusted and custom healing abutment is finished to develop smooth contours (Figure 18).</p>  <p>Figure 18. Remove sharp angles and corners rounded.</p> |
| 7. | <p>The height of the temporary abutment is reduced so that it does not interfere with the patient's occlusion.</p> |
| 8. | <p>All surfaces of the customized healing abutment are polished using polishing brushes and paste (Figure 19).</p>  <p>Figure 19.</p> |

Table 1 Cont.

The customized healing abutment is tried in the mouth, and further modified as necessary. It is finished, polished, and attached to the implant (Figure 20).

9.

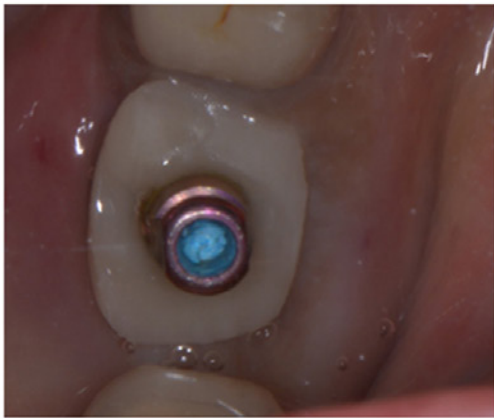

Figure 20.

A radiograph is taken (Figure 21) to confirm the complete seating of the custom healing abutment.

10.

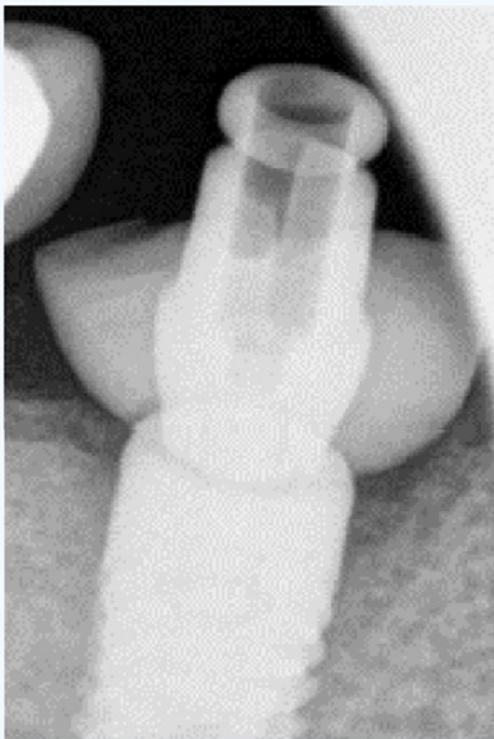


Figure 21.

Table 2. Steps for Custom Healing Abutment using the Cervical Contouring Concept:⁶⁰

1. A conventional wax-up is created on the diagnostic cast.

2. The cervical extent of the wax-up is traced circumferentially using a marker.

The wax-up is indexed using laboratory putty which is then used to transfer the traced marking to the implant-level cast (recorded at the time of implant placement) (Figure 22).

3.



Figure 22.

The cast is sculpted using laboratory rotary instruments (Figure 23) in the area slightly superficial to the implant platform up to the marked line such that there would be a smooth and gradual transition from the implant platform to the marked line. Care is taken to avoid nicking the platform of the implant analog.

4.



Figure 23.

Table 2 Cont.

An engaging temporary abutment is attached to the implant analog on the modified cast. The space between the abutment and the marking is filled with a flowable resin material (Figure 24). The composite resin is polymerized using a curing light (Figure 25).



5.


Figure 24.



Figure 25.

6. The height of the temporary abutment is adjusted to ensure it does not interfere with the patient's occlusion.

The modified temporary abutment/customized healing abutment is removed from the cast, the intaglio surface is evaluated, and voids if any are filled with the resin material and polymerized via curing light (Figure 26).



7.

Figure 26.

8. The customized healing abutment is tried in the mouth, and may be further modified as necessary. It is finished, polished, and attached to the implant.

9. A radiograph is taken to confirm the complete seating of the custom healing abutment.

The procedural steps for the fabrication of a custom impression coping are shown in the following **Table 3:**




| Table 3. Steps for Fabricating a Custom Impression Coping: ^{12,66} | |
|---|---|
| 1. | <p>The provisional restoration restoration/custom healing abutment is removed from the patient's mouth, and attached to an implant analog.</p> |
| 2. | <p>The assembly is placed in a dappen dish/paper cup filled with freshly mixed impression material (Figure 28); The impression material should extend up to the middle third of the provisional restoration restoration/top of the custom healing abutment.</p>  <p>Figure 28.</p> |
| 3. | <p>Once the impression material polymerizes, the provisional restoration/custom healing abutment is removed (Figure 29) and replaced in its designated position in the oral cavity.</p>  <p>Figure 29.</p> |
| 4. | <p>An open tray impression coping is attached to the implant analog (Figure 30) retained in the dappen dish.</p>  <p>Figure 30.</p> |

Table 3 Cont.

Flowable composite resin is introduced around the impression coping (Figure 31) to fill the void between the coping and the impression material (area of the transmucosal contour). The composite is polymerized using a curing light for 20 seconds.

5.



Figure 31.

The custom impression coping is removed from the dappen dish (Figure 32) and attached to the implant platform intraorally in the mouth.

6.



Figure 32.

7. An open tray impression is then made with this customized impression coping supporting the soft tissue profile.

8. The impression is poured using a soft tissue replacement material around the customized impression coping. This enables the fabrication of a soft-tissue cast that replicates the developed intraoral emergence profile and guides in the creation of optimal contours of the definitive restoration.

Next, the interocclusal record, the opposing arch, and the shade are recorded. The restoration is fabricated and placed using standard prosthodontic procedures.

Summary

Thorough diagnosis and treatment planning are necessary to develop the optimal transmucosal contours of an implant restoration. The contour of the soft tissues may be either preserved at the time of tooth extraction or subsequently reconstructed using a provisional restoration/custom healing

abutment. Depending on the thickness of the soft tissues, implant position, and timing of placement, the transmucosal region of the provisional restoration/custom healing abutment may require different shapes. Provisionalisation/placement of a custom healing abutment is a critical step to help achieve optimal implant esthetics and soft tissue contours in a final restoration. Careful attention to the key steps in the fabrication and development of provisionals and/or custom healing abutments can optimize implant success and patient satisfaction.

Course Test Preview

To receive Continuing Education credit for this course, you must complete the online test. Please go to: www.dentalcare.com/en-us/ce-courses/ce684/test

1. Which two factors play a critical role in developing an optimal emergence profile?

- A. Implant position and bone volume
- B. Implant position and tissue volume
- C. Restoration position and bone volume
- D. Restoration position and tissue volume

2. The emergence profile of a restoration will affect the _____.

- A. esthetics and occlusion.
- B. esthetics and the periodontal health of the surrounding soft tissues.
- C. occlusion and periodontal health of the surrounding soft tissues.
- D. orthodontic stability.

3. Consider the following two statements:

The subcritical contour is associated with the cervical margin of the restoration.

The critical contour is located immediately coronal to the implant platform.

- A. Both the statements are false.
- B. Both the statements are true.
- C. The first statement is true the second is false.
- D. The first statement is false, the second is true.

4. The interproximal critical contour affects the _____.

- A. apparent shape of the crown.
- B. position of the facial gingival margin.
- C. shape of the crown and the zenith of the facial margin.
- D. zenith of the facial mucosal margin.

5. Which form/shape is most commonly used while designing the subcritical facial contour?

- A. Concave
- B. Convex
- C. Convexo-concave
- D. Straight

6. What is the minimum amount of keratinized tissue thickness that should be present to maintain the long-term health of the implant?

- A. 1mm
- B. 2mm
- C. 3mm
- D. 4mm

7. A thick peri-implant mucosal phenotype has a mucosal thickness of _____.

- A. equal to or more than 0.3mm.
- B. equal to or more than 0.5mm.
- C. equal to or more than 1.3mm.
- D. equal to or more than 1.6mm.
- E. equal to or more than 2mm.

8. Which of the following is a characteristic of thin peri-implant mucosal phenotype?

- A. broad contact areas.
- B. large amount of keratinized tissue.
- C. flat bony architecture.
- D. thick marginal bone.
- E. triangular anatomic crowns.

9. Consider the following two statements:

Mesio-distally, the implant should be centered in the missing tooth space with at least 2.5mm space between the implant and the adjacent tooth CEJ to provide optimal tissue contours and appropriately distribute the forces.

Maintaining the minimum distance ensures that the vertical defect associated with the implant will not affect the bone of the adjacent natural tooth.

- A. Both the statements are false.
- B. Both the statements are true.
- C. The first statement is true the second is false.
- D. The first statement is false, the second is true.

10. Which of the following would be indicated to maintain/condition the soft tissues when the implant has suboptimal primary stability?

- A. Custom healing abutment
- B. Customized impression coping
- C. Provisional restoration
- D. Stock healing abutment

References

1. González-Martín O, Lee E, Weisgold A, Veltri M, Su H. Contour management of implant restorations for optimal emergence profiles: Guidelines for immediate and delayed provisional restorations. *Int J Periodontics Restorative Dent*. 2020;40(1):61-70.
2. Rojas-Vizcaya F. Biological aspects as a rule for single implant placement. The 3A-2B rule: a clinical report. *J Prosthodont*. 2013;22(7):575-80.
3. Beretta M, Poli PP, Pieriboni S, Tansella S, Manfredini M, Cicciù M, Maiorana C. Peri-implant soft tissue conditioning by means of customized healing abutment: A randomized controlled clinical trial. *Materials*. 2019;12(18):3041.
4. Esquivel J, Meda RG, Blatz MB. The impact of 3d implant position on emergence profile design. *Int J Periodontics Restorative Dent*. 2021;41(1):79-86.
5. Liu X, Tan Y, Liu J, Tan J. A digital technique for fabricating implant-supported interim restorations in the esthetic zone. *J Prosthet Dent*. 2018;119(4):540-4.
6. Chu SJ, Kan JY, Lee EA, Lin GH, Jahangiri L, Nevins M, Wang HL. Restorative emergence profile for single-tooth implants in healthy periodontal patients: Clinical guidelines and decision-making strategies. *Int J Periodontics Restorative Dent*. 2019;40(1):19-29.
7. Su H, Gonzalez-Martin O, Weisgold A, Lee E. Considerations of implant abutment and crown contour: critical contour and subcritical contour. *Int J Periodontics Restorative Dent*. 2010;30(4):335-43.
8. The Glossary of prosthodontic terms 2023: Tenth edition. *J Prosthet Dent*. 2023;130(4 Suppl 1):e1-e3.
9. Minoru S, Sato D, Baba K. Optimization of emergence profile of implant prosthesis: a literature review. *Scientific Dental Journal*. 2018;2(1):31. Accessed June 6, 2024
10. Son MK, Jang HS. Gingival recontouring by provisional implant restoration for optimal emergence profile: report of two cases. *J Periodontal Implant Sci*. 2011;41(6):302-8.
11. Bishara M, Kurtzman GM, Krause ES. Implant restorations: Establishing a proper emergence Profile. *Compend Contin Educ Dent*. 2020 Sep;41(8):e16-e20.
12. Alshiddi IF, Dent DC. Accurate registration of peri-implant soft tissues to create an optimal emergence profile. *Contemp Clin Dent*. 2015;6(Suppl 1):S122-5.
13. Jivraj S, Chee W. Treatment planning of implants in the aesthetic zone. *Br Dent J*. 2006;201(2):77-89.
14. Ramanauskaite A, Schwarz F, Sader R. Influence of width of keratinized tissue on the prevalence of peri-implant diseases: A systematic review and meta-analysis. *Clin Oral Implants Res*. 2022;33 Suppl 23:8-31.
15. Linkevicius T, Puisys A, Steigmann M, Vindasiute E, Linkeviciene L. Influence of Vertical Soft Tissue Thickness on Crestal Bone Changes Around Implants with Platform Switching: A Comparative Clinical Study. *Clin Implant Dent Relat Res*. 2015 Dec;17(6):1228-36.
16. Linkevicius T, Apse P, Grybauskas S, Puisys A. The influence of soft tissue thickness on crestal bone changes around implants: a 1-year prospective controlled clinical trial. *Int J Oral Maxillofac Implants*. 2009 Jul-Aug;24(4):712-9
17. Cavallaro J, Greenstein, G. Prosthodontic complications related to non-optimal dental implant placement. *Dental Implant Complications: Etiology, Prevention, and Treatment*. 2010:156-71. Accessed June 6, 2024
18. Seibert JL, Lindhe J. Esthetics and periodontal therapy. In: Lindhe J, editor. *Textbook of Clinical Periodontology*. 2nd ed. Copenhagen, Denmark: Munksgaard; 1989. pp. 477–514. Accessed June 6, 2024
19. Lin GH, Curtis DA, Kapila Y, Velasquez D, Kan JYK, Tahir P, Avila-Ortiz G, Kao RT. The significance of surgically modifying soft tissue phenotype around fixed dental prostheses: An American Academy of Periodontology best evidence review. *J Periodontol*. 2020 Mar;91(3):339-351.
20. Song JW, Leesungbok R, Park SJ, Chang SH, Ahn SJ, Lee SW. Analysis of crown size and morphology, and gingival shape in the maxillary anterior dentition in Korean young adults. *J Adv Prosthodont*. 2017;9(4):315-20.

21. Singh VP, Uppoor AS, Nayak DG, Shah D. Black triangle dilemma and its management in esthetic dentistry. *Dent Res J (Isfahan)* 2013;10(3):296-301.
22. Ahuja S, Cagna DR. Defining available restorative space for implant overdentures. *J Prosthet Dent.* 2010;104(2):133-6.
23. Misch C. *Dental Implant Prosthetics*, Second Edition, Elsevier Health Sciences, St. Louis, MO, 2015.
24. Nissan J, Ghelfan O, Gross O, Priel I, Gross M, Chaushu G. The effect of crown/implant ratio and crown height space on stress distribution in unsplinted implant supporting restorations. *J Oral Maxillofac Surg.* 2011;69(7):1934-9.
25. Shenoy, Vidya Kamalaksh. Single tooth implants: Pretreatment considerations and pretreatment evaluation. *J Interdiscip Dent.* 2012;2(3):149-57.
26. Monteiro DR, Silva EV, Pellizzer EP, Filho OM, Goiato MC. Posterior partially edentulous jaws, planning a rehabilitation with dental implants. *World J Clin Cases.* 2015;3(1):65-76.
27. Katafuchi M, Weinstein BF, Leroux BG, Chen YW, Daubert DM. Restoration contour is a risk indicator for peri-implantitis: A cross-sectional radiographic analysis. *J Clin Periodontol.* 2018 Feb;45(2):225-232.
28. van Hooft J, Kielenstijn G, Liebrechts J, Baan F, Meijer G, D'haese J, Bronkhorst E, Verhamme L. Intraoral scanning as an alternative to evaluate the accuracy of dental implant placements in partially edentate situations: A prospective clinical case series. *J Clin. Med.* 2022;11(19):5876.
29. Flügge T, Kramer J, Nelson K, Nahles S, Kern F. Digital implantology-a review of virtual planning software for guided implant surgery. Part II: Prosthetic set-up and virtual implant planning. *BMC Oral Health.* 2022;22(1):23.
30. Bianchi J, Mendonca G, Gillot M, Oh H, Park J, Turkestani NA, Gurgel M, Cevidanes L. Three-dimensional digital applications for implant space planning in orthodontics: A narrative review. *J World Fed Orthod.* 2022;11(6):207-15.
31. Luthra KK. Implant success!!!.....simplified. *J Indian Soc Periodontol.* 2009;13(1):27-9.
32. Liu W, Zhu F, Samal A, Wang HL. Suggested mesiodistal distance for multiple implant placement based on the natural tooth crown dimension with digital design. *Clin Implant Dent Relat Res.* 2022;24(6):801-8.
33. Su, CY, Fu JH, Wang HL. The role of implant position on long-term success. *Clin Adv Periodontics* 2014;4:187-93.
34. Grunder U, Gracis S, Capelli M. Influence of the 3-D bone-to-implant relationship on esthetics. *Int J Periodon Restor Dent.* 2005;25:113-9.
35. Ebenezer S, Kumar VV, Thor A. Basics of dental implantology for the oral surgeon. In: Bonanthaya, K., Panneerselvam, E., Manuel, S., Kumar, V.V., Rai, A. (eds) *Oral and Maxillofacial Surgery for the Clinician*. Springer, Singapore 2021. Accessed June 6, 2024
36. Meng HW, Chien EY, Chien HH. Immediate implant placement and provisionalization in the esthetic zone: A 6.5-year follow-up and literature review. *Case Rep Dent.* 2021;2021:4290193.
37. Verma, Mahesh; Nanda, Aditi; Sood, Abhinav. Principles of occlusion in implant dentistry. *J Int Clin Dent Res Org.* 2015;7(Suppl 1):p S27-S33.
38. Hamilton A, Putra A, Nakapaksin P, Kamolroongwarakul P, Gallucci G.O. Implant prosthodontic design as a predisposing or precipitating factor for peri-implant disease: A review. *Clin Implant Dent Relat Res* 2023;25(4):710-22.
39. Chokaree P, Poovarodom P, Chaijareenont P, Yavirach A, Rungsiyakull P. Biomaterials and clinical applications of customized healing abutment-A narrative review. *J Funct Biomater.* 2022;13(4):291.
40. Teślak M, Ziemiański A, Foltyn I, Ordyniec-Kwaśnica I, Drogoszewska B. Development of custom anatomic healing abutment based on cone-beam computer tomography measurement on human teeth cross-section. *Materials.* 2021;14:4570.
41. Santosa RE. Provisional restoration options in implant dentistry. *Aust Dent J.* 2007;52(3):234-42; quiz 254.

42. Ladino LG, Rosselli D. Use of extracted anterior teeth as provisional restorations and surgical guide for immediate multiple implant placement: A clinical case report. *J Esthet Restor Dent.* 2019;31(3):209-12.
43. Khzam N, Arora H, Kim P, Fisher A, Mattheos N, Ivanovski S. Systematic review of soft tissue alterations and esthetic outcomes following immediate implant placement and restoration of single implants in the anterior maxilla. *J Periodontol.* 2015;86(12):1321-30.
44. Kan JY, Rungcharassaeng K, Lozada J. Immediate placement and provisionalization of maxillary anterior single implants: 1-year prospective study. *Int J Oral Maxillofac Implants* 2003;18(1):31-9.
45. Pagni G, Pellegrini G, Giannobile WV, Rasperini G. Postextraction alveolar ridge preservation: biological basis and treatments. *Int J Dent.* 2012;2012:151030.
46. Wittneben JG, Buser D, Belser UC, Bragger U. Peri-implant soft tissue conditioning with provisional restorations in the esthetic zone: The dynamic compression technique. *Int J Periodontics Restorative Dent.* 2013; 33(4):447-55.
47. Beretta M, Poli PP, Pieriboni S, Tansella S, Manfredini M, Cicciù M, Maiorana C. Peri-implant soft tissue conditioning by means of customized healing abutment: A randomized controlled clinical trial. *Materials.* 2019;12(18):3041.
48. Bichacho N, Landsberg CJ. Single implant restorations: Prosthetically induced soft tissue topography. *Pract Periodontics Aesthet Dent.* 1997;9(7):745-52.
49. Tarnow DP, Magner AW, Fletcher P. The effect of the distance from the contact point to the crest of bone on the presence or absence of the interproximal dental papilla. *J Periodontol.* 1992 Dec;63(12):995-6.
50. Janakievski J. Case report: Maintenance of gingival form following immediate implant placement - The custom-healing abutment. *Advanced Esthetics & Interdisciplinary Dentistry.* 2007;3:24-8.
51. Sutariya PV, Mehta SP, Upadhyay HH, Pathan MR, Patel SR, Bhatia YA. The soft tissue esthetic outcome with and without immediate provisionalization in immediate implants: A systematic review and meta-analysis. *J Indian Prosthodont Soc.* 2022;22(1):2-12.
52. Ruales-Carrera E, Pauletto P, Apaza-Bedoya K, Volpato CAM, Özcan M, Benfatti CAM. Peri-implant tissue management after immediate implant placement using a customized healing abutment. *J Esthet Restor Dent.* 2019;31(6):533-41.
53. Akin R, Chapple AG. Clinical advantages of immediate posterior implants with custom healing abutments: Up to 8-year follow-up of 115 cases. *J Oral Maxillofac Surg.* 2022 ;80(12):1952-65.
54. Menchini-Fabris GB, Cosola S, Toti P, Hwan Hwang M, Crespi R, Covani U. Immediate implant and customized healing abutment for a periodontally compromised socket: 1-year follow-up retrospective evaluation. *J Clin Med.* 2023;12(8):2783.
55. Douglas M. Custom healing abutment fabrication using extracted teeth. Replicating the natural emergence profile supports the dentogingival complex, facilitates hygiene
Inside Dental Technology 2023;14(1).
56. Vág J, Freedman G, Szabó E, Románszky L, Berkei G. Cervical tooth anatomy considerations for prefabricated anatomic healing abutment design: A mathematical formulation. *J Prosthet Dent.* 2022;127(6):852-9.
57. Pow EHN, McMillan AS. A modified implant healing abutment to optimize soft tissue contours: A case report. *Implant Dent.* 2004;13:297-300.
58. Almadani TM, Abozaid HM, Elsayed IS, Amer AM. Clinical and radiographic evaluation of peri-implant tissue changes associated with use of standard versus customized healing abutments. *Al-Azhar Journal of Dental Science* 2023;26:229-39. Accessed June 6, 2024
59. Bichacho N. Cervical contouring concepts: enhancing the dentogingival complex. *Pract Periodontics Aesthet Dent.* 1996;8(3):241-54; quiz 256. PMID: 9028279.
60. Bichacho N, Landsberg CJ. A modified surgical/prosthetic approach for an optimal single implant-supported crown. Part II. The cervical contouring concept. *Pract Periodontics Aesthet Dent.* 1994;6(4):35-41; quiz 41. PMID: 8054640.

61. Zeng H, Zhou M, Ge Y, Yao Y, Cai X. Digital workflow in the design of individualized emergence profiles of implant restorations based on the contralateral tooth. *J Prosthodont Res.* 2024 Jan 3.
62. Alshhrani WM, Al Amri MD. Customized CAD-CAM healing abutment for delayed loaded implants. *J Prosthet Dent.* 2016;116(2):176-9.
63. El-Danasory MB, Khamis MM, Abdel Hakim AA, Fahmy RA. CAD-CAM custom healing abutments: A dental technique. *J Prosthet Dent.* 2022 Nov 8:S0022-3913(22)00638-2.
64. Chee WW, Cho GC, Ha S. Replicating soft tissue contours on working casts for implant restorations. *J Prosthodont* 1997;6:218-20.
65. Buskin R, Salinas TJ. Transferring emergence profile created from the provisional to the definitive restoration. *Pract Periodontics Aesthet Dent.* 1998;10:1171-9.
66. Patras M, Martin W. Simplified custom impression post for implant-supported restorations. *J Prosthet Dent.* 2016;115(5):556-9.

Additional Resources

- No Additional Resources Available

About the Author

Swati Ahuja, BDS, MDS



Dr. Ahuja graduated with a BDS from Nair Hospital Dental College in 2002 and an MDS certificate in Prosthodontics from the University of Tennessee Health Science Center, Memphis, TN. She then joined the same University as an Assistant Professor in the Department of Prosthodontics where she worked for 3 and half years. She served as the editor for the Department of Prosthodontics at University of Tennessee Health Science Center, Memphis, TN for the next 6 years. She has lectured nationally and internationally on various prosthodontic topics at various dental conferences. She has more than 60 publications in peer reviewed national and international journals. Dr. Ahuja is also the co-author of the textbook titled, "Applications of the Neutral Zone in Prosthodontics." Currently, she has a private practice in Mumbai.

Updated: Nov 2022

Email: swatiahuja@gmail.com