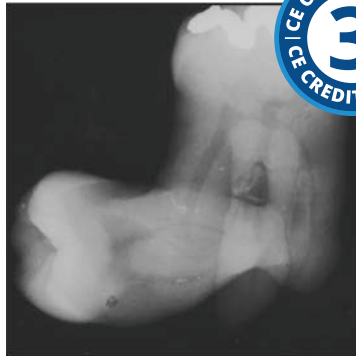

Anomalies of Tooth Structure



Course Author(s): Gail F. Williamson, Professor Emerita

CE Credits: 3 hours

Intended Audience: Dentists, Dental Hygienists, Dental Assistants, Dental Students, Dental Hygiene Students, Dental Assistant Students

Date Course Online: 06/24/2021

Last Revision Date: N/A

Course Expiration Date: 06/23/2024

Cost: Free

Method: Self-instructional

AGD Subject Code(s): 730

Online Course: www.dentalcare.com/en-us/professional-education/ce-courses/ce651

Disclaimers:

- P&G is providing these resource materials to dental professionals. We do not own this content nor are we responsible for any material herein.
- Participants must always be aware of the hazards of using limited knowledge in integrating new techniques or procedures into their practice. Only sound evidence-based dentistry should be used in patient therapy.

Conflict of Interest Disclosure Statement

- Ms. Williamson reports no conflicts of interest associated with this course. She has no relevant financial relationships to disclose.

Introduction – Dental Anomalies

This course will present the radiographic appearance of the various components of tooth structure as well as the development and eruption of the primary and permanent dentitions. Subsequently, dental anomalies associated with the eruption, number, size, and shape of the teeth along with acquired alterations of tooth structure will be discussed. This information will facilitate differentiation between normal and abnormal tooth structure and enhance the ability to recognize and describe various tooth related anomalies.

Course Contents

- Overview
- Learning Objectives
- Introduction
- Normal Radiographic Appearance of Teeth
- Normal Radiographic Appearance of the Supporting Structures of the Teeth
- Eruption of Primary, Mixed, and Permanent Dentition
 - Primary and Permanent Dentition Eruption Sequences
 - Universal Tooth Numbering System
 - Delayed Eruption
 - Transposition
- Congenital, Developmental, and Acquired Anomalies
- Alterations in the Number of Teeth
- Alterations in the Size of Teeth
- Alterations in the Shape of Teeth
 - Conjoined Teeth
 - Talon Cusp
 - Dens Evaginatus and Dens Invaginatus
 - Enamel Pearls
 - Taurodontism
 - Hypercementosis
 - Dilaceration
 - Supernumerary Roots
- Loss of Tooth Structure
 - Attrition
 - Abrasion
 - Abfraction
 - Erosion
 - Resorptive Processes
- Dentinal Deposition
- Summary
- Course Test
- References / Additional Resources
- About the Author

Overview

This course will focus on the normal radiographic appearance of the teeth as viewed on intraoral and panoramic radiographic images followed by the presentation of anomalies associated with the teeth. Recognition of the normal radiographic appearance of the teeth serves as a baseline to differentiate normal from abnormal. Anomalies or alterations of the teeth can be congenital, developmental, or acquired and include a variety of changes associated with the eruption, number, size, and shape of the teeth as well as acquired variations.

Learning Objectives

Upon completion of this course, the dental professional should be able to:

- Recognize and describe the radiographic appearance of healthy tooth structure in both the primary and permanent dentitions including eruption patterns.
- Recognize and describe the radiographic appearance of healthy supporting structures of the teeth.
- Describe the various origins of dental anomalies; congenital, developmental, and acquired.
- Recognize and describe processes that can interfere with normal tooth eruption.
- Identify and classify tooth impactions by their position.
- Recognize and describe processes that can cause loss of tooth structure.
- Discuss and identify alterations in tooth structure and the dental pulp.
- Identify and describe alterations in the number of teeth.
- Recognize and discuss alterations in the size of teeth.
- Identify and describe alterations in the shape of teeth.
- Given an intraoral radiograph, radiographic survey and/or a panoramic image, identify and describe anomalies that may be recorded on those images.

Introduction

Fundamental to basic radiographic interpretation of intraoral and panoramic radiographic images is the ability to recognize normal tooth structure and how teeth appear radiographically during various stages of growth and development. This discussion will begin with a review of the various components of tooth structure and the supporting structures of the teeth, followed by presentation of tooth structure anomalies.

Normal Radiographic Appearance of Teeth

Enamel, Dentin, Cementum, Pulp

The teeth are comprised of four basic anatomic structures: enamel, dentin, cementum, and the pulp (Figure 1). The enamel is the layer of mineralized tissue covering the crown of the tooth, which has the highest level of

calcified content, approximately 95%.¹ As a result, the enamel appears highly radiopaque (white) on dental images. Underlying the dense enamel layer is the dentin. The dentin, less calcified than enamel with about 75% mineralized content, composes the majority of the tooth.¹ It appears less radiopaque than the enamel due to its lesser mineral content. The dentinoenamel junction (DEJ) is the distinct interface between the enamel and dentin in the coronal aspect of the tooth, while the cementoenamel junction (CEJ) is the interface at the cervical region of the tooth where the crown intersects with the root(s). The cementum covers the root of the tooth but cannot be distinguished from dentin radiographically.² Finally, the pulp, located in the center of the tooth, contains the nerve and blood supply. The pulp cavity consists of the pulp chamber and pulp canals. The canals are narrow linear structures that extend from the broader pulp chamber and terminate at the end of the root(s). Pulpal anatomy varies, appearing more linear in anterior teeth, while in posterior teeth, the pulp appears like a miniature tooth within the tooth itself. As a non-calcified structure, the pulp appears radiolucent (black) on radiographic images. The size of the dental pulp varies with maturity, appearing larger in children (Figure 2) and more diminished in adults as they age.³

Normal Radiographic Appearance of the Supporting Structures of the Teeth

Cancellous Bone

The maxilla and mandible are composed of cancellous or trabecular bone located between the dense cortical outer plates. The cancellous

bone consists of trabeculae, thin bony rods, and plates, surrounded by areas of bone marrow, presenting a mixed radiopaque and radiolucent radiographic appearance.² The bone pattern varies among individuals as well as in the different regions of the dental arches.³ The maxilla, especially in the anterior region, has numerous thin trabeculae with many small marrow spaces, displaying a fine granular appearance radiographically.² The posterior maxilla demonstrates a similar pattern with larger marrow spaces (Figures 3-4).² In comparison, the anterior mandible shows thicker trabeculae with a coarser horizontal pattern with fewer plates and larger marrow spaces than the maxilla.² The posterior regions of the mandible exhibit a pattern similar to the anterior region, but the trabeculae and marrow spaces tend to be larger and sparser (Figures 5-6).² A ladder-like effect may be visualized due to the large size of the posterior marrow spaces. Apical to the molar teeth, the trabeculae may be very sparse or appear to be absent, resulting in a very radiolucent radiographic appearance which may be misinterpreted as pathologic.²

Alveolar Bone and Alveolar Crest

The alveolar bone is the teeth-bearing bony process of the jaws. The alveolar crest is the gingival margin of the alveolar process and extends between and around the tooth root(s).^{4,5} The crest is covered by a thin layer of cortical bone, appearing radiopaque radiographically (Figure 7).^{3,4} The crestal alveolar bone level ranges from 0.5 to 2.0 millimeters from the CEJ, in health, and follows the plane of adjacent CEJs.⁴ The shape of the crestal bone varies from narrow and pointed

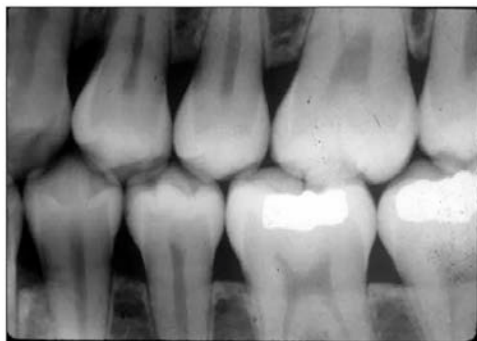


Figure 1. Bitewing radiograph displaying enamel, dentin, and pulp structures.

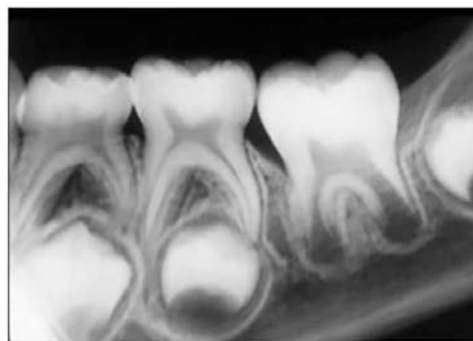


Figure 2. Periapical radiograph of posterior primary and developing permanent teeth.

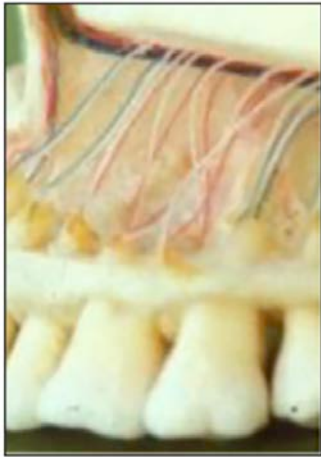

Figure 3. Maxillary posterior cancellous bone.

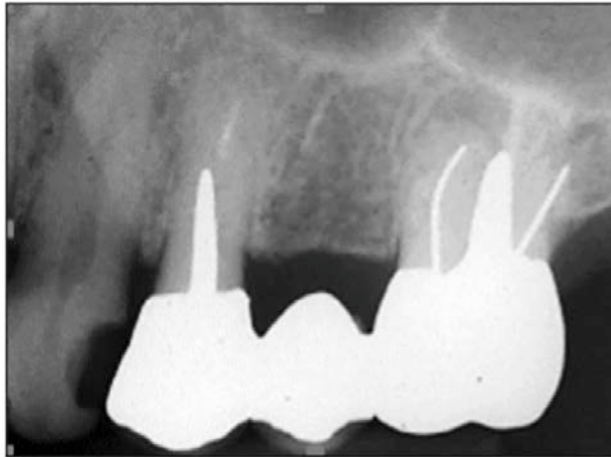


Figure 4. Periapical radiograph of maxillary posterior bone pattern.

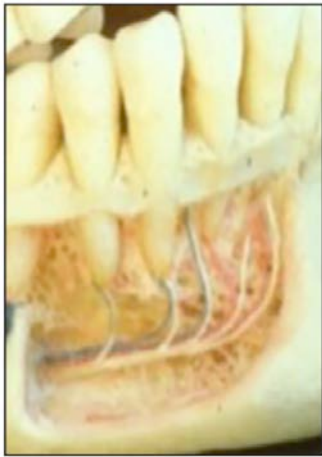

Figure 5. Mandibular posterior cancellous bone.

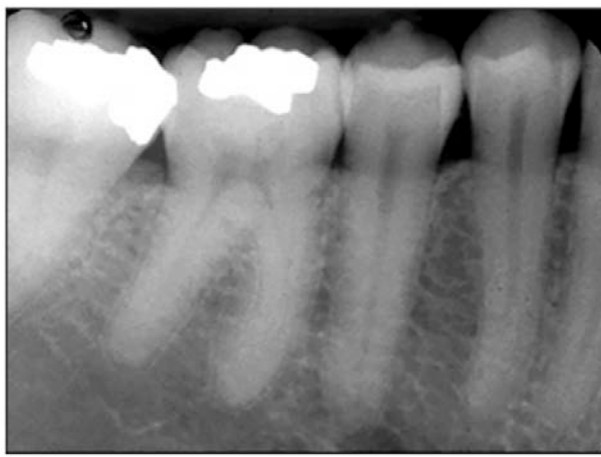


Figure 6. Periapical radiograph of mandibular posterior bone pattern.

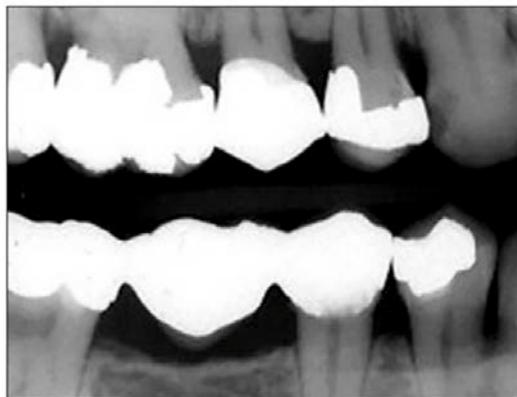

Figure 7. Bitewing radiograph of posterior alveolar bone crests.

between the anterior teeth and flat and angular between the posterior teeth.³ The crestal shape is dictated by the space or distance between the teeth.²

Lamina Dura and Periodontal Ligament Space

Surrounding the tooth root(s) is a layer of dense bone which lines the tooth socket called the lamina dura (LD) (Figure 8).² This radiopaque structure is contiguous with the alveolar crests.³ The thickness and degree of radiopacity of the lamina dura varies with occlusal function.² It is thicker and more radiopaque with heavy function and thinner and less radiopaque with loss of function.² Immediately adjacent to the lamina dura is the periodontal ligament space (PDLS) which contains flexible collagen fibers surrounding and cushioning the tooth root in its bony socket.¹ It is a radiolucent structure that begins at the alveolar crest, surrounds the root, and returns back to the crest on the other side of the tooth (Figure 8).² The periodontal ligament varies in width, demonstrating differences among patients and the dentition itself.² In normal function, the periodontal ligament space appears thinner mid-root and wider at the crest and root apex.²⁻⁴

Eruption of Primary, Mixed, and Permanent Dentition

The teeth develop and erupt in three different stages: primary (deciduous), mixed, and permanent dentitions. All teeth begin their development in a tooth follicle or dental sac with coronal development occurring first followed by progressive apical formation until the root end is closed. As mentioned previously, the dental pulp is larger in immature teeth and smaller in mature teeth.⁵ As primary or permanent teeth develop, the root apex/apices remain open until the root is fully formed.

Primary and Permanent Dentition Eruption Sequences

Primary Dentition Eruption Sequence

The primary dentition starts to erupt at around 6 months of age, beginning with the mandibular central incisors and ending with

the eruption of the maxillary second primary molars between 25-33 months (2-2.75 years).⁶ Table 1 outlines the eruption sequence for the primary dentition.⁶ The primary dentition consists of 20 teeth including 4 central incisors (E, F, O, P), 4 lateral incisors (D, G, N, Q), 4 canines (C, H, M, R), 4 first molars (B, I, L, S), and 4 second molars (A, J, K, T) distributed equally between the two dental arches (Figures 9-10).

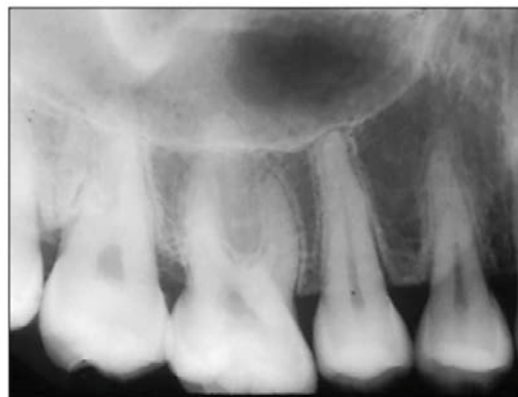

Figure 8. Periapical radiograph of showing the LD and PDLS.

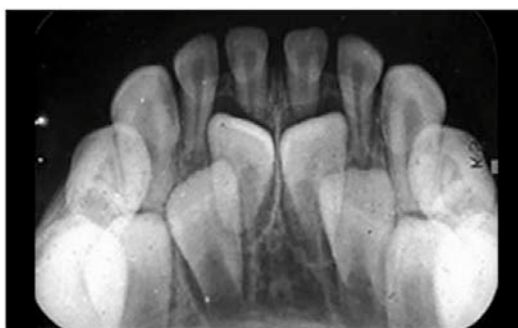


Figure 9. Periapical radiograph of primary mandibular anterior teeth.

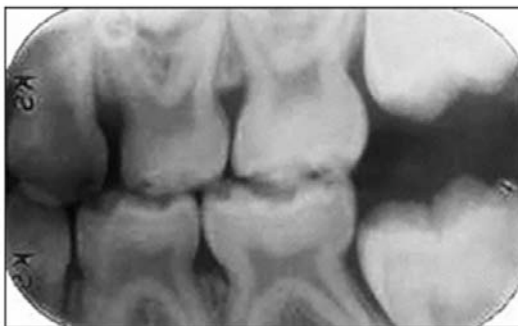

Figure 10. Bitewing radiograph of primary posterior teeth.

Table 1. Primary Dentition Eruption.⁶

Tooth Type	Months
Mandibular Centrals	6-10
Maxillary Centrals	8-12
Maxillary Laterals	9-13
Mandibular Laterals	10-16
Maxillary First Molars	13-19
Mandibular First Molars	14-18
Maxillary Canines	16-22
Mandibular Canines	17-23
Mandibular Second Molars	23-31
Maxillary Second Molars	25-33

The mixed dentition is composed of a combination of primary and permanent teeth (Figure 11). As the child matures, the primary teeth begin to exfoliate and are replaced by the permanent dentition. The mandibular central incisors and the first molars are the first to erupt, replacing their primary predecessors while the third molar teeth are the last to erupt in the late teen to early adult years.⁶ The permanent dentition consists of 32 teeth including 4 central incisors (8, 9, 24, 25), 4 lateral incisors (7, 10, 23, 26), 4 canines (6, 11, 22, 27), 4 first premolars (5, 12, 21, 28), 4 second premolars (4, 13, 20, 29), 4 first molars (3, 14, 19, 30), 4 second molars (2, 15, 18, 31), and 4 third molars (1, 16, 17, 32) distributed uniformly between the maxilla and mandible. The primary first and second molars are replaced by the premolar teeth and the permanent molar teeth erupt posterior to the primary molars. Table 2 outlines the eruption sequence of the permanent dentition.⁶

Permanent Dentition Eruption Sequence

Table 2. Permanent Dentition Eruption.⁶

Tooth Type	Years
Mandibular Centrals/ First Molars	6-7
Maxillary Centrals/ Mandibular Laterals	7-8
Maxillary Laterals	8-9
Mandibular Canines	9-10
Maxillary First Premolars	10-11
Mandibular First Molars/ Maxillary Second Premolars	10-12
Maxillary Canines/ Mandibular Second Premolars	11-12
Mandibular Second Molars	11-13
Maxillary Second Molars	12-13
Third Molars	17-21

Universal Tooth Numbering System

There are several tooth numbering systems used around the world. In the United States, the Universal System is the most commonly employed.¹ The primary dentition is identified by the letters of the alphabet, A-T, while the permanent dentition is identified by the numbers 1-32. Table 3 outlines the Universal Tooth Numbering System.

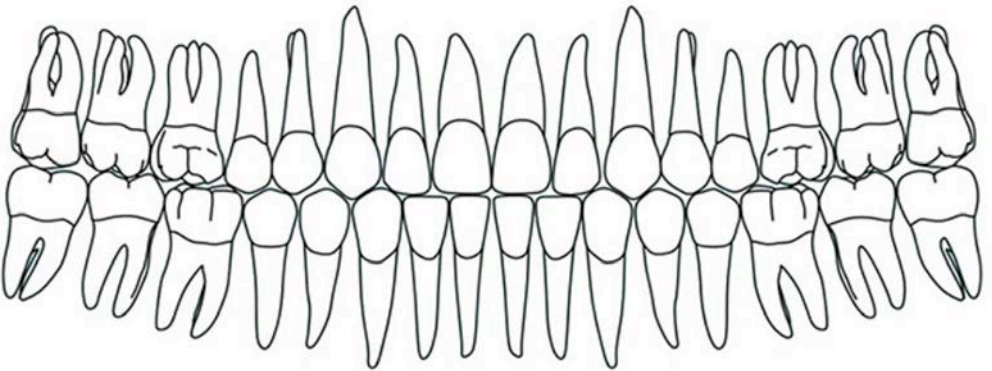
Delayed Eruption

Eruption is the physiologic movement of the teeth from the place of development within the jawbone to its functional position inside the oral cavity.⁷ Typically, the teeth erupt into the mouth when the first part of the tooth crown

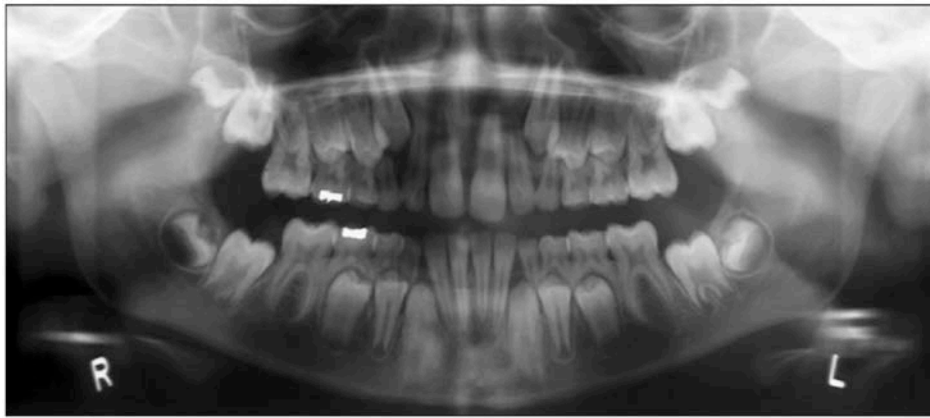

Figure 11. Panoramic radiograph of a mixed dentition.

Table 3. Universal Tooth Numbering System.

MAXILLA															
A	B	C	D	E	F	G	H	I	J						
1	2	3	4	5	6	7	8	9	10	11	12	13	14	15	16
															
32	31	30	29	28	27	26	25	24	23	22	21	20	19	18	17
T	S	R	Q	P	O	N	M	L	K						
MANDIBLE															
RIGHT								LEFT							

peaks through the gingival tissue.⁷ This usually happens once the tooth root is approximately 2/3 of its maximum length.⁷ Tooth eruption occurs over a wide age range and can differ by both gender and race.⁷ Eruption is considered to be delayed if the tooth has not surfaced 12 months after the normal eruption time or when the tooth root is 3/4 complete.⁷ There are a number of reasons why teeth might be delayed in their eruption. The problem can

be localized in which the eruption path is obstructed (Figure 12) or more widespread when a systemic disorder is implicated.⁷ Teeth continue to erupt after emergence to offset masticatory wear and jaw growth.⁷

Ankylosis

Ankylosis is the cessation of eruption after tooth emergence.⁷ This is caused by fusion of the tooth dentin or cementum with the

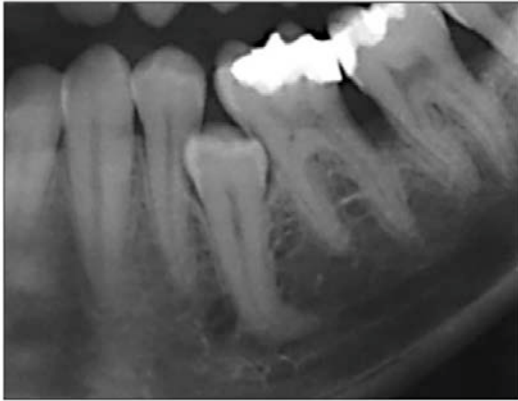


Figure 12. Cropped panoramic image of obstructed eruption path.

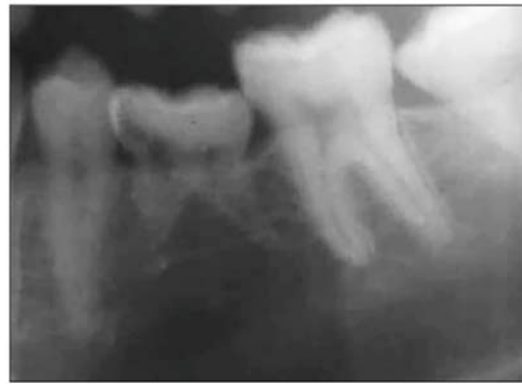

Figure 13. Cropped panoramic image of ankylosed primary tooth K.

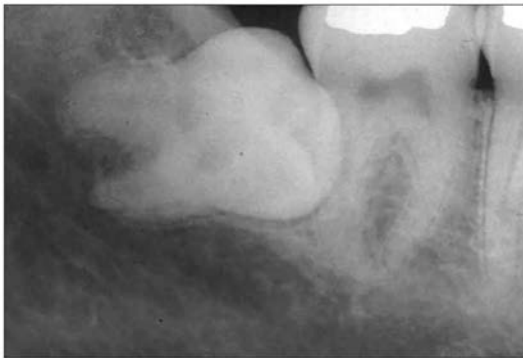


Figure 14. Mesioangular horizontal mandibular third molar impaction #32.

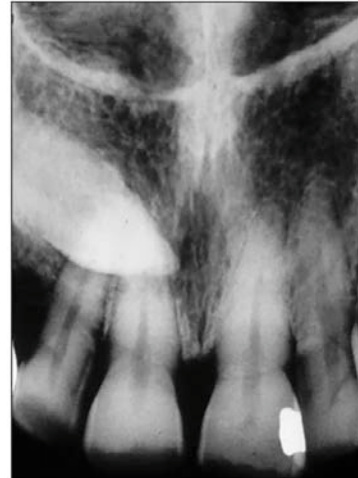

Figure 15. Mesioangular maxillary canine impaction #6.

alveolar bone.⁷ The pathogenesis of this process is not known.⁷ While ankylosis can occur at any age, it is most common in children 8 to 9 years of age.⁷ The teeth that are most frequently involved include the primary mandibular first molar, followed respectively by the primary mandibular second molar (Figure 13), the primary maxillary first molar, and the primary maxillary second molar.⁷ The involved ankylosed tooth usually has a submerged occlusal plane compared to the adjacent teeth and may, upon percussion, produce a sharp, solid sound.⁷ The periodontal ligament space may be absent radiographically.⁷ Permanent teeth rarely become ankylosed.⁷

Impacted Teeth

The term used to describe teeth that fail to erupt is impacted.⁸ Primary teeth impactions are uncommon but when they do happen, the primary second molar is usually involved.⁷ In the permanent dentition, the most commonly impacted teeth in order by frequency are the

mandibular third molars, the maxillary third molars, and the maxillary canine teeth.⁷ See Figures 14-17 for examples of impacted teeth. Impacted teeth are classified according to their position angulation relative to the rest of the erupted dentition such as: mesioangular, distoangular, horizontal, vertical, or inverted.⁷ They can be completely encased in the bone or partially erupted.

Transposition

When two adjacent teeth have exchanged their normal sequential order, the condition is called transposition.⁹ The teeth most frequently involved are the permanent canine and first premolar in which the premolar erupts anterior to the canine tooth (Figure 18).⁹ This condition is observed in the permanent dentition but is not seen in the primary dentition.⁹

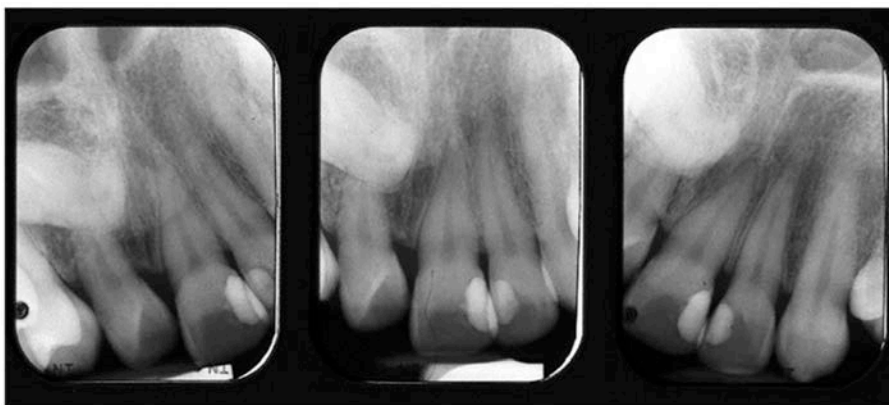


Figure 16. Periapical radiographs of distoangular horizontal impaction of maxillary central incisor #8.

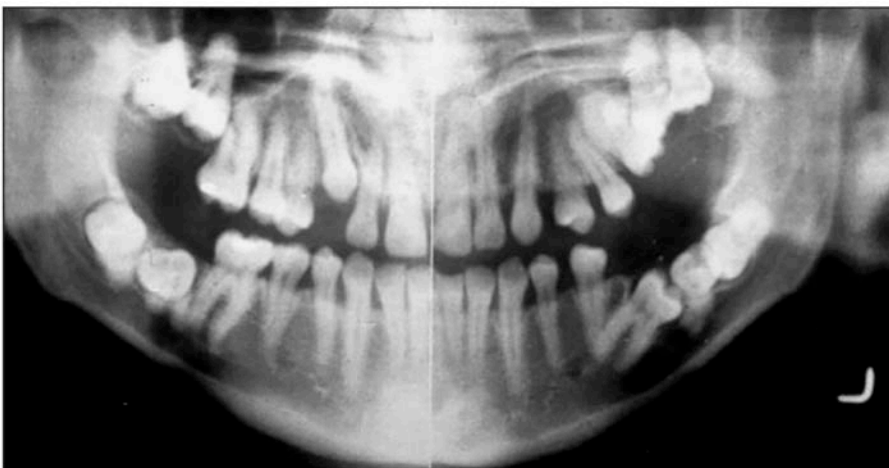


Figure 17. Panoramic radiographic image of multiple impacted molar teeth in various positions.

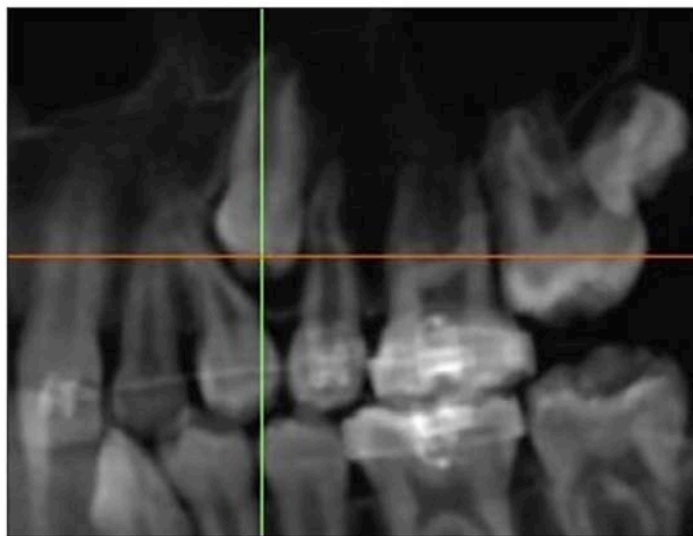


Figure 18. Cropped Cone Beam Computed Tomography (CBCT) panoramic reformat showing transposition of maxillary left first premolar #12 and impacted maxillary left canine #11.

Image courtesy of Dr. Christos Angelopoulos.

Congenital, Developmental, and Acquired Anomalies

The anomalies of tooth structure can be categorized as congenital, developmental, and acquired.⁹ Congenital anomalies are those that are present or exist at the time of birth. Such anomalies may result from genetic, infectious, environmental, or nutritional factors.^{7,9} Developmental anomalies are abnormalities that result from flawed growth and differentiation during tooth formation.⁹ By contrast, acquired anomalies are caused by external factors which affect the teeth subsequent to normal development.⁹

Alterations in the Number of Teeth

There are a number of developmental alterations that may occur which influence the number of teeth that are present. Several different terms are used to describe the absence or presence of teeth.^{7,9} Anodontia is the proper term for the total lack of tooth development involving the entire dentition.⁷ This is uncommon, particularly in the primary dentition. Several other terms are used to define missing teeth such as hypodontia, one or more missing teeth, and oligodontia, six or more missing teeth excluding the third molars.⁷ In contrast, hyperdontia is the development of more than the usual complement of teeth.⁷ These extra teeth are sometimes referred to as supernumerary teeth.^{7,9}

Hypodontia

While rare in the primary dentition, hypodontia is not uncommon in the permanent dentition. In fact, it is one of the most common developmental abnormalities affecting nearly 20% of individuals with a slight female predominance.⁷ The most frequently missing teeth are the third molars, followed by the second premolars (Figure 19), the maxillary lateral incisors, and mandibular central incisors (Figure 20).^{7,9} The maxillary central incisors, the mandibular first molars, and canines are the least likely teeth to be absent.⁷

In instances in which multiple teeth are missing, especially key teeth like maxillary central incisors or the first molars, a hereditary condition known as ectodermal dysplasia should be considered.^{7,9} In this entity, the teeth

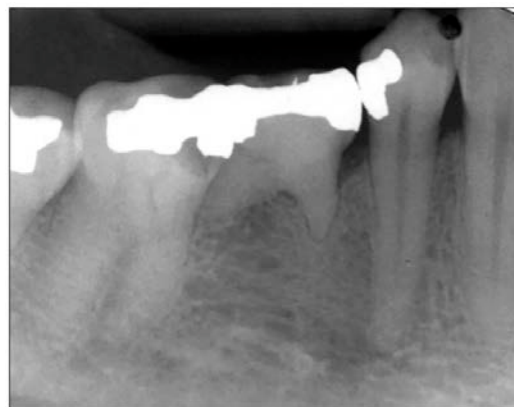

Figure 19. Congenitally missing mandibular right premolar #29.

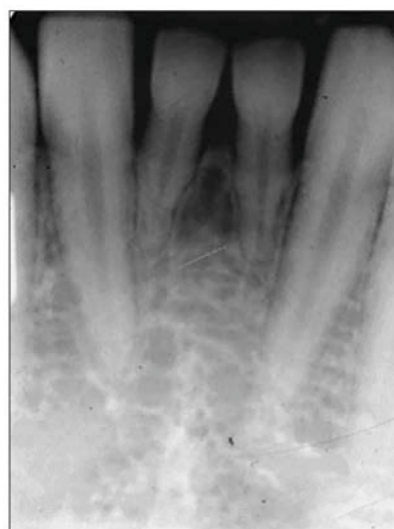

Figure 20. Congenitally missing mandibular central incisors #24 & #25.

that are present have an abnormal crown shape (Figure 21).⁹ Clinically, dermal adnexal structures like hair, eyebrows and eyelashes are also affected.^{9,10}

Hyperdontia

Extra or supernumerary teeth usually involve a single tooth in the permanent dentition within the maxilla, particularly in the anterior segment.⁷ Other common sites for supernumerary teeth include the maxillary molar area, and the mandibular molar, premolar, canine, and lateral incisor areas.^{7,9} A supernumerary tooth in the anterior maxilla is a mesiodens (Figure 22), while a fourth molar tooth is a distodens or distomolar (Figure 23),

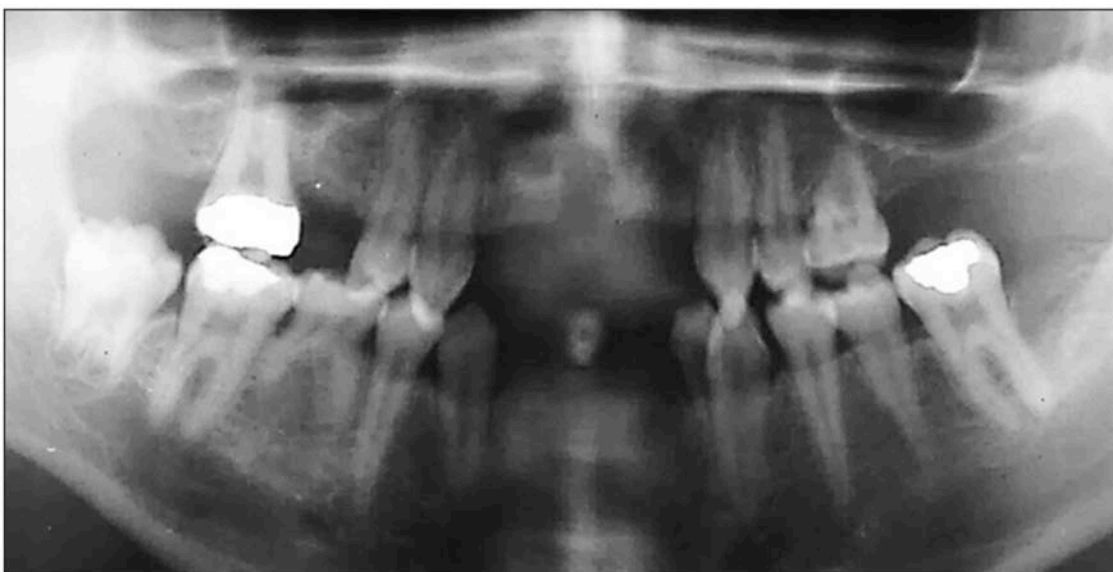

Figure 21. Cropped panoramic radiograph of child patient with ectodermal dysplasia.

Image courtesy of Dr. Géza T. Terézhalmy.

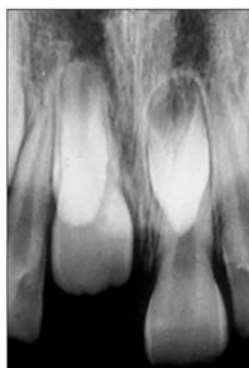
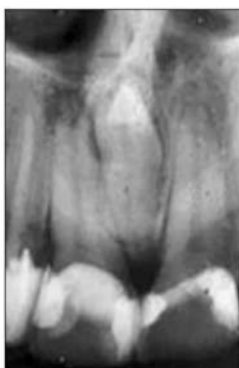

Figure 22. Periapical radiographs of single and multiple mesiodens.

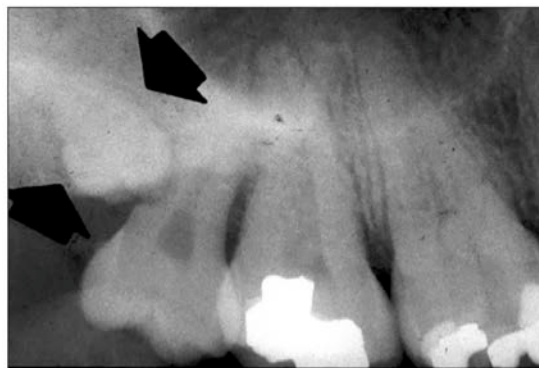


Figure 23. Periapical radiograph of a maxillary distomolar.

and an extra tooth in the premolar area is a peridens (Figure 24).⁷⁻¹⁰ The term paramolar is used for a posterior extra tooth positioned buccally or lingually to a molar tooth.^{7,10} Supernumerary teeth can be of normal size and shape or abnormally shaped and diminished in size.⁷ The latter type can display various shapes including conical, barrel-like or a petite version of a molar or premolar tooth.⁷ These teeth can be erupted or unerupted.

It is possible that supernumerary teeth will present in a multiple manner. When multiple extra teeth occur, the most common location is in the mandibular premolar region (Figure 24), but molar and anterior areas also can be involved (Figure 25).⁷

Alterations in the Size of Teeth

Tooth size is variable among racial groups and between genders.^{7,9} Generally speaking, males have larger teeth than females.^{7,9} Both genetic and environmental factors can impact the size of the developing teeth.⁷ Microdontia is the term used for teeth that are smaller than normal while macrodontia is the presence of teeth that are larger than usual.^{7,9,10} Typically, these conditions do not affect the entire dentition.⁹

Microdontia

In microdontia, the teeth are visibly smaller and may have an altered shape.⁷ Supernumerary teeth may present as microdents as well.⁹ The maxillary lateral incisor tooth (Figure 26)

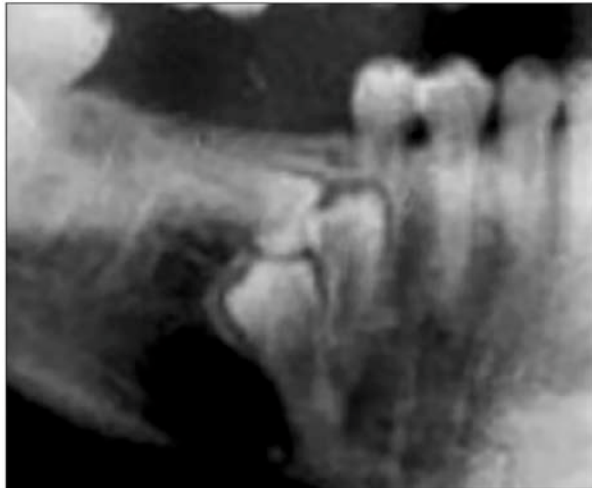

Figure 24. Cropped panoramic radiograph of supernumerary premolar teeth, peridons.

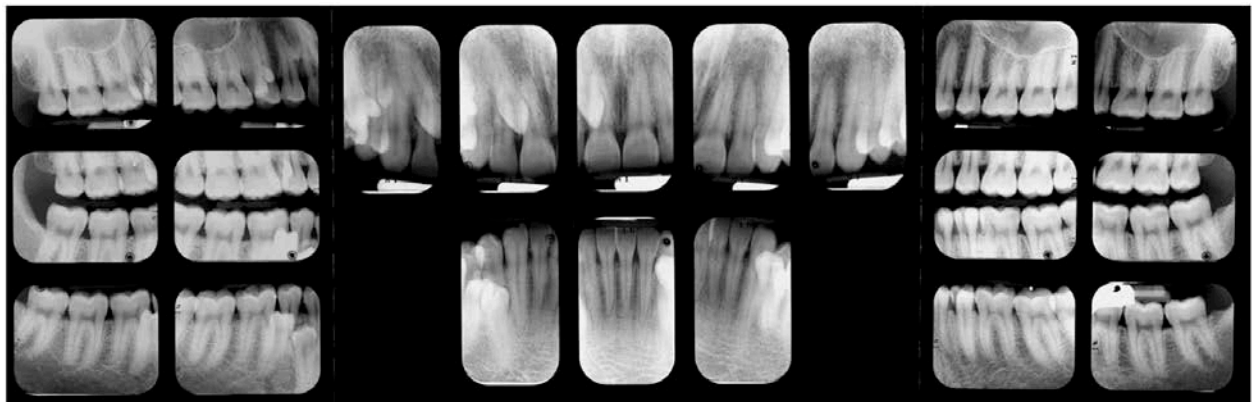


Figure 25. Full mouth radiographic survey of multiple supernumerary teeth. Note the size, shape, and location of the numerous supernumerary teeth.

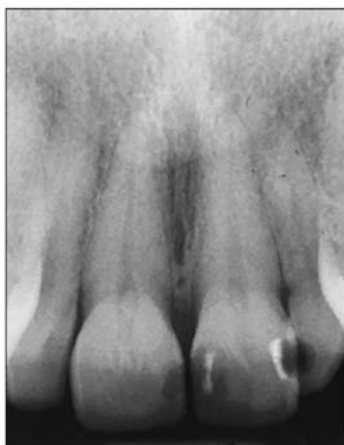

Figure 26. Periapical radiograph of a peg lateral incisors, #7 and #10.

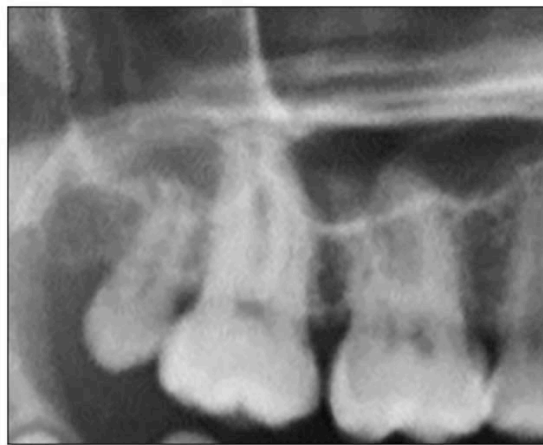

Figure 27. Cropped panoramic image of microdont third molar, #1.

is the most frequently involved and typically demonstrates a peg-shaped crown.^{7,9,10} Microdontia is associated with hypodontia and occurs more frequently in females.⁷ Third molar teeth are often affected by microdontia as seen in Figure 27.⁹ Of note, these same teeth are often congenitally missing.

Macrodontia

Macrodontia is sometimes called megalodontia or megadontia.^{7,9,10} Macrodont teeth appear larger and may be associated with crowding, malocclusion, or impaction.⁹ Often a single tooth or several teeth are involved rather than affecting the entire dentition.⁷ Macrodontia is associated with hyperdontia and occurs more frequently in males.⁷ Macrodontia tends to occur in incisor or canine teeth but may also occur in second premolars and third molars.⁷ Macrodontia terminology should not be applied to teeth that have been altered by gemination or fusion processes which will be discussed next.⁷

Alterations in the Shape of Teeth

There are a number of conditions in which the usual morphology of the tooth is altered, and as a result presents differently both clinically and/or radiographically. These alterations can affect various aspects of the tooth structure and tooth anatomy.

Conjoined Teeth

Conjoined or double teeth can occur through different processes. Traditionally, conjoined teeth fall into three categories: gemination, fusion, and concrescence.⁷ In some cases it is quite difficult to discern the true pathogenesis of the particular anomaly.⁷ Some of the traditionally accepted parameters discussed in the following text do not apply to every occurrence of conjoined teeth.

Gemination

Gemination, or twinning, is a rare abnormality in which a single tooth bud tries to divide.⁹ Partial division may produce a bifid crown (Figure 28) with a shared pulp canal and root.⁹ Complete division, while rare, produces a normal tooth along with a supernumerary tooth (Figure 29).⁹ Gemination usually affects the primary teeth but the permanent dentition

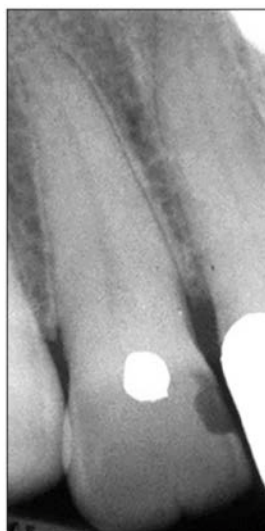


Figure 28. Periapical radiograph of maxillary lateral incisor #7 with coronal cleft.

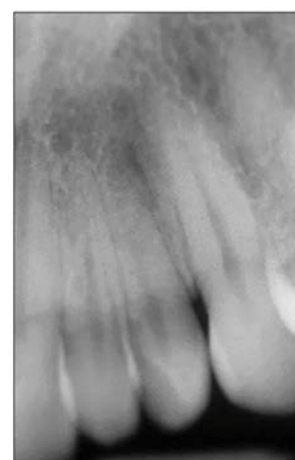


Figure 29. Periapical radiograph of maxillary lateral incisor #10 showing complete division.

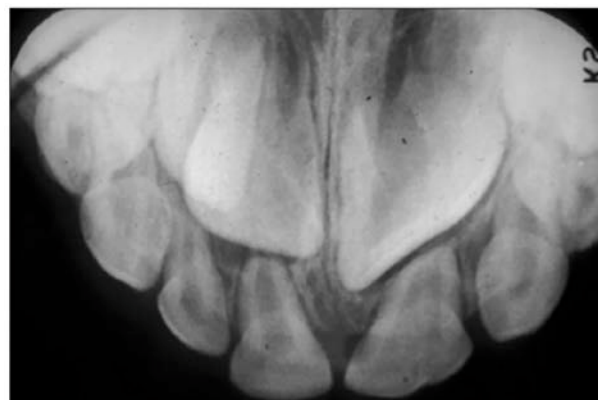

Figure 30. Periapical radiograph of fused primary teeth F & G and permanent teeth #9 & #10. Note the larger fused crown size.

can be involved as well.^{7,9} The incisor region is the most commonly affected area with no apparent gender predilection.⁷ In gemination, the number of teeth is usually normal.¹⁰

Fusion

Fusion is defined as two adjacent tooth buds that join together to form one normal looking tooth or a much larger tooth (Figure 30).^{7,9,10} The degree of union may be total or partial and often presents with a coronal cleft.¹⁰ The normal complement of teeth is reduced by one.^{7,9} Like gemination, fusion is more common in the primary dentition but can

occur in the permanent dentition as well.^{7,9,10} It also leans toward involvement in the anterior region of the dental arch.^{7,9,10} While there is no gender predilection, incidence is higher among Native American, Asian, and other indigenous peoples.^{7,9}

Concrescence

Concrescence is the joining of two completely formed teeth by the cementum along the root surface (Figure 31).^{7,9} It favors posterior teeth and the maxillary arch, often involving a second molar tooth closely approximating the roots of an impacted third molar.⁷ The affected teeth may fail to erupt or only partially erupt.⁹ The cause of this altered morphology is not known.⁹ In instances in which concrescence causes eruption difficulties, surgical extraction may be necessary and result in loss of both teeth.^{9,10}

Talon Cusp

The talon cusp, a supernumerary or accessory cusp, affects maxillary or mandibular incisor teeth.¹⁰ This extra cusp occurs on the cingulum of maxillary lateral incisor teeth, most commonly, followed respectively by maxillary central incisors, mandibular incisors, and maxillary canine teeth.⁷ More common in the permanent dentition, the cusp extends from the lingual aspect of the tooth with a formation that resembles an eagle's talon.¹⁰ Facial talon cusps have been reported but are rare.¹⁰ The cusp is well-formed and extends at least half the distance from the cemento-enamel junction to the incisal edge, often containing a pulpal extension.^{7,10} A deep developmental groove may exist between the talon cusp and the underlying tooth structure.^{7,10} Radiographically, the cusp anatomy will appear superimposed over the other tooth structure components.^{7,10} The pulpal extension, if present, may not be demonstrated radiographically.¹⁰

Talon cusps tend to occur more frequently in Native American, Asian, Inuit and Arab populations with prevalence ranging from 1-8%.^{7,10} This cuspal anomaly can occur in either gender and may present unilaterally or bilaterally.^{7,9} The talon cusp is often associated with other dental anomalies such as supernumerary teeth, impacted teeth and dens invaginatus.^{9,10}

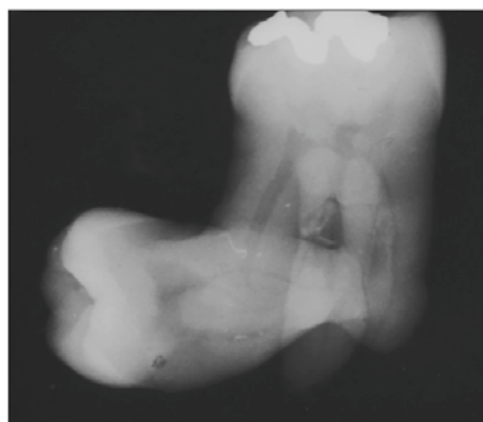

Figure 31. Periapical radiograph depicting molar concrescence.

Dens Evaginatus and Dens Invaginatus

Dens evaginatus is a cusp-like projection of enamel on the tooth crown while dens invaginatus is an inversion or enfolding of enamel into the crown, sometimes extending beyond the CEJ or into the root.^{7,9} Dens evaginatus is usually found in the central groove or on the lingual ridge of the buccal cusp of a molar or premolar tooth.^{7,9} Most often, the mandibular premolar teeth are involved bilaterally.^{7,9} This extra cusp or tubercle is composed of enamel and dentin, and in many instances pulp tissue as well. This particular anomaly occurs in less than 5% of the population, most commonly in Native American, Asian, and aboriginal racial groups.^{7,9} Exposure and necrosis of the pulp can result from cuspal wear or fracture.⁹ As discussed, dens evaginatus is an external outcropping of tooth structure in contrast to dens invaginatus, an internal involution of tooth structure.^{7,9}

Dens invaginatus varies in the degree of tooth structure enfolding. Three types are recognized per Oehlers Classification, the most widely used nomenclature (Table 4).^{10,11} These coronal invaginations usually involve the permanent maxillary lateral incisors but other permanent teeth can be affected including central incisors, premolar, canine, and molar teeth with the maxillary arch more frequently involved than the mandibular arch.^{7,9,10} The least severe form, dens invaginatus, typically involves the cingulum on the lingual surface of the crown of permanent maxillary lateral incisors and

may appear as a small pit (Figure 32).^{7,9} A more severe coronal type of invagination, dens in dente or tooth within a tooth, arises from the incisal edge of the involved tooth (Figure 33).^{7,9} The permanent maxillary lateral incisor teeth are most commonly affected with a tendency for bilateral occurrence.⁹ The most severe form, dilated odontome, involves the tooth root with a doughnut-shaped invaginated defect lined with cementum.^{7,9} Radiographically, the affected tooth is significantly malformed displaying a radiopaque round or oval periphery with a radiolucent center as seen in Figure 34.^{7,9,12} This anomaly is rare and appears to be independent of the traditional classification system outlined in Table 4.¹² The clinical relevance of these defects is the possibility of pulpal involvement and necrosis.^{7,9,10}

Enamel Pearls

Enamel pearls are tiny nodules of ectopic enamel that occur most typically on the root surface of permanent maxillary molar teeth, although mandibular molars can be affected.^{7,10} These projections typically consist of enamel, but dentin and pulp tissue may be present underneath the enamel layer posing a potential

risk for pulp exposure. Radiographically, enamel pearls are singular, well-defined circular radiopacities located near the cervical aspect of the tooth (Figure 35) or in the root furcation area (Figure 36).⁷⁻¹⁰ The prevalence of enamel pearls ranges from \approx 1% to 10% with Asians demonstrating the greatest incidence.^{7,10} In most circumstances, enamel pearls are asymptomatic, but their presence may impact oral hygiene care and periodontal health.^{9,10}

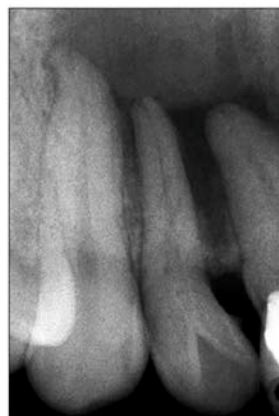

Figure 32. Periapical radiograph of tooth #7 with dens invaginatus Type I.

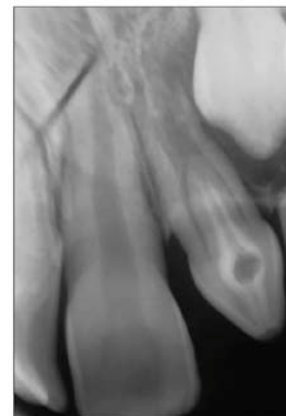

Figure 33. Periapical radiograph of tooth #10 with dens invaginatus Type II.

Table 4. Oehlers Classification.^{10,11}

Type	Description
Type I	Defect is enamel-lined and confined to the tooth crown
Type II	Defect is enamel-lined and extends into the pulp chamber but remains within the root canal
Type III	Defect extends into the tooth root and perforates the root laterally or through the apical foramen (See subtypes A and B)
Type IIIA	Perforates the root laterally with PDLS communication; usually without pulp involvement
Type IIIB	Communicates with the PDLS at the apical foramen; usually without pulp involvement

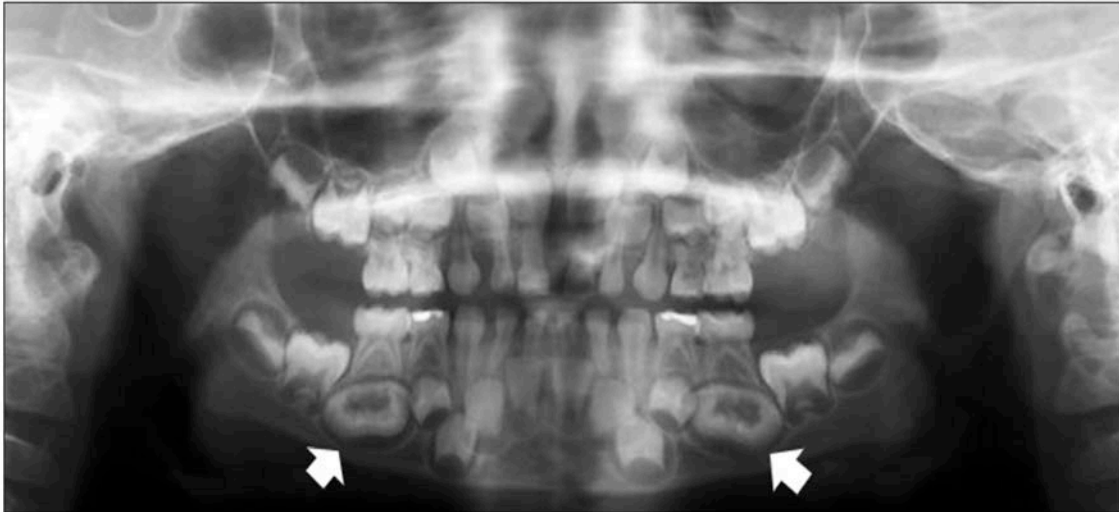

Figure 34. Panoramic radiograph with developing dilated odontomes of mandibular premolar teeth #20 & #29.

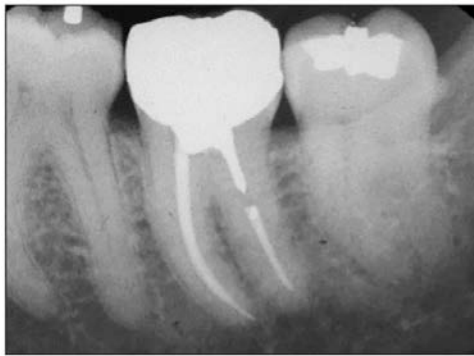

Figure 35. Periapical radiograph of #17 with a distal enamel pearl.

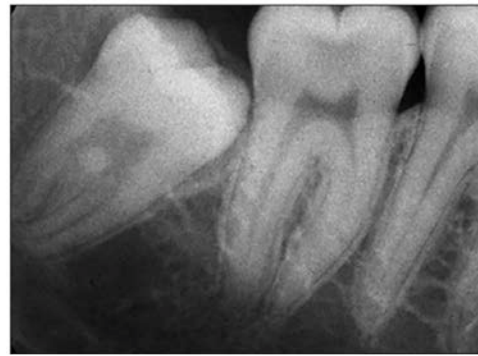

Figure 36. Periapical radiograph of #32 with a furcal enamel pearl.

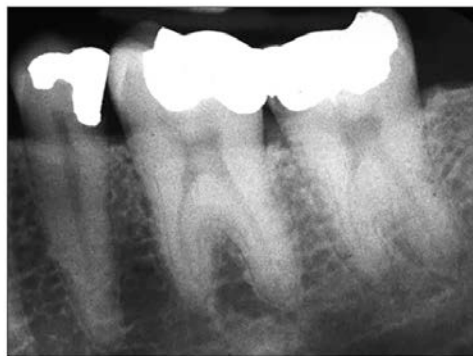

Figure 37. Periapical radiograph of mesotaurodont teeth #18 and #19.

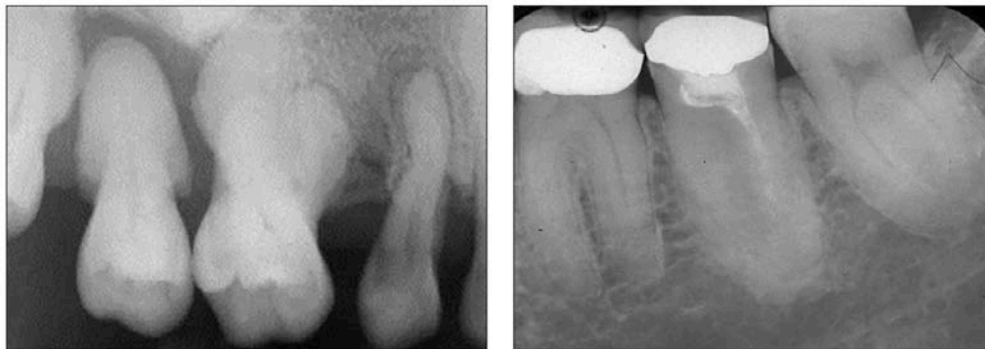Taurodontism

Taurodonts are molar teeth that present unusual tooth morphology, resembling the teeth of bulls (Figure 37).^{10,13,14} This may be a variation of normal tooth formation.

Radiographically, taurodonts display elongated pulp chambers and short stubby roots that look like bull's horns.⁷⁻¹⁰ Table 5 outlines three categories used to classify the severity of the deformity, originally described by Shaw in 1928:

Table 5. Taurodontism Classification.^{7,13,14}

Category	Degree	Description
Hypotaurodontism	Mild	Moderate enlargement of the pulp chamber compared to the roots
Mesotaurodontism	Moderate	Large pulp chamber with short separate roots
Hypertaurodontism	Severe	Pulp chamber nearly reaches root apices before dividing into stubby separate roots

**Figure 38.** Periapical radiographs of several posterior teeth demonstrating hypercementosis.

Hypotaurodontism (Mild), Mesotaurodontism (Moderate), and Hypertaurodontism (Severe).¹³⁻¹⁵ The severity is determined by the increasing apical displacement of the pulpal floor.^{7,13-15} Permanent molar teeth are more frequently involved than primary teeth with either unilateral or bilateral presentation.⁷ The prevalence is variable but approximates 3% of the U.S. population.⁷ Taurodontism is associated with a number of syndromes indicating possible linkage to chromosomal aberrations in tooth development.^{7,13,14}

Hypercementosis

Hypercementosis is overproduction or increased proliferation of cementum on the tooth root (Figure 38). This can result in mild to marked misshaping of the tooth root with a bulbous-like or lobular appearance.^{9,10} The excess cementum will appear slightly less

radiopaque than the dentin with the lamina dura and periodontal ligament space evident around the excess cementum.⁹ Usually the additional cementum demonstrates a smooth outline, but it can also appear irregular.^{9,10} The exact cause is unknown but hypercementosis may be a reaction to inflammation or loss of function of a supraerupted tooth due to absence of an opposing tooth.⁸⁻¹⁰ Hypercementosis is known to be associated with fractured teeth or teeth in heavy occlusion.^{9,10}

Dilaceration

Dilaceration, a disturbance in tooth development, generates a sharp angular bend or distinct curvature in the root (Figures 39-40) or less often, in the crown.⁷⁻¹⁰ While coronal curvatures may be evident clinically, radicular dilacerations are best revealed

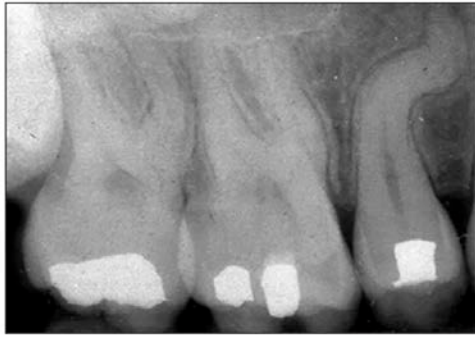

Figure 39. Periapical radiograph of root dilaceration of #4.

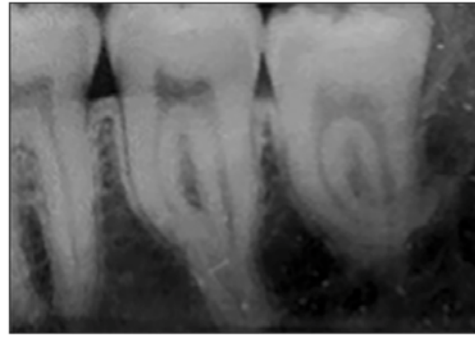


Figure 40. Periapical radiograph of root dilaceration #17 and #18.

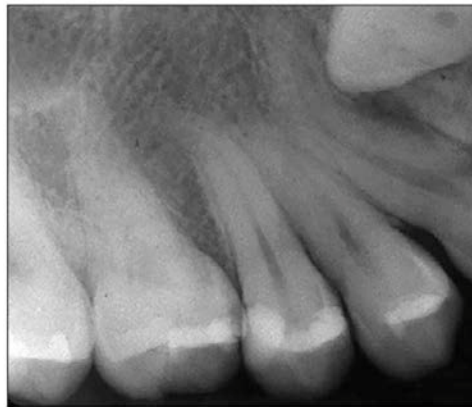


Figure 41. Dilaceration of tooth #6 secondary to impingement of an adjacent impacted tooth.

radiographically. The most commonly involved teeth tend to be mandibular third molars, maxillary second premolars and mandibular second molars with the maxillary premolars demonstrating the greatest incidence.^{7,9,10} Although most cases are idiopathic (without a known cause) in nature, this alteration can occur as a result of trauma.⁷⁻¹⁰ Injury induced dilaceration usually involves anterior teeth or less frequently occurs secondary to impingement of an adjacent anatomic structure or pathologic entity (Figure 41).¹⁰ Usually, dilaceration is not problematic but treatment difficulties may be encountered if endodontic treatment or tooth extraction are necessary.⁷⁻¹⁰

Supernumerary Roots

Similar to supernumerary teeth, an extra root or several more can develop beyond the normal number of root(s) typical for the specific tooth type (Figures 42-43). Whether

primary or permanent, any tooth can form an accessory root.⁷ Third molars are especially prone to supernumerary roots, but the other molars from either arch may be involved as well as mandibular canine and premolar teeth.^{7,10} At times, the extra root is easily seen radiographically while in other instances it may be fused to the other root(s) or so small as not to be visible.^{7,10} Although not typically a problem, the extra root may present a challenge if endodontic treatment or extraction is indicated.^{7,10}

Loss of Tooth Structure

Loss of tooth structure typically occurs through tooth wear, a normal physiological function associated with aging. Wearing of the teeth can be caused by several processes including attrition, abrasion, abfraction, and erosion. These processes are acquired alterations that occur subsequent to tooth development and eruption.

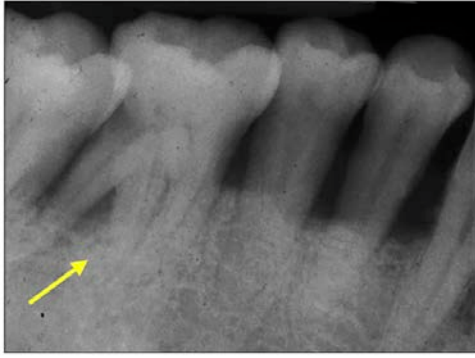

Figure 42. Periapical radiograph of supernumerary tooth root #30.

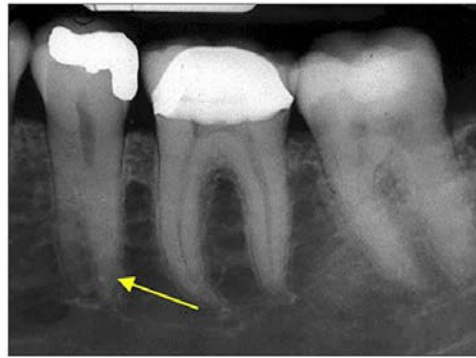

Figure 43. Periapical radiograph of supernumerary tooth root #20.

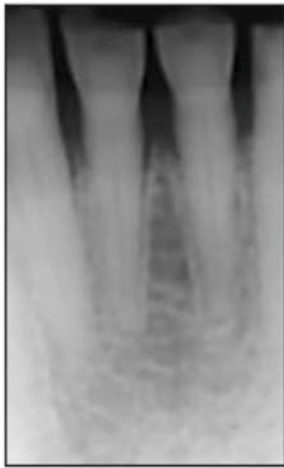

Figure 44. Periapical radiograph of anterior teeth with attrition.

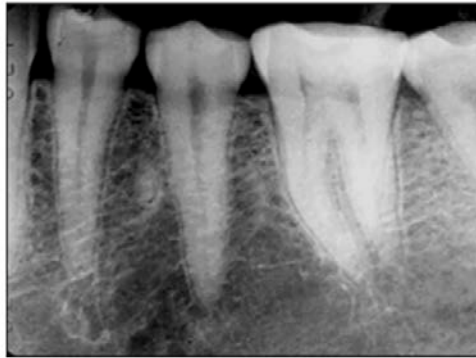

Figure 45. Periapical radiograph of posterior teeth with attrition.

Attrition

Attrition of the tooth structure is the result of tooth-to-tooth contact during mastication and occlusion.^{7,16} This condition affects the incisal and occlusal surfaces of the teeth and can be exacerbated by contact or ingestion of abrasive materials, abrasive foods, and behaviors like teeth grinding or bruxism.^{7,9,16} Attrition is quite prevalent in adults and tends to be more severe in men.⁹ Both clinical and radiographic manifestations can be observed. Clinically, the incisal edges demonstrate broadening and wear facets will be evident on the cusps and ridge anatomy of posterior teeth (Figures 44-45).^{7,9,16} The dentin can become exposed and the wear facets, which appear flat and shiny, can deepen over time, and become stained.⁹

Radiographically, the teeth will appear flattened and shorter coronally with reduction in the size of the pulp chambers and canals due to deposition of secondary dentin.^{9,16} Ultimately, the pulpal structures can become completely obliterated.^{9,16}

Abrasion

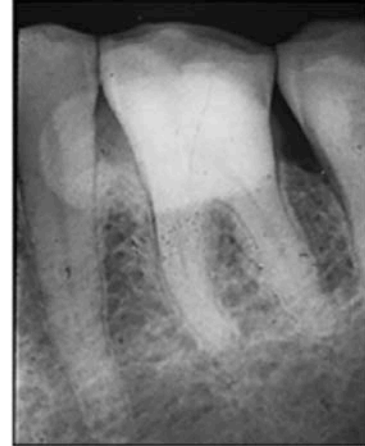
In abrasion, the loss of tooth structure is not from physiologic wear but rather from contact with substances or devices that cause friction.⁹ These frictional forces are often associated with improper toothbrush and flossing habits that wear away the tooth structure.^{7,9,16} Toothbrush abrasion can be the result of vigorous scrub-brushing methods and the use of abrasive toothpastes or powders. The back-and-forth scrubbing action produces V-shaped notches or grooves in the cervical aspect of the tooth buccally near the gingival tissue (Figure 46).⁹ The side of the dentition that is most severely affected is the side opposite the tooth brusher's

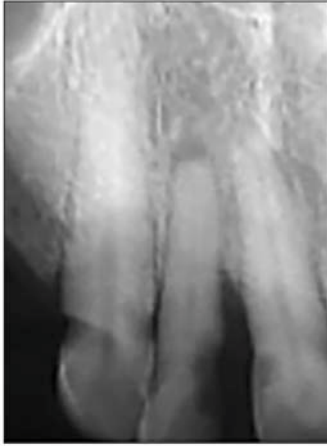

Figure 46. Periapical radiograph of #6 with toothbrush abrasion.

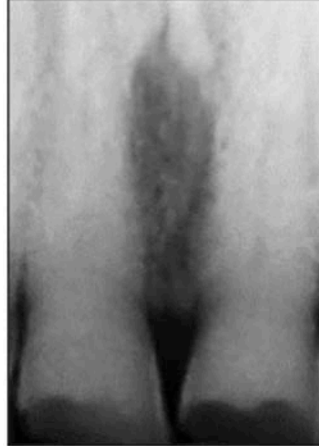

Figure 47. Periapical radiographs demonstrating erosion.



dominant hand.^{7,9,16} In addition, wear can result from incorrect dental floss usage producing interproximal cervical notches or craters, deeper on the distal aspect than the mesial.^{9,16} These areas of reduced tooth structure appear radiolucent on radiographs and may be misinterpreted as cervical or root caries. Parafunctional habits can be causal factors such as improper toothpick usage, hairpin opening, thread-biting, pipe smoking as well as grooves produced by partial denture clasp friction.^{9,16}

Abfraction

Heavy occlusal forces that repetitively flex the tooth structure over time, like bruxism, can cause cervical loss of tooth structure.¹⁶ This process, known as abfraction, produces deep, narrow, wedge-shaped defects on the buccocervical aspect of the teeth.^{7,16} It usually involves a single premolar or molar tooth with the adjacent teeth remaining unaffected.^{7,16} These defects can mimic abrasion, erosion, and cervical caries but solitary tooth involvement and subgingival defect occurrence can help differentiate abfraction from the other entities.¹⁶

Erosion

Erosion is the loss of tooth structure from a non-bacterial, chemical process.^{9,16} Typically, the chemical agent is acid from acid reflux or regurgitation, frequent vomiting (e.g., bulimia-associated), excessive home tooth-whitening, high acidic dietary intake, or occupationally related acid exposure.^{7,16,17} The location and

pattern of erosion is a key to the likely causal agent. Erosion affecting the facial surfaces of the cervical aspect of maxillary anterior teeth often is indicative of dietary acid from habits such as lemon-sucking.¹⁶ Regurgitated acids typically affect the palatal and lingual surfaces of the maxillary anterior teeth and the occlusal surfaces of maxillary and mandibular posterior teeth.^{7,16,17} Clinically, the areas of erosion look smooth and shiny where the enamel has been removed and the dentin is exposed.^{7,9,16,17} However, these exposed areas of dentin can subsequently take-up stain.⁷ Radiographically, these eroded coronal depressions appear radiolucent with smooth margins (Figure 47).

Resorptive Processes

Normal resorptive processes occur to allow the exfoliation of primary teeth in preparation for the eruption of the permanent teeth. However, there are other resorptive processes that can result in the destruction or removal of tooth structure including external resorption, which affects the outer surface of the tooth, and internal resorption, which affects the pulp chamber and canal(s) housed inside the tooth. Some cases may be referred to as idiopathic when no causal factor can be identified for the resorption.

External Resorption

A common entity, external resorption tends to be mild, affects one or more teeth, and usually is only discovered upon radiographic

examination.^{7,9} It most commonly involves the dentin and cementum of the root surfaces of the teeth but the crown of an unerupted tooth (Figure 48) can be affected as well.⁹ In most situations, it does not present any substantial clinical problems. However, 10% of patients demonstrate significant external resorption.⁷ A number of factors are associated with this condition such as excessive mechanical forces, extreme occlusal forces, tooth reimplantation, dental trauma, as well as systemic conditions and pathologic entities.¹⁶ Root resorption may be an aftermath of orthodontic treatment when heavy forces are applied to the teeth, and significant tooth movement is required to correct malocclusion (Figure 49).⁷ A genetic component may be at play in situations in which the resorption is severe.⁷

Internal Resorption

While less common than external resorption, internal resorption can affect both the

primary and permanent teeth.⁹ When internal resorption does occur, usually it is associated with trauma to the tooth and inflammation of the pulp tissues.^{7,9} The resorption involves the pulp chamber or pulp canal and the adjacent dentin, giving rise to an enlarged or expanded pulp structure (Figure 50).^{7,16} The permanent central incisors and the first and second molar teeth are most frequently

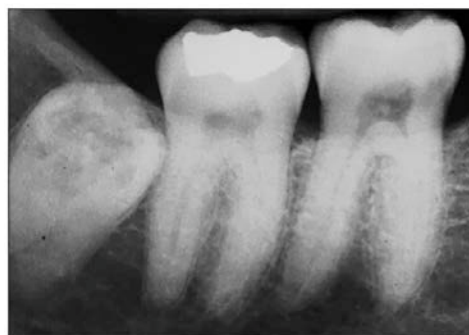

Figure 48. External resorption of impacted molar tooth #32.

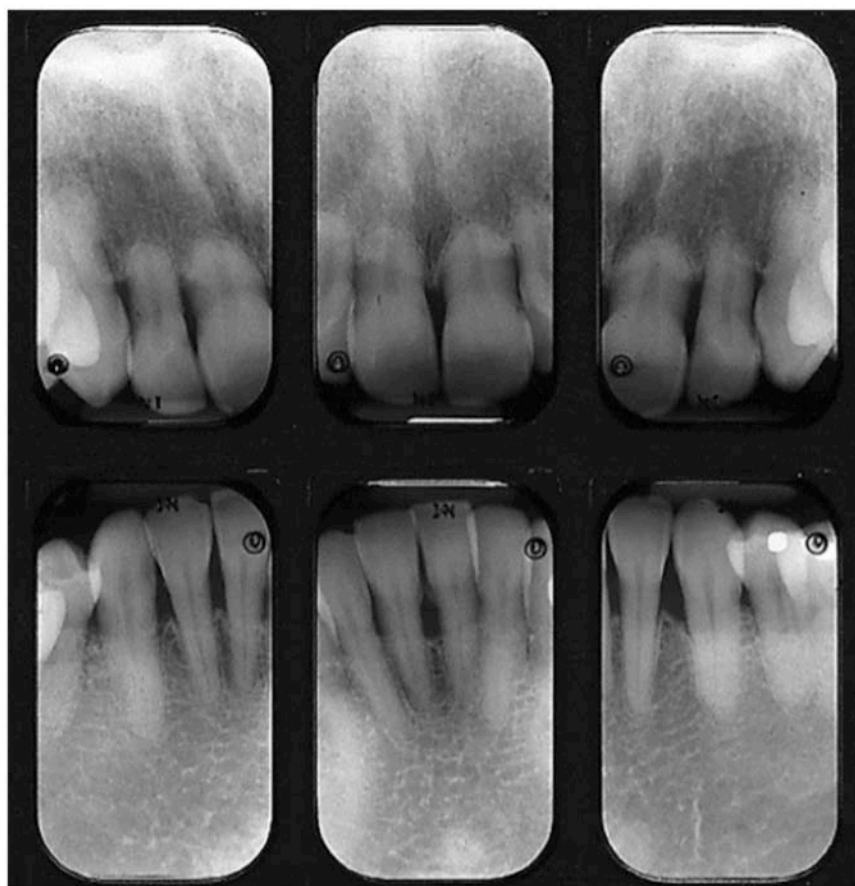

Figure 49. Anterior periapical radiographs of teeth with external resorption, especially severe on the maxilla.

involved.⁹ Typically asymptomatic, internal resorption can illicit pain if the resorption results in major pulpal inflammation. When the resorptive lesion affects the coronal pulp structure, a pink coloration known as the pink tooth of Mummery may be observed clinically.⁷ If the root and pulpal canal are involved and the integrity of the normal canal anatomy is breached, an oval or balloon-shaped radiolucent area of expansion may be visualized radiographically (Figure 51).^{7,16} In severe cases, perforation of the lateral root can occur. If the tooth remains sound, endodontic therapy can be rendered to stop the resorptive process, or in cases of root perforation, surgical endodontic retrofill procedures may be necessary.¹⁶ Ultimately, extraction may be required if the tooth is unrestorable.¹⁶

Dentinal Deposition

Secondary and Tertiary Dentin

Secondary dentin is that which is deposited in the pulp structures. This process occurs after the primary dentin has fully formed, usually as part of aging.⁹ Dentinal deposition can be a response to a variety of conditions such as moderate carious lesions, prolonged tooth trauma, deep restorative treatments, and tooth-wearing processes like attrition (Figure 52), abrasion, and erosion.^{7,9} In such instances, the term tertiary dentin may be applied, suggesting that the additional dentin is deposited in response to conditions unrelated to aging.^{7,9}

Age-related secondary dentin deposition diminishes the size of the pulp chamber, especially the pulp horns early in the process, and the pulp canals.⁹ These changes can be visualized radiographically. This process may eventually result in obliteration of all pulp structures.^{7,9} Tertiary dentinal deposition tends to be a more rapid, localized process by comparison.⁷

Pulpal Calcifications

Several other types of calcifications can affect the pulpal structures of the teeth including pulp stones and pulpal sclerosis. The stones tend to be more localized while pulpal sclerosis is more generalized.

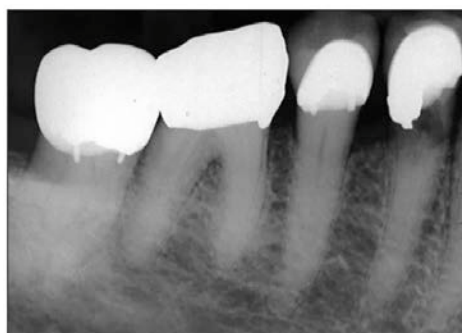

Figure 50. Periapical radiograph showing internal resorption of tooth #28 visible below the restoration.

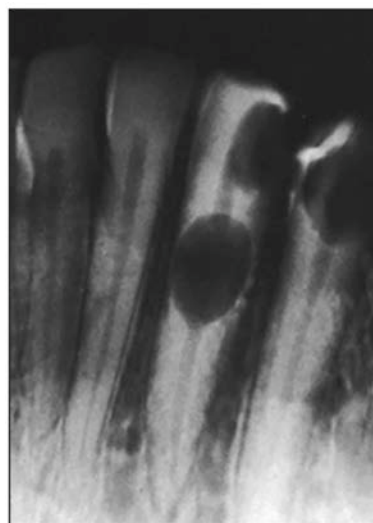


Figure 51. Periapical radiograph demonstrating ballooning of the pulp canal in tooth #22.

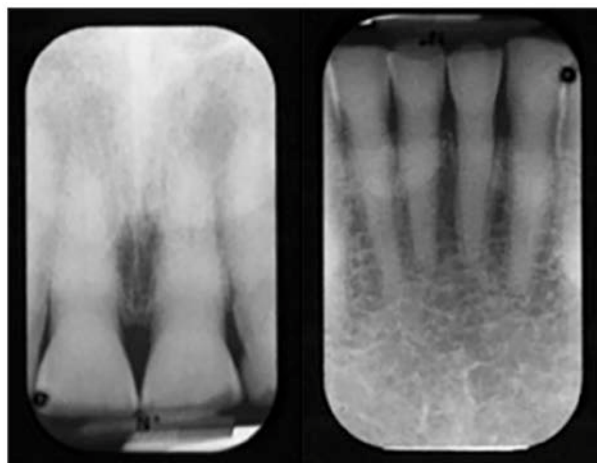


Figure 52. Periapical radiographs showing secondary dentin deposition likely due to attrition.

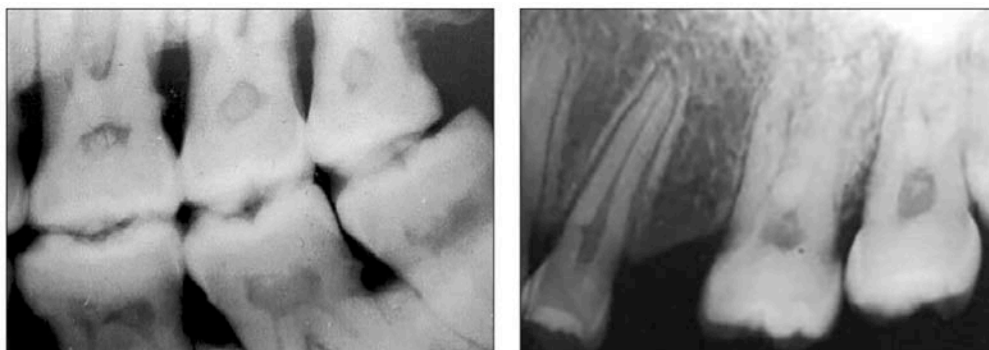

Figure 53. Bitewing and periapical radiographs showing posterior pulp stones of varying sizes.

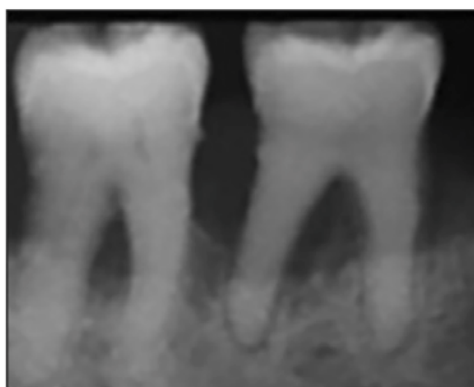


Figure 54. Periapical radiograph of pulp sclerosis with total obliteration of pulp structures #30.

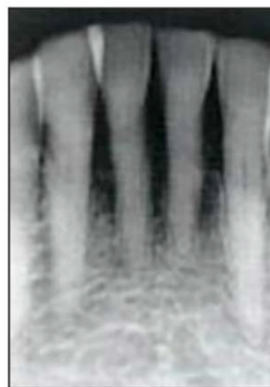

Figure 55. Periapical radiograph of pulp sclerosis in the mandibular anterior teeth.

Pulp Stones

Pulp stones are small focal calcifications that occur within the pulp structures of the teeth. Of unknown origin, pulp stones are rather common and affect the teeth of both the young and old.⁹ Most stones are so tiny that they cannot be seen radiographically, while others are large and calcified enough to be visualized.⁷ Their size, shape, number, and density are variable, and they can be found in every type of tooth, but especially the molars (Figure 53).⁹ No treatment is required.

Pulpal Sclerosis

Another alteration of the pulp structures, sclerotic changes can result in complete obliteration of the pulp chamber and canals (Figures 54-55). Although the etiology is unknown, total obliteration may be a result of trauma to the affected tooth.⁷ The calcifications are diffuse and ill-defined radiographically,

with a strong association with older age.⁹ This process is asymptomatic and requires no treatment. If endodontic therapy is indicated, the calcification may present difficulty in completing the procedure.⁹

Summary

The normal radiographic appearance of the teeth and their supporting structures throughout the various stages of tooth development, eruption, and maturation are important to recognize and understand. This foundational knowledge provides a sound baseline to assist the clinician in identifying and describing deviations from normal. Dental anomalies associated with the eruption, number, size, and shape of the teeth include a variety of entities, some which may have important treatment considerations and implications. Acquired alterations of tooth structure such as attrition, abrasion, abfraction,

and erosion may affect the appearance or function of the teeth. In some cases, clinical intervention will be required to preserve the remaining tooth structure and maintain normal function. This information will facilitate

differentiation between normal and abnormal tooth structure and enhance the ability to recognize and describe various structural anomalies.

Course Test Preview

To receive Continuing Education credit for this course, you must complete the online test. Please go to: www.dentalcare.com/en-us/professional-education/ce-courses/ce651/test

- 1. Which structural component comprises the majority of the tooth?**
 - A. Enamel
 - B. Cementum
 - C. Dentin
 - D. Pulp

- 2. The cancellous bone in the posterior mandible _____.**
 - A. consists of many thin rods and plates of bone
 - B. contains numerous tiny islands of bone marrow
 - C. displays a fine granular appearance radiographically
 - D. has large sparse trabeculae and marrow spaces

- 3. Which phrase best describes the periodontal ligament space?**
 - A. Cushions the tooth via flexible collagen fibers
 - B. Lines the entire periphery of the tooth socket
 - C. Located approximately 0.5 to 2.0 mm from the CEJ
 - D. Visualized as a radiopaque structure on dental images Lines the entire periphery of the tooth socket

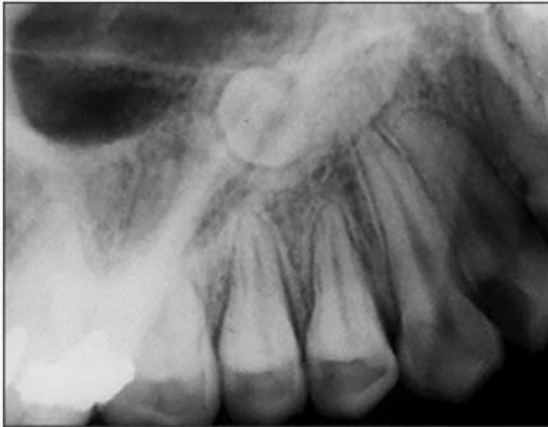- 4. Which primary teeth erupt between nine and thirteen months of age?**
 - A. Mandibular canine teeth
 - B. Mandibular first molars
 - C. Maxillary lateral incisors
 - D. Maxillary second molars

- 5. The permanent maxillary canine teeth erupt _____.**
 - A. after the mandibular canine teeth
 - B. after the maxillary second molars
 - C. before the mandibular first premolars
 - D. before the maxillary lateral incisors

- 6. Which phrase accurately describes tooth eruption?**
 - A. Considered delayed if tooth emergence is 6 months behind
 - B. Continues after tooth emergence to offset masticatory wear
 - C. Not affected by factors such as age, race, gender, or ethnicity
 - D. Occurs once half of the tooth root has formed and calcified

- 7. Which feature is characteristic of tooth ankylosis?**
 - A. Dentinal fusion with the coronal enamel
 - B. Involvement of the permanent dentition
 - C. Occlusal plane submersion of the crown
 - D. Widening of the periodontal ligament space

8. Which term best describes the position angulation of the impacted tooth recorded on this periapical radiograph?



- A. Distoangular
 - B. Inverted
 - C. Mesioangular
 - D. Vertical
9. What is the definition of the term anodontia?
- A. Absence of the third molars
 - B. Lack of tooth development
 - C. One or more missing teeth
 - D. Six or more missing teeth
10. Which is the most common type of supernumerary tooth?
- A. Distodens
 - B. Distomolar
 - C. Mesiodens
 - D. Paramolar
11. Which phrase is most closely associated with microdontia?
- A. Frequently associated with hyperdontia
 - B. Linked to teeth crowding and malocclusion
 - C. Tendency for occurrence in the male gender
 - D. Usually involves the maxillary lateral incisor
12. Gemination is an anomaly in which _____.
- A. a single tooth tries to divide into two
 - B. a tooth forms larger than normal size
 - C. two adjacent teeth join to form one tooth
 - D. two separate teeth fuse along the root
13. Each phrase is consistent with dens evaginatus EXCEPT one. Which is this EXCEPTION?
- A. Coronal cusp-like projection of enamel
 - B. Mandibular premolar teeth most affected
 - C. Produces an involution of tooth structure
 - D. Found commonly in aboriginal racial groups

14. According to Oehlers Classification, the most severe form of dens invaginatus involves the _____.
A. crown cingulum
B. incisal edge
C. pulp chamber
D. tooth root
15. Which phrase accurately describes taurodontism?
A. Demonstrates elongated pulp chamber anatomy
B. Greatest incidence is among Asian populations
C. Is frequently associated with fractured molar teeth
D. Tendency toward a female gender predilection
16. Hypercementosis is characterized by _____.
A. Innumerable tiny nobs of cementum
B. Lobular, misshaped root anatomy
C. Outcroppings of secondary dentin
D. Short stubby root configuration
17. Of the teeth listed, which is most frequently affected by root dilaceration?
A. Mandibular canine teeth
B. Mandibular first molars
C. Maxillary second premolars
D. Maxillary third molar teeth
18. What causes abfraction of the tooth structure?
A. Chemical agent exposure
B. Friction-induced wearing
C. Heavy occlusal forces
D. Tooth-to-tooth contact
19. Which of the following is NOT associated with External Resorption?
A. Linked to excessive mechanical forces
B. Produces a distinct tooth discoloration
C. Root dentin and cementum are affected
D. Usually involves more than one tooth
20. Which feature is characteristic of pulp stones?
A. Affected teeth have a long trauma history
B. Correlated strongly with increased age
C. Pulp chamber is diminished in overall size
D. Focal calcifications within chambers/canals

References

1. Tamimi D. Part I: Anatomy, Section 1: Oral Cavity - Teeth. In: Diagnostic Imaging: Oral and Maxillofacial, 2nd ed. Koenig LJ, Tamimi DF, Petroski CG, Perschbacher SE (Eds.). Salt Lake City, UT. Elsevier. 2017.
2. White SC, Pharoah MJ. Oral radiology: Principles and interpretation, 7th ed. St. Louis, MO. Elsevier/Mosby. 2014.
3. Williamson GF, Parks ET. Radiographic Evaluation. In: Hall's Critical Decisions in Periodontology & Dental Implantology, 5th ed. Harpenau LA, Kao RT, Lundergan WP, Sanz M (Eds.). Shelton, CT. People's Medical Publishing House-USA. 2013.
4. Perschbacher S. Periodontal Diseases. In: Oral radiology: Principles and interpretation, 7th ed. White SC, Pharoah MJ (Eds.). St. Louis, MO. Elsevier/Mosby. 2014.
5. Iannucci JM, Howerton LJ. Dental Radiography: Principles and Techniques, 4th ed. St. Louis, MO. Elsevier Saunders. 2012.
6. ADA. Mouth Healthy. Eruption Charts. Accessed June 14, 2021.
7. Neville BW, Damm DD, Allen CM, Chi AC. Oral and Maxillofacial Pathology, 4th ed. St. Louis, MO. Elsevier. 2016.
8. Miles DA, Van Dis ML, Williamson GF, Jensen CW. Radiographic Imaging for the Dental Team, 4th ed. St. Louis, MO. Elsevier Saunders. 2009.
9. Lam EWN. Dental Anomalies. In: Oral radiology: Principles and interpretation, 7th ed. White SC, Pharoah MJ (Eds.). St. Louis, MO. Elsevier/Mosby. 2014.
10. Potter BJ, Van Dis ML. Part II: Diagnosis, Section 1: Teeth – Developmental Alterations in Size and Shape of Teeth. In: Diagnostic Imaging: Oral and Maxillofacial, 2nd ed. Koenig LJ, Tamimi DF, Petroski CG, Perschbacher SE (Eds.). Salt Lake City, UT. Elsevier. 2017.
11. Thakur S, Thakur NS, Bramta M, Gupta M. Dens invagination: A review of literature and report of two cases. J Nat Sci Biol Med. 2014 Jan;5(1):218-21. doi: 10.4103/0976-9668.127341.
12. Galvez P, Garot E, Bres A, et al. Dilated Odontoma: an unusual case report literature review. J Oral Med Oral Surg 2021;27(2):24. doi: 10.1051/mbcb/2020067. Accessed June 14, 2021.
13. Jafarzadeh H, Azarpazhooh A, Mayhall JT. Taurodontism: a review of the condition and endodontic treatment challenges. Int Endod J. 2008 May;41(5):375-88. doi: 10.1111/j.1365-2591.2008.01388.x. Epub 2008 Mar 21.
14. Dineshshankar J, Sivakumar M, Balasubramaniam AM, Kesavan G, Karthikeyan M, Prasad VS. Taurodontism. J Pharm Bioallied Sci. 2014 Jul;6(Suppl 1):S13-5. doi: 10.4103/0975-7406.137252.
15. Shaw JC. Taurodont Teeth in South African Races. J Anat. 1928 Jul;62(Pt 4):476-498.1.
16. Tamimi D. Part II: Diagnosis, Section 1: Teeth – Acquired Alterations of Teeth and Supporting Structures. In: Diagnostic Imaging: Oral and Maxillofacial, 2nd ed. Koenig LJ, Tamimi DF, Petroski CG, Perschbacher SE (Eds.). Salt Lake City, UT. Elsevier. 2017.
17. Fehrenbacher JE, Reddington AR. Oral implications of gastroesophageal and laryngopharyngeal reflux diseases. Dimensions of Dental Hygiene. 2020;18(11):26-31. Accessed June 14, 2021.

Additional Resources

- No Additional Resources Available

About the Author

Gail F. Williamson, Professor Emerita



Gail F. Williamson is Professor Emerita of Dental Diagnostic Sciences, Department of Oral Pathology, Medicine and Radiology at Indiana University School of Dentistry in Indianapolis, Indiana. Prof. Williamson has received numerous awards for teaching excellence during her academic career including the 2013 Outstanding Teacher of the Year Award from the Indiana University School of Dentistry and the 2018 Gordon J. Christensen Lecturer Recognition Award from the Chicago Dental Society. She is a co-author of several Radiology textbooks and author/co-author of multiple book chapters, journal articles and continuing education monographs. She has held numerous positions in several professional organizations including the American Academy of Oral and Maxillofacial Radiology and the American Association of Dental Schools. She presents continuing education courses on topics in oral and maxillofacial radiology nationally.

Email: gwilliam@iu.edu