

## The Intraoral and Extraoral Exam



**Course Author(s):** Nancy W. Burkhart, EdD, MEd, BSDH, AFAAOM, IFDH

**CE Credits:** 3 hours

**Intended Audience:** Dentists, Dental Hygienists, Dental Assistants, Dental Students, Dental Hygiene Students, Dental Assistant Students

**Date Course Online:** 02/20/2009

**Last Revision Date:** 03/31/2025

**Course Expiration Date:** 03/30/2028

**Cost:** Free

**Method:** Self-instructional

**AGD Subject Code(s):** 730

**Online Course:** [www.dentalcare.com/en-us/ce-courses/ce337](http://www.dentalcare.com/en-us/ce-courses/ce337)

### Disclaimers:

- P&G is providing these resource materials to dental professionals. We do not own this content nor are we responsible for any material herein.
- Participants must always be aware of the hazards of using limited knowledge in integrating new techniques or procedures into their practice. Only sound evidence-based dentistry should be used in patient therapy.

### Conflict of Interest Disclosure Statement

- Dr. Burkhart reports no conflicts of interest associated with this course. She has no relevant financial relationships to disclose.

### Short Description

The Intraoral and Extraoral Exam is a free dental continuing education course that covers a wide range of topics relevant to the oral healthcare professional community.

## Course Contents

- Overview
- Learning Objectives
- Background
- Introduction and Statistics
- The General Physical Appraisal
- The Head and Neck Examination
  - Symmetry and Profile
  - Cutaneous Area
  - Lips
  - Eyes
  - Lymph Nodes
  - Salivary Glands
  - Thyroid Gland
  - Temporomandibular Joint Evaluation
- The Intraoral Examination
  - Oropharynx
  - Posterior Pharyngeal Wall
  - Anterior and Posterior Pharyngeal Pillars
  - Tonsillar Crypt
  - Soft Palate and Uvula
  - Hard Palate
  - Buccal Mucosa
  - Labial Mucosa
  - Mandible
  - Floor of the Mouth
  - Tongue
  - Attached Gingiva
  - Salivary Flow and Consistency
  - Adjuncts for the Oral Cancer Screening
    - Vital Tissue Staining-Toluidine Blue Staining
    - Liquid-Based Cytology
    - OralCDx® Brush Test CDx Diagnostics
    - Direct Autofluorescence Visualization Technology
    - Salivary Test SaliMark™
    - Radiographs and Oral Photography
- Conclusion
- Appendix A. Your Oral Cancer Examination
- Appendix B. Oral Cancer Examination Physician Referral
- Appendix C. Oral Pathologist/Oral Surgeon Referral Form
- Course Test
- References
- About the Authors

## Overview

The purpose of this course is to introduce the protocol for a complete oral cancer examination with proper techniques for both the head and neck and intraoral examinations; to pro-

vide patient education information; to provide information on adjunct technologies that may be utilized in lesion detection and; to promote informing all patients that they are receiving a complete oral cancer examination.

## Learning Objectives

**Upon completion of this course, the dental professional should be able to:**

- State eight objectives of the intraoral and head and neck examinations.
- List the sequence of performing a total oral cancer examination.
- List prime areas for the development of oral cancer.
- Describe four adjunct tests or devices and procedures that may be performed in conjunction with the oral cancer examination.
- Discuss reasons for using an adjunct device when performing an oral cancer examination.
- List five descriptors important for accurately documenting oral lesions.
- List four risk factors for the development of oral cancer.
- Define the term “professional delay.”
- Identify and define the three general classification categories most examination findings can be placed into.

## Background

In 2024, an estimated 396,937 People were living with oral cavity cancer in the United States. The National Cancer Institute (SEER) 2024 reports an estimate of new cases of oral cavity and pharyngeal cancers to be 54,450 which is 2% of all new cancer cases. This amounts to 12,230 of estimated deaths and 2% of all cancer deaths. SEER data suggests that 64.8% of patients will survive more than 5 years. Men are two times more likely to develop oral cancer. The average age or risk factor is 66 and over — with only 20% under 55 years old. White males are more likely to develop cancer followed by black males and Hispanic males. The tongue is the most prominent area followed by the tonsils, oropharynx, gums and floor of the mouth.<sup>1,3</sup>

Cancer of the Lung and bronchus is responsible for most full-body cancer deaths with 131,880 people expected to die from these cancers. Colon and rectal cancer is the second most commonly occurring cancer. The oral exam is extremely important in early oral cancer

detection, but it is also invaluable in detecting other cancers that may occur elsewhere in the body and may also exhibit signs within the oral tissues. Estimates of new cancers in 2024 from the National Cancer Institute is 2,001,140 with an estimated death of 611,720. The five-year survival rate is 69%. 39.3% men and women will be diagnosed with cancer during their lifetime. Very similar data is reported from the American Cancer Society for 2025: 2,041,910 new cancer cases with 618,120 cancer deaths in the United States.<sup>6</sup>

The increase in incidence of oropharyngeal cancer in white males is due to an increase in cancers at the base of the tongue and tonsils associated with human papillomavirus (HPV) infections.<sup>1</sup> It is expected that the rate of HPV infections for both male and females will decrease in the future with the new vaccines that are available currently. Head and neck cancers rank 8th in cancers worldwide with an annual incidence rate of 600,000 individuals.<sup>46</sup> Studies have shown that visual and tactile examination of the structures of the head, neck and oral cavity are effective in detecting abnormalities occurring within these structures. Therefore, procedures such as the head and neck and intraoral examinations, often referred to as an oral cancer examination or oral cancer screening, are important elements of a complete patient assessment. These examinations should be performed on a routine basis who presents for a yearly dental exam, not just new patients or those with known risk factors such as the use of tobacco or alcohol, increasing age, or + HPV status.

Current SEER data indicates that over the last ten years, cancer rates in general have decreased. This is attributed to new testing technology, patient awareness, early intervention and a focus on life-style interventions. Only 5% of cancers are due to hereditary factors.<sup>2</sup> Cancers detected at Stage 1 or Stage 2 have an 80% chance of being cured, cancer detected at Stage 3 or 4 have an 80% chance that you will not like the outcome. When detected early, the survival rate is 90%; but sadly 80% of cancer is detected late and at stage 3 or 4. There is also a cost benefit to early detection. A late-stage renal cancer

treatment can run into the millions of dollars. If an early diagnosis had been found, the person would have paid about 10,000 dollars for a surgical intervention with a positive outcome. Another example is colorectal cancer that is localized at stage 1, has a five-year survival rate of almost 100% but when it has spread, the rate is 14%. Early detection and treatment normally results in less surgery, less radiation and chemotherapy, and a better quality of life for the patient long-term. Treatment for oral, oropharyngeal and other head and neck cancers diagnosed at later stages is usually associated with more extensive dysfunction and disfigurement than treatment for those same cancers diagnosed in earlier stages. Complications associated with therapy for oral, oropharyngeal and other head and neck cancers include: altered eating and swallowing patterns, salivary gland dysfunction (often total loss of the salivary glands), and loss of hard and soft oral tissues such as teeth, bone, and parts of the tongue, among others. Recent SEER data reports an increase in detection of cancers in the posterior tongue region (Oral Pharyngeal Cancer). The estimate for new United States cases of oral cancer in 2024 is 54,450 with 12,230 deaths. This represents 2.9% of all cancer deaths. With more knowledge by dental professionals, more cancers are being identified and treated early.<sup>3</sup>

In a 2010 study, Rethman et al. reported there was sufficient evidence-based information to support oral cancer screening by visual and tactile methods as a means to detect cancer in the early stages.<sup>4</sup> The report further stated that adjunctive screening devices were no more effective in early detection than a thorough visual and tactile exam. In 2009 Watson et al. looked at a group of patients already diagnosed with oral or pharyngeal cancer to determine if oral/pharyngeal cancer screening examinations conducted in the general dental office were associated with early detection. The researchers found those patients who had a screening examination within the last year were significantly more likely to have an early stage cancer than those who did not have the examination.<sup>4</sup> Oral exams and screenings continue to be an intricate part of the dental appointment. Recent studies conducted by the

US Preventive Services Task Force evaluated the screening and preventive interventions for oral health in children and adolescents aged 5 to 17 years old. The researchers concluded insufficient evidence (assigning an “I” statement score) exists to assess the balance of benefits and harms of routine screening for oral health conditions when performed by primary care clinicians in asymptomatic children and adolescents in this age group. They suggest that further research should be conducted.<sup>5</sup>

Some screenings in years past, have been performed by non-dental or medical providers. Recently in 2020, Otolaryngologists have reported screening of the oral tissues and oropharyngeal areas within community screenings. The screening of 285 patients resulted in referrals to dental, ENT and Primary Physician follow ups. They suggested opportunities for collaborative efforts with other professions.<sup>7</sup> This is especially important because of the involvement of HPV in increased oral cancer cases. The ACS and the American Dental Association among others continue to recommend oral cancer examinations as a vital element of routine dental examinations.<sup>8,9</sup>

The length of time between a patient’s initial consultation with a healthcare provider and a diagnosis of cancer is termed “professional delay.”<sup>10</sup> Professional delay may be caused by inadequate clinical skills and knowledge, a low threshold of suspicion, lack of experience, and the presence of non-specific signs/symptoms. Studies by Yu found a delay of as much as 6 months, much longer than expected, from the time of the initial examination to the diagnosis/treatment.<sup>11</sup> In addition to professional delay, patients may delay seeking care themselves for many reasons. A study by Zhang, et al. 2019 listed males, farmers and current smokers as most likely to delay seeing a dental professional. Some common reasons listed for patient delay in seeking treatment are: lack of knowledge of the signs and symptoms of oral cancer leading to a low level of suspicion, no pain, and fear of the dentist.<sup>12,13</sup> Cancer progression is relatively rapid in the oral tissues, and as one would expect, professional and or patient delay results in more late stage diagnoses, more extensive surgery and more radiation and chemotherapy for the patient.

A complete head/neck and intraoral examination is not only important for the early detection of cancer but also for accomplishing a comprehensive assessment of the patient prior to providing dental treatment (Table 1).

**Box 1. Best management practices for the disposal of mercury-containing scrap amalgam.**<sup>19,20</sup>

- Stock pre-capsulated amalgam alloys in a variety of sizes instead of bulk elemental mercury to minimize the amount of hazardous mercury-containing amalgam waste generated.
- Collect and store used disposable amalgam capsules in a wide-mouthed, airtight container labeled “Hazardous Waste - Amalgam Capsules.”
  - Once the container is full, have an approved hazardous waste transporter deliver it to an approved hazardous waste management facility.
  - DO NOT PLACE AMALGAM CAPSULES IN NON-HAZARDOUS OFFICE WASTE OR REGULATED MEDICAL WASTE CONTAINERS.
- Use chairside disposable or reusable traps, vacuum pump filters and an ISO 11143-compliant amalgam separator to capture amalgam particles generated when removing old or carving new amalgam restorations.
  - Chairside trap – when the trap is full, remove trap according to manufacturer’s recommendations. If reusable, clean according to manufacturer’s recommendations. Place contents and any disposable traps in a wide-mouthed, airtight container labeled “Hazardous Waste – Scrap Amalgam.”
  - Once the container is full, have an approved hazardous waste transporter deliver it to an approved hazardous waste management facility. a. DO NOT RINSE DISPOSABLE CHAIRSIDE TRAPS THAT CONTAIN AMALGAM PARTICLES IN THE SINK. b. DO NOT TROW DISPOSABLE CHAIRSIDE TRAPS THAT CONTAIN AMALGAM PARTICLES

IN NON-HAZARDOUS OFFICE WASTE OR REGULATED MEDICAL WASTE CONTAINERS.

- Vacuum pump filter – change filter according to manufacturer’s recommendations, put the lid on the filter and place it in the box in which it was originally shipped. Once the box is full, have an approved hazardous waste transporter deliver it to an approved hazardous waste management facility.
  - DO NOT RINSE VACUUM PUMP FILTERS THAT CONTAIN AMALGAM PARTICLES IN THE SINK.
  - DO NOT TROW DISPOSABLE VACUUM PUMP FILTERS THAT CONTAIN AMALGAM IN NON-HAZARDOUS OFFICE WASTE OR REGULATED MEDICAL WASTE CONTAINERS.
- Amalgam separators -- Follow manufacturer’s recommendations for maintenance and recycling procedures.

The head and neck examination is often overlooked by busy clinicians, but it is as crucial an element of the total cancer examination. A thorough head and neck examination is essential for detecting early skin cancers and enlarged lymph nodes that may indicate cancer metastasis. In addition to cancer, manifestations of systemic disease may be observed during routine dental and oral cancer examinations. With the baby boomers in retirement age, the number of patients with chronic disease continues to increase. By 2040 about 22% of all Americans, more than 82 million people, will be older than 65 years old.<sup>15</sup> The knowledgeable dental professional will be able to identify suspicious manifestations and arrange the appropriate referral for evaluation, and follow-up. Although oral cancer is a disease associated with aging, we have seen a continuing increase of oral cancer diagnoses in patients under age 40 with no known risk factors; HPV 16 included in this age group is a significant increase in cancer of the tongue.<sup>17</sup> Current research implicates the human papillomavirus (HPV) as the underlying cause of as many as 72 percent of oropharyngeal squamous cell carcinomas with a predominate increase seen in younger white men.<sup>18</sup> Persistent HPV infections are

the leading cause of oral pharyngeal cancers, specifically HPV 16 and 18 that are classified as high oncogenic/high risk types.<sup>43</sup> Practitioners who focus on patients at high risk may miss subtle changes in those patients who have no known risk factors or those who do not fit the perceived profile of oral cancer susceptibility such as those who have not smoked or consumed alcohol. With increases of oral cancer in younger age groups, all patients, regardless of age or presence of risk factors, should be examined for oral cancer. In general, cancer in younger populations tends to be much more aggressive and have a poorer prognosis.<sup>27</sup> In a study by Rowan, et al. 2015, participants consisting of dental hygienists and dentists reported that only 73% of respondents included the oropharynx in their oral exam. Less than 50% reported the correct location for the greatest increase in cancer with 40% of all groups indicating that a biopsy from the posterior oropharynx should be tested for HPV.<sup>42</sup> The authors recommend continued education on HPV and oral cancer. In an educational intervention by Shukla et al. 2018, the authors provided a toolkit and a post intervention survey. The researchers concluded that over 91.6% of participants increased their knowledge about HPV. They concluded that the educational process gave participants an opportunity to talk to their patients about HPV and also the HPV vaccination and prevention of the virus.<sup>42</sup> There is also a rise in thyroid cancer with an estimated 2,170 deaths in 2024. This is 2.2% of all new cancer cases. The total number of new cases is 44,020 according to the National Cancer Institute. The thyroid exam is an integral part of the total oral cancer examination.<sup>42</sup>

The purpose of this course is multifold:

1. to introduce the protocol for a complete oral cancer examination with proper techniques for both the head and neck and intraoral examinations,
2. to provide patient education information,
3. to provide information on adjunct technologies that may be utilized in lesion detection and,
4. to promote informing all patients that they are receiving a complete oral cancer examination.

## Introduction and Statistics

The National Health and Nutrition Examination Survey (NHANES) for 1997 through 2013, found that approximately 66.2 percent of persons age 2 years and older had seen a dentist during the previous year.<sup>19</sup> While not one hundred percent, sixty-six percent of the population is a significant number of individuals who present at a dental office at least one time per year. Is the dental community providing appropriate oral cancer examinations to these individuals? The American Cancer Society, based on SEER data, predicts that there will be in 2023 54,540 oral pharyngeal cancers, with 11,580 deaths and a five-year survival rate of 50% of oral cancers detected in the population. With the rise we have seen in cancer of the pharynx and thyroid, patient education and close observation is warranted.<sup>20</sup> The National Cancer Institute reports that 70% of oropharyngeal cancers are HPV related.

Although, the public has become more informed about oral cancer in the last decade, the oral cancer exam is not being performed as often as it should be in many cases. The 2020 issues with COVID have caused delayed dental visits, decreased time spent in the dental office and there has been less of an emphasis on the exam probably because of limited appointment time. One of the goals specified in Healthy People 2020 was to have 20% of the adult population receive an oral cancer screening examination within the past year. By 2008 only 18% of the population had received this examination.<sup>20</sup> Healthy People 2020 reemphasizes the objective to "Increase the proportion of adults who receive an oral and pharyngeal cancer screening from a dentist or dental hygienist in the past year."<sup>22</sup> Studies have found that dental hygienists did not consistently provide oral cancer screening examinations for their patients even though most of them knew it should be done.<sup>2</sup> In one study less than 25% of hygienists stated they performed the examination at the initial appointment with less than 50% reporting they performed the procedure at recall appointments and almost all reported they did not perform extraoral palpation of nodes and other structures.<sup>21</sup>

The top reasons for not performing this vital service were 1) the dentist does it, 2) it takes too much time, and 3) they did not feel adequately trained.<sup>21,22,23</sup> In March 2004, Case Western Reserve University's School of Dental Medicine presented the results of a similar survey to the annual research meeting of the American Dental Education Association. They reported that although hygienists placed a high value on oral cancer screening, only 53% actually did the examinations on their patients. A recent study by Tax, et al.(2017) in a cross sectional study investigated whether dental hygienists in Nova Scotia were transferring their knowledge of oral cancer screening into their practice. Although they perceived themselves as knowledgeable, only a small percentage (7%) were performing a comprehensive intra-oral examination. The perceived barriers were: lack of time, the dentists performs the exam and patient compliance. The authors point out that Canada requires hygienists to perform tactile and visual examinations in practice and it is a comprehensive competency requirement for licensure. Studies by Pavao Spaulonci et al. 2018, reported on the knowledge level of newly graduated dentists compared to more senior level dentists on oral cancer knowledge recently in a study conducted in Brazil. The findings indicated that newer graduates exhibited more comprehensive knowledge about oral cancer than their senior colleagues. The junior clinicians appeared to refer suspicious lesions to a dental school for evaluation rather than the senior clinicians. The authors suggest that more continuing education in oral cancer education is warranted.<sup>21,22,23</sup> A recent study in the British Dental Journal found hygiene-therapists/hygienists to be just as competent as primary care dentists when differentiating between oral cancer, potentially malignant disorders and benign lesions.<sup>26</sup> Several studies support findings indicating that oral exams are either not performed or poorly performed even when the practitioner is educated or informed. Recent studies by Daley, et al. indicate that dental hygienists had lower knowledge about HPV induced cancer outcomes and that dental providers in general did not discuss HPV prevention with

their patients.<sup>27</sup> A 2007 study found that 92 percent of Illinois dentists reported providing oral cancer screening examinations, but many were not being performed correctly or at the appropriate intervals.<sup>28</sup> Additional studies support findings indicating that only 14 percent of dentists perform all aspects of the intraoral and extraoral examinations.<sup>29</sup> In 2022, the COVID crises has limited the number of patients seeking dental care and this has been especially true with those patients who are deemed “high risk” such as the elderly. As we know, the aging population may also be at a greater risk for oral cancer. However, recent data suggests that we are seeing more cancer in individuals who are younger diagnosed with breast and colon cancers.<sup>42</sup>

Public ignorance of oral cancer, its symptoms and risk factors and how it can be detected early does not help the situation. For example, many patients are unaware they have had an oral cancer examination even when one has been completed because the practitioner may not inform them that the procedure has been performed.<sup>23</sup> Studies by Patton et al. 2004,<sup>30</sup> found that 29% of a North Carolina population consisting of 1,096 respondents reported having had an oral cancer screening examination only after the procedure was described to them. A study by Kerr, et al. (2020) assessed the clinical decisions of a group of dentists. The cohort were 228 dentists with a mean age of 52 with practice times of 38 hours per week. 130 out of 228 used cues of color and location in their assessment. In malignancy, the crucial cues are palpable induration, deep ulceration, exophytic components and pain. The crucial cues were used the least amount by this study group. The conclusion of the study reported that 58% of the dentist did not equate pain with malignancy and 40% had no decision making policy of assigning benign, pre-malignant or malignant lesions. The authors concluded there is a need for better education and training models for general dentists and hygienists in terms of the examination and lesion assessment of oral cancer. They suggest a decision making tree should be developed in the training.<sup>31</sup>

In a publication in JADA, a report by the American Dental Association, guidelines for clinicians (specified as dentists), the panel recommends that clinicians perform an oral exam on every patient. A list of clinical pathways for the clinician in evaluating potentially malignant disease, good practice statements and the evaluation of potentially malignant disorders and oral squamous cell carcinomas of the oral cavity are reported in this publication Lingen, M, et al. October, 2017.<sup>30</sup> The panel of experts recommended that patients with suspicious lesions need to be referred to those who perform biopsies and adjunct techniques such as: autofluorescence, tissue reflectance and vital staining and cytologic testing are not more effective than a comprehensive oral exam. However, in patients who decline biopsy and refuse a referral, cytologic adjuncts could give the clinician more information and perhaps persuade the patient to seek further treatment through a biopsy or referral to a specialist. The panel suggests immediate biopsy in unexplained, suspicious lesions and referral to a specialist who performs such biopsies when they cannot be performed in the present clinic/office.

The publication recommends that the oral exam should be addressed by the dentist, but hygienists are well-versed in tissue management and spend a substantial amount of time with patients and especially the patients who are seen multiple times in a practice for tissue maintenance and recare appointments. A team approach is recommended and an oral exam takes very little time with large advantages when viewed by multiple professionals even in the same office or clinic. With the surprisingly high rates of oral cancer, the oral exam is never wasted time and very often will provide large benefits to the patient. Other studies conducted by Tomar et al. surveyed the oral cancer screening experiences of adult patients in Florida and the self-reported frequency of performing oral cancer screening examinations by dentists/ dental hygienists in Florida. Less than 20% of adults over age 40 reported having a screening examination while the dentists and hygienists reported they screened almost all of their over age 40 patients.<sup>32</sup>

Education regarding the risk factors related to oral cancer is crucial in reducing the risk for all patients including those patients who consume alcohol, use tobacco products and for those who maintain a poor quality lifestyle. Teaching patients to become cognizant of changes in their oral tissues empowers them to become an active participant in their own health and to perhaps discover an early lesion between dental visits. A study of North Carolina dental hygienists by Bigelow, et al. found hygienists play a key role in prevention not only in detecting precancerous and malignant lesions early but also in educating patients to avoid risk factors.<sup>33</sup>

Two major reporting agencies in the United States are the American Cancer Society (ACS) and The National Cancer Institute, Surveillance, Epidemiology and End Results Program (SEER). Oral squamous cell carcinoma (SCCA) comprises 90% of all oral cancers. Comprising the remaining 10% are cancers of the salivary glands, sarcomas and other cancers classified as rare.<sup>1</sup> According to current SEER data 2024, approximately 58,450 cases of oral cavity and oral pharynx cancer will be diagnosed in the United States of which more cases will be found in men and this is twice that of oral cancer found in women.<sup>34</sup> This is 2.9% of all new cancers. According to SEER data the median age at diagnosis for oropharyngeal cancer is approximately 63 years of age and the five year survival rate in the United States is approximately 66.9% all stages combined. At the current time only 31% of cases are diagnosed at a localized stage which has the highest 5-year survival rate of 69.0%. SEER data estimates 12,230 deaths from oropharyngeal cancers will occur in 2024.<sup>33</sup>

Head and neck cancers have multifactorial etiologies. In addition to increasing age and use of tobacco and alcohol, sun exposure, genetic predisposition, viruses such as HPV and HIV, and inadequate nutrition, play a role in the development of head and neck cancer. Alterations in host immunity, chronic inflammation associated with some mucosal diseases, and exposure to radiation or carcinogens also play a role in the development of head and neck cancers.<sup>35</sup> Patients should

be examined at every visit, encouraged to perform self-exams and to report any observed abnormality. One study conducted in Maryland found that current and former smokers were no more likely to have had an oral cancer examination than anyone else in the general population.<sup>36</sup> Knowing the health history of the patient should be even more of a reason to focus on the susceptibility of certain individuals.

Recent discoveries associating oral HPV infection (especially HPV 16 and HPV 18) with the dramatic increase of HPV-related oropharyngeal cancers worldwide have researchers scrambling to determine the impact this will have on the future. Some are predicting an epidemic of HPV-related oropharyngeal cancers in the coming years.<sup>34,37</sup> Chaturvedi, et al. estimate that by 2020 human papilloma virus (HPV) associated oropharyngeal squamous cell cancer cases may surpass the annual number of cervical cancers; the majority of these oral cancers being found in men.<sup>18</sup> We are all aware of the vaccinations available for preventing HPV-related cervical cancer in women and genital warts in both men and women, but current research is focused on whether these vaccines might prevent oropharyngeal cancers as well. Recent acceptance and recommendation by the ADA 2018, has extended the focus and commitment of dental professionals in promoting the vaccine. The organization cites the American Academy of Pediatric Dentistry in issuing a 2017 policy statement on the HPV vaccination. The academy encourages education and counseling of patients on the health risk of HPV and providing information about the current vaccination against HPV. The FDA approved a supplemental application for Gardasil 9 (HPV 9 valent-vaccine, recombinant; Merck & Co., Inc extending the age group for both males and females to aged 27-45 years old.<sup>44,45</sup> They have already determined that HPV-related cancers affect the base of the tongue, tonsils and other pharyngeal tissues that includes the nasopharynx significantly more often than tissues in the oral cavity proper and that they are affecting a younger population often with no history of tobacco or alcohol use.<sup>34,37</sup> SEER data notes that HPV is associated with



70% of oral cancers. There are over 40 HPV types that may cause oral cancer. White males are most often affected followed by Black males, American Indian, Hispanic, and Asian men.<sup>1,2</sup> Research has shown that HPV-related oropharyngeal/tonsillar cancer has a better prognosis than cancers not related to HPV. While there seem to be more questions than answers on this topic, it is up to the dental professional to remain informed and to be cognizant of the fact that early detection of any of these cancers can be accomplished by practitioners who are actively looking for them. The Oral Exam is still, by far, the most effective way of detecting an early oral cancer.<sup>3,30</sup>

### **SIGNS THAT SHOULD GET YOUR ATTENTION WITH REGARD TO ORAL HPV INFECTION:**

(based on SEER data)<sup>1,2</sup>

- A sore throat that is persistent
- A noticeable lump in the nose, neck throat, mouth, oral tissues or lips
- The patient complains of trouble breathing, speaking, chewing, swallowing, opening the mouth, jaw or moving the tongue
- Ear Pain
- A change in the voice

The dental professional is in an excellent position to assist the patient in obtaining and maintaining total health. By providing information on health-related topics and referring patients to specialists such as oral pathologists & Oral medicine specialists, dermatologists, internists, nutritionists and others, we can assist the patient in obtaining quality healthcare. Dentists and hygienists are in a prime position to talk to patients, assess oral tissues (which are a good indicator of total health), and provide health related information to our patients. Dental hygienists have more one-on-one contact time with patients than most other health care providers and can spend more time providing education even while providing treatment. Many patients have established regular 6 month or yearly recall or maintenance appointments increasing the probability for lesions to be detected early if the dental professional looks for them. In addition, the dental operatory is engineered to provide the best possible visualization of the oral cavity and surrounding structures. We

have better light sources than are available to most other practitioners allowing us to better visualize oral tissues and the patient chair enables us to position the patient for optimum access.

The study by Cotter et al., published in the Fall 2011 *Journal of Dental Hygiene*, concluded that greater emphasis should be placed on the importance of the oral cancer assessment in dental hygiene education and that practicing hygienists should avail themselves of continuing education in oral cancer assessment.<sup>21</sup>

### **The General Physical Appraisal**

The clinician needs to determine an overall impression of the general health and physical wellbeing of each patient. The general appraisal begins with the initial patient contact and continues during the entire appointment. The first opportunity to observe the patient's general health and physical characteristics usually presents as the patient is escorted to the operatory from the reception area. During this walk the clinician can observe the patient's posture and gait and any physical limitations which may be apparent. The general appraisal continues as the clinician obtains or updates the medical and dental histories (Figure 1).

The person's overall cleanliness and personal appearance may give the clinician clues as to the ability of the patient to perform routine self-care procedures and could provide clues about their emotional/mental health status as well. The hair should be discreetly observed for cleanliness, amount and distribution, and the presence of nits which are indicative of an infestation with head lice. Be aware a strain of head lice has formed that is resistant to the most common medications used to eliminate them. Any patient suspected of harboring head lice should be dismissed and the chair and surrounding area should be thoroughly cleaned by vacuuming. A fresh headrest cover for every patient is necessary. The following web sites have interesting and timely information on preventing the spread of and treating lice infestations: [Headlice.org](http://Headlice.org) and [Centers for Disease Control and Prevention/Head Lice](http://Centers for Disease Control and Prevention/Head Lice).

In addition to a general appraisal of skin texture, color, and general health, any exposed skin surface should be examined for evidence of skin cancer or other lesions. The American Academy of Dermatology's ABCDE's of Malignant Lesions<sup>39</sup> should be referenced frequently. This information is available at: ([American Academy of Dermatology: Melanoma](#)). It is easy to identify lesions, such as the one seen on the forearm in Figure 2, as abnormal but it is beyond the scope of our practice to make any other assumptions. The patient should be referred to a dermatologist or physician for evaluation of any suspicious skin lesions. The lesion seen in Figure 2 was eventually diagnosed as a squamous cell carcinoma. As the appraisal continues, the clinician should look for evidence of dermatological manifestations of systemic conditions, such as scleroderma, psoriasis, eczema, lupus, lichen planus, pemphigus vulgaris, and mucous membrane pemphigoid, and other general health concerns (Figure 2).

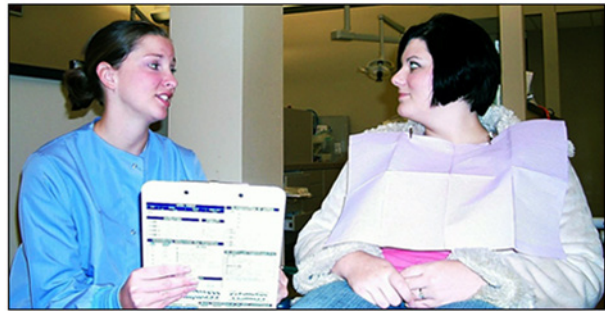Many disorders present with oral and cutaneous lesions and the presence of both may assist in the identification of an undiagnosed condition. Before continuing with the examination, be sure to check the hands for evidence of habits such as pitting, HPV infections, signs of infections, nail pitting, signs of arthritis, systemic diseases and tobacco use (Figure 3). Ask the patient questions about suspicious areas to determine their history and possible etiology and document your findings in the dental record.

The head and neck and oral examinations follow the general appraisal of the patient. Findings from these examinations will fall into one of three general classifications:

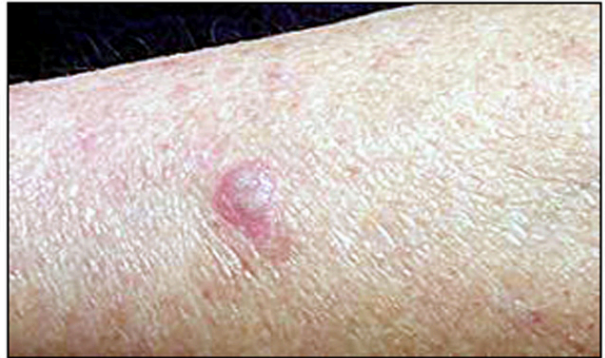1. Normal – found in most individuals,
2. Atypical – not present in all individuals but still within normal limits (a variation of normal),
3. Pathologic – associated with infection, trauma, neoplastic growth, errors in development causing functional problems, immune system disorders, and more.

### The Head and Neck Examination

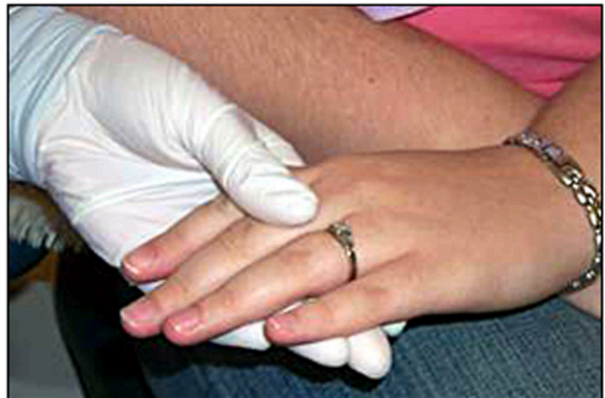The head and neck examination will enable the clinician to focus attention on careful



**Figure 1.** General appraisal to obtain or update the medical and dental history of the patient.



**Figure 2.** Diagnosed squamous cell carcinoma.



**Figure 3.** Check the hands for evidence of habits such as nail biting, HPV infections, nail infections, nail pitting, signs of arthritis, systemic diseases and tobacco use.

observation of the structures of the head and neck. The sequence used in performing the head and neck examination and subsequently the intraoral examination is not as important as performing each examination using the exact same sequence every time. Consistency enables the clinician to perform these examinations quickly and efficiently while still maintaining the highest degree of awareness in order to identify abnormal versus normal conditions.

### Symmetry and Profile

Discreetly observe the patient for facial symmetry (Figure 4) and profile type (Figure 5). Obvious asymmetry may be a red flag for neoplastic growths, muscle atrophy or hypertrophy, and neurological problems. Asymmetry is also associated with temporomandibular joint dysfunction and malocclusions (Figures 4 and 5).

### Cutaneous Area

As in the general appraisal, the exposed skin of the head and neck should be examined for suspicious lesions. The skin of the neck and scalp can be examined while the clinician is palpating the occipital and cervical nodes. The area behind and around the ear can be observed while palpating the auricular nodes. The patient should be questioned about their knowledge of any lesions discovered during the examination and also any lesions that they may have noticed themselves anywhere on the body. Information about the history, and any symptoms such as pain, pruritus (itching) or other abnormal sensations associated with the lesions is crucial in determining a differential diagnosis and can assist in deciding whether to refer to a specialist. The size and physical characteristics of suspicious nevi should be documented. These and other lesions exhibiting the warning signs associated with the ABCDE's of Malignant Skin Lesions should be referred for further evaluation. In addition, the patient should be advised to watch for changes in nevi and other pigmented lesions not exhibiting the warning signs of skin cancer. Any evidence of physical abuse should be noted. This is especially relevant in the case of children who may not voice any problems. Subsequently, correlation between cutaneous lesions and intraoral lesions found during the intraoral examination should be made as in the case of the patient with discoid lupus erythematosus shown in Figures 6 and 7. The cutaneous lesions of discoid lupus (Figure 6) presented concurrently with the gingival inflammation (Figure 7) seen during the oral examination.

### Lips

The lips should be examined for symmetry and tissue consistency and texture. Normally the lip tissue should be resilient, smooth and



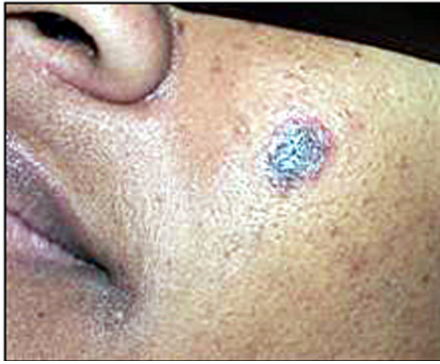
Figure 4. Facial Symmetry.



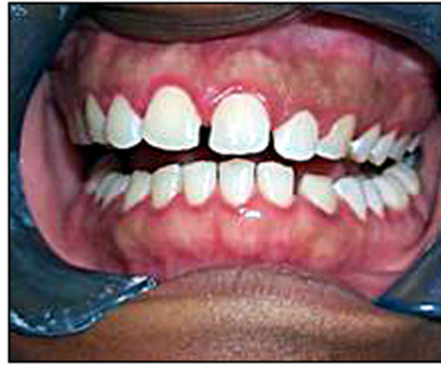
Figure 5. Profile Type.

have a homogenous pink color (Figure 8). The vermillion border should be distinct and even. Early ultraviolet damage may present as an indistinct or broken vermillion border with color variations or white blotches within the lip tissue. More advanced signs of damage include induration, pitting and ulceration of the tissues. Patients with the very early signs of damage should be shown the area and advised to limit exposure to the sun and use a lip balm with a sunscreen. They should be advised about the signs and appearance of more serious changes. Patients should monitor their lips for evidence of these changes. The commissures should be clear of lesions and should not show signs of cracking or dryness (Figure 9).

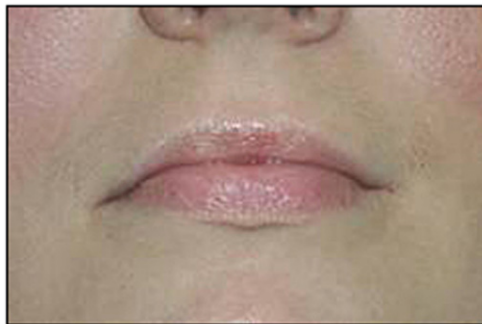
Common pathological conditions which affect the commissures include angular cheilitis, *Candida Albicans*, nutritional deficiencies, and Human Herpes Virus 1 or 2 lesions. The lips may also be affected by lesions associated with contact dermatitis or allergic reactions to food



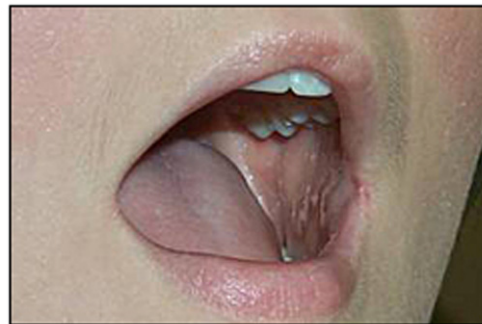**Figure 6.** Cutaneous lesion of discoid lupus.



**Figure 7.** Gingival Inflammation.



**Figure 8.** Normal lip tissue.



**Figure 9.** Commissures should be clear of lesions.

(even flavoring agents such as peppermint, spearmint, wintergreen and cinnamon), cosmetics, lip balms, dental products such as toothpaste, and other environmental substances. Habits such as lip chewing, biting the lips, and licking the lips may result in chapping and abrasion of the delicate tissues of the lips and the surrounding skin. It is often difficult to diagnose and to manage these lesions and patients may find it very difficult to break the long-term habits causing them.

Long-term exposure to ultraviolet light is known to be a cause of actinic cheilitis and is especially seen in adults over 50 years old. This may be a premalignant change or squamous cell carcinoma.

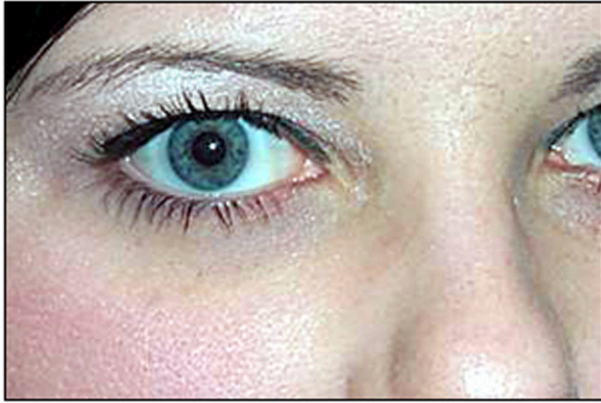### Eyes

Observe the eyes and the tissues around the eyes for any abnormalities. The tissue surrounding the eye is a common area to find lesions associated with sun damage such as basal cell carcinoma. Always remove the

patient's glasses. Metal frames increase sun damage around the eye area which could lead to skin cancer. The rise in thyroid disease is noted in statistical data and thyroid eye implications are to be referred to a specialist. Other oral signs should be evaluated such as indications of pemphigoid affecting the eye and other systemic conditions that may be noted or that are suspicious.<sup>1,2,3</sup>

Pay close attention to the color of the sclera and the size of the pupils (Figure 10).

Yellow sclera is associated with jaundice and may indicate an undiagnosed case of hepatitis (A or B), other liver dysfunction or a blood disorder. Blue sclera is associated with osteogenesis imperfecta which may include alteration of the structure of dentin. Pupil size may help identify patients who are at risk for medical emergencies due to illegal drug use. Lesions such as symblepharon or pterygium may affect the sclera. Symblepharon is a partial or complete adhesion of one or both



**Figure 10.** Observe the eyes for any abnormalities.

eyelids to the eyeball associated with benign mucous membrane pemphigoid, lichen planus, and trauma such as burns. Pterygium is an excessive growth of the conjunctiva which begins to cover portions of the sclera potentially obstructing vision. A referral to a specialist such as an ophthalmologist is needed to assess any condition exhibiting symblepharon or pterygium. These types of eye changes may also be an early sign of pemphigus vulgaris and mucous membrane pemphigoid. A recent focus on complaints of the eye such as excessive tearing, irritation and dryness have been associated with thyroid eye disease and may be a consideration when patients exhibit these signs. There is a notable increase in thyroid disease and thyroid cancer.

### Lymph Nodes

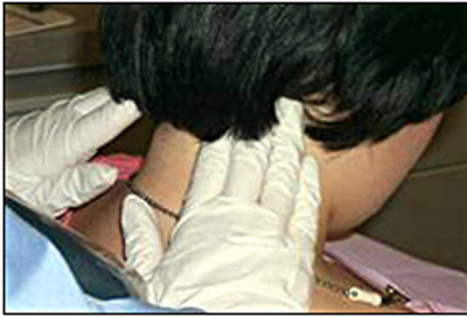The major lymph nodes of the head and neck area should be palpated with the patient in an upright position. Findings which should be noted in the patient record include enlarged palpable nodes, fixed nodes, tender nodes and whether the palpable nodes are single or present in groups. Single or multiple non-tender, and fixed nodes are very suspicious for malignancy. Groups of tender nodes usually occur in conjunction with some type of acute infection. Occasionally nodes will remain enlarged and palpable after an infection. This is a relatively common occurrence especially within the submandibular group of lymph nodes. When examined, these nodes should be small (less than 1 cm), non-tender and mobile. Remember to correlate findings from

the medical history and general appraisal of the patient to the observations made during the head and neck examination. For example, a previous history of cancer should cause the clinician to be more suspicious of newly appearing palpable nodes than if there is no history of cancer. If suspicious nodes are discovered, the patient should be referred to a physician for immediate evaluation. Figures 11 through 18 depict the examination techniques for the following lymph nodes.

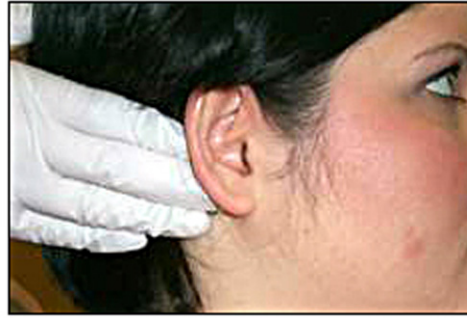- Occipital nodes (Figure 11) – Palpate the occipital nodes about one inch above and below the hairline.
- Auricular (Figures 12 and 13) – Palpate the pre and post auricular nodes bilaterally using the pads of the index, middle and ring fingers.
- Cervical Chain (Figures 14 and 15) – Palpate the nodes medial to the sternocleidomastoid muscle using a bidigital technique and the nodes posterior to the muscle with a bimanual technique.
- Supraclavicular (Figure 16) – These nodes are examined using digital compressions just superior to the clavicle.
- Submandibular (Figure 17) – Palpate the submandibular nodes by pulling or rolling the tissues under the chin up and over the inferior border of the mandible. Next ask the patient to firmly press the roof of the mouth with the tongue. This will allow you to assess the muscles and any pathology associated with the submandibular lymph node areas.
- Submental (Figure 18) – Use digital palpation to determine the presence of an abnormal submental lymph node.

### Salivary Glands

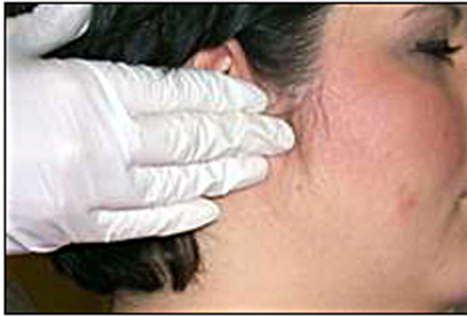Palpate the parotid (Figure 19) and submandibular (Figure 20) salivary glands using a bilateral technique. Normally these glands should not be palpable. Induration and pain could be signs of infection, blockage, immune system disorder or a neoplastic process. In addition, non-tender parotid enlargement may occur with alcoholism, diabetes, Sjögren's syndrome, eating disorders, HIV infection and various malignant/non-malignant states involving the salivary glands.



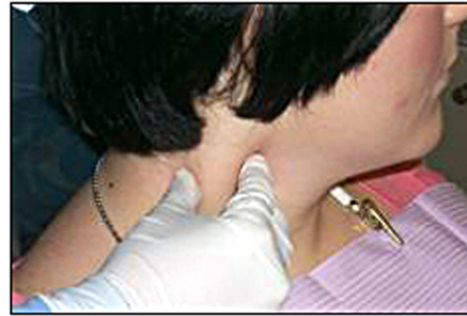**Figure 11.** Bilateral palpation of the occipital nodes. Be sure to also observe the skin in this area.



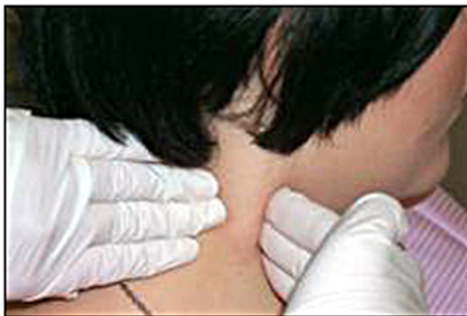**Figure 12.** Postauricular nodes.



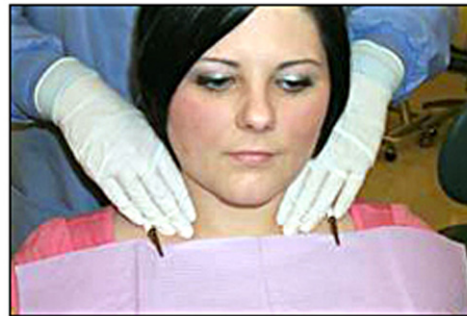**Figure 13.** Preauricular nodes.



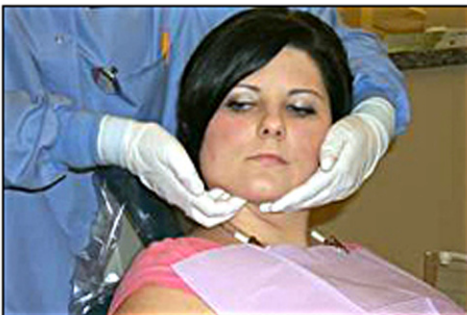**Figure 14.** Palpation of the anterior cervical nodes.



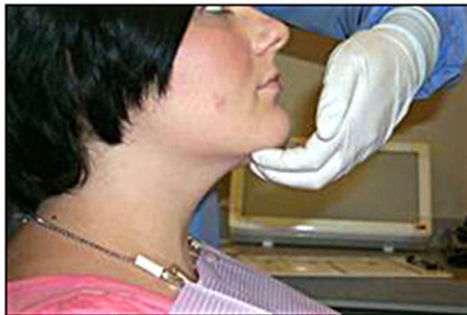
**Figure 15.** Palpation of the posterior cervical nodes.



**Figure 16.** Bilateral palpation of the supraclavicular lymph nodes.



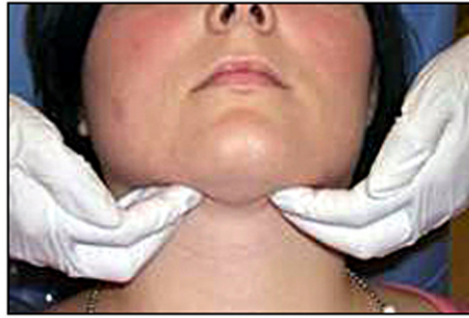
**Figure 17.** Palpate the submandibular lymph nodes using a cupped hand as shown.



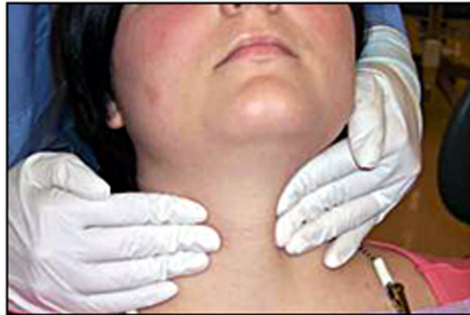**Figure 18.** Digital palpation of the submental lymph nodes.



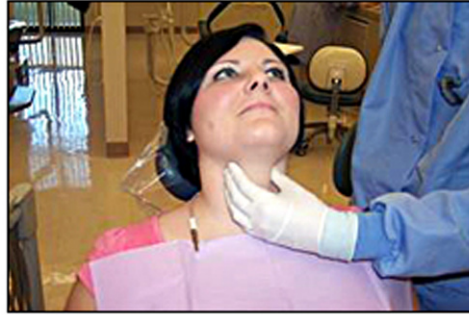**Figure 19.** Palpation of the parotid gland.



**Figure 20.** Palpation of the submandibular glands.



**Figure 21.** Bimanual palpation of the thyroid gland.



**Figure 22.** Hold the fingers lightly over the gland while the patient swallows.

### Thyroid Gland

The thyroid gland is found inferior to the larynx and just superior to the clavicles on either side of the trachea. It consists of two lobes connected by an isthmus. Palpate the gland using a bimanual technique where one hand supports the tissue and the other hand palpates the gland on one side and then the reverse is done to examine the opposite side of the gland (Figure 21)

The normal thyroid gland should not be visible and is most often not palpable. In addition, the area surrounding the gland should elevate smoothly and symmetrically during swallowing (Figure 22).

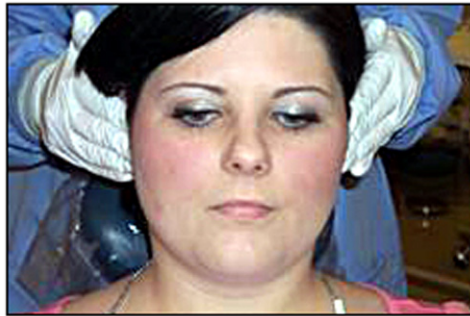
Any variation from these normal findings should be discussed with the patient and the patient should be referred to their physician for further evaluation (see provided forms for referral – Appendix A, B & C). An increase in thyroid carcinoma with an undetermined etiology has been reported in recent years. The National Cancer Institute estimates 44,000 new diagnoses of thyroid cancer in 2024 comprising 2.2%

of cancer cases and 2,170 deaths and a 98.4 percent survival rate from thyroid cancer in the United States in 2024.<sup>42</sup>

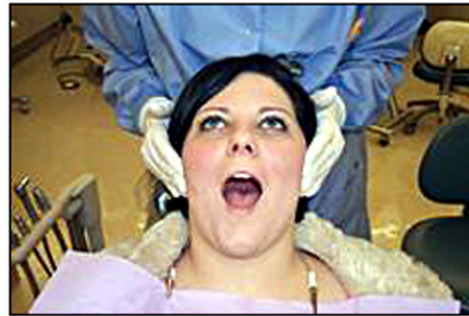
### Temporomandibular Joint Evaluation

The function of the TM joint should be evaluated using a bilateral technique. Place the fingertips over the joint and have the patient open and close slowly (Figures 23 and 24), move the jaw to the left and right and jut the chin out.

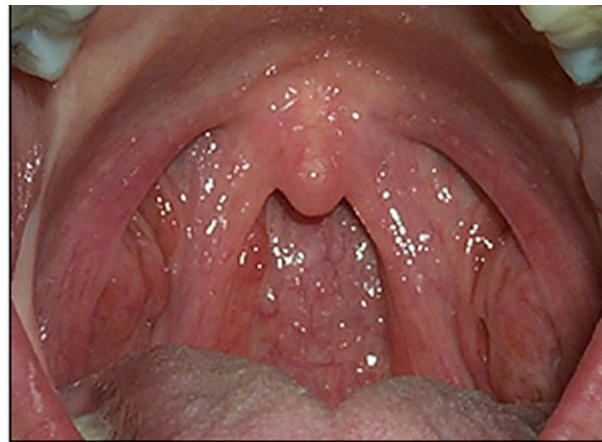Look for altered opening and closing pathways, abnormal sounds, tenderness and limitations in opening. There are two basic types of altered opening pathways, deviations and deflections. An altered pathway on opening which comes back to the midline at maximum opening is termed a deviation. If the greatest distance from the midline occurs at maximum opening it is called a deflection. Abnormal sounds may be heard or felt and usually fall into one or more of three major categories, clicks, pops and crepitus. Clicks and pops are associated with articular disk derangement and crepitus is usually associated with some form of arthritis. Correlate TM joint findings with the patient's occlusal classification



**Figure 23.** Proper positioning of the fingers on the TM joint.



**Figure 24.** Have the patient open and close slowly.



**Figure 25.** Normal anatomy of the oropharyngeal area.

and other dental findings such as missing teeth and poorly fitting partial and/or full dentures. Follow-up questions should focus on the history of any observed symptoms and determination of any lifestyle or dietary modifications the patient may have made to alleviate discomfort. Examination of the TM joint provides a perfect transition point for the intraoral examination.

### The Intraoral Examination

As with the head and neck evaluation, this examination should be done using the same sequence every time. Areas should be visually examined then palpated wherever possible. Findings should be thoroughly investigated, and the information should be noted in the patient's record. Oral cancer may have multiple appearances. The first step in the intraoral examination is a quick general examination of the cheeks, hard palate, tongue and gingiva looking for any contraindications for continuing the evaluation. If there are none, start the examination.

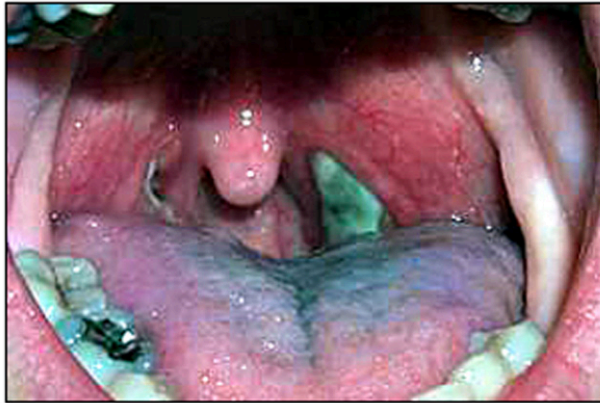
### Oropharynx

Examine the oropharynx by placing a mirror or tongue depressor on the dorsal surface of the tongue applying gentle pressure without having the patient stick their tongue out. You should be able to visualize the posterior pharyngeal wall, anterior and posterior pillars and the tonsillar crypt and tonsils, if present (Figure 25). These areas are normally not palpated unless there is a need.

### Posterior Pharyngeal Wall

The tissue in this area should appear very vascular but otherwise homogenous in color tending towards reddish pink (Figure 25). The surface may be smooth or appear to have small coral pink to translucent, gelatin-like, homogenous surface prominences which are consistent with normal areas of scattered lymph tissues (lymphoid aggregates). Pathologic findings include:





**Figure 26.** Streptococcal infection of the tonsils. Note the purulent exudate.

- Homogenous and non-tender erythema associated with post nasal drip and/or smoking
- Erythema and purulent exudate associated with pharyngitis (infection of the pharynx) may cover portions of the pharyngeal wall
- Ulcers, erosions or noticeable enlargements or growths

#### **Anterior and Posterior Pharyngeal Pillars**

The anterior and posterior pillars should appear vascular, smooth and symmetrical (Figure 25). Atypical findings one may encounter include lymphoid aggregates (as found on the posterior pharyngeal wall), areas of pale scarring in a radial or stellate pattern from tonsillectomy, or torn or absent pillars also a result of this surgery. Pathologic findings include:

- Asymmetry, unless due to tonsillectomy
- Lesions of any kind
- Erythema associated with tenderness or exudates

#### **Tonsillar Crypt**

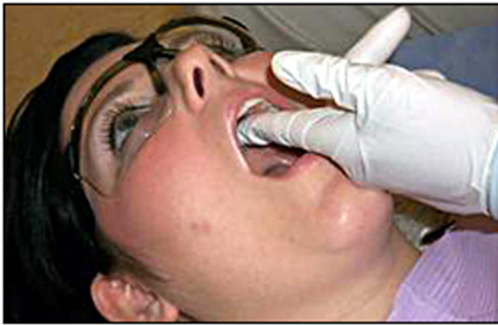The tonsils are examined using direct visualization. You will observe rough, lobular, and coral to light pink tissue of varying amounts between the anterior and posterior pharyngeal pillars (Figure 25). Atypical presentations include excessively large or asymmetrical tonsils, cratered surfaces without evidence of erythema or exudates. Occasionally, individuals have large crypts in the tonsils that collect food debris, bacteria and hardened material. Patients with this type of cryptic tonsil often complain of halitosis.

Careful inspection is needed to evaluate the tonsils for serious diseases. Since increases have been reported in tonsillar cancer it is important to fully evaluate, refer if necessary and follow-up on any suspicious areas seen. Early stages of this cancer may not be very suspicious looking so it is essential to be vigilant. After a tonsillectomy one may observe residual tonsil tissue or a regrowth of lymph tissue in the area. Pathologic findings include:

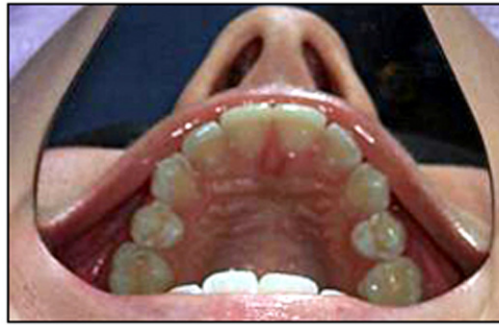- Dysphagia (painful or difficult swallowing)
- Swelling, asymmetry, erythema and/or surface exudates (Figure 26)
- Erythema and/or dysphagia may also be associated with mouth breathing and may indicate a nasal obstruction.

#### **Soft Palate and Uvula**

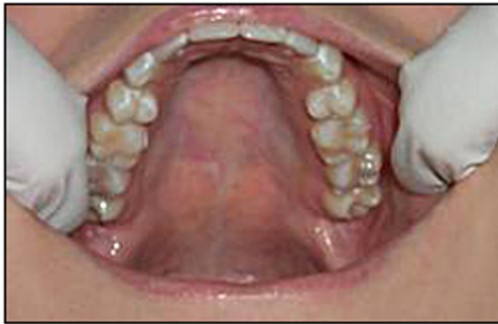This area is examined using direct vision and is normally not palpated unless necessary. If palpation is necessary a topical anesthetic should be used and the tissues should be palpated from the mid line out towards the lateral surfaces. Normally, this area is slightly less vascular than the oropharynx and is usually reddish pink in color (Figure 25). Observe the area as the patient says “ah.” The tissue should appear loose, mobile and symmetrical during function. The tissue will have a homogenous, spongy consistency on palpation. Atypical observations include yellowish coloring due to increased adipose tissue (especially in older patients), excessively long or short uvulas and uvulas that appear slightly asymmetrical at rest. Occasionally one will discover a bifid (cleft) uvula. Pathologic findings include:



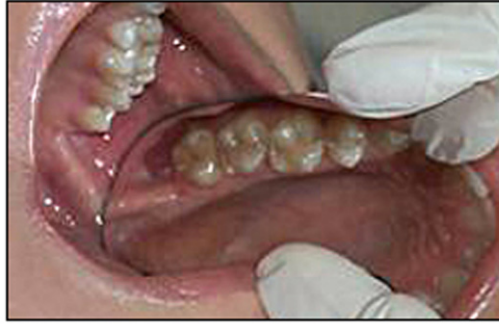**Figure 27.** Palpating the hard palate. Use firm pressure and try not to slide the fingers along the tissue.



**Figure 28.** Normal structures of the anterior hard palate.



**Figure 29.** Normal structures of the posterior hard palate. Observe the dimensions (height and width) of the vault.



**Figure 30.** Normal maxillary tuberosity.

- Lesions of any kind
- Loss of function or lack of symmetry during function, both of which may indicate compromised swallowing capability and a higher risk of aspiration of food and oral fluids into the lungs

### Hard Palate

The hard palate and maxillary tuberosity areas are examined using both direct and indirect vision and illumination. Following the visual examination the clinician should digitally palpate the entire area using firm non-sliding pressure against the bone (Figure 27).

In general, the tissue is a homogenous pale pink color, firm to palpation towards the anterior and lateral to the midline while more compressible towards the posterior and medial to the apices of the teeth. The normal structures of the hard palate should be identified:

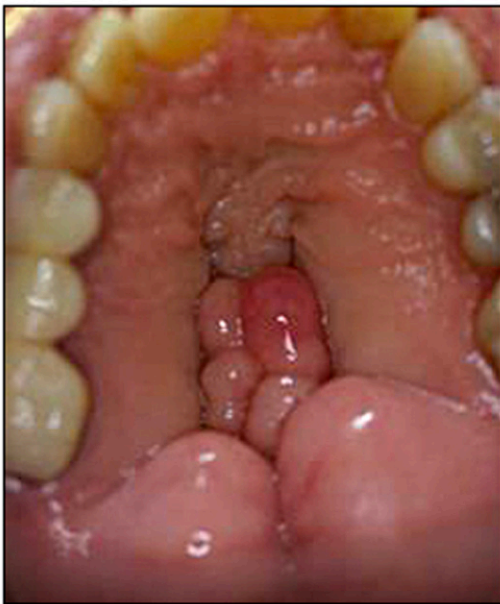
- Incisive papilla – protuberance of soft tissue lingual to the maxillary central incisors which covers the incisive foramen

and normally appears redder than the surrounding tissues (Figure 28)

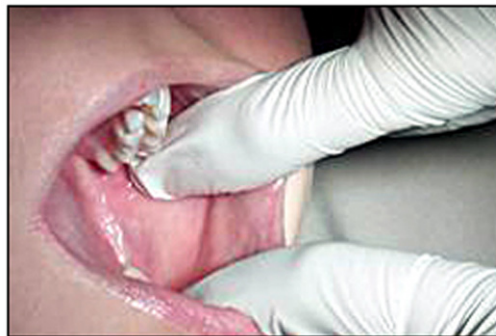- Raphe – slightly elevated line extending from the incisive papilla to the soft palate (Figure 28)
- Rugae – corrugated ridges radiating laterally from the raphe (Figure 28)
- Vault – relates to the depth and width of the palate (Figure 29)
- Maxillary tuberosities – area distal to the last molars (Figure 30), the tissue should be a homogenous pink color and firm to palpation

The torus palatinus is the most common atypical finding in the hard palate. These tori may range in size from very small to very large. They present as single or multilobular masses (Figure 31) and usually have a smooth surface texture. Often the larger tori will have traumatic ulcers or other traumatic lesions on their surfaces.

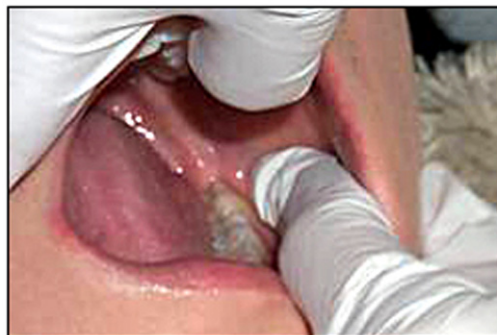Tori are not usually considered a problem unless prosthetic appliances are being



**Figure 31.** Extreme example of a multilobulated torus palatinus.  
Image contributed by Dr. Alan Coleman



**Figure 32.** Stretch the tissues making sure you look under the areas covered by your fingers.



**Figure 33.** Stretch the tissues away from the retromolar area.

considered. Tori also make it difficult to expose intraoral radiographic films. Pathologic findings include:

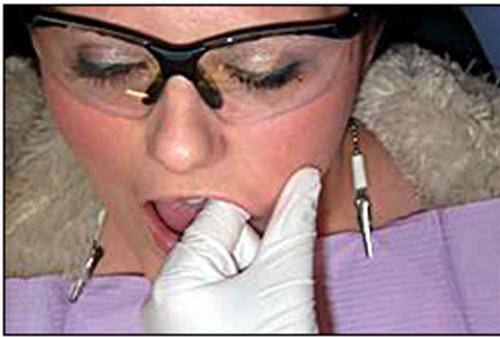
- Pigmented macules – pigmented lesions of any type should be identified to rule out melanoma. The palate is also a common area for unintentional tattoos resulting from pencil leads being jabbed into the tissues while playing with a pencil or holding it in the mouth.
- Thermal burns – the anterior palate is the most common area for this type of traumatic injury
- Nicotine stomatitis – whitening and fissuring of the attached gingiva of the hard palate and inflammation of the minor salivary gland ducts
- Papillary hyperplasia – development of finger-like projections usually under a poorly fitting full or partial denture
- Other traumatic lesions – abrasions and lacerations resulting from eating and factitial injuries
- Systemic related lesions – lesions related to lupus are commonly found in the palate and the palate is a prime location for the blue nevus

### Buccal Mucosa

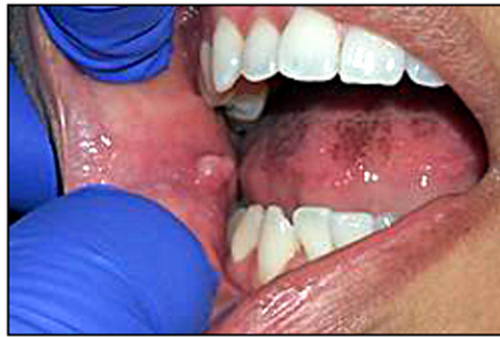The buccal mucosa is examined using direct and indirect vision followed by bi-digital palpation of the entire area. Be sure to pull the tissues away from the retromolar area and stretch the mucosa away from the mucogingival junction (Figures 32 and 33).

The buccal mucosa should be bidigitally palpated pressing the tissue between the index finger and thumb of one hand (Figure 34).

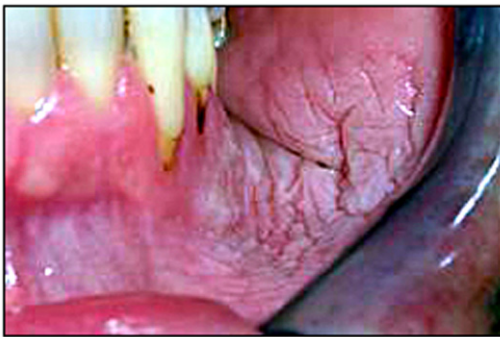Normal tissues of the buccal mucosa appear moist and pink/dark pink. They are soft and pliable on palpation with no discernible indurations. Stensen's duct should be identified with or without the presence of a parotid papilla. Linea alba, Fordyce's granules and leukoedema are common atypical findings on the buccal mucosa. You may feel small papules within the tissues usually indicative of sclerotic or fibrotic minor salivary glands. Varicosities



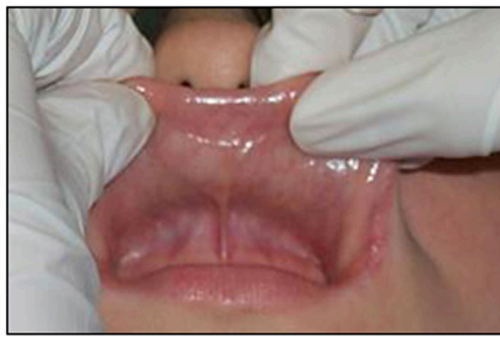**Figure 34.** Palpating the buccal mucosa.



**Figure 35.** Traumatic fibroma associated with chronic cheek biting.



**Figure 36.** Leukoplakia associated with spit tobacco.



**Figure 37.** Visual examination of the upper labial mucosa.

may often present on the buccal mucosa of older patients. The buccal mucosa is also a prime area for stress related habits such as cheek chewing (morsicatio buccarum). Assisting the patient in stress reduction techniques and providing awareness of the habit is helpful. Pathologic findings associated with the buccal mucosa include:

- Traumatic injuries – thermal burns, cheek bites, ulcers, traumatic fibroma (Figure 35)
- Leukoplakia associated with spit tobacco (Figure 36)
- Neoplastic changes – erythroplakia, speckled leukoplakia and pigmented lesions
- Systemic disease – oral lichen planus, pemphigus vulgaris, pemphigoid, lupus, lipomas, aphthous ulcers, erythema multiforme, and Crohn’s disease, as well as, allergy-related tissue responses.

### Labial Mucosa

The labial mucosa is examined using direct vision by averting the tissues over the fingers or thumbs (Figures 37 and 38) followed by bidigital palpation of the tissues of the lips.

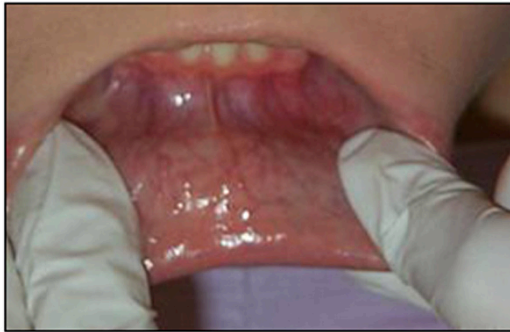Move the tissues from side to side and visualize the frena. Normal lip tissues are a homogenous deep pink color which changes gradually to a deep red color with more prominent vascularity near the mucolabial vestibule. The tissues should be moist and have uniform consistency and thickness when palpated (Figure 39).

Sclerotic minor salivary glands are common atypical findings as are Fordyce’s granules. Pathologic findings include the following:

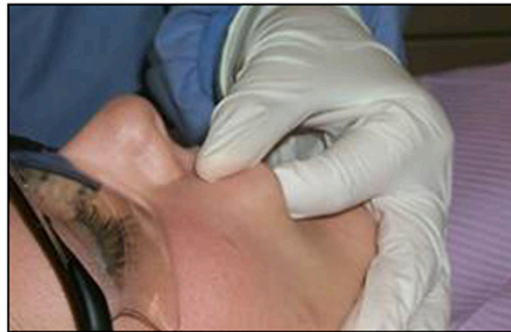- Traumatic injuries – abrasions, lacerations
- Dry, cracked lips
- Angular cheilitis – human herpes virus, Candida Albicans
- Aphthous ulcers
- Neoplastic changes

### Mandible

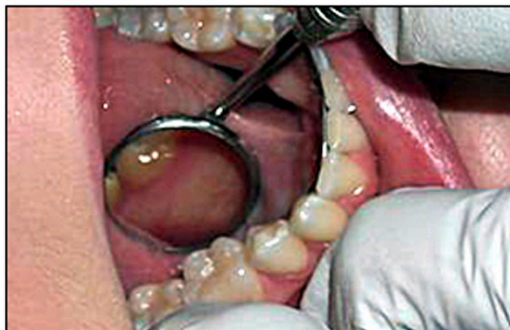The body of the mandible will be examined using direct and indirect vision followed by digital palpation of the entire structure. The tissues of the floor of the mouth should be stretched away from the inferior border of the mandible with a mouth mirror (Figures 40 & 41).



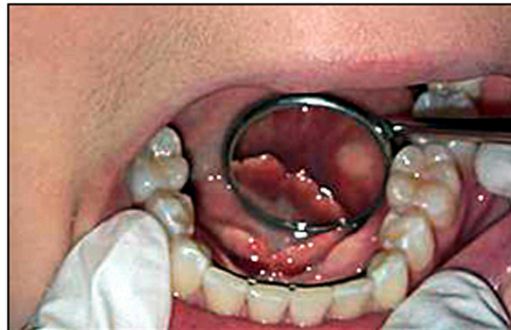**Figure 38.** Visual examination of the lower labial mucosa.



**Figure 39.** Bidigital palpation of the upper labial mucosa.



**Figure 40.** Use the mirror to stretch the tissue away from the inferior border of the mandible.



**Figure 41.** The mirror is used to visualize the anterior lingual portion of the mandible.

Digitally palpate the body of the mandible along the lingual and facial surfaces (Figure 42). Normal tissues will be a homogenous coral pink and have a firm consistency with no visible or palpable lesions. Mandibular tori and exostoses are the most common atypical findings in this area. The retromolar area may present with partially erupted third molars or scarring from third molar extraction. This area is also prone to hyperkeratosis from constant friction from masticatory function. Pathologic findings include:

- Traumatic lesions – ulcers, abrasions
- Infections – pericoronitis (Figure 43)
- Neoplastic growths
- Leukoplakia associated with spit tobacco

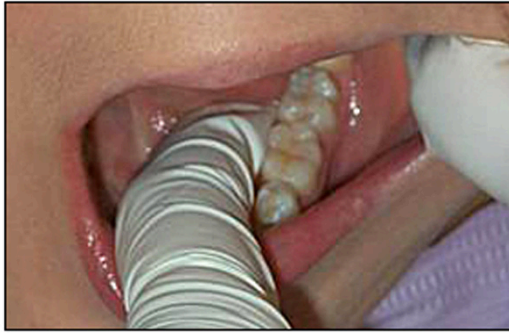### Floor of the Mouth

The floor of the mouth is examined using direct and indirect vision followed by bimanual palpation of the entire area. The patient should be asked to raise the tongue making direct visual examination of the tissues toward the midline of the floor of the mouth possible (Figure 44).

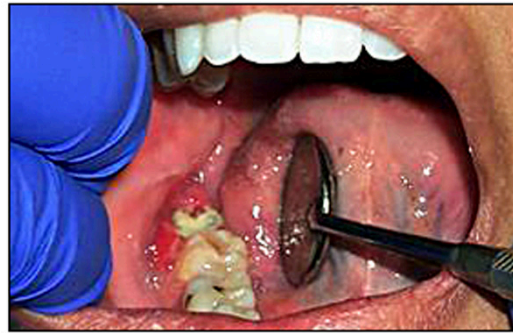The mirror should be used to examine the areas near the inferior border of the mandible. The tissues should appear moist and very vascular. The normal anatomy of the area should be identified (Figure 44) including:

- Sublingual caruncle – small rounded projection at the base of the lingual frenum which houses Wharton’s duct from the submandibular salivary gland
- Sublingual folds – two oblique elevations found radiating laterally away from the lingual frenum on either side of the caruncle which house the ducts from the sublingual salivary gland
- Lingual frenum – muscle attachment from the ventral surface of the tongue to the floor of the mouth. This attachment varies in length from person to person.

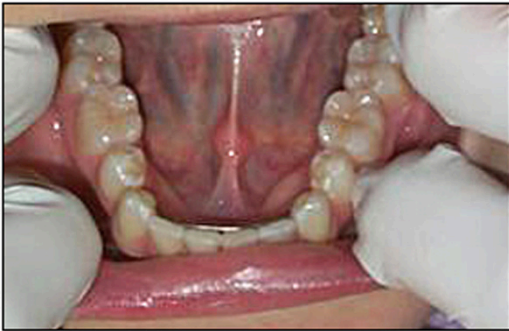Bimanual intraoral palpation with the index finger of the nondominant hand supported extraorally by the fingers of the dominant hand will allow the clinician to feel the structures of the area between the fingers as they are compressed together gently (Figures 45 and 46).



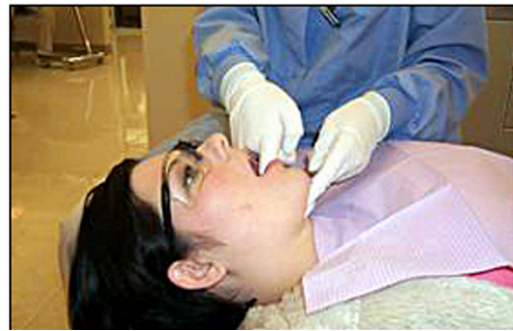
**Figure 42.** Use digital palpation pressing the tissues against the body of the mandible for both the lingual and the facial aspects.



**Figure 43.** Painful pericoronitis surrounding partially erupted #32.



**Figure 44.** Visual examination of the floor of the mouth. Note the normal structures of the area.



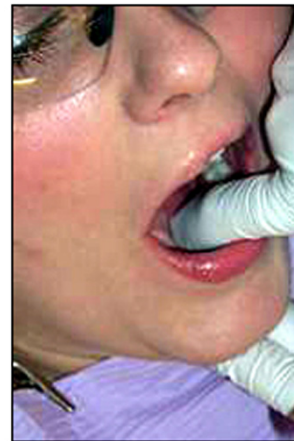
**Figure 45.** Extraoral view of proper palpation technique.

The tissue will be soft on palpation with firmer areas noted in the area of the suprahyoid muscles (digastric, geniohyoid, mylohyoid). The sublingual folds will feel ridge-like and mobile. Varicosities are the most common atypical observation in this area. Other atypical findings are enlarged lingual folds and caruncle and a short lingual frenum (ankyloglossia). Ankyloglossia is only considered a problem if it begins to affect the speech development of the individual. Pathologic findings include:

- Traumatic injuries – ulcers (Figure 47), mucoceles
- Salivary gland pathology – ranula, sialoliths, enlargement
- Neoplastic changes
- Ankyloglossia – this is considered pathologic only if it interferes with the normal development of proper speech

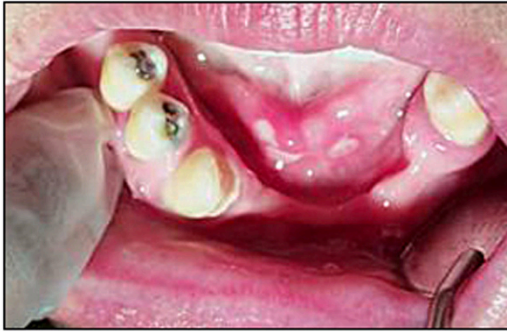
### Tongue

The tongue is examined using both direct and indirect vision. The most common place for cancer to occur on the tongue is the lateral

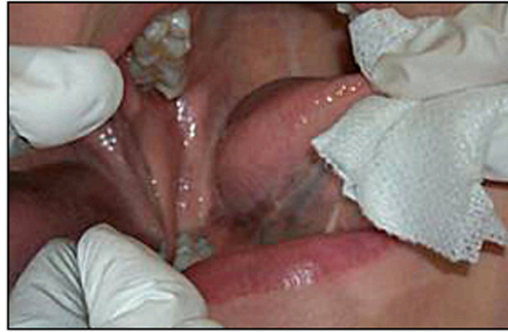

**Figure 46.** Intraoral view.

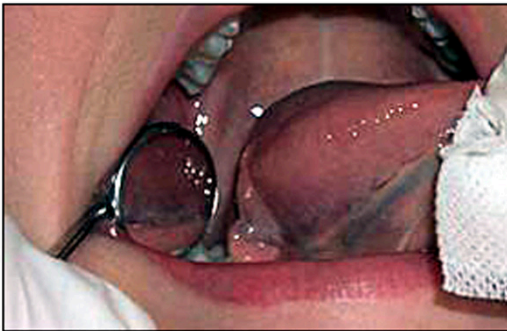
border and the base of the tongue (very high risk area). Grasp the tip of the tongue with a gauze square and roll the tongue over on one side to observe the lateral border then repeat for the other side (Figure 48). Use the mirror to examine the posterior lateral borders if necessary (Figure 49).



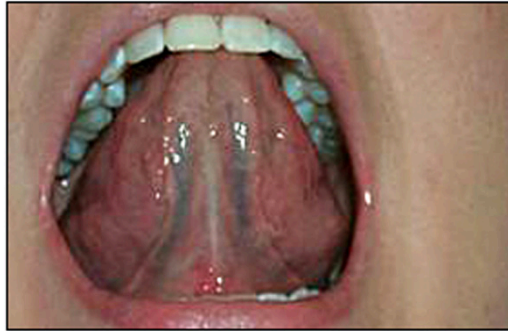
**Figure 47.** Traumatic ulcers resulting from intraoral radiographs.



**Figure 48.** Examination of the lateral borders of the tongue.



**Figure 49.** Proper use of the mirror to aid in the visual examination of the tongue.



**Figure 50.** Visually examine the ventral surface of the tongue.

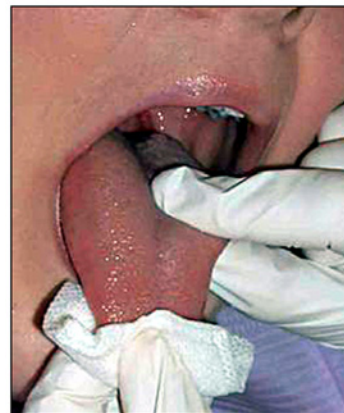Have the patient raise the tongue to the roof of the mouth to observe the ventral surface (Figure 50).

The tissues should appear pink in color with a rough surface texture on the dorsal surface and a smoother surface texture on the ventral surface. The tongue should be symmetrical in shape and in function.

Use a bidigital technique to palpate the entire tongue between the finger and thumb of one hand (Figure 51).

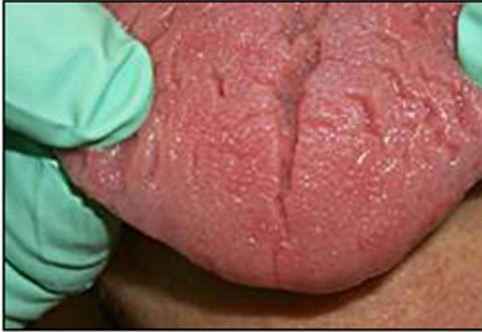The tissues of the tongue should feel soft and resilient with no palpable indurations or masses. The clinician should identify the normal anatomy of the tongue including:

- Dorsal surface – papillae (filiform, fungiform, circumvallate), median sulcus, sulcus terminalis
- Lateral borders – foliate papillae
- Ventral surface – lingual veins, plica fimbriata, lingual frenum

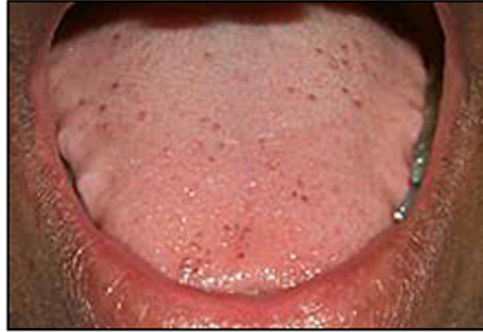

**Figure 51.** Grasp the tip of the tongue with gauze while palpating the body of the tongue.

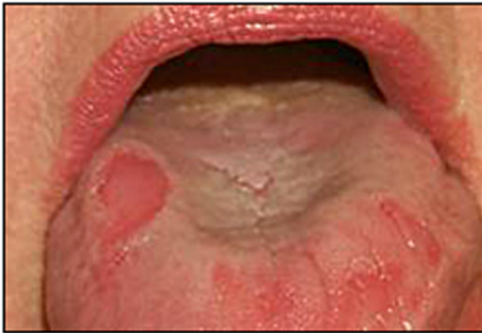Atypical findings on the dorsal surface of the tongue are common. They include: fissuring (Figure 52), scalloping (Figure 53), benign migratory glossitis (Figure 54) and enlarged papillae, among others. A lingual thyroid may rarely be found on the posterior dorsal surface at the foramen cecum. Lingual varicosities are



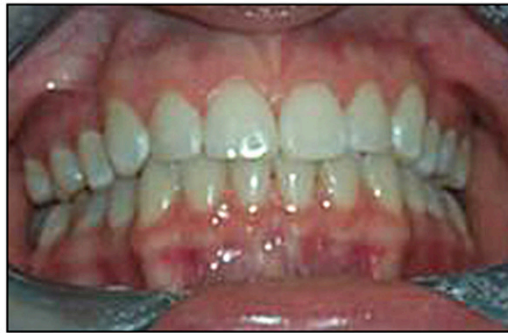**Figure 52.** Fissured tongue.



**Figure 53.** Scalloped tongue.



**Figure 54.** Benign migratory glossitis.



**Figure 55.** Normal attached gingiva, facial surfaces of the maxilla and mandible.

a common finding on the ventral surface of the tongue, especially in older patients. The Glands of Blandin-Nuhn (minor salivary glands found on the ventral surface of the tongue) may become enlarged prompting the need for a referral or diagnostic procedure to confirm the origin.

The tongue is the most common intraoral site for oral cancer. Therefore, any sign of pathology should be investigated thoroughly. Some of the pathological findings that are found on the tongue include:

- Hairy tongue – filiform papilla become elongated due to a variety of reasons from overuse of mouth rinses to not cleaning the tongue adequately.
- Candidiasis – fungal infection of the tongue often associated with deeply fissured tongues.
- Glossitis – inflammation of the tongue due to anemia, nutritional deficiencies and others.

It is also important to note if the tongue is coated with dental biofilm. The tongue is

home to the highest number of bacteria found anywhere in the oral cavity. Bacteria located on the tongue have been associated with halitosis, increased pH of the saliva, and periodontal disease. Tongue cleaning and methods of cleaning the tongue should be stressed during patient education.

### **Attached Gingiva**

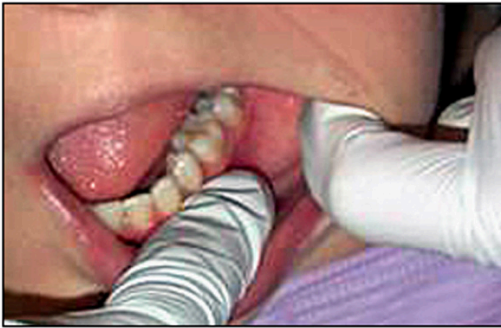The attached gingiva of the maxillary and mandibular arches is visually examined using both direct and indirect vision. The tissues should appear pale pink and homogenous in color and texture (Figure 55). Following the visual examination, the attached gingiva is palpated using a digital technique as shown in Figure 56.

The tissue should feel firm to touch and tightly attached to the bone. The most common atypical finding in the area of the attached gingiva is exostoses (Figure 57).

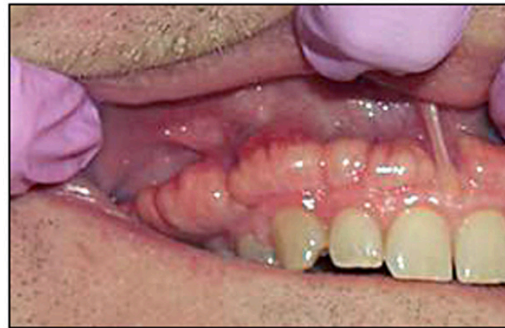Pathologic findings include:

- Inadequate zones of attached gingiva – the clinician should determine the presence of adequate amounts of attached gingiva in all areas. Less than 1 mm of attached gingiva is

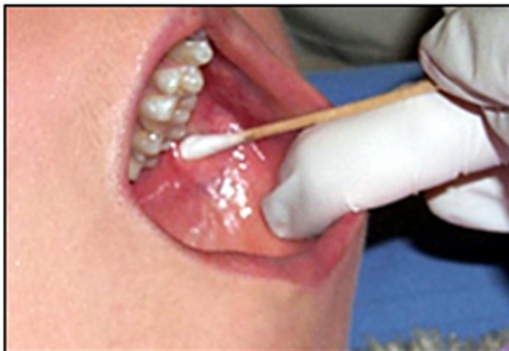



**Figure 56.** Digital palpation of the mandibular facial attached gingiva.



**Figure 57.** Extensive exostoses on the maxillary facial surfaces.



**Figure 58 and 59.** Use gauze to dry off the buccal mucosa then press the area above the duct to milk the gland.

considered to be inadequate in most cases and the patient should be referred to a periodontist for evaluation of the affected area.

- Mucogingival involvement – areas with no attached gingiva or areas of extreme recession
- Frena problems – tight frenum attachments or pulls
- Traumatic lesions – ulcers, abrasions, burns
- Mucosal disease such as lichen planus, pemphigus vulgaris, mucous membrane pemphigoid, lupus, and allergic type responses

### Salivary Flow and Consistency

Salivary flow and consistency will vary with each patient. Some abnormal findings must be noted such as frothy saliva or thick ropy saliva. Xerostomia should be suspected based on information collected from the medical/dental histories. Sometimes the patient's perception of dryness must be assessed as well. The patient may voice a concern of overall oral dryness, while the actual flow of saliva appears normal.

The mixture of serous and mucous saliva affects the perception of dryness as well. When problems arise with the parotid gland, the flow from Stensen's duct will be diminished. Milking the salivary glands from the tail toward the mid line assists the clinician in visually assessing the Stensen's duct orifice found next to the maxillary first molar.

Gauze should be used to dry the floor of the mouth and visually assess the flow from the Wharton's duct orifice and other ducts of both the sublingual and submandibular glands (Figure 58 and 59).

### Adjuncts for the Oral Cancer Screening

A panel convened by The American Dental Association (ADA) Council on Scientific Affairs to address the benefits and limitations of oral cancer screenings and the use of adjunctive screening aids concluded that screening by means of visual and tactile examination to detect potentially malignant lesions may result in detection of oral cancers at early stages of development, but there is insufficient evidence

to determine if screening alters disease-specific mortality in **asymptomatic people** seeking dental care.<sup>3</sup> The panel noted that additional research regarding oral cancer screening and the use of adjuncts is needed. However, the panel suggested that clinicians should observe the patient during routine examinations with both visual and tactile examination for any oral lesions and remain alert.<sup>3</sup>

Adjunct technologies and products available today, such as fluorescence, may provide the clinician with additional information and may help the patient visualize suspicious areas; however, they cannot determine what a lesion is or whether it is malignant or benign.<sup>41</sup> A biopsy involving the removal of part or all of a suspicious area of tissue and microscopic evaluation by a pathologist to determine its histological makeup is the **gold standard** for determining a definitive diagnosis. A study by Kondori, et al. in 2011 reported a high rate (43%) of misdiagnosis of oral lesions by dental practitioners when they based their diagnosis on clinical observations alone. The study conclusion supports the histologic diagnosis or biopsy as the standard of care<sup>41</sup> When malignancy is discovered, a second opinion may be appropriate.

The oral examination adjuncts listed on the following pages are currently available for use in offices, but they are considered \*only adjuncts\* to the complete oral cancer examination consisting of both visual and tactile examinations. The adjuncts can be categorized as follows:

1. Tissue staining techniques
2. Brush cytology to detect abnormal cells
3. Devices that aid in visually detecting abnormal tissue through the use of different wavelengths of light including: blue, amber, white or violet

#### ***Vital Tissue Staining-Toluidine Blue Staining***

Toluidine blue is a metachromatic dye that binds to DNA in vital tissues. It has been used for decades and was originally used for cervical screenings. It is not cancer specific, but it has been reported to stain cells with increased amounts of DNA and possibly altered DNA in premalignant and malignant epithelial lesions.

The product is usually applied topically followed by rinsing with water then blotting with 1% acetic acid. Toluidine blue can be obtained from most compounding pharmacies.

#### ***Liquid-Based Cytology***

A new cytology technique being used by many hospitals and gynecology practices in place of the traditional scraped Pap smear may be used with oral specimens as well. Instead of transferring the specimen onto a glass slide, the brush used to collect the cell specimen is twirled in a vial containing an alcohol-based fixative/preservative liquid. The brush head remains in the fixative so that no cell is lost during this process and the entire vial is sent to a laboratory for microscopic evaluation of the cells.

#### ***OralCDx® Brush Test CDx Diagnostics***

The brush biopsy, oral exfoliative cytology, is considered an adjunct diagnostic tool which uses a patented spiral-shaped stiff brush to remove epithelial cells for examination by a pathologist. The brush is firmly rolled over the lesion until bleeding points are observed signaling the epithelial tissues have been penetrated. The brush retrieves cells from all three tissue layers. The cells caught on the brush are smeared on a glass slide and then fixed with the provided alcohol-based fixative. The brush itself is placed in a vial of fixative and then both the slide and the brush are sent to the company for a computer-assisted specimen analysis. The brush biopsy cannot render a definitive diagnosis, but will give the practitioner more conclusive evidence of further abnormalities such as abnormal cells that have been detected. The results are classified as inadequate, negative, atypical or positive. An example for the use of such tests would be as a way to differentiate between white lesions caused by hyperkeratosis and those that are of a more serious nature. The test is also beneficial in persuading the patient that a biopsy is necessary since a patient may be reluctant to proceed directly to a scalpel biopsy. While false positives can occur, any positive result would warrant a surgical biopsy. Since false negative results can also occur negative results should be followed to ensure the lesions resolve. See [OralCDx.com](http://OralCDx.com).

## **Direct Autofluorescence Visualization Technology**

### **VELscope VX®**

The VELscope VX® is a hand held device that uses an appropriate wavelength of light to excite the fluorophores that exist in living tissues causing them to fluoresce, or emit their own light. Normal, healthy tissue will appear pale green when exposed to the emitted blue light, abnormal tissue will be darker green to black. Alterations in tissue autofluorescence have been observed in OSCC. The manufacturers also claim detection of viral, fungal and bacterial infections, Inflammation from a variety of causes (including lichen planus and other lichenoid reactions), squamous papillomas and salivary gland tumors. No pre-rinse is used with this adjunct. The device has been found useful especially to delineate surgical margins that may extend beyond the visible lesion margins. When there is a high degree of inflammation, such as in the case of lichen planus, mucous membrane pemphigoid, pemphigus vulgaris, lupus, varix, etc. or when an amalgam tattoo is present the tissue may appear dark; thereby, producing a false positive result. Any type of inflammatory process such as cheek chewing, etc. will also exhibit a darker color change. See [VelScope.com](http://VelScope.com).

### **OralID™**

Developed in 2013, the OralID™ is a light-based diagnostic adjunct. The device is a hand-held instrument that emits a blue light which is shined directly into the patient's mouth. The device requires goggles and other eyewear that are included. Accessories for taking clinical images with either cameras or cell phones can be purchased separately. The device works on the principle of autofluorescence and shows areas of abnormality as dark blue. The company purports that this device may help detect oral cancer, pre-cancer and other abnormal tissue changes at an earlier stage. No rinses or dyes are used. See [OralID.com](http://OralID.com).

### **ViziLite Plus STM® with TBlue® (toluidine blue)**

The ViziLite Plus device has several components: ViziLite® Lightstick, and TBlue® dye

rinse swab. The patient rinses with one percent acetic acid for 30-60 seconds followed by the use of a chemiluminescence light. The light stick is especially beneficial in identifying white and erythroleukoplakia lesions. After the light stick is broken and shaken, it is placed next to all visible oral soft tissue surfaces. The device will cause illumination of any leukoplakia and/or erythroleukoplakia lesions causing them to appear bright white. TBlue is a part of the soft tissue management system and contains pharmaceutical grade toluidine chloride, which is a toluidine-blue dye that stains the epithelial cell's nuclear material blue. The use of the TBlue assists in further delineating the extent or margins of any detected lesions. A complete guide to the various products can be found on the Den-Mat site using the link to [Vizilite](http://Vizilite.com). This is an FDA approved product.

### **Identafi® Multi-Spectral, Oral Cancer Screening**

First released to the market in 2009, now manufactured and sold by Henry Schein®, the portable AA rechargeable battery-operated Identafi aluminum plated handpiece emits safe white, violet and amber wavelengths of light into the mouth which stimulates the fluorophores (natural molecules found within tissue that emit light when exposed to specific wavelengths of light) within the superficial mucosa tissues, causing them to emit a fluorescent blue glow when viewed through glasses fit with special optical filters. The handpiece and attached angled mouth mirror are covered by a disposable plastic sheath. The light source is emitted through the plastic sheath next to the mirror. As with the VELscope®, this device allows the clinician to view the different fluorescence responses of healthy versus abnormal oral tissue. Viewed with the violet light from this system, healthy tissues will appear bright green while suspicious areas will appear dark.

The device has a white, violet and amber light setting. The white light setting is used to enhance the clinician's normal cancer examination. When abnormalities are present the selector is then switched to amber light that enhances the normal tissue's reflectance properties so the clinician can view the vascular

architecture. Studies indicate that abnormal tissue has a diffuse vasculature as opposed to the more clearly defined vasculature of normal tissue. A combination of fluorescence and reflectance uses the body's natural tissue properties as an adjunctive tool for oral mucosal examination. The latter wavelength, according to the manufacturer, allows the clinician to evaluate the blood vessels feeding the suspicious area to help reduce false positives. See [Identifi](#)<sup>®</sup>.

### **DentLight D.O.E.™**

The portable, lithium rechargeable battery-operated handpiece emits a safe blue wavelength of light into the mouth stimulating the fluorophores within the superficial mucosa tissues, causing them to emit a fluorescent green glow when viewed through supplied optical loupes with special flip-down optical filters. Viewed with this system, healthy tissues will appear bright green while suspicious areas will appear dark. The handpiece utilizes the manufacturer's composite curing light (Fusion<sup>®</sup>) with a removal attachment head. Both a white light and blue light attachment come with the kit. The handpiece has a LCD display with a variable activation timer (range 5-20 seconds in 5 second increments) and a manual mode. Note: if the clinician already owns the Fusion light curing system the two additional attachments can be purchased at a reduced price. See [DentLight](#).

### **Salivary Test SaliMark™**

Current research is in process that would detect markers in saliva as biomarkers for oral cancer. Both the research that has been conducted and the future of such tests are very promising not only for oral cancer but for other diseases states as well. See PeriRx.

### **Radiographs and Oral Photography**

Radiographs and oral photography are important adjuncts which can be utilized to compare changes in tissue. Photography is especially beneficial in cases where severe inflammation is present. Some of the adjunct devices can identify inflammation in the soft tissues but they cannot differentiate between inflammation caused by, for example,

cheek biting or lichen planus. At the same time, because inflammation is a constant in some cases, frequent biopsy may not be appropriate since constant biopsies are not the optimal form of patient management. Often tissue specimens return with a "non-specific ulcerative tissue" diagnosis and crucial areas may be missed due to excessive inflammation. Being able to compare digital images of the lesion provides the practitioner the added benefit of actually seeing the progression or extension of the lesion. An added benefit is being able to show the patient how the lesion has progressed over time when suggesting they need to have a biopsy. Oral photography is highly beneficial as a key part of the patient's permanent record as well. Radiographs can be used to determine if a lesion seen on the surface of the oral tissues actually extends into the bone or other hard structures adding another dimension to the diagnostic process. Radiographs are also important in assessing both hard and soft tissue lesions within the oral cavity that may not be visible during the standard oral cancer exam. Periodic radiographs may find pathology and lesions at a much earlier existence when treatment may be far less invasive for a patient. The American Cancer Society provides an extensive review of the current staging of oral lesions that have been detected with information about the spread of oral cancer or the recurrence.<sup>60</sup>

### **STATICYTE (Proteocyte AI)**

The early diagnosis of oral squamous cell carcinoma (OSCC) is the ultimate goal in dentistry today. Mouth cancer affects an estimated 450+ individuals worldwide each year. The deaths resulting from oral epithelial dysplasia which reach the OSCC classification present the patient with major surgery and even death. STATICYTE has developed a new method assessing a protein called S100A7. This biomarker is linked to the risk of developing oral cancer and may provide an objective way to assess whether the OED might result in cancer. This method allows the patient to understand their own risks and assists in making decisions going forward about their treatment.<sup>61</sup> See [STATICYTE](#)

## Conclusion

This course has been presented to enhance the skills of practicing dentists and hygienists. We learn to perform a complete exam during our educational programs, but the ideal clinical environment and expectations sometimes change the further away we get from those formative years. The sequence may change, how we remember key points may become vague and the pressure to keep a schedule makes the oral cancer examination less likely to be performed in its entirety. This CE course has been presented in a logical sequence with key points related to normal and abnormal findings. We have also included some documents that may be used in an office to make the patient aware that a complete oral cancer examination has been performed:

- **Appendix A. Your Oral Cancer Examination** – A form that may be used stating that the dental professional has just performed an oral cancer examination as part of the dental office visit. Check off the appropriate boxes on the form and fill in the required information. Inform the patient what changes to watch for if the “Watch area for changes” box is checked and tell them what to do if changes are noted. If the “Follow-up dental appointment required” box is checked write in when the appointment should be scheduled, 2 weeks, 2 months, 3 months etc. Describe changes the patient might see if the area being watched begins to progress and tell them to contact the office immediately if these changes are seen. Inform the patient that if they think the area has returned to normal they should still return for the follow-up appointment to confirm the status of the previous lesion. If a “referral required” box

is checked briefly describe the condition the patient is being referred for and to whom they are being referred. Inform them that additional forms containing detailed information about the condition for which they are being referred will be sent to the healthcare provider of their choice.

- **Appendix B. Oral Cancer Examination Physician Referral** – A form that may be used when a condition requires further evaluation by a physician.
- **Appendix C. Oral Pathologist/Oral Surgeon/Oral Medicine Referral Form** – A form that may be used when a condition requires further evaluation by an oral pathologist, oral medicine practitioner or an oral surgeon. Sending a clinical image of the area in question to an oral pathologist is a true gift! The image provides an added element that will enhance the final diagnosis.

Everyone will have their own techniques and approaches to an oral cancer examination; however, telling the patient what is being performed is a key element of the total exam. Since many patients do not know they are receiving an oral cancer examination, we believe that this point should be emphasized. Some offices give patients a button/brochure stating that they have had an oral cancer examination; thereby, calling attention to the fact that the examination is vitally important. The Oral Cancer Foundation provides a lighted tongue blade and instruction on examining the mouth for patients and also buttons that can be given to patients indicating that they have had an oral cancer exam. The buttons can be obtained from the Oral Cancer Foundation Store at (<http://www.oralcancer.org>).<sup>42</sup>

# Appendix A. Your Oral Cancer Examination

## Your Oral Cancer Examination

Your dental professional has just performed an oral cancer examination as part of your dental visit today. Our dental practice conforms to the standards set by the American Dental Association and the American Dental Hygienists' Association that recognize this service as a critical element in disease prevention and health promotion that should be performed at routine dental visits. The results of this examination are being provided to you for your personal health record.

**Head and neck examination:**

- No findings
  
- Watch area for changes
  
- Referral required

**Oral examination:**

- No findings
  
- Follow-up dental appointment required
  
- Referral required

If the results of your examination are negative, we suggest that you continue to look at your own mouth using the checklist provided with the Oral Self-Exam Technique you have been shown and report any changes or suspicious areas to us for evaluation.

We emphasize the importance of returning for a follow-up visit to find out whether findings have improved, stayed the same, gone away or gotten worse, and if you need further treatment.

We will provide help with referrals and we stress the importance of completing the referral to find out what is causing the condition we found.

Thank you for allowing us to care for you.

Dr. \_\_\_\_\_

Address: \_\_\_\_\_

Phone Number: \_\_\_\_\_

# Appendix B. Oral Cancer Examination Physician Referral

## Oral Cancer Examination Physician Referral

Mr./Ms./Mrs. \_\_\_\_\_ was seen in our office for a dental exam. As part of the general appraisal of all patients, we completed an extraoral and intraoral examination. Our assessment revealed an area we believe warrants further evaluation. Please see the information provided below:

Location: \_\_\_\_\_

Description: \_\_\_\_\_

Digital Image/Radiograph is attached.

From the office of:

Dr. \_\_\_\_\_

Address: \_\_\_\_\_

Phone Number: \_\_\_\_\_

Please call our office if you have any questions or need more information.

**Appendix C. Oral Pathologist/Oral Surgeon Referral Form**

Mr./Mrs./Dr. \_\_\_\_\_ was seen today in our practice.

**Age:** \_\_\_\_\_ If Child, accompanied by:  Parent  Grandparent  Other \_\_\_\_\_

**Reason for patient visit:**

- Periodic Recare
- Specific Concern

Please list details:

**Please evaluate the specific area(s) noted below for intraoral examination:**

- Lips/Perioral area
- Labial Mucosa
- Buccal Mucosa
- Vestibule
- Tongue Lateral
- Tongue Ventral
- Floor of the Mouth
- Gingiva
- Palate Anterior
- Palate Posterior
- Tongue Dorsum
- Retromolar Trigone
- Oropharynx and Tonsil Region

**Specific concerns for evaluation of head and neck area:**

- Craniofacial/Headache
- TMJ
- Upper / Med / Lower Face
  - Left  Right  Both
- Midline / Anterior / Lateral Posterior Neck
  - Left  Right  Both

**Level of pain reported by patient: (pain)**

Lowest-0 1 2 3 4 5 6 7 8 9 10-Highest

**Location of Pain Perception from above list:** \_\_\_\_\_

**Specific tooth number of pain association:** \_\_\_\_\_



## Appendix C. (continued.)

**Lesion description and history:** (measurements, color, consistency, and general impression):

**Listed below please find any relevant medication/drug history and/or medical history:**

Pertinent medical history:

Pertinent drug history:

- Digital image of lesion is attached.
- Oral digital or hard copy radiograph of lesion are attached.
- Digital or hard copy clinical image is attached.

**From the office of:**

Dr. \_\_\_\_\_

Address: \_\_\_\_\_

Phone: \_\_\_\_\_ Fax: \_\_\_\_\_

Date: \_\_\_\_\_

Please call our office if you have any further questions or need more information.

## Course Test Preview

To receive Continuing Education credit for this course, you must complete the online test. Please go to: [www.dentalcare.com/en-us/ce-courses/ce337/start-test](http://www.dentalcare.com/en-us/ce-courses/ce337/start-test)

- 1. As you examine the TM joint you notice an altered opening pathway which has its greatest distance from the midline at maximum opening. This defines which one of the following terms?**
  - A. Crepitus
  - B. Deviation
  - C. Deflection
  - D. Subluxation
  - E. Derangement
- 2. Which one of the following is usually associated with arthritis of the TM joint?**
  - A. Pop
  - B. Click
  - C. Crepitus
  - D. Bruxism
  - E. Missing teeth
- 3. All of the following structures would be noted when examining the oropharynx except one. Which one is the EXCEPTION?**
  - A. Tonsils
  - B. Adenoids
  - C. Tonsillar crypt
  - D. Anterior/posterior pillars
  - E. Posterior pharyngeal wall
- 4. Which one of the following best describes an acute infection of the tonsils?**
  - A. Post nasal drip
  - B. Enlarged tonsils
  - C. Cratered tonsils
  - D. Purulent exudate
  - E. Non-tender erythema
- 5. Compromised swallowing capabilities are associated with a higher risk of which one of the following?**
  - A. Bifid uvula
  - B. Loss of function
  - C. Aspiration of food
  - D. Candida infections
  - E. Excessively long uvula
- 6. Which one of the following techniques should be used to palpate the hard palate?**
  - A. Digital
  - B. Bidigital
  - C. Bilateral
  - D. Bimanual
  - E. Auscultation

7. **Which one of the following is a common atypical structural finding in the area of the hard palate?**
- A. Thermal burn
  - B. Torus palatinus
  - C. Mucosal abrasion
  - D. Nicotine stomatitis
  - E. Papillary hyperplasia
8. **Stensen's duct is associated with which of the following glands?**
- A. Buccal
  - B. Parotid
  - C. Sublingual
  - D. Submandibular
  - E. Sublingual caruncle
9. **Which one of the following conditions would be considered pathologic?**
- A. Linea alba
  - B. Varicosities
  - C. Leukoedema
  - D. Erythroplakia
  - E. Fordyce's granules
10. **Which one of the techniques listed below would be appropriate for palpating the buccal and labial mucosa?**
- A. Digital
  - B. Bidigital
  - C. Bilateral
  - D. Bimanual
  - E. Unilateral
11. **When examining the body of the mandible you would use the mouth mirror to stretch the mucosal tissues away from the inferior border, BECAUSE you might miss a lesion which is obscured by a fold of tissue.**
- A. Both the statement and the reason are correct and related.
  - B. Both the statement and the reason are correct but NOT related.
  - C. The statement is correct but the reason is not.
  - D. The statement is NOT correct, but the reason is correct.
  - E. NEITHER the statement NOR the reason is correct.
12. **Which of the following is NOT a common atypical finding in the body of the mandible and retromolar area?**
- A. Tori
  - B. Scarring
  - C. Pericoronitis
  - D. Hyperkeratosis
  - E. Partially erupted third molars

- 13. Which one of the techniques listed below should be used when palpating the structures of the floor of the mouth?**
- A. Digital
  - B. Bidigital
  - C. Bilateral
  - D. Bimanual
  - E. Finger and thumb of the same hand
- 14. The \_\_\_\_\_ is the most common intraoral site for oral cancer development.**
- A. uvula
  - B. tongue
  - C. hard palate
  - D. buccal mucosa
  - E. floor of the mouth
- 15. Which of the following findings associated with the tongue is caused by an error in development?**
- A. Fissuring
  - B. Scalloping
  - C. Hairy tongue
  - D. Plica fimbriata
  - E. Lingual thyroid
- 16. Which one of the following adjunct devices might be used to help determine surgical margins when removing or biopsying a suspicious lesion?**
- A. Identafi 3000 Ultra
  - B. OralDx® Brush Test
  - C. ViziLite
  - D. VELscope
  - E. Liquid-Based Cytology
- 17. Which of the following is NOT a consideration in the perception of oral dryness?**
- A. Amount of saliva actually present
  - B. Amount of serous saliva
  - C. Amount of mucous saliva
  - D. Salt/calcium composition of the saliva
  - E. Consistency of the saliva
- 18. Which of the following examination findings would be considered atypical?**
- A. Stippled gingiva
  - B. Fordyce granules
  - C. Leukoedema
  - D. Two mms of attached gingiva
  - E. Both B and C
- 19. Nutritional deficiencies, Candida albicans, human herpes virus and lesions associated with loss of dimension are common to which one of the following structures/areas?**
- A. Tongue
  - B. Hard palate
  - C. Commissures
  - D. Floor of the mouth
  - E. Pharyngeal pillars

- 20. A symblepharon discovered during an extraoral exam would be found in or on which one of the following?**
- A. Ear
  - B. Nose
  - C. Neck
  - D. Eye
  - E. Lip
- 21. The patient with a symblepharon would be referred to which one of the following specialists?**
- A. Oral surgeon
  - B. Oral pathologist
  - C. Immunology specialist
  - D. Ophthalmologist
  - E. Dermatologist
- 22. Which one of the following known cancer risk factors cannot be lowered or modified by a change in lifestyle or behavior?**
- A. Alcohol
  - B. Tobacco
  - C. Diet
  - D. Age
  - E. Sunlight
- 23. Patients with known risk factors for cancer should be screened at \_\_\_\_\_.**
- A. normal maintenance visits
  - B. more frequent intervals
  - C. any time that an abnormality is noticed by the patient
  - D. yearly visits
  - E. every visit and encouraged to perform self-exams and report any abnormality
- 24. Which one of the following viruses is associated with a significant increase in oropharyngeal cancers?**
- A. HIV
  - B. HPV
  - C. HCV
  - D. HBV
  - E. CMV
- 25. What percentage of oropharyngeal cancers are squamous cell carcinomas?**
- A. 10%
  - B. 30%
  - C. 60%
  - D. 80%
  - E. 90%
- 26. Which of the following most closely describes the appearance of oral cancer?**
- A. White lesion
  - B. Red and white lesion
  - C. Pigmented lesion
  - D. Ulcer-like lesion
  - E. Any of the above.

- 27. Salivary gland tumors, lymphoma, and sarcoma-related cancers comprise what percentage of oropharyngeal cancers?**
- A. 10%
  - B. 20%
  - C. 30%
  - D. 40%
  - E. 50%
- 28. Which of the following is a common reason for failing to detect oral cancer in a young person?**
- A. Oral tissues appear more suspicious in the older person.
  - B. Young people do not seek treatment as readily as older populations.
  - C. Clinicians do not suspect cancerous changes in young individuals.
  - D. Cancer does not progress as rapidly with young individuals.
  - E. Younger individuals usually develop cancer in the tonsil region making it virtually undetectable.
- 29. Debris tends to collect in tonsils affected by which one of the following conditions?**
- A. Erythema
  - B. Tonsillitis
  - C. Streptococcal infection
  - D. Cratered and cryptic tissue
  - E. Cancer
- 30. Which one of the following is the most common site for cancer to develop on the tongue?**
- A. Dorsal surface
  - B. Circumvallate papillae
  - C. Lateral border
  - D. Tip of the tongue
  - E. Ventral surface

## References

1. Ms. Casey Buentello, RDH, Ms. Buentello was a senior dental hygiene student at Lamar Institute of Technology in Beaumont, Texas when these photographs were taken. Ms. Buentello is the patient depicted in most of the images.
2. Ms. Elizabeth Carter, RDH, was a senior dental hygiene student at Lamar Institute of Technology in Beaumont, Texas when these photographs were taken. Ms. Carter performed the role of operator in most of the images.
3. Ms. Ruth Fearing-Tornwall, Associate Professor of Dental Hygiene at Lamar Institute of Technology in Beaumont, Texas. Ms. Tornwall provided much needed technical assistance with setting up and posing the patient and operator for each of the images.
4. SEER Cancer Stat Facts: Oral Cavity and Pharynx Cancer. National Cancer Institute. Bethesda, MD. Accessed February 10, 2025.
5. Howlader N, Chen HS, Noone AM, Miller D, Byrne J, Negoita S, Cronin KA, Mariotto AB. Impact of COVID-19 on 2021 cancer incidence rates and potential rebound from 2020 decline. *J Natl Cancer Inst.* 2025 Mar 1;117(3):507-510. doi: 10.1093/jnci/djae180. PMID: 39316386; PMCID: PMC11884841. Accessed February 1, 2022.
6. American Cancer Society. Cancer Statistics 2025. Accessed February 10, 2025.
7. Rethman MP, Carpenter W, Cohen EE, et al. Evidence-based clinical recommendations regarding screening for oral squamous cell carcinomas. *J Am Dent Assoc.* 2010 May;141(5):509-20. doi: 10.14219/jada.archive.2010.0223.
8. Sung H, Ferlay J, Siegel RL, et al. Global Cancer Statistics 2020: GLOBOCAN Estimates of Incidence and Mortality Worldwide for 36 Cancers in 185 Countries. *CA Cancer J Clin.* 2021 May;71(3):209-249. doi: 10.3322/caac.21660. Epub 2021 Feb 4.
9. US Preventive Services Task Force. Screening and Preventive Interventions for Oral Health in Children and Adolescents Aged 5 to 17 Years: US Preventive Services Task Force Recommendation Statement. *JAMA.* 2023;330(17):1666–1673. doi:10.1001/jama.2023.21408.
10. Straughan AJ, Zapanta PE, Goodman JF. Building Community Relations and Promoting Cancer Prevention: An Oral Cancer Screening Event. *Otolaryngol Head Neck Surg.* 2020 Dec;163(6):1073-1075. doi: 10.1177/0194599820942464. Epub 2020 Jul 14.
11. Oral Cancer Screening Clinical Practice Statement: American Academy of Oral Medicine.
12. Walsh T, Liu JL, Brocklehurst P, et al. Clinical assessment to screen for the detection of oral cavity cancer and potentially malignant disorders in apparently healthy adults. *Cochrane Database Syst Rev.* 2013 Nov 21;2013(11):CD010173. doi: 10.1002/14651858.CD010173.pub2. Update in: *Cochrane Database Syst Rev.* 2021 Dec 10;12:CD010173.
13. Burzynski NJ, Rankin KV, Silverman S Jr, Scheetz JP, Jones DL. Graduating dental students' perceptions of oral cancer education: results of an exit survey of seven dental schools. *J Cancer Educ.* 2002 Summer;17(2):83-4. doi: 10.1080/08858190209528804.
14. Zhang X, Liu D, Dong H, Li Y, Zhang Y, Wang X, Zhang B, Bian L. Factors associated with delay in presentation among patients for oral cancer. *J Comp Eff Res.* 2019 Sep;8(12):1003-1071. doi: 10.2217/cer-2019-0067. Epub 2019 Jul 10.
15. Väisänen JA, Syrjälä AM, Pesonen PR, et al. Characteristics and medical-care-seeking of head and neck cancer patients: a population-based cross-sectional survey. *Oral Oncol.* 2014 Aug;50(8):740-5. doi: 10.1016/j.oraloncology.2014.04.009. Epub 2014 May 21.
16. Tromp DM, Brouha XD, Hordijk GJ, Winnubst JA, de Leeuw JR. Patient factors associated with delay in primary care among patients with head and neck carcinoma: a case-series analysis. *Fam Pract.* 2005 Oct;22(5):554-9. doi: 10.1093/fampra/cm1058. Epub 2005 Jul 8.
17. DeLong L, Burkhart NW. *General and Oral Pathology for the Dental Hygienist* 2nd ed. Wolters Kluwer/Lippincott Williams & Wilkins. Philadelphia, PA. 2013.
18. U.S. Department of Health and Human Services. Administration on Aging (AoA). *A Profile of Older Americans: 2020.* Accessed March 19, 2025.
19. Lynch DP, Oral cancer risk and detection. The importance of screening technology. *RDH* 2007 Sep;27(9):1010-112. Accessed February 15, 2025.

20. Schantz SP, Yu GP. Head and neck cancer incidence trends in young Americans, 1973-1997, with a special analysis for tongue cancer. *Arch Otolaryngol Head Neck Surg.* 2002 Mar;128(3):268-74. doi: 10.1001/archotol.128.3.268.
21. Chaturvedi AK, Engels EA, Pfeiffer RM, et al. Human papillomavirus and rising oropharyngeal cancer incidence in the United States. *J Clin Oncol.* 2011 Nov 10;29(32):4294-301. doi: 10.1200/JCO.2011.36.4596. Epub 2011 Oct 3.
22. Centers for Disease Control and Prevention (CDC). Oral and Dental Health. Dental Visits. Accessed February 1, 2022.
23. Siegel RL, Miller KD, Fuchs HE, Jemal A. Cancer Statistics 2022. *CA CANCER J CLIN* 2022;72(1):7-33. doi: 10.3322/caac.21708. Accessed February 1, 2022.
24. Cotter JC, McCann AL, Schneiderman ED, De Wald JP, Campbell PR. Factors affecting the performance of oral cancer screenings by Texas dental hygienists. *J Dent Hyg.* 2011 Fall;85(4):326-34. Epub 2011 Nov 11.
25. Horowitz AM, Siriphant P, Canto MT, Child WL. Maryland dental hygienists' views of oral cancer prevention and early detection. *J Dent Hyg.* 2002 Summer;76(3):186-91.
26. Forrest JL, Horowitz AM, Shmueli Y. Dental hygienists' knowledge, opinions, and practices related to oral and pharyngeal cancer risk assessment. *J Dent Hyg.* 2001 Fall;75(4):271-81.
27. Tax CL, Haslam SK, Brilliant M, Doucette HJ, Cameron JE, Wade SE. Oral cancer screening: knowledge is not enough. *Int J Dent Hyg.* 2017 Aug;15(3):179-186. doi: 10.1111/idh.12172. Epub 2015 Aug 30. screening : knowledge is not enough. *Int J Dent Hyg.* 2017; Aug;15:3: 179-186.
28. Pavão Spaulonci G, Salgado de Souza R, Gallego Arias Pecorari V, Lauria Dib L. Oral Cancer Knowledge Assessment: Newly Graduated versus Senior Dental Clinicians. *Int J Dent.* 2018 Feb 14;2018:9368918. doi: 10.1155/2018/9368918.
29. Brocklehurst P, Pemberton MN, Macey R, Cotton C, Walsh T, Lewis M. Comparative accuracy of different members of the dental team in detecting malignant and non-malignant oral lesions. *Br Dent J.* 2015 May 8;218(9):525-9. doi: 10.1038/sj.bdj.2015.344.
30. Daley EM, Thompson EL, Vamos CA, Griner SB, Vazquez-Otero C, Best AL, Kline NS, Merrell LK. HPV-Related Knowledge Among Dentists and Dental Hygienists. *J Cancer Educ.* 2018 Aug;33(4):901-906. doi: 10.1007/s13187-016-1156-5.
31. Kerr AR, Robinson ME, Meyerowitz C, Morse DE, Aguilar ML, Tomar SL, Guerrero L, Caprio D, Kaste LM, Makhija SK, Mungia R, Rasubala L, Psoter WJ; National Dental PBRN Collaborative Group. Cues used by dentists in the early detection of oral cancer and oral potentially malignant lesions: findings from the National Dental Practice-Based Research Network. *Oral Surg Oral Med Oral Pathol Oral Radiol.* 2020 Sep;130(3):264-272. doi: 10.1016/j.oooo.2020.05.007. Epub 2020 May 23. PMID: 32561250; PMCID: PMC8256887.
32. Patton LL, Agans R, Elter JR, Southerland JH, Strauss RP, Kalsbeek WD. Oral cancer knowledge and examination experiences among North Carolina adults. *J Public Health Dent.* 2004 Summer;64(3):173-80. doi: 10.1111/j.1752-7325.2004.tb02748.x.
33. Lingen MW, Abt E, Agrawal N, et al. Evidence-based clinical practice guideline for the evaluation of potentially malignant disorders in the oral cavity: A report of the American Dental Association. *J Am Dent Assoc.* 2017 Oct;148(10):712-727.e10. doi: 10.1016/j.adaj.2017.07.032.
34. Tomar SL, Logan HL. Florida adults' oral cancer knowledge and examination experiences. *J Public Health Dent.* 2005 Fall;65(4):221-30. doi: 10.1111/j.1752-7325.2005.tb03022.x.
35. Bigelow C, Patton LL, Strauss RP, Wilder RS. North Carolina dental hygienists' view on oral cancer control. *J Dent Hyg.* 2007 Fall;81(4):83. Epub 2007 Oct 1.
36. National Cancer Institute. Surveillance, Epidemiology and End Results Program. SEER Stat Fact Sheets: Oral Cavity and Pharynx Cancer. Accessed February 1, 2025.
37. Sciubba JJ. Oral cancer and its detection. History-taking and the diagnostic phase of management. *J Am Dent Assoc.* 2001 Nov;132 Suppl:12S-18S. Erratum in: *J Am Dent Assoc* 2002 Apr;133(4):422.
38. Ling H, Gadalla S, Israel E, Langenberg P, Zhan M, Dwyer DM, Groves C, Hopkins A, Steinberger EK. Oral cancer exams among cigarette smokers in Maryland. *Cancer Detect Prev.* 2006;30(6):499-506. doi: 10.1016/j.cdp.2006.10.005. Epub 2006 Nov 20.



39. Young D, Xiao CC, Murphy B, Moore M, Fakhry C, Day TA. Increase in head and neck cancer in younger patients due to human papillomavirus (HPV). *Oral Oncol.* 2015 Aug;51(8):727-30. doi: 10.1016/j.oraloncology.2015.03.015. Epub 2015 Jun 9.
40. Anderson KS, Dahlstrom KR, Cheng JN, et al. HPV16 antibodies as risk factors for oropharyngeal cancer and their association with tumor HPV and smoking status. *Oral Oncol.* 2015 Jul;51(7):662-7. doi: 10.1016/j.oraloncology.2015.04.011. Epub 2015 May 6.
41. American Academy of Dermatology. Melanoma. Accessed February 15, 2025.
42. National Cancer Institute. Accessed February 15, 2025.
43. Kondori I, Mottin RW, Laskin DM. Accuracy of dentists in the clinical diagnosis of oral lesions. *Quintessence Int.* 2011 Jul-Aug;42(7):575-7.
44. The Oral Cancer Foundation. Accessed February 15, 2025.
45. Rowan SD, Hu SL, Brotzman JS, Redding SW, Rankin KV, Vigneswaran N. Knowledge Assessment of the Dental Community in Texas on the Role of Human Papilloma Virus in Oropharyngeal Cancer. *Tex Dent J.* 2015 Aug;132(8):528-36.
46. Shukla A, Nyambose J, Vanucci R, Johnson LB, Welch K, Lind E, Villa A. Evaluating the Effectiveness of Human Papillomavirus Educational Intervention among Oral Health Professionals. *J Cancer Educ.* 2019 Oct;34(5):890-896. doi: 10.1007/s13187-018-1391-z.
47. Mouth Healthy/ADA: HPV and Oral Cancer. Accessed February 1, 2022.
48. ADA Research: American Dental Association. March 19, 2025.
49. Ferlay J, Soerjomataram I, Dikshit R, et al. Cancer incidence and mortality worldwide: sources, methods and major patterns in GLOBOCAN 2012. *Int J Cancer.* 2015 Mar 1;136(5):E359-86. doi: 10.1002/ijc.29210. Epub 2014 Oct 9.
50. Castellsagué X, Alemany L, Quer M, et al. HPV Involvement in Head and Neck Cancers: Comprehensive Assessment of Biomarkers in 3680 Patients. *J Natl Cancer Inst.* 2016 Jan 28;108(6):djv403. doi: 10.1093/jnci/djv403.
51. Sung H, Ferlay J, Siegel RL, et al. Global Cancer Statistics 2020: GLOBOCAN Estimates of Incidence and Mortality Worldwide for 36 Cancers in 185 Countries. *CA Cancer J Clin.* 2021 May;71(3):209-249. doi: 10.3322/caac.21660. Epub 2021 Feb 4.
52. Horowitz AM, Drury TF, Goodman HS, Yellowitz JA. Oral pharyngeal cancer prevention and early detection. Dentists' opinions and practices. *J Am Dent Assoc.* 2000 Apr;131(4):453-62. doi: 10.14219/jada.archive.2000.0201.
53. Llewellyn CD, Johnson NW, Warnakulasuriya S. Factors associated with delay in presentation among younger patients with oral cancer. *Oral Surg Oral Med Oral Pathol Oral Radiol Endod.* 2004 Jun;97(6):707-13. doi: 10.1016/j.tripleo.2004.01.007.
54. Massano J, Regateiro FS, Januário G, Ferreira A. Oral squamous cell carcinoma: review of prognostic and predictive factors. *Oral Surg Oral Med Oral Pathol Oral Radiol Endod.* 2006 Jul;102(1):67-76. doi: 10.1016/j.tripleo.2005.07.038. Epub 2006 Jan 10.
55. Rhodus NL. Oral Cancer Update: 2017. *Northwest Dent.* 2017 Jan;96(1):21-3, 25-7. PMID: 30549746.
56. Siegel MA, Kahn MA, Palazzolo MJ. Oral cancer: a prosthodontic diagnosis. *J Prosthodont.* 2009 Jan;18(1):3-10. doi: 10.1111/j.1532-849X.2008.00373.x.
57. Silverman S Jr. Demographics and occurrence of oral and pharyngeal cancers. The outcomes, the trends, the challenge. *J Am Dent Assoc.* 2001 Nov;132 Suppl:7S-11S. doi: 10.14219/jada.archive.2001.0382.
58. Warren-Morris D, Wade P. Oral cancer exams: Does your practice pass? *Tex Dent J.* 2006 Jun;123(6):494-9.
59. Chiang CP, Yu-Fong Chang J, Wang YP, Wu YH, Lu SY, Sun A. Oral lichen planus - Differential diagnoses, serum autoantibodies, hematinic deficiencies, and management. *J Formos Med Assoc.* 2018 Sep;117(9):756-765. doi: 10.1016/j.jfma.2018.01.021. Epub 2018 Feb 19.
60. Oral Cavity and Oral Pharyngeal Cancer Stages: American Cancer Society.
61. Understanding oral epithelial dysplasia and its link to cancer.

## Additional Resources

- Sung H, Ferlay J, Siegel RL, et al. Global Cancer Statistics 2020: GLOBOCAN Estimates of Incidence and Mortality Worldwide for 36 Cancers in 185 Countries. *CA Cancer J Clin*. 2021 May;71(3):209-249. doi: 10.3322/caac.21660. Epub 2021 Feb 4.
- Horowitz AM, Drury TF, Goodman HS, Yellowitz JA. Oral pharyngeal cancer prevention and early detection. Dentists' opinions and practices. *J Am Dent Assoc*. 2000 Apr;131(4):453-62. doi: 10.14219/jada.archive.2000.0201.
- Llewellyn CD, Johnson NW, Warnakulasuriya S. Factors associated with delay in presentation among younger patients with oral cancer. *Oral Surg Oral Med Oral Pathol Oral Radiol Endod*. 2004 Jun;97(6):707-13. doi: 10.1016/j.tripleo.2004.01.007.
- Massano J, Regateiro FS, Januário G, Ferreira A. Oral squamous cell carcinoma: review of prognostic and predictive factors. *Oral Surg Oral Med Oral Pathol Oral Radiol Endod*. 2006 Jul;102(1):67-76. doi: 10.1016/j.tripleo.2005.07.038. Epub 2006 Jan 10.
- Rhodus NL. Oral cancer: Early detection and prevention. *Inside Dentistry*. 2007 Jan;(3)1.
- Siegel MA, Kahn MA, Palazzolo MJ. Oral cancer: a prosthodontic diagnosis. *J Prosthodont*. 2009 Jan;18(1):3-10. doi: 10.1111/j.1532-849X.2008.00373.x.
- Silverman S Jr. Demographics and occurrence of oral and pharyngeal cancers. The outcomes, the trends, the challenge. *J Am Dent Assoc*. 2001 Nov;132 Suppl:7S-11S. doi: 10.14219/jada.archive.2001.0382.
- Warren-Morris D, Wade P. Oral cancer exams: Does your practice pass? *Tex Dent J*. 2006 Jun;123(6):494-9.
- Chiang CP, Yu-Fong Chang J, Wang YP, Wu YH, Lu SY, Sun A. Oral lichen planus - Differential diagnoses, serum autoantibodies, hematitic deficiencies, and management. *J Formos Med Assoc*. 2018 Sep;117(9):756-765. doi: 10.1016/j.jfma.2018.01.021. Epub 2018 Feb 19.
- National Cancer Institute: <https://www.cancer.gov/about-cancer/causes-prevention/risk/infectious-agents/hpv-and-cancer>.
- The Cleveland Clinic: Head and Neck Cancer <https://my.clevelandclinic.org/health/diseases/14458-head-and-neck-cancer>

## Acknowledgements

Our thanks are extended to the following individuals for their help in the production of this course.

- Ms. Casey Buentello, RDH, Ms. Buentello was a senior dental hygiene student at Lamar Institute of Technology in Beaumont, Texas when these photographs were taken. Ms. Buentello is the patient depicted in most of the images.
- Ms. Elizabeth Carter, RDH, was a senior dental hygiene student at Lamar Institute of Technology in Beaumont, Texas when these photographs were taken. Ms. Carter performed the role of operator in most of the images.
- Ms. Ruth Fearing-Tornwall, Associate Professor of Dental Hygiene at Lamar Institute of Technology in Beaumont, Texas. Ms. Tornwall provided much needed technical assistance with setting up and posing the patient and operator for each of the images.

## About the Authors

### **Nancy W. Burkhardt, BSDH, MEd, EdD, AFAAOM**



Dr. Burkhardt received a Bachelor of Science degree in dental hygiene from Fairleigh Dickinson University School of Dentistry, a Master of Education degree from North Carolina State University in Occupational Health Education, a Doctor of Education Degree from North Carolina State University in Adult Education/ Interdisciplinary studies. Nancy conducted a one-year postdoctoral fellowship in the section of Oral Pathology at the University of North Carolina School of Dentistry in Chapel Hill in the section of oral pathology. Her dissertation topic was "Oral Lichen Planus Commonalities: Educational and Psychological Implications." Dr. Burkhardt is an Adjunct Associate Professor and Educational Consultant in the Department of Periodontics/Stomatology at The Baylor College of Dentistry where she has been a faculty member since 1997. She is founder and faculty Co-Host of the International Oral Lichen Planus Support Group established in 1997.

Dr. Burkhardt has presented papers both nationally and internationally on Oral Lichen Planus/ Mucosal Diseases and has published articles in national dental journals. She is co-author of "General and Oral Pathology for the Dental Hygienist" published through Lippincott, Williams & Wilkins and the book is now in its 3rd edition 2018. She was a 2006 recipient of the ADHA Crest Award through Proctor & Gamble and The Philips Consumer Lifestyle and PennWell Corporation "Mentor of Distinction Award" in 2012. She is an Academic Affiliate Fellow of The American Academy of the Oral Medicine Association-awarded fellowship in 2016. Nancy is a 2017 recipient of the "Award of Distinction" through SUNSTAR and PennWell, Corporation and a 2017 "Dental Professional of the Year" recipient through The International Pemphigus and Pemphigoid Foundation. As a columnist for RDH magazine since 2007, she writes a monthly column titled, "Oral Exams/Oral Pathology" for the PennWell publication that appears in both dental and dental hygiene literature. To date, she has written more than 120 columns for the publication on oral pathology/oral medicine topics. She is a reviewer for several national dental journals and a representative on the JCDE from 2014-2018.

Email: [nburkhart@tamhsc.edu](mailto:nburkhart@tamhsc.edu)