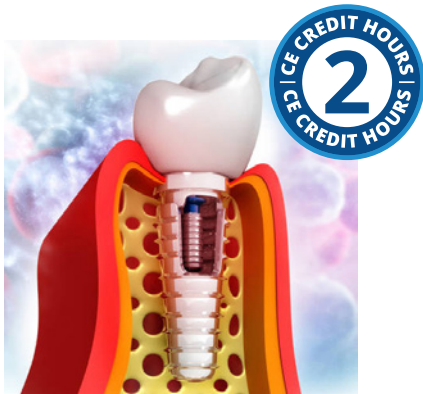

# Adjunctive Implant Surface Decontamination for Treatment of Peri-Implant Disease



**Course Author(s):** Maria L. Geisinger, DDS, MS

**CE Credits:** 2 hours

**Intended Audience:** Dentists, Dental Hygienists, Dental Students, Dental Hygiene Students

**Date Course Online:** 02/01/2019

**Last Revision Date:** 06/30/2025

**Course Expiration Date:** 06/30/2028

**Cost:** Free

**Method:** Self-instructional

**AGD Subject Code(s):** 10, 135, 690

**Online Course:** [www.dentalcare.com/en-us/ce-courses/ce696](http://www.dentalcare.com/en-us/ce-courses/ce696)

## Disclaimers:

- P&G is providing these resource materials to dental professionals. We do not own this content nor are we responsible for any material herein.
- Participants must always be aware of the hazards of using limited knowledge in integrating new techniques or procedures into their practice. Only sound evidence-based dentistry should be used in patient therapy.

## Conflict of Interest Disclosure Statement

- Dr. Geisinger does not have any conflicts of interest in regard to the topic of this course. She has no relevant financial relationships to disclose.

## Short Description – Implant Laser Therapy

Adjunctive Implant Surface Decontamination for Treatment of Peri-Implant Disease is a free dental continuing education course that covers a wide range of topics relevant to the oral healthcare professional community.

## Course Contents

- Overview
- Learning Objectives
- Introduction
- Peri-implant Health and Disease
  - Peri-implant Health
  - Peri-implant Mucositis
  - Peri-implantitis
- Risk Factors for Peri-implant Diseases
  - Systemic Diseases
  - Smoking Status and or Tobacco Cessation
  - Periodontal Health
  - Plaque Control and Adherence to Regular Supportive Implant Therapy
  - Prosthetic Design and Occlusal Load
  - Retained Cement
  - Peri-implant Soft Tissue Quality Quantity
- Current Treatment Strategies for Peri-implant Diseases
- Implant Surface Disinfection: Treatment Modalities and Effectiveness
  - Mechanical Implant Surface Decontamination
  - Chemical Implant Surface Decontamination
  - Laser Implant Surface Decontamination
  - Clinical Decision Making for Treatment of Patients with Peri-implant Diseases
- Importance of Supportive Peri-Implant Therapy
- Conclusion
- Course Test
- References
- About the Author

## Overview

This course seeks to evaluate the effectiveness of implant surface decontamination therapies for treatment of peri-implant disease.

The placement of endosseous dental implants is a well-accepted treatment option for edentulism as implants have demonstrated high survival rates over long periods of time.<sup>1</sup> Dental implants are a common and growing treatment modality and it is estimated that up to 5 million dental implants are placed each year.<sup>2</sup> While dental implant survival rates remain high, reports indicate that a significant proportion of dental implants will develop peri-implant mucositis and peri-implantitis.<sup>3-6</sup> Prevalence data for peri-implant disease is

heterogeneous, but estimates suggest that the prevalence of peri-implant mucositis and peri-implantitis range from 46-63% and 19-23%, respectively.<sup>7</sup> Inflammatory implant diseases are progressive and it has been shown that the inflammatory lesions associated with peri-implant diseases are larger than those around teeth with similar clinical presentation.<sup>8,9</sup> There are several risk factors that can lead to inflammation, peri-implant mucositis, and, later, peri-implantitis.<sup>4,10-12</sup> Systemic and environmental factors may play a secondary role in disease progression and susceptibility, but peri-implant diseases are initiated by accumulation of bacterial biofilm.<sup>4,13,14</sup> As bacterial plaque is the primary etiology for peri-implant disease, current therapies for peri-implantitis require dental plaque removal and implant surface detoxification as a critical step for successful surgical and/or nonsurgical treatment of peri-implantitis.<sup>15,16</sup> This surface detoxification has been accomplished with physical, chemical, laser therapy, and/or other means.

Treatment of peri-implantitis is unpredictable. It has been reported that even with strict supportive peri-implant therapy after active treatment for peri-implant disease, complete resolution of disease is not achieved in the majority of cases over the long term.<sup>17,18</sup> Given the paucity of evidence for efficacious treatments of peri-implant disease, it is imperative that clinicians monitor and prevent the development of inflammation and provide intervention at the earliest possible time in the disease process. Further, critical evaluation of available treatment modalities is imperative to understand best practices for treatment of implant diseases.

## Learning Objectives

**Upon completion of this course, the dental professional should be able to:**

- Understand the current scientific literature about the prevalence, etiology, and stages of peri-implant diseases.
- Recognize, assess, and develop treatment and preventative strategies for peri-implant diseases.
- Evaluate the available evidence regarding the efficacy of implant surface disinfection

treatments to be performed as a part of surgical and nonsurgical treatment of peri-implant diseases.

- Discuss risks, benefits and therapeutic options with patients prior to implant therapy or with peri-implant diseases.

## Introduction

Peri-implantitis has been defined as an inflammatory process that affects the soft and hard tissues surrounding an osseointegrated implant in function demonstrating loss of supporting marginal bone.<sup>4,19</sup> Peri-implantitis is, in many ways, an analogous disease to periodontitis, in that it affects the hard and soft tissues around implants and it is initiated by oral bacterial biofilms.<sup>10,20,21</sup> The definitive treatment of peri-implantitis may be more challenging than that of periodontitis. In a recent review of studies examining peri-implantitis treatment with at least a one-year follow up, peri-implantitis was shown to be difficult to fully resolve with up to 100% of cases recurring with some treatment modalities.<sup>15</sup> This and other reports indicate that frequent monitoring and retreatment of this chronic disease may be necessary.<sup>15,17,18</sup> Furthermore, a practitioner's ability to effectively treat peri-implantitis may differ based upon the severity of the presenting levels of attachment loss and the treatment modality used for treatment.<sup>12,15,22,23</sup> Based upon this, early intervention and preventive therapy of peri-implant diseases should be an integral part of therapy to maintaining implants in health and function.<sup>12,24</sup>

There are several risk factors that can lead to inflammation, peri-implant mucositis, and, later, peri-implantitis.<sup>4,6,10</sup> These include dental plaque accumulation, smoking, patients' systemic health conditions, implant design, surgical technique, prosthetic design/procedures, and occlusal forces.<sup>10-12</sup> While these systemic and environmental factors certainly play a role in disease progression and susceptibility, peri-implant diseases are initiated by accumulation of bacterial biofilm.<sup>4,13,14</sup> Therapies to treat peri-implant diseases have focused upon dental plaque removal and implant surface detoxification as a part of surgical and/or nonsurgical

treatments.<sup>12,16</sup> Many methods have been used to remove bacteria from dental implant surfaces and the surrounding inflamed tissues. These include: mechanical debridement, chemical detoxification, and laser therapy.<sup>25-27</sup>

## Peri-implant Health and Disease

Missing teeth and supporting structures lost to dental diseases and trauma have been replaced in myriad ways through fixed and/or removable dental prostheses. In 1977, Dr. P.I. Brånemark demonstrated that bone will integrate into the surface of endosseous titanium dental implants,<sup>28</sup> and the modern era of root form endosseous dental implantology arose. It is estimated that up to 5 million dental implants are placed in the United States each year.<sup>2</sup> While longitudinal survival rates of osseointegrated dental implants range between 90-95%,<sup>12,29</sup> these numbers represent implants that are present and in function, but may not fully capture rates of peri-implant disease and or health. It is estimated that rates of peri-implantitis range from 10-47% and rates of peri-implant mucositis have been observed in up to 65% of subjects with dental implants.<sup>30-34</sup> Furthermore, it has also been demonstrated that these peri-implant diseases are increased in patients who smoke and have a history of periodontal disease, which may increase the difficulty in treating these implants.<sup>35</sup>

Given the high prevalence of peri-implant diseases, surveillance, early identification of disease, and intervention is critical. A key factor in long-term success of implants is proper maintenance of their surrounding soft and hard tissues. It has been shown that bacterial accumulation induces inflammatory changes in the tissues surrounding implants.<sup>36</sup> Furthermore, it has been estimated that a monitoring program including regular examination and supportive implant therapy to identify and intercept peri-implant mucositis is highly cost-effective and the economic advantage is increased in high risk patients.<sup>37</sup> In order to determine proper treatment steps to intervene for an implant with signs of peri-implant disease, it is essential to identify disease as early as possible to provide intervention. Clinicians must distinguish

between “ailing” and “failing”/“failed” implants to select an appropriate intervention.

The primary etiology for both peri-implant and periodontal diseases is virulent bacterial plaque.<sup>36,38</sup> While the inflammatory process that occurs around implants is similar to that around natural teeth, progression of disease is quicker in the peri-implant environment and the histologic peri-implant inflammatory lesions are larger and may prove more difficult to resolve at implant sites.<sup>39</sup> This may relate to the peri-implant attachment apparatus and lack of a periodontal ligament as well as the unique implant-soft tissue interface.<sup>39</sup> Multiple systematic reviews and randomized controlled trials have evaluated the efficacy of various treatment strategies for peri-implant diseases and identification of one ideal treatment strategy has proven elusive.<sup>12,40,41</sup> Ideal therapy of peri-implantitis would result in active disease resolution (no suppuration, bleeding on probing, no further bone loss) and the establishment and maintenance of healthy hard and soft peri-implant tissues in a patient and clinical environment where plaque removal was feasible over time.<sup>12</sup> Studies have shown that many therapies may be used to achieve these goals including non-surgical and surgical interventions, alone or combined, including mechanical debridement, pharmaceutical therapy, laser therapy, and open flap debridement with either resective or regenerative procedures.<sup>12</sup> This discussion will focus on laser interventions as an adjunct to improve overall implant health. . Table 1 describes the clinical and histologic characteristics of peri-implant health, peri-implant mucositis, and peri-implantitis.

### **Peri-implant Health**

Healthy peri-implant mucosa is comprised by a core of connective tissue covered by either keratinized or non-keratinized mucosal epithelium. A healthy implant should demonstrate an endosseous implant surface is in contact with mineralized bone, while the remainder is associated with bone marrow, intraosseous vascular structures, and/or fibrous tissues. A healthy implant is asymptomatic and provides function in mastication, speech, and esthetics and the healthy peri-implant environment presents with an absence of clinical inflammation and progressive bone loss.<sup>43</sup>

### **Peri-implant Mucositis**

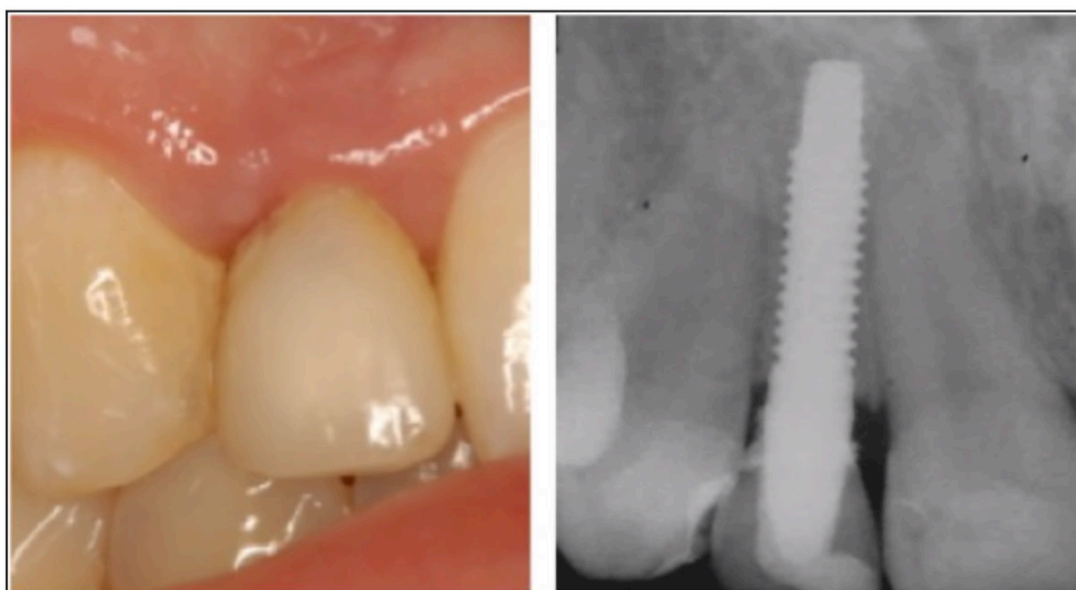Peri-implant mucositis is an inflammatory lesion confined to the soft tissues surrounding an endosseous dental implant without loss of supporting bone loss (Figure 1). While this stage of disease may still be reversible, it has been noted that the inflammatory lesion seen in experimental peri-implant mucositis is larger than that seen in experimental gingivitis of the same chronicity and that resolution of the clinical signs of peri-implant mucositis requires a longer time period than the 21-day time period required for resolution of experimental gingivitis.<sup>8</sup> This may indicate that more aggressive and/or invasive treatment may be indicated for such cases to allow for complete resolution of the defects; some authors have advocated earlier intervention, ideally as soon as disease is identified to prevent progression to bone loss and peri-implantitis.<sup>8,9,44</sup> Several factors have been identified as risk factors and/or potential risk factors for peri-implant mucositis, including plaque biofilm accumulation, smoking, head and neck radiation, diabetes mellitus/glycemic control, keratinized mucosa, and the presence of excess luting cement.<sup>10,41,45-47</sup> Successful treatment of peri-implant mucositis has been demonstrated through nonsurgical intervention consisting of supragingival and subgingival debridement with or without adjuncts such as laser and/or photodynamic therapy, locally delivered antibiotics, or chlorhexidine rinse.<sup>10</sup> Regardless of treatment modality used, oral hygiene reinforcement, assurance of adequate plaque control, and regular maintenance is crucial to treat the inflammation and prevent future loss.

### **Peri-implantitis**

Peri-implantitis is characterized by inflammation of peri-implant soft tissues and progressive loss of supporting bone that is often circumferential in nature (Figure 2).<sup>48,49</sup> Histologically, peri-implant lesions with similar clinical characteristics often have larger inflammatory lesions than periodontitis lesions around teeth.<sup>50</sup> At an implant presenting with clinical signs of inflammation and radiographic bone loss, systemic, oral and local risk factors should be assessed to determine all possible underlying etiologic factors. Initial therapy should include elimination of the etiologic factors to ensure success of reparative

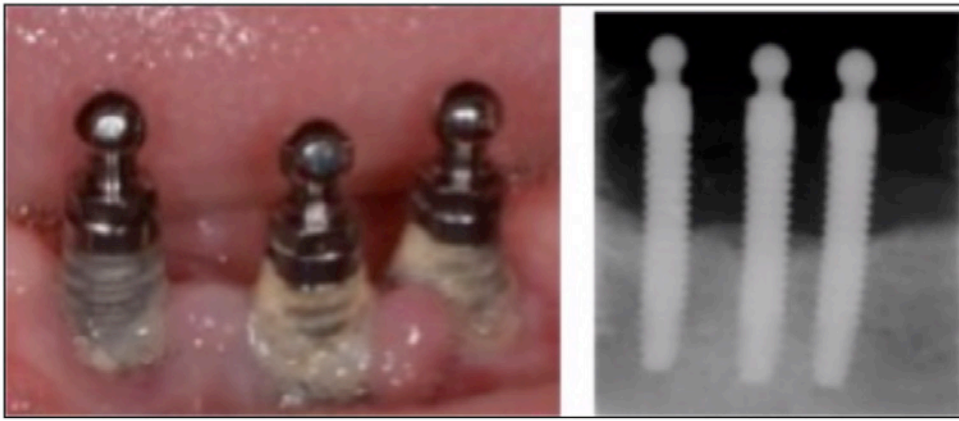**Table 1: Case definitions for peri-implant health, peri-implant mucositis, and peri-implantitis<sup>46</sup>**

	Peri-implant health	Peri-implant mucositis	Peri-implantitis
<b>Definition</b>	Implant without signs and symptoms of disease at either the soft or hard tissue attachment and without noted pathology	Reversible inflammation of the soft tissue mucosal attachment around dental implants without concomitant bone loss	An inflammatory lesion around dental implants that affects the soft and hard tissue attachment and characterized by bone loss.
<b>Visual Inspection</b>	No noted erythema No noted edema Firm mucosal consistency	Erythema may be present Edema may be present Soft mucosal consistency	Erythema may be present Edema may be present Soft mucosal consistency
<b>Patient-Reported Signs/Symptoms</b>	No pain No paresthesia No loss of function	Patients may report pain	Patients may report pain
<b>Bleeding Upon Probing</b>	Lack of profuse bleeding on probing.	Presence of profuse bleeding and/or suppuration on probing	Presence of profuse bleeding and/or suppuration on probing
<b>Probing Pocket Depths</b>	Probing pocket depths may vary based upon soft tissue height, but should not increase over time.	Probing depths are increased from baseline levels	Probing depths are increased from baseline levels
<b>Radiographic Bone Loss</b>	Absence of bone loss after initial remodeling.	Absence of bone loss after initial remodeling.	Progressive bone loss after initial remodeling.



**Figure 1.** Peri-implant mucositis clinical and radiographic presentation.





**Figure 2.** Peri-implantitis clinical and radiographic presentation.

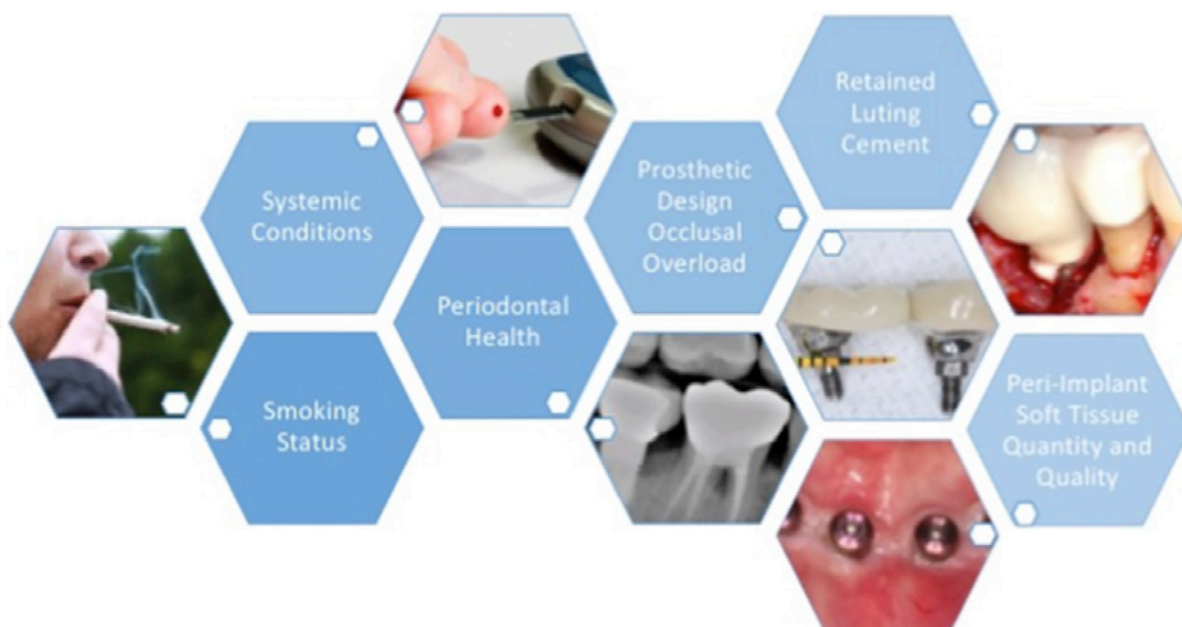
treatment, if necessary. Establishing ideal overall health, plaque control, and compliance with professional maintenance is critical to the long-term success of therapy. Once it is established that it is possible for the patient to maintain good oral health, site-specific assessment should be performed to determine if defects can be repaired. Additionally, assessment of the best treatment option for the individual patient and site should be undertaken. This assessment should include an evaluation of the implant and/or prosthetic component mobility, peri-implant defect dimensions, and condition of the implant should be undertaken to allow for optimal customization of the treatment protocol.

### **Risk Factors for Peri-implant Diseases**

In clinical practice, achieving optimal oral health and esthetic results of implant procedures is dependent upon the patient, site, and treatment-related factors. Several risk factors are known to affect the development of peri-implant diseases.<sup>4</sup> Factors that can negatively impact implant health and treatment outcomes include: systemic inflammatory diseases, smoking status, poor plaque control, maintenance adherence, prosthetic design and occlusal overload, retained cement, soft tissue quality/quantity, and previous or active periodontal disease.<sup>4</sup> Due to these risk factors, proper patient selection, site development, and treatment planning are key to achieving high success rates and identification of early clinical signs of disease is critical to successful intervention for peri-implant diseases (Figure 3).<sup>51</sup>

### **Systemic Diseases**

Dental implants are generally elective surgical procedures and should be undertaken on patients who are systemically healthy enough to undergo elective, outpatient procedures. Some common systemic diseases may also directly affect the rates of implant survival. It has been shown that implant failure rates were similar for patients with well-controlled diabetes (HbA1C < 8%) and patients without diabetes; with failure rates in patients with Type 2 diabetes overall demonstrating a marginally significant increase in failures.<sup>52</sup> Patients with uncontrolled diabetes may be poor implant and surgical candidates and demonstrate higher levels of early and late implant failures.<sup>53</sup> In humans, hyperglycemia is known to impair wound healing, impair host defense against pathogens, prolong the inflammatory response to injury, and impair new bone formation and bone repair.<sup>53</sup> The recommended osseointegration periods may be extended in diabetics due to this delay in wound healing caused by hyperglycemia.<sup>54</sup> Future studies are needed to identify distinct cut-off points and quantify the risks, if any, associated with diabetes and development of peri-implantitis. Osteoporosis may also potentially affect implant survival. Osteoporosis and osteopenia are diseases characterized by low bone mass and micro-architectural deterioration with a consequent increase in bone fragility and susceptibility to fracture.<sup>55,56</sup> Osteoporosis is diagnosed when bone mineral density (BMD) is 2.5 standard deviations or more below mean for age and gender-matched individuals and osteopenia is characterized as



**Figure 3.** Risk factors for development of peri-implant diseases.

BMD between 1 and 2.5 standard deviations.<sup>55,56</sup> While osteoporosis/osteopenia have common risk factors with periodontal and peri-implant diseases, including cigarette smoking, dietary factors, and medications, periodontal disease has been independently associated with osteoporotic status.<sup>57</sup> Peri-implantitis, periodontal disease and osteoporosis are mediated by similar dysfunction in the bone remodeling process and the interaction between these diseases may be expected. Patients with osteoporosis demonstrated decreased alveolar and axial bone density and mass and thinner cortical bone than healthy counterparts.<sup>58</sup> To date, studies have not shown a definitive association of peri-implantitis with osteoporosis or osteopenia, although implant placement and use of bisphosphonate medications have been shown to potentially mitigate alveolar bone loss in osteoporotic patients.<sup>4,59-61</sup>

### Smoking Status and/or Tobacco Cessation

Smoking has been shown to have many negative effects on the oral cavity and wound healing after procedures, such as reduction in neutrophil chemotactic response, vasoconstriction, alterations in innate and adaptive immune response, an increase in number or proportion of periopathogenic

bacteria, and a decrease in fibroblast number and collagen production.<sup>62</sup> These effects of smoking can lead to chronic inflammation at periodontal and peri-implant tissues. Patients who smoke have been shown to have up to two times the failure rate of implants compared to non-smokers.<sup>63</sup> Smoking itself, independent of periodontal health, is a predisposing factor in implant failure and development of peri-implant diseases.<sup>63</sup> Smoking cessation is an important contributing factor to implant success; even though cessation cannot reverse past effects it can increase implant success rates to that of nonsmokers.<sup>64</sup> Supportive implant therapy in patients who smoke has also shown a benefit in reducing rates of peri-implantitis that is of larger magnitude than that seen in non-smokers.<sup>65</sup>

### Periodontal Health

Periodontal diseases affecting teeth can similarly affect implants. A history of periodontitis is a risk factor for peri-implantitis.<sup>4,66,67</sup> The primary cause of inflammation around peri-implant tissues is the presence of anaerobic bacteria and their byproducts.<sup>68</sup> Findings suggest that bacteria associated with periodontal disease and peri-implant diseases are similar and the principal pathogens in peri-implant disease

are *P gingivalis* and *A actinomycetemcomitans*.<sup>69</sup> Colonization of dental implants with these bacterial species has been shown to occur within the first 28 days after exposure to the oral environment and bacteria can be transferred from distant reservoirs at tooth sites within a patient's mouth.<sup>70,71</sup> Given the high prevalence of periodontal disease and the rate of tooth loss due to periodontal disease in adult patients, treatment of active periodontal disease and maintenance therapy of both natural dentition and/or dental implants is critical to overall implant success.<sup>4,66</sup>

### **Plaque Control and Adherence to Regular Supportive Implant Therapy**

Plaque control for the prevention and management of peri-implant mucositis is essential in the long-term maintenance of implants in health.<sup>72</sup> Both patient-performed and professional plaque control can result in a reduction in clinical signs of peri-implant inflammation. Additionally, partially edentulous patients demonstrate higher rates of periopathogenic bacteria compared to fully edentulous patients likely resulting from transfer of bacteria and, in particular, pathogenic bacterial species from tooth sites to dental implant sites.<sup>72</sup> Therefore, regular maintenance protocols which reduce overall bacterial loads are critical to reduce the transmission of periodontal pathogenic bacteria from active periodontal sites to implant sites in same mouth.<sup>73</sup> Adherence to regular professional maintenance is key to detect and manage implants that are ailing or failing.<sup>72</sup> A lack of adherence to supportive peri-implant therapies results in significantly higher frequencies of sites with mucosal inflammation and peri-implant bone loss. Therefore, tailored supportive peri-implant therapies, such as reinforcement of personalized oral hygiene instructions combined with professional implant and/or tooth cleaning, should be an integral part of implant therapy.<sup>72</sup>

### **Prosthetic Design and Occlusal Load**

It has been postulated that mechanical overloading is a contributing factor to many instances of peri-implant bone loss and late implant failures.<sup>74</sup> Occlusal load is influenced by prosthetic design but hard to study due

to lack of quantification of overload. Some studies indicate that micromotion at the implant-abutment interface compromises the establishment of implant osseointegration during early healing<sup>75</sup> and that implants that have off-axis forces, such as a cantilever design demonstrate more peri-implant bone loss after loading.<sup>74,75</sup> Despite being difficult to quantify occlusal overload in the literature, a systematic review concluded that occlusal overloading was associated with peri-implant marginal bone loss caused by microtrauma concentrated at the marginal bone.<sup>76</sup> It follows that prosthetically-driven and biologically executed treatment planning as well as assessment of occlusal load, including inspection of implant prostheses for signs of potential grinding and other parafunctional habits and occlusal adjustment or prosthetic replacement when premature contacts or interferences are present should be undertaken during the maintenance phase to insure optimal dental implant health.<sup>29</sup>

### **Retained Cement**

Retained cement has been indicated in a large number of peri-implant disease cases. Many dental implant cements are radiolucent and residual cement may not be detected radiographically, particularly if present on the buccal and/or lingual of the fixture. Residual cement may be rough and allow bacterial attachment and, subsequently, peri-implant inflammation.<sup>77</sup> Prosthesis design in combination with the additional irritant of subgingival cement may promote incomplete plaque removal due to the creation of non-cleansable sites.<sup>78</sup> Peri-implant disease prevalence is significantly higher at fixtures with cement-retained versus screw-retained restorations<sup>77,79</sup> and in a case-control study, within a group of implants with diagnosed peri-implantitis, 81% had excess cement present compared to no retained cement found at healthy, control implants.<sup>80</sup> Due to excess cement being a possible risk factor for peri-implant disease, it may be advisable to use screw-retained restorations when possible, practice techniques to avoid excess cement, allow for adequate soft tissue healing prior to seating of a permanent restoration, and allow for early follow up after initial restorative cementation to detect any early signs of cement retention.



### Peri-implant Soft Tissue Quality/Quantity

While current evidence on the importance of keratinized and/or attached mucosa around teeth and implants for their health and survival is equivocal, it has been proposed that the establishment of a circumferential seal of tightly packed collagen around the implant-oral cavity interface may improve long-term implant success.<sup>81</sup> Implant survival rates have been shown to be equivalent for implants placed in keratinized and alveolar mucosa, but increased radiographic bone loss and higher levels of gingival inflammation are associated with a lack of keratinized mucosa.<sup>82</sup> Furthermore, increasing bands of keratinized peri-implant mucosa have been associated with improved clinical outcomes, particularly in individuals with erratic compliance to implant maintenance.<sup>83</sup> While there are no definitive studies to conclude that there is a benefit when implants have an adequate band of fixed and/or keratinized mucosa, in patients with other risk factors, including increased plaque accumulation and previous history of periodontitis, increased keratinized and/or fixed mucosa may be protective to allow for personal and professional plaque removal.<sup>82,84</sup>

### Current Treatment Strategies for Peri-implant Diseases

Peri-implant mucositis is a reversible condition of the soft tissues around an implant and implants exhibiting inflammation limited to soft tissue and implants with peri-implant mucositis are sometimes described as “ailing” implants.<sup>29</sup> Clinical signs of peri-implant mucositis include presence of bleeding on probing, swelling of the peri-implant mucosa, increase of probing depth (pseudopockets), and/or erythema of surrounding tissues.<sup>85</sup> Peri-implantitis is a bacterially-initiated, inflammatory condition of the tissues around osseointegrated implants characterized by progressive loss of supporting bone that is verified by radiographs and clinical signs of inflammation (bleeding and/or suppuration on probing).<sup>86</sup> Implants with peri-implantitis are often categorized as “failing” implants and when these implants are refractory to treatment and/or present with clinical mobility they are classified as “failed.”<sup>87</sup> Implants can fail at various stages in treatment and function. When implants fail due to lack

of initial osseointegration, this is referred to as early implant failure. Early failures are influenced by patient-specific impaired healing responses, acute infection, premature loading, and/or surgical trauma.<sup>88</sup> Late failure of implants occurs after the initial phase of osseointegration, remodeling and loading. Late failures are associated with occlusal overload, fixture or prosthetic fracture, and peri-implant disease.<sup>89</sup> Peri-implantitis has been seen in a mean of 22% of implants in place and has been noted in 10% of implants and 20% of implant patients within 10 years of surgical implant placement.<sup>3-6,86</sup> When either peri-implant mucositis or peri-implantitis is detected, it is imperative to initiate therapeutic intervention as soon as possible.<sup>12</sup>

Successful therapy to treat peri-implantitis can be assessed in a number of ways. Ideally, resolution of disease would mean absence of clinical inflammation (bleeding on probing) and a lack of progressive bone loss and/or regeneration of lost tissues.<sup>40,41</sup> At sites with peri-implant mucositis, biofilm control and adequate implant maintenance can reestablish implant health.<sup>51,90</sup> A systematic review examining various methods to treat peri-implant disease included studies that reported on implant loss, mean probing depth, percentage of sites or implants with bleeding and/or suppuration on probing, and radiographic bone levels at 12 months (or longer) following treatment. Successful treatment outcomes were defined as: implant survival with no mean probing depths  $\geq$  5 mm and no further bone loss 12 months after treatment.<sup>40,41</sup> Non-surgical treatment included debridement using manual or ultrasonic instruments, laser treatments in conjunction with local debridement, and adjunctive systemic or local application of antimicrobial agents.<sup>40,41</sup> Successful treatment outcomes for nonsurgical therapy ranged from 0%-84%.<sup>91-93</sup> Generally, these therapies were not successful at sites with initial peri-implantitis demonstrating extensive bone loss and/or deep probing depths.<sup>91</sup> At these sites, additional surgical intervention has been demonstrated to be necessary.<sup>91</sup> Surgical treatment of peri-implantitis included regenerative protocols, access surgery, and resective surgery.<sup>94-102</sup> The

success rates for regenerative surgery ranged from 0-100%<sup>94-98,100,101</sup> and included treatments of bone grafting without membrane using xenograft, autograft, or combination,<sup>95,96</sup> using non-resorbable membranes alone,<sup>94</sup> resorbable membrane in combination with bone graft materials,<sup>95,96</sup> or bone grafting in combination with subepithelial connective tissue graft.<sup>97,98,100</sup> Non-resorbable membranes included in this analysis had a high rate of exposure and did not demonstrate significant clinical improvements.<sup>94</sup> Access surgery using curettes for debridement of implant surface and saline soaked gauze for surface decontamination had success rate of 88% in achieving implant stability over time.<sup>99</sup> Resective surgery alone demonstrated success rate of 0% due to bone loss over 3 years, while implantoplasty with resective surgery had success rate of 100% and bone level remained unchanged over 3 years.<sup>101,102</sup> However, few implants were included in each group of treatment modalities and definitive identification of a superior therapy cannot be made from the current data.

### **Implant Surface Disinfection: Treatment Modalities and Effectiveness**

The rationale for implant surface decontamination includes elimination of calculus, biofilm, and hard deposits such as residual cement, to better prepare the implant surface for re-osseointegration prior to or during reconstructive therapy, and/or to establish an implant surface with decreased biofilm adhesion in advance of resective procedures.<sup>103</sup> Commonly used methods for implant surface detoxification include mechanical methods, chemical methods, and laser therapy.<sup>104</sup> It should be noted that many implant surface decontamination methods induce changes in implant surface chemical and physical properties, which may impact long-term clinical outcomes of surgical and nonsurgical therapies.<sup>103,105</sup> It is also notable that little evidence exists on the impact of implant surface geography and baseline surface characteristics on outcomes of decontamination procedures.<sup>103</sup> It is clinically evident that endosseous dental implants with undercuts and screw-form threads present real-life difficulties for thorough debridement of the implant surface while reducing deleterious

alterations to implant surface characteristics.<sup>103</sup> Further, there has been emerging evidence that some implant surface decontamination strategies targeting biofilm may lead to titanium particle dissolution.<sup>103,105</sup> Such titanium particles have also demonstrated cytotoxic effects on fibroblasts and osteoblasts and association with increased biofilm pathogenicity, which may lead to failed treatments.<sup>103,105</sup>

### **Mechanical Implant Surface Decontamination**

Mechanical methods of surface decontamination include implantoplasty, use of hand or ultrasonic scalers, and the use of air powder abrasives.<sup>104,106</sup> Implantoplasty involves the use of rotary instruments to remove modified implant surfaces and to flatten or smooth threads on exposed implant surfaces.<sup>106</sup> Implantoplasty is often combined with resective approaches so that soft tissues are apically positioned and exposed implant surfaces demonstrate decreased plaque adherence.<sup>107,108</sup> Scaling with hand or ultrasonic scalers seeks to mechanically disrupt and remove biofilm deposits. The materials that the scalers and curettes consist of may influence both efficacy of biofilm removal and resultant damage and/or alterations to implant surfaces. Metal ultrasonic scaler tips and curettes are more efficient in removing biofilm and calculus, but alter implant surface topography.<sup>109,110</sup> It is often recommended that metals that are of equivalent or less hardness compared to the composition of dental implants (e.g. gold, titanium) should be used to minimize damage while maximizing biofilm removal.<sup>111</sup> Conversely, nonmetal curettes may be made of plastic, carbon, or resin. Such nonmetal curettes have demonstrated decreased effectiveness in biofilm removal and deposition of curette material on implant surfaces.<sup>106,112</sup> Air powder abrasives use an abrasive powder, including aluminum oxide, sodium bicarbonate, sodium hydrocarbonate, amino acid glycine, or erythritol, propelled by compressed air.<sup>112</sup> Effective biofilm and bacterial endotoxin removal has been demonstrated with minimal damage to implant surfaces.<sup>109,113-115</sup> However, some investigations have demonstrated that powder particles can stay attached to the implant surface after cleaning.<sup>115</sup> It should also be noted that subcutaneous emphysema have been reported after air abrasives around teeth and implants and care should be taken to avoid forcibly directing compressed air into tissues.<sup>116-117</sup>

### Chemical Implant Surface Decontamination

Chemical surface decontamination involves the use of acidic and antimicrobial compounds to reduce biofilm on implant surfaces and they are often used in conjunction with nonsurgical and surgical regenerative approaches for treatment of peri-implant disease.<sup>104</sup> Commonly used chemical implant surface decontaminants include citric acid, chlorhexidine, ethylene diamine tetraacetic acid (EDTA), hydrogen peroxide, tetracycline, and saline.<sup>104</sup> Citric acid has a pH of 1 and has been used extensively for implant surface detoxification.<sup>104</sup> In vitro studies demonstrate endotoxin reduction and bacterial cell inactivation with citric acid applications ranging from 30 seconds to 2 minutes in smooth-surface and moderately rough implant surfaces.<sup>118,119</sup> Concentration of citric acid in studies were not consistent with concentrations ranging from 4-40%. Lower concentrations of citric acid demonstrated decreased osteoblastic cytotoxicity, but cell proliferation was impacted at all concentrations.<sup>120,121</sup> Chlorhexidine gluconate is a broad-spectrum antimicrobial and has demonstrated significant reduction in endotoxin and bacterial load on implant surfaces when applied to those surfaces.<sup>118,122</sup> Chlorhexidine has also been associated with induced apoptotic and autophagic/necrotic cell death of osteoblasts and fibroblasts.<sup>123,124</sup> EDTA is widely used in dentistry as a chelating agent and has the advantage of a neutral pH.<sup>104</sup> Little data is available on the clinical efficacy of EDTA for implant surface decontamination.<sup>104</sup> In vitro studies have demonstrated that hydrogen peroxide reduction of endotoxin and elimination of pathogenic bacteria from titanium surfaces.<sup>125</sup> Animal studies have also verified the capability of hydrogen peroxide to decontaminate implant surfaces in vivo and allow re-osseointegration.<sup>126</sup> Tetracycline is a bacteriostatic antibiotic that inhibits bacterial protein synthesis.<sup>104</sup> A slurry including tetracycline 50mg/mL applied to implant surfaces after resective implant surgery has been associated with arrest of peri-implant disease progression and radiographic bone fill.<sup>127,128</sup> Saline combined with mechanical implant surface debridement has been associated with clinical stability after treatment for up to 24 months.<sup>129,130</sup> It has also been reported that use of saline for decontamination provides similar results to other chemical disinfective processes and results in a more biocompatible surface with no deleterious effects on host tissues.<sup>131</sup>

### Laser Implant Surface Decontamination

Commercially available lasers that have been used for implant surface disinfection include: carbon dioxide (CO<sub>2</sub>), diode, erbium yttrium aluminum garnet (Er:YAG), and neodymium yttrium aluminum garnet (Nd:YAG).<sup>132-135</sup> The specific functions and targets of these lasers are summarized in Table 2.

Adjunctive use of laser therapy has been shown to result in decreases in clinical signs of inflammation at 3 months<sup>136-139</sup> and bleeding on probing at six months after treatment, but the effect on other clinical parameters demonstrated minimal benefit.<sup>136</sup> While the preponderance of the current literature body presented does not present definitive findings demonstrating a clinical or microbiological improvement after adjunctive laser therapy, laser therapy with appropriate wavelength and settings can be used effectively to detoxify titanium surfaces without alteration of the surface morphology.<sup>136,140</sup> Additionally, some of the risks of laser therapy may be mitigated by the use of photodynamic therapy (PDT), which uses low-level laser therapy to perform surface decontamination. Recent in vitro studies have indicated that PDT may be more efficient than standard laser disinfection protocols without many of the associated risks.<sup>141</sup> Additionally, given the current evidence, only Er:YAG, diode, and CO<sub>2</sub> lasers can be reliably assessed.<sup>140,142, 143</sup> Given the decreased risk of damage to tissues and implants with the use of appropriate time, wavelength, presence of cooling and laser power and the ability of the lasers to detoxify titanium surfaces, they may be a viable adjunctive therapy with nonsurgical and surgical implant treatment, although additional investigations are necessary to standardize protocols and classify expected outcomes.

### Clinical Decision Making for Treatment of Patients with Peri-implant Diseases

Complications affecting implants are common and of concern for patients and practitioners alike. Proper maintenance of implants to insure health as well as identification and treatment of prosthetic and biologic complications is critical to the long-term function, esthetics, phonetics, and health of patients who have received endosseous dental implants for tooth replacement. It has been a great challenge of clinicians to properly manage and treat peri-implant disease. The decision tree presented here (Figure 4) was

**Table 2. Laser types commonly used to treat peri-implant diseases and their properties.**

Laser Type	Wavelength	Chromophore	Classification
Diode	450-1064 nm	Melanin, hemoglobin	Hot; soft tissue
Neodymium yttrium aluminum garnet (Nd:YAG)	1064 nm	Melanin, hemoglobin	Hot; soft tissue
Erbium yttrium aluminium garnet (Er:YAG)	2940 nm	Water, hydroxyapatite	Cold; hard or all tissue
Carbon dioxide (CO <sub>2</sub> )	9300 to 10,600 nm/td>	Water, hydroxyapatite	Hot or cold; soft or all tissue

fabricated to guide treatment of these diseases and to possibly intervene at an earlier time point. This particular assessment emphasizes ongoing monitoring of implant health as a part of supportive peri-implant therapy and early detection of peri-implant disease. When treating peri-implant conditions, it is critically important to recognize peri-implant disease at the earliest stage of disease to start treatment immediately to reduce clinical signs of inflammation and progressive attachment loss. If peri-implant disease is identified, clinical decisions for nonsurgical and surgical intervention to treat that disease must be undertaken in a systematic manner. Because evidence suggests that traditional nonsurgical therapy alone is inadequate to treat peri-implantitis, use of adjunctive methods for implant surface decontamination should be considered by the clinician when appropriate. The decision tree in Figure 4 may help guide the management of clinical complications with implant therapy, such as peri-implant mucositis, peri-implantitis, and loss of osseointegration.

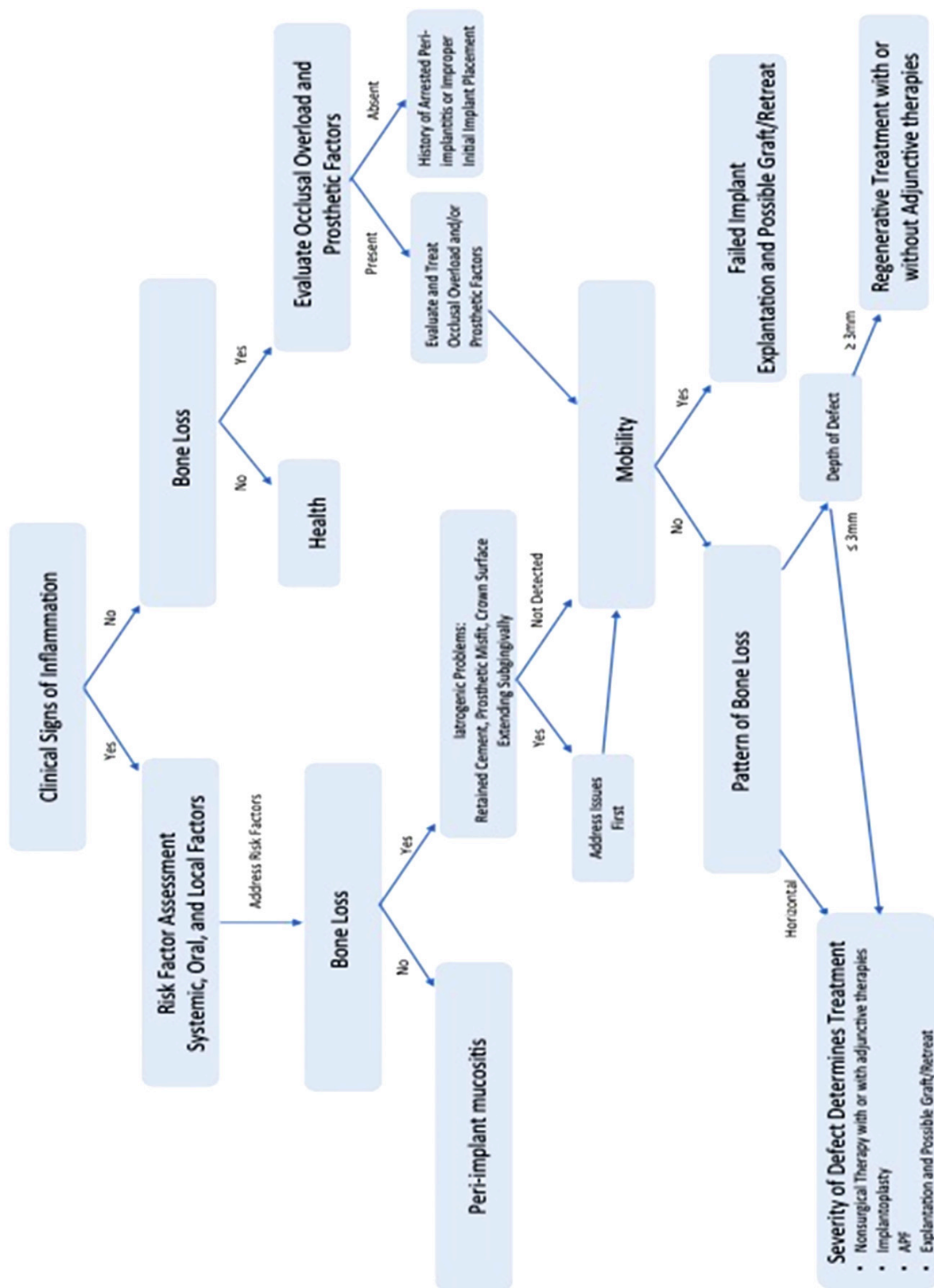
### Importance of Supportive Peri-Implant Therapy

It is well-established that in the case of successful periodontal treatment, ongoing supportive periodontal therapy is essential to maintain health, prevent periodontal reinfection, reduce the risk of disease recurrence, and decrease the incidence of tooth loss.<sup>144-147</sup> Similarly, supportive peri-implant therapy both prior to any diagnosis of peri-implant disease and after treatment of peri-implant mucositis or

peri-implantitis is critical to long-term implant success.<sup>17,148</sup> Patients who did not receive supportive peri-implant therapy, including ongoing surveillance for peri-implant disease, were over twice as likely to develop peri-implant mucositis and four times more likely to develop peri-implantitis than those who were compliant with at least annual supportive implant therapy over a 7 year period.<sup>148</sup> Given these findings, clinicians should discuss the need for supportive peri-implant therapy with patients during implant treatment planning and should utilize risk-based protocols<sup>149</sup> for maintenance interval selection after implant placement and restoration.

### Conclusion

Peri-implant health, peri-implant mucositis, and peri-implantitis are distinct entities and present with distinct clinical and microbiologic findings. Ongoing appropriate implant maintenance and examination as well as early identification of peri-implant disease and treatment of reversible inflammation in peri-implant mucositis with nonsurgical therapy is critical for optimal outcomes of implant therapy. In cases where implants demonstrate peri-implantitis, adjunctive mechanical, chemical, and/or laser treatment may be considered for implant surface disinfection. To facilitate diagnosis and treatment of peri-implant diseases, a decision matrix was formulated to allow for identification and treatment for ailing/failing implants. More studies are needed to quantify best treatment options in the varying clinical scenarios seen in practice.



**Figure 4.** Decision matrix for peri-implant conditions.



## Course Test Preview

To receive Continuing Education credit for this course, you must complete the online test. Please go to: [www.dentalcare.com/en-us/ce-courses/ce696/start-test](http://www.dentalcare.com/en-us/ce-courses/ce696/start-test)

**1. How many implants are placed annually in the US?**

- A. 500,000
- B. 1 million
- C. 5 million
- D. 15 million

**2. Definitive treatment of peri-implantitis has proven difficult and disease has been shown to recur in up to \_\_\_\_\_% of cases, depending upon the treatment modality used.**

- A. 50%
- B. 60%
- C. 80%
- D. 100%

**3. Peri-implant mucositis is defined as clinical inflammation without progressive bone loss and it has been observed in up to \_\_\_\_\_% of subjects with dental implants.**

- A. 10%
- B. 27%
- C. 47%
- D. 65%

**4. Healthy peri-implant mucosa is comprised of:**

- A. A core of connective tissue covered by either keratinized or non-keratinized epithelium
- B. Connective tissue with significant inflammatory infiltrate
- C. Keratinized mucosal epithelium only
- D. A core of connective tissue with pseudostratified columnar epithelium

**5. Peri-implant mucositis is reversible, the inflammatory lesion seen in experimental peri-implant mucositis is \_\_\_\_\_ that seen in experimental gingivitis of the same chronicity and with similar clinical signs.**

- A. Larger Than
- B. Similar To
- C. Smaller Than

**6. All of the following have been associated with an increased risk of peri-implantitis, EXCEPT one. Which one is the exception?**

- A. Smoking cessation
- B. Poor plaque control
- C. Poor maintenance adherence
- D. Periodontal disease

**7. Failure rates for dental implants are increased in smokers up to \_\_\_\_\_ times.**

- A. 1.5
- B. 2
- C. 5
- D. 10

- 8. How long does it take for periopathogenic bacteria to colonize dental implant components after their exposure to the oral environment?**
- A. 14 days
  - B. 28 days
  - C. 3-6 months
  - D. 12-24 months
- 9. In a case-control study, \_\_\_\_\_% of healthy implants and \_\_\_\_\_% of those diagnosed with peri-implantitis demonstrated retained cement upon surgical evaluation?**
- A. 7%; 76%
  - B. 25%; 88%
  - C. 0%; 81%
  - D. 14%; 94%
- 10. Which of the following is NOT a reason to perform implant surface decontamination?**
- A. Elimination of calculus and biofilm
  - B. To prepare the implant surface for re-osseointegration prior to or during reconstructive therapy
  - C. To remove the outer layer of surface roughness and alter implant surface topography
  - D. To establish an implant surface with decreased biofilm adhesion in advance of resective procedures.
- 11. Which of the following is a potentially harmful effect of implant surface decontamination?**
- A. Titanium particle dissolution
  - B. Endotoxin removal
  - C. Decreased colony forming units of *P. gingivalis*
  - D. Re-osseointegration
- 12. Which of the following has NOT been associated with air abrasion therapy?**
- A. Effective biofilm and bacterial endotoxin removal
  - B. minimal damage to implant surfaces
  - C. Retained powder particles at the implant surface
  - D. Change in pH after use
- 13. Which of the following chemical disinfection treatments has NOT been associated with deleterious impacts on host cells?**
- A. Chlorhexidine gluconate
  - B. Saline
  - C. Citric Acid
- 14. Which of the following commercially available lasers has the longest wavelength?**
- A. Diode
  - B. Nd:YAG
  - C. Er:YAG
  - D. Carbon dioxide

- 15. Adjunctive use of laser therapy has been shown to result in decreases in clinical signs of inflammation out to \_\_\_\_\_ months and bleeding on probing at \_\_\_\_\_ months after treatment.**
- A. Six, Twelve
  - B. Six, Eighteen
  - C. Three, Six
  - D. Three, Twelve

## References

1. Buser D, Ingimarsson S, Dula K, et al., Long-term stability of osseointegrated implants in augmented bone: a 5-year prospective study in partially edentulous patients. *Int J Periodontics Rest Dent* 2002; 22: 109-117.
2. ADA Patient Smart. Patient Education Center. Accessed February 3, 2022
3. Zitzmann NU and Berglundh T. Definition and prevalence of peri-implant diseases. *J Clin Periodontol* 2008; 35(8 Suppl): 286-291.
4. Schwarz F, Derks J, Monje A, Wang H-L. Peri-implantitis. Proceedings from the 2017 World Workshop. *J Periodontol* 2018; 89(Suppl 1): S267-S290.
5. Roos-Jansåker AM, Lindahl C, Renvert H, Renvert C. Nine- to fourteen-year follow-up of implant treatment. Part II: presence of peri-implant lesions. *J Clin Periodontol* 2006; 33: 290-295.
6. Derks J, Tomasi C. Peri-implant health and disease. A systematic review of current epidemiology. *J Clin Periodontol* 2015; 42(Suppl 16): S158-S171.
7. Diaz P, Gonzalo E, Villagra LJG et al. What is the prevalence of peri-implantitis? A systematic review and meta-analysis. *BMC Oral Health* 2022; 22: 449.
8. Zitzman NU, Berglundh T, Marinello CP, Lindhe J. Experimental peri-implant mucositis in man. *J Clin Periodontol* 2001; 28: 517-523.
9. Salvi GE, Aglietta M, Eick S, Sculean A., Lang NP, Ramseier CA. Reversibility of experimental peri-implant mucositis compared with experimental gingivitis in humans. *Clin Oral Implants Res* 2012; 23: 182-190.
10. Heitz-Mayfield L, Salvi G. Peri-implant mucositis. *J Periodontol* 2018; 89(Suppl 1): S257-S266.
11. Salvi GE, Zitzmann NU. The effects of anti-infective preventive measures on the occurrence of biologic implant complications and implant loss: a systematic review. *Int J Oral Maxillofac Implants* 2014; 29(Suppl): 292-307.
12. Esposito M, Hirsch JM, Lekholm U, Thomsen P. Biological factors contributing to failures of osseointegrated oral implants. (II). Etiopathogenesis. *Eur J Oral Sci* 1998; 106: 721-764.
13. Academy Report: AAP. Rosen P, Clem D, Cochran D, et al., Peri-implant mucositis and peri-implantitis: a current understanding of their diagnoses and clinical implications. *J Periodontol* 2013; 84: 436-443.
14. Shibli JA, Melo L, Ferrari DS, et al., Composition of supra- and subgingival biofilm of subjects with healthy and diseased implants. *Clin Oral Implants Res* 2008; 19: 975-982.
15. Esposito M, Grusovin MG, Worthington HV. Treatment of peri-implantitis: what interventions are effective? A Cochrane systematic review. *Eur J Oral Implantol* 2012; 5 Suppl: S21-41.
16. Hammerle CH, Fourmoussis I, Winkler JR, et al., Successful bone fill in late peri-implant defects using guided tissue regeneration. A short communication. *J Periodontol* 1995; 66: 303-308.
17. Heitz-Mayfield LJA, Salvi GE, Mombelli A, Loup PJ, Heitz F, Kruger E, Lang NP. Supportive peri-implant therapy following anti-infective surgical peri-implantitis treatment: 5-year survival success. *Clin Oral Implants Res* 2018; 29(1): 1-6.
18. Heitz-Mayfield LJA, Mombelli A. The therapy of peri-implantitis: A systematic review. *Int J Periodont Rest Dent* 2014; 29(Suppl): 325-345.
19. Clem DS, Wang H-L, Froum SJ. Where is dentistry today regarding the treatment of peri-implant disease? *Compendium Cont Educ Dent* 2018; 39(1): 16.
20. Albrektsson T, Isidor F. Consensus report of session IV. In: Lang NP, Karring T, eds. *Proceedings of the 1st European Workshop on Periodontology*. London: Quintessence Publishing; 1994: 365-369.
21. Albrektsson T, Isidor F. Consensus report of session IV. In: Lang NP, Karring T, eds. *Proceedings of the 1st European Workshop on Periodontology*. London: Quintessence Publishing; 1994: 365-369.
22. Van Winkelhoff AJ, Goené RJ, Benschop C, Folmer T. Early colonization of dental implants by putative periodontal pathogens in partially edentulous patients. *Clin Oral Implants Res*. 2000 11: 511-520.
23. Quirynen M, Vogels R, Peeters W, et al., Dynamics of initial subgingival colonization of 'pristine' peri-implant pockets. *Clin Oral Implants Res* 2006; 33: 49-52.

24. Klinge B, Hultin M, Berglundh T. Peri-implantitis. *Dent Clin North Am* 2005; 49: 661-676.
25. Mombelli A, Lang NP. The diagnosis and treatment of peri-implantitis. *Periodontol* 2000 1998; 17: 63-76.
26. Schwarz F, Sculean A, Rothamel D, et al., Clinical evaluation of an Er:YAG laser for nonsurgical treatment of peri-implantitis: a pilot study. *Clin Oral Implants Res* 2005; 16: 44-52.
27. Roos-Jansåker AM, Renvert S, Egelberg J. Treatment of peri-implant infections: a literature review. *J Clin Periodontol* 2003; 30: 467-485.
28. Gosau M, Hahnel S, Schwarz F, et al., Effect of six different peri-implantitis disinfection methods on in vivo human oral biofilm. *Clin Oral Implants Res* 2010; 21: 866-872.
29. Brånemark PI, Hansson BO, Adell R, Breine U, Lindström J, Hallen O, Ohman A. Osseointegrated implants in the treatment of the edentulous jaw. Experience from a 10-year period. *Scand J Plast Reconstr Surg Suppl* 1997; 16: 1-132.
30. Ashley ET, Covington LL, Bishop BG, Breault LG. Ailing and Failing Endosseous Dental Implants: A Literature Review. *J Contemp ent Pract* 2003; 4(2): 1-12.
31. Mombelli A, Müller N, Cionca N. The epidemiology of peri-implantitis. *Clin Oral Implants Res* 2012; 23(Suppl 6): 67-76.
32. Dierks J and Tomasi C. Peri-implant health and disease: A systematic review of current epidemiology. *J Clin Periodontol* 2015; 42( Suppl 16): S158-S171.
33. Fransson C, Wennström J, Tomasi C, Berglundh T. Extent of peri-implantitis associated bone loss. *J Clin Periodontol* 2009; 36: 357-363.
34. Atieh MA, Alsabeeha NH, Faggion CM Jr, Duncan WJ. The frequency of peri-implant diseases: A systematic review and meta-analysis. *J Periodontol* 2013; 84: 1586-1598.
35. Sgolastra F, Petrucci A, Severina M, Gatto R, Monaco A. Periodontitis, implant loss and peri-implantitis: A meta-analysis. *Clin Oral Implants Res* 2015; 26: e8-e16.
36. Clementini M, Rossetti PH, Penarrocha D, Micarelli C, Bonachela WC, Canullo L. Systemic risk factors for peri-implant bone loss: A systematic review and meta-analysis. *Int J Oral Maxillofac Surg* 2014; 43: 323-334.
37. Pontoriero R, Tonelli MP, Carnevale G, Mombelli A, Nyman SR, Lang NP. Experimentally induced peri-implant mucositis. A clinical study in humans. *Clin Oral Implants Res* 1994;5: 254-259
38. Schwendicke F, Tu Y-K, Stolpe M. Preventing and Treating Peri-implantitis: A Cost-effectiveness analysis. *J Periodontol* 2015; 86: 1020-1029.
39. Lang NP, Brägger U, Walther D, Beamer B, Kornman KS. Ligature-induced peri-implant infection in cynomolgus monkeys. *Clin Oral Implants Res* 1993; 4: 2-11.
40. Lindhe J, Berglundh T, Ericsson I, et al. Experimental breakdown of peri- implant and periodontal tissues. A study in the beagle dog. *Clin Oral Implants Res*. 1992;3:9-16.
41. Grusovin MG, Coulthard P, Worthington HV, Esposito M. Maintaining and recovering soft tissue health around dental implants: a Cochrane systematic review of randomized controlled clinical trials. *Euro J Oral Implantol* 2008; 1(1): 11-22.
42. Heitz-Mayfield LJ, Mombelli A. The Therapy of Peri-implantitis: A systematic review. *Int J Oral Maxillofac Implant* 2014; 29(Suppl): 325-345.
43. Renvert S, Persson GR, Pirih FQ, Camargo PM. Peri-implant health, peri-implant mucositis, and peri-implantitis: Case definitions and diagnostic considerations. Proceedings from the 2017 World Workshop for Classification of Periodontal and Peri-Implant Diseases and Conditions. *J Periodontol* 2018; 89(Suppl 1): S304-S312.
44. Araujo MG and Lindhe J. Peri-implant health. *J Periodontol* 2018; 89(Suppl 1): S249-S256.
45. Meyer S, Giannopoulou C, Courvoisier D, Schimmel M, Müller F, Mombelli A. Experimental mucositis and experimental gingivitis in persons aged 7 or over. Clinical and biological responses. *Clin Oral Implants Res* 2017; 28(8): 1005-1012.
46. Heitz-Mayfield LJ. Peri-implant diseases. Diagnosis and risk indicators. *J Clin Periodontol* 2008; 35: 292-304.
47. Sanz M, Chapple IL. Clinical research on peri-implant diseases: consensus report of working group 4. *J Clin Periodontol* 2012; 39(Suppl. 12): 202-206.



48. Tomasi C, Derks J. Clinical research of peri-implant diseases—quality of reporting, case definitions and methods to study incidence, prevalence, and risk factors of peri-implant diseases. *J Clin Periodontol* 2012; 39(Suppl. 12): 207-223.
49. Lindhe J, Meyle J, Group DoEWoP. Peri-implant diseases: consensus report of the Sixth European Workshop on Periodontology. *J Clin Periodontol* 2008; 35(Suppl 8): 282-285.
50. Schwarz F, Derks J, Monje A, Wang H-L. Peri-implantitis. *J Periodontol* 2018; 89(Suppl 1: S267-S290.
51. Carcuac O, Berglundh T. Composition of human peri-implantitis and periodontitis lesions. *J Dent Res* 2014; 93: 1083-1088.
52. Curtis DA, Lin G-H, Fishman A, et al. Patient-centered risk assessment in implant treatment planning. *Int J Oral Maxillofac Impl* 2019; 34: 506-520.
53. Morris, H F. Implant survival in patients with type 2 diabetes: placement to 36 months. *Ann Periodontol* 2000; 5: 157-177.
54. Iacopino AM. Periodontitis and diabetes interrelationships: role of inflammation. *Ann Periodontol* 2001; 6:125-37.
55. Oates TW, Huynh-Ba G, Vargas A. A critical review of diabetes, glycemic control, and dental implant therapy. *Clin Oral Implants Res* 2013;24(2):117-27.
56. Kanis JA. Assessment of fracture risk and its application to screening for postmenopausal osteoporosis: synopsis of a WHO report. WHO Study Group. *Osteoporos Int* 1994; 4: 368-381.
57. Kanis JA, Melton LJ III, Christiansen C, Johnston CC, Khaltaev N. The diagnosis of osteoporosis. *J Bone Miner Res* 1994; 9: 1137-1141.
58. Geurs, N. C. Osteoporosis and periodontal disease. *Periodontology* 2000 2007; 44: 29-43.
59. Wehren LE. The epidemiology of osteoporosis and fractures in geriatric medicine. *Clin Geriatr Med* 2003; 19: 245-258.
60. Ruggiero SL, Mehrotra B, Rosenberg TJ, Engroff SL. Osteonecrosis of the jaws associated with the use of bisphosphonates: a review of 63 cases. *Int J Oral Maxillofac Surg* 2004; 62: 527-534.
61. Kribbs PJ, Smith DE, Chesnut CH Jr. Oral findings in osteoporosis. Part I: measurement of mandibular bone density. *J Prosthet Dent* 1983; 50: 576-579.
62. Geurs NC, Lewis CE, Jeffcoat MK. Osteoporosis and periodontal disease progression. *Periodontol* 2000 2003; 32: 105-110.
63. Johnson, G. K. and Guthmiller, J. M. (2007), The impact of cigarette smoking on periodontal disease and treatment. *Periodontol* 2000, 44: 178-194.
64. Bain CA. Implant installation in the smoking patient. *Periodontol* 2000 2003; 33: 185-193
65. Lambert PM, Morris HF, Ochi S. The influence of smoking on 3-year clinical success of osseointegrated dental implants. *Ann Periodontol* 2000; 5: 79-89.
66. Schwendicke F, Tu Y-K, Stolpe M. Preventing and Treating Peri-implantitis: A Cost-effectiveness analysis. *J Periodontol* 2015; 86: 1020-1029.
67. Academy report: peri-implant mucositis and peri-implantitis: a current understanding of their diagnoses and clinical implications. *J Periodontol* 2013;84(4): 436-443
68. Roccuzzo M, DeAngelis N, Bonino L, Aglietta M. Ten-year results of a three-arm prospective cohort study on implants in periodontally compromised patients. Part 1: implant loss and radiographic bone loss. *Clinical Oral Imp Res* 2010; 21 (5): 490-496.
69. Mombelli A, Lang NP. The diagnosis and treatment of peri-implantitis. *Periodontol.* 2000. 1998;17:63-76.
70. Ata-Ali J, Candel-Marti M, Flichy-Fernandez A, et al. Peri-implantitis: associated microbiota and treatment. *Med Oral Patol Oral Cir Bucal* 2011;16(7):e937-43.
71. Renvert S, Roos-Jansaker AM, Lindahl C, et al. Infection at titanium implants with or without a clinical diagnosis of inflammation. *Clin Oral Implants Res.* 2007;18:509-516.
72. Quirynen M, Vogels R, Peeters W, et al. Dynamics of subgingival colonization of 'pristine' peri-implant pockets. *Clin Oral Implants Res* 2006;17(1):25-37.
73. Ramanauskaite, A. The Efficacy of Supportive Peri-Implant Therapies in Preventing Peri-Implantitis and Implant Loss: a Systematic Review of the Literature. *J Oral Maxillofac Res* 2016; 7(3), p. e12.

74. Gouvoussis J, Sindhusake D, Yeung S. Cross-infection from periodontitis sites to failing implant sites in the same mouth. *Int J Oral Maxillofac Implants*. 1997 Sept-Oct;12(5):666-73.
75. Esposito M, Hirsch JM, Lekholm U, Thomsen P. Biological factors contributing to failures of osseointegrated oral implants I. Success criteria and epidemiology. *Eur J Oral Sci* 1998; 106: 527-551.
76. Szmukler-Moncler S, Salama H, Reingewirtz Y, Dubruille JH. Timing of loading and effect of micromotion on bone-dental implant interface: review of experimental literature. *J Biomed Mater Res*.1998; 43: 192-203.
77. Fu JH, Hsy YT, Wang HL. Identifying occlusal overload and how to deal with it to avoid marginal bone loss around implants. *Eur J Oral Implantol* 2012; 5(Suppl): S91-103.
78. Staubli N, Walter C, Schmidt JC, Weiger R, Zitzmann NU. Excess cement and the risk of peri-implant disease-a systematic review. *Clin Oral Implants Res* 2017; 28(10): 1278-1290.
79. Roberston K, Shabazian T, MacLeod S. Treatment of peri-implantitis and the failing implant. *Dent Clin N Am* 2015; 59: 329-343.
80. Linkevicius, T., Puisys, A., Vindasiute, E., Linkeviciene, L. & Apse, P. (2013) Does residual cement around implant-supported restorations cause peri- implant disease? A retrospective case analysis. *Clinical Oral Implants Research* 24: 1179-1184
81. Wilson T. The positive relationship between excess cement and peri-implant disease: a prospective clinical endoscopic study. *J Periodontol* 2009; 80(9): 1388-92.
82. Brånemark PI, Hansson BO, Adell R, Breine U, Lindström J, Hallen O, Ohman A. Osseointegrated implants in the treatment of the edentulous jaw. Experience from a 10-year period. *Scand J Plast Reconstr Surg Suppl* 1997; 16: 1-132.
83. Albrektsson T, Zarb G, Worthington DP, Eriksson R. The long-term efficacy of currently used dental implants. A review and proposed criteria of success. *Int J Oral Maxillofac Implants* 1986;1:11-25.
84. Monje A, Blasi G. Significance of keratinized mucosa/gingiva on peri-implant and adjacent periodontal conditions in erratic maintenance compliers. *J Periodontol*. 2019; 90: 445-453.
85. Avila-Ortiz G, Gonzalez-Martin O, Couso-Queiruga E, Wang HL. The peri-implant phenotype. *J Periodontol* 2020; 91(3): 283-288
86. Tonetti MS, Schmid J. Pathogenesis of implant failures. *Periodontol*. 2000. 1994;4:127-138.
87. Mombelli A, Müller N, Cionca N. The epidemiology of peri-implantitis. *Clin Oral Implants Res* 2012; 23(Suppl 6): 67-76.
88. Misch CE, Perel ML, Wang HL, et al. Implant success, survival, and failure: The International Congress of Oral Implantologists (ICOI) Pisa Consensus Conference. *Implant Dent*. 2008;17:5-15.
89. Tonetti MS. Risk factors for osseointegration. *Periodontol*. 2000. 1998; 17:55-62.
90. Becker W, Becker BE, Newman MG, et al. Clinical and microbiologic findings that may contribute to dental implant failure. *Int J Oral Maxillofac Implants*. 1990; 5:31-38.
91. Lang NP, Berglundh T, Heitz-Mayfield LJ, Pjetursson BE, Salvi GE, Sanz M. Consensus statements and recommended clinical procedures regarding implant survival and complications. *Int J Oral Maxillofac Implants*. 2004; 19(Suppl):150-154.
92. Schwarz F, Sculean A, Rothamel D, Schwenzer K, Georg T, Becker J. Clinical evaluation of an Er:YAG laser for nonsurgical treatment of peri-implantitis: A pilot study. *Clin Oral Implants Res* 2005;16:44-52.
93. Mombelli A, Feloutzis A, Bragger U, Lang NP. Treatment of peri-implantitis by local delivery of tetracycline. Clinical, microbiological, and radiological results. *Clin Oral Implants Res* 2001;12:287-294.
94. Salvi GE, Persson GR, Heitz-Mayfield LJA, Frei M, Lang NP. Adjunctive local antibiotic therapy in the treatment of peri-implantitis II: Clinical and radiographic outcomes. *Clin Oral Implants Res* 2007;18:281-285.
95. Augthun M, Richter E-J, Hauptmann S, Yildirim M. Untersuchungen zur Behandlung von tiefen periimplantären Knochentaschen mit ePTFE-Membranen. *Z Zahnärztl Implantol* 1992; 8: 246-250.

96. Roccuzzo M, Bonino F, Bonino L, Dalmaso P. Surgical therapy of peri-implantitis lesions by means of a bovine-derived xenograft: Comparative results of a prospective study on two different implant surfaces. *J Clin Periodontol* 2011; 38: 738-745.
97. Wiltfang J, Zernial O, Behrens E, Schlegel A, Warnke PH, Becker ST. Regenerative treatment of peri-implantitis bone defects with a combination of autologous bone and a demineralized xenogenic bone graft: A series of 36 defects. *Clin Implant Dent Relat Res* 2012; 14: 421-427.
98. Froum SJ, Froum SH, Rosen PS. Successful management of peri-implantitis with a regenerative approach: A consecutive series of 51 treated implants with 3- to 7.5-year follow-up. *Int J Perio Rest Dent* 2012; 32: 11-20.
99. Roos-Jansåker A-M, Renvert H, Lindahl C, Renvert S. Submerged healing following surgical treatment of peri-implantitis: A case series. *J Clin Periodontol* 2007; 34: 723-727.
100. Heitz-Mayfield LJA, Salvi GE, Mombelli A, Faddy M, Lang NP, Implant Complication Research G. Anti-infective surgical therapy of peri-implantitis. A 12-month prospective clinical study. *Clin Oral Implants Res* 2012; 23: 205-210.
101. Roos-Jansåker A-M, Renvert H, Lindahl C, Renvert S. Surgical treatment of peri-implantitis using a bone substitute with or without a resorbable membrane: A prospective cohort study. *J Clin Periodontol* 2007; 34: 625-632.
102. Romeo E, Ghisol M, Murgolo N, Chiapasco M, Lops D, Vogel G. Therapy of peri-implantitis with resective surgery. A 3-year clinical trial on rough screw-shaped oral implants. Part I: clinical outcome. *Clin Oral Implants Res* 2005; 16: 9-18.
103. Suarez F, Aparico C, Gil J, Kotsakis. Current understanding and future directions in implant surface decontamination. *Perio Clinica* 2023; 27(2): 119-129.
104. Valderrama P, Wilson Jr. TG. Detoxification of Implant Surfaces Affected by Peri-Implant Disease: An Overview of Surgical Methods. *Int J Dent* 2013; 740680: 1-9.
105. Kotsakis GA, Black R, Kum J, Berbel L, Sadr A, Karoussis I, Simopoulou M, Daubert D. Effect of implant cleaning on titanium particle dissolution and cytocompatibility. *J Periodontol* 2021; 92: 580-591.
106. Louropoulou A, Slot DE, Van der Weijden FA. Titanium surface alterations following the use of different mechanical instruments: a systematic review. *Clin Oral Implants Res* 2012; 11: 146-155.
107. Quirynen M, van der Mei HC, Bollen Cm, et al., An in vivo study of the influence of the surface roughness of implants on the microbiology of supra- and subgingival plaque. *J Dent Res* 1993; 72(9): 1304-1309.
108. Subramani K, Jung RE, Molenberg A, Hammerle CHF. Biofilm on dental implants: a review of the literature. *Int J Oral Maxillofac Implant* 2009; 24(4): 616-626.
109. Mengel R, Buns C-E, Mengel C, Flores-de-Jacby L. An in vitro study of the treatment of implant surfaces with different instruments. *Int J Oral Maxillofac Implant* 1998; 13(1): 91-96.
110. Park JB, Jang YJ, Koh M, Choi BK, Kim KK, Ko Y. In vitro analysis of the efficacy of ultrasonic scalers and a toothbrush for removing bacteria from RBM titanium discs. *J Periodontol* 2012; 84(8): 1191-1198.
111. Nee WY, Awang RAR, Hassan A. Effects of the titanium implant surface by different hygiene instrumentations: A narrative review. *Cureus* 2022; 14(10): e30884.
112. Augthun M, Tinschert J, Huber A. In vitro studies on the effect of cleaning methods on different implant surfaces. *J Periodontol* 1998; 69(8): 857-864.
113. Tastepe CS, van Waas R, Liu Y, Wismeijer D. Air powder abrasive treatment as an implant surface cleaning method: a literature review. *Int J Oral Maxillofac Implants* 2012; 27(6): 1461-1473.
114. Meyle J. Mechanical, chemical, and laser treatments of the implant surface in the presence of marginal bone loss around implants *Europ J Oral Implantol* 2012; 13(1): 91-96.
115. Chairay J-P, Boulekbache H, Jean A, Soyer A, Bouchard P. Scanning electron microscopic evaluation of the effect of an air-abrasive system on dental implants: a comparative in vitro study between machined and plasma-sprayed titanium surfaces. *J Periodontol* 1997; 68(12): 1215-1222.

116. Finlayson RS, Stevens FD. Subcutaneous facial emphysema secondary to use of the Cavi-Jet. *J Periodontol* 1988; 59(5): 315-317.
117. Bergendal T, Forsgren L, Kvint S, Lowstedt E. The effect of an airbrasive instrument on soft and hard tissues around osseointegrated implants: A case report. *Swed Dent J* 1990; 14(5): 219-223.
118. Dennison DK, Huerzeler MB, Quinones C, Caffese RG. Contaminated implant surfaces: an in vitro comparison of implant surface coating and treatment modalities for decontamination. *J Periodontol* 1994; 65(10): 942-948.
119. Gosau M, Hahnel S, Schwarz F, Gerlach T, Reichert TE, Burgers R. Effect of six different peri-implantitis disinfection methods on in vivo human oral biofilm. *Clin Oral Implants Res* 2010; 21(8): 866-872.
120. Guimaraes LF, Fidalgo TK, Menezes GC, Primo LG, Costa e Silva-Filho F. Effects of citric acid on cultured human osteoblastic cells. *Oral Surg, Oral Med, Oral Path, Oral Radiol, Endodont* 2010; 110(5): 665-669.
121. Lan WC, Lan WH, Chan CP, Hsieh CC, Chang MC, Jeng J-H. The effects of extracellular citric acid acidosis on the viability, cellular adhesion capacity, and protein synthesis of cultured human fibroblasts. *Austral Dent J* 1999; 44(2): 123-130.
122. Cohen DW, Atlas SL. Chlorhexidine gluconate in periodontal treatment. *Compendium Suppl* 1994; 18(Suppl): S711-S714.
123. Verdugo F, Saez-Roson A, Uribarri A, et al. Bone microbial decontamination agents in osseous grafting: an in vitro study with fresh human explants. *J Periodontol* 2011; 82(6): 863-871.
124. Gianelli M, Chellini F, Margheri M, Tonelli P, Tani A. Effect of chlorhexidine digluconate on different cell types: A molecular and ultrastructural investigation. *Toxicology in Vitro* 2008; 22(2): 308-317.
125. Zablotsky MH, Diedrich DL, Meffert RM. Detoxification of endotoxin-contaminated titanium and hydroxyapatite-coated surfaces utilizing various chemotherapeutic and mechanical modalities. *Implant Dent* 1992; 65(10): 154-158.
126. Burgers R, Wittey C, Hahnel S, Gosau M. The effect of various topical peri-implantitis antiseptics on *Staphylococcus epidermidis*, *Candida albicans*, and *Streptococcus sanguinis*. *Archives Oral Biol* 2012; 57(7): 940-947.
127. Tinti C, Parma-Benefati S. Treatment of peri-implant defects with the vertical ridge augmentation procedure: a patient report. *International J Oral Maxillofac Implants* 2001; 16(4): 572-577.
128. Park J-B. Treatment of peri-implantitis with deproteinized bovine bone and tetracycline: A case report. *Gerodontology* 2011; 29(2): 145-149.
129. Schwarz F, Sahm N, Becker J. Combined surgical therapy of advanced peri-implantitis lesions with concomitant soft tissue augmentation. A case series. *Clin Oral Implants Res* 2014; 25(1): 132-136.
130. Schwarz F, John S, Mainusch S, Sahm N, Becker J. Combined surgical therapy of peri-implantitis evaluating two methods of surface debridement of decontamination. A two-year clinical follow-up report. *J Clin Periodontol* 2012; 39(8): 789-797.
131. Kotsakis GA, Lan C, Barbosa J, Lill K, Chen R, Rudney J, Aparicio C. *J Periodontol* 2016; 87(7): 809-819.
132. Mills MP, Rosen PS, Chambrone L, Greenwell H, et al. American Academy of Periodontology best evidence consensus statement on the efficacy of laser therapy used alone or as an adjunct to non-surgical and surgical treatment of periodontitis and peri-implant diseases. *J Periodontol* 2018; 89:737-742.
133. Cheng Y, Chen JW, Ge MK, Zhou ZY, Yin X, Zou SJ. Efficacy of adjunctive laser in non-surgical periodontal treatment: a systematic review and meta-analysis. *Lasers Med Sci* 2016; 31: 151-163.
134. Natto ZS, Aladmawy M, Levi PA Jr Wang H-L. Comparison of the efficacy of different types of lasers for the treatment of peri-implantitis: A systematic review. *Int J Oral Maxillofac Implants*. 2015; 30: 338-345.

135. Convissar RA, Goldstein EE. An overview of lasers in dentistry. *Gen Dent* 2003; 51: 436-440.
136. Geisinger ML, Holmes CM, Vassilopoulos PJ, Geurs NC, Reddy MS. Is Laser Disinfection an Effective Adjunctive Treatment to Bone Augmentation for Peri-implantitis? A review of current evidence. *Clin Adv Periodont* 2014; 4(4): 274-279.
137. Tosun E, Tasar F, Strauss R, et al. Comparative evaluation of antimicrobial effects of Er:YAG, diode, and CO2 lasers on titanium discs: an experimental study. *J Oral Maxillofac Surg* 2012; 70: 1064-1069.
138. Stubinger S, Etter C, Miskiewicz M, et al., Surface alterations of polished and sandblasted and acid-etched titanium implants after Er:YAG, carbon dioxide, and diode laser irradiation. *Int Oral Maxillofac Implants* 2010; 25: 104-111.
139. Park JH, Heo SJ, Koak JY, et al., Effects of laser irradiation on machined and anodized titanium disks. *Int J Oral Maxillofac Implants* 2012; 27: 265-272.
140. Chambrone L, Wang H-L, Romanos GE. Antimicrobial photodynamic therapy for the treatment of periodontitis and peri-implantitis: An American Academy of Periodontology best evidence review. *J Periodontol* 2018; 89: 783-803.
141. Marotti J, Tortamano P, Cai S, et al., Decontamination of dental implant surfaces by means of photodynamic therapy. *Lasers Med Sci* 2013; 28: 303-309.
142. Ashnagar S, Nowzari H, Nokbatolfoghahaei H, Zadeh BY, Chiniforush N, Zadeh NC. Laser treatment of peri-implantitis: A literature review. *J Lasers Med Sci* 2014; 5(4):153-62.
143. Lin G-H, López del Amo FS, Wang H-L. Laser therapy for treatment of peri-implant mucositis and peri-implantitis: An American Academy of Periodontology best evidence review. *J Periodontol* 2018; 89: 766-782.
144. Axelsson P., Lindhe J. The significance of maintenance care in the treatment of periodontal disease. *J Clin Periodontol* 1981; 8: 281-294.
145. Rosling B., Serino G., Hellstrom M.K., Socransky S.S., Lindhe J. Longitudinal periodontal tissue alterations during supportive therapy. Findings from subjects with normal and high susceptibility to periodontal disease. *J Clin Periodontol* 2001; 28: 241-249.
146. Hirschfeld L., Wasserman B. A long-term survey of tooth loss in 600 treated periodontal patients. *J Periodontol* 1978; 49: 225-237.
147. Chambrone L.A., Chambrone L. Tooth loss in well-maintained patients with chronic periodontitis during long-term supportive therapy in Brazil. *J Clin Periodontol* 2006; 33: 759-764.
148. Frisch E, Vach K, Ratka-Krueger P. Impact of supportive implant therapy on peri-implant diseases: A retrospective 7-year study. *J Clin Periodontol* 2020; 47: 101-109.
149. Curtis DA, Lin G-H, Fishman A, Sadowsky SJ, Daubert DM, Kapila Y, Sharma AB, Conte GJ, Yonemura CY, Marinello CP, Kao R. Patient-centered risk assessment in implant treatment planning. *Int J Oral Maxillofac Implants* 2019; 34(2): 506-520.

### Additional Resources

- No Additional Resources Available



## About the Author

### **Maria (Mia) L. Geisinger, DDS, MS**



Mia L. Geisinger, DDS, MS is a Professor and Director of Advanced Education in Periodontology in the Department of Periodontology in the University of Alabama at Birmingham (UAB) School of Dentistry. Dr. Geisinger received her BS in Biology from Duke University, her DDS from Columbia University School of Dental Medicine, and her MS and Certificate in Periodontology and Implantology from the University of Texas Health Science Center at San Antonio. Dr. Geisinger is a Diplomate in the American Board of Periodontology and a Fellow in the International Team for Implantology. She has served as the President of the American Academy of Periodontology Foundation, as the Chair of the American Dental Association's Council on Scientific Affairs, as a Board member for the ADA Science and Research Institute, and on multiple national and regional organized dentistry committees. She currently serves as the President of the American Academy of Periodontology and on numerous AAP, AADOCR and ADA committees and task forces. She has authored over 75 peer-reviewed publications and serves on the editorial and advisory boards of several journals. Her research interests include periodontal and systemic disease interaction, implant dentistry in the periodontally compromised dentition, and novel treatment strategies for oral soft and hard tissue regeneration. She lectures nationally and internationally on topics in periodontology and oral healthcare.

Email: [miagdds@uab.edu](mailto:miagdds@uab.edu)