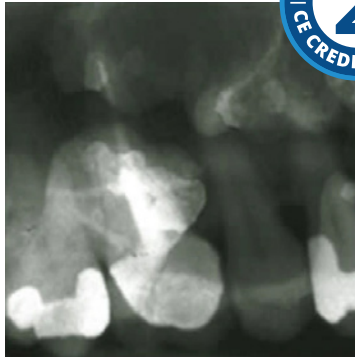


Intraoral Imaging: Basic Principles, Techniques and Error Correction



Course Author(s): Gail F. Williamson, Professor Emerita

CE Credits: 2 hours

Intended Audience: Dental Hygienists, Dental Assistants, Dental Students, Dental Hygiene Students, Dental Assisting Students

Date Course Online: 03/01/2018

Last Revision Date: 10/31/2024

Course Expiration Date: 10/30/2027

Cost: Free

Method: Self-instructional

AGD Subject Code(s): 731

Online Course: www.dentalcare.com/en-us/ce-courses/ce559

Disclaimers:

- P&G is providing these resource materials to dental professionals. We do not own this content nor are we responsible for any material herein.
- Participants must always be aware of the hazards of using limited knowledge in integrating new techniques or procedures into their practice. Only sound evidence-based dentistry should be used in patient therapy.

Conflict of Interest Disclosure Statement

- Prof. Williamson reports no conflicts of interest associated with this course. She has no relevant financial relationships to disclose.

Short Description

Intraoral Imaging: Basic Principles, Techniques and Error Correction is a free dental continuing education course that covers a wide range of topics relevant to the oral healthcare professional community.

Course Contents

- Overview of Intraoral Image Receptors
- Principles of Accurate Image Projection
- Intraoral Radiographic Techniques
- Patient Management
- Technique Errors
- Exposure and Miscellaneous Errors
- Conclusion
- References / Additional Resources

Overview

This course will focus on intraoral imaging basic principles, techniques and error correction. Appropriately prescribed intraoral radiographic images are an important component of patient diagnosis and treatment. Radiographs are especially helpful in the diagnosis of dental caries, periodontal bone loss, periapical pathoses, and other observations that may impact patient treatment. It is of the utmost importance that dental professionals are competent in taking intraoral and extraoral radiographic images that are diagnostically acceptable while keeping the radiation exposure to patients as low as reasonably achievable.

The dental radiographer must have a working knowledge of radiographic image receptors and intraoral radiographic techniques to produce quality images. Occasionally, errors will occur which can result in undiagnostic radiographic images. When errors do occur, the radiographer must have the requisite skills to evaluate, correct, and ultimately eliminate the errors. A review of image receptors and the following troubleshooting steps can help correct and subsequently prevent common errors.

Syllabus: Dental Radiology

The information in this 12-module syllabus is intended (1) to meet elements of initial educational/training requirements for Dental Students, Dental Hygiene Students, and Dental Assistant Students related to dental radiography; (2) to provide a framework for an in-service training program in oral healthcare settings to meet annual educational/training requirements as mandated by federal, state, local and professional organizations; and (3) to serve as a resource for oral healthcare personnel wishing to review evidence-based information on specific topics related to dental

radiography. A PDF is available for each module that may serve as a convenient resource.

[LEARN MORE](#)

Learning Objectives

Upon completion of this course, the dental professional should be able to:

- Describe image receptors used to acquire intraoral radiographic images.
- List and describe the principles of accurate image projection.
- Identify, describe, and compare intraoral radiographic techniques.
- Discuss patient management strategies to assist in error avoidance.
- Identify and describe how to correct intraoral radiographic image errors.

Overview of Intraoral Image Receptors

Intraoral radiographic images can be acquired with digital receptors or radiographic film (Figure 1). All three modalities are available for use. Digital image receptors include rigid sensors and phosphor plate receptors. Intraoral digital receptors are available in sizes comparable to traditional dental film. Rigid digital receptors are typically available in sizes 0, 1, and 2 while the plate receptors are available in sizes 0, 1, 2, 3, and 4. The range of available sizes is dependent on the specific product manufacturer. Digital receptors cannot be sterilized. Therefore, it is important to utilize proper infection control techniques to prepare and cover digital receptors for placement inside the mouth and effective barrier removal following completion of the survey. Refer to manufacturer recommendations for proper infection control procedures for digital receptors both rigid sensors and phosphor plates.

Rigid digital receptors are categorized as direct digital devices. These rigid receptors are usually either a charge-coupled device (CCD) or complementary metal oxide semiconductor (CMOS) sensors with the latter being the most common. The same receptor can be used for each projection by repositioning the receptor for the next view after each exposure. These direct digital receptors convert the x-ray beam into an electronic signal, which is then displayed as a grayscale image and stored in a computer. The direct digital image can be viewed on the computer monitor almost immediately.



Figure 1: Rigid CCD Digital Sensor

Digital Phosphor Plate

F-Speed Dental Film

Indirect digital receptors known as storage phosphor plates (SPP) or photostimulable phosphor plates (PSP) are also available. These plates have a europium-activated barium fluorohalide emulsion which stores the latent image after exposure. A separate plate is needed for each projection and the plates must be erased with white light before reuse. After the plate is exposed, the receptor is laser scanned and the image is digitized and displayed on the computer monitor. In newer scanner models, plate erasure occurs after the scanning step but before exit of the plate from the device. Phosphor plates require careful handling to avoid abrasion of the emulsion and resultant image artifacts.²

Digital images can be adjusted to view the information in different ways. Software enhancement features include changes in density, contrast, colorization, zoom or magnification of particular areas of interest, measurement, image reversal and the application of filters for noise reduction or edge sharpening. These tools allow the clinician to view the captured image in different ways. Image enhancement tends to be subjective and is dependent on the visual preferences of the clinician interpreting the image.³ There is some evidence in the literature that suggests post-processing or image enhancement applications may not necessarily improve the diagnostic utility of the image and, at times, may lead to inaccurate interpretation.³⁻⁸

Subtraction can also be performed using digital images. This is the process used to compare an area before and subsequent to treatment to assess progress or change. The computer subtracts the two images and the image that remains represents the difference or change between pre- and post-treatment. The challenge

with digital subtraction is the need to register the images prior to subtraction. The images are seldom identical in their placement or projection geometry and must be matched structurally in order to determine the actual change that occurred between the two images taken at different points in time.^{2,3}

After the image has been obtained, it can be viewed and stored on the computer, printed, or sent electronically in instances of referral or insurance claims. Digital radiography facilitates storage and easy access for image viewing, duplication, printing, or electronic transfer. Digital imaging is an integral part of a complete electronic record without the need for physical storage space and concern that the images will be damaged or destroyed. However, it is important to back-up patient records daily to avoid lost data. There are a variety of media that can be used for back-up storage such as external hard drives, CDs, DVDs, or cloud technology.

Digital imaging like film radiography utilizes x-ray beam collimators to reduce the area of exposure at the skin surface with a preference for rectangular collimation and receptor holding devices to reduce retakes. Rectangular collimation more so than round reduces both primary and scatter radiation which not only benefits the patient by reducing exposure but also improves image quality.^{3,8} Because digital receptors are more sensitive to scatter radiation than film, rectangular collimation is recommended for use with digital imaging systems. There are a number of commercially available devices that the clinician can utilize to achieve rectangular collimation and reduce exposure.^{3,9} Current digital receptors offer equal or greater dose reduction than F-speed film and comparable diagnostic utility.³

The majority of technique and exposure errors can be produced with digital receptors and conventional film with a few exceptions. The greatest advantage of digital imaging is elimination of processing errors which are the most common causes of retakes in film-based radiography. In addition, digital imaging also eliminates the darkroom, processor and chemical maintenance which requires additional time and effort when done properly, and lengthy processing time. Regardless of the imaging system employed, the clinician should take all necessary steps to reduce the amount of radiation the patient receives in compliance with the ALARA Principle (As Low As Reasonably Achievable). Primary to dose reduction is the application of selection criteria in the determination of necessary radiographs.¹

Principles of Accurate Image Projection

To better understand x-ray imaging, it is helpful to consider a radiograph as a picture of the projected image of the teeth and surrounding structures similar to a photograph. Whether using rigid or phosphor plate digital receptors or conventional film, the purpose of the receptor is to capture the projected image or area of interest. In discussing the principles of accurate image projection, the source of x-ray photons is the focal spot on the anode target inside the x-ray tube within the x-ray head (Figure 2). The principles of accurate image projection can be summarized as follows:

Principle One: X-rays Should be Emitted from the Smallest Source of Radiation Possible.

As electrons strike the focal spot, x-rays are emitted. The smaller the focal spot is inside the x-ray tubehead, the greater the detail or resolution of the resultant image. Manufacturers govern the size of the focal spot, and it cannot be changed by the operator. However, the focal spot can become enlarged over time due to continuous machine use.³ This enlargement is often referred to as “blooming” of the focal spot. When focal spot enlargement does occur, the resultant radiographic image becomes less sharp

or fuzzy in appearance.³ X-ray machines in high-use operatories may exhibit signs of blooming before other intraoral x-ray machines in the office as a consequence of the greater workload and excessive heat generation. The focal spot should be monitored through a quality

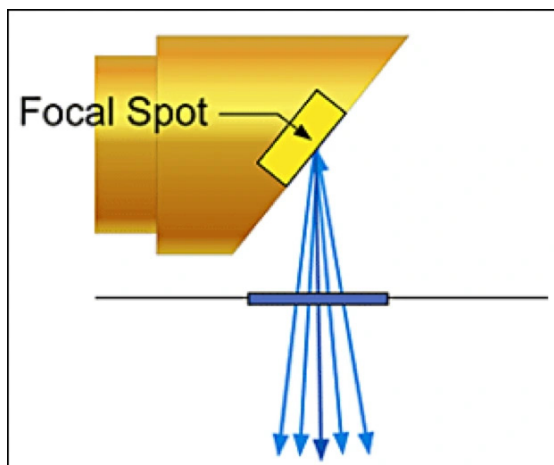


Figure 2: Focal Spot

assurance program. Resolution test devices will determine any change in the focal spot size and can indicate when an x-ray head may need to be replaced. Specialized equipment is required to conduct this test.³ This test may be part of periodic state-mandated x-ray machine inspections.

Principle Two: The X-ray Source-to-Object Distance Should be as Long as Possible.

The x-ray source-to-object distance (Figure 3) refers to the distance between the focal spot and the object to be recorded. The use of a long open-ended position indicating device (PID or cone) will enable the x-ray photons to emerge in a straighter line, therefore, producing a more dimensionally accurate image. The straighter the x-ray photon line, the less divergent the x-ray beam. The resultant image will be a sharper, more accurate representation of the structures being radiographed and demonstrate less image magnification.



Figure 3: Source-to-Object Distance

Principle Three: The Object-to-Receptor Distance Should be as Short as Possible.

The object in this principle refers to the tooth or anatomical structures being radiographed. Placing the receptor as close as possible to the object reduces magnification and improves image sharpness (Figure 4). The bisecting angle technique follows this single principle more than the paralleling technique. However, the bisecting angle technique does not conform to the other principles of accurate image projection. As a result, it is more prone to shape distortion and is not recommended as the primary technique. Shape distortion is defined as deviation from the true shape or dimension of the object. The bisecting angle technique is considered a secondary method but may be a necessary compromise in certain clinical situations such as a shallow plate or presence of tori.

Principle Four: The Receptor and Long Axis of the Tooth Should be Parallel to Each Other.

When the receptor and the long axis of the tooth are parallel to each other (as in the paralleling technique), the distortion of the radiographic image is minimized. When this alignment is achieved, the x-ray beam is directed perpendicular (right angle) to both the object and receptor (Figure 5). Receptor to structure parallelism improves anatomic accuracy and reduces shape distortion.

Principle Five: The X-ray Beam Should be Directed Perpendicular to the Tooth and Receptor.

The x-ray beam must be directed perpendicular or at a right angle to the long axis of the tooth, which ideally is also perpendicular to the receptor (Figure 6). When this principle is not followed, an error in vertical angulation or length is seen, and the resultant image will appear either foreshortened (shorter than the actual object) or elongated (longer than the actual object). Right angle entry of the x-ray beam improves anatomic accuracy and reduces shape distortion. Table 1 provides a summary of these principles and their impact on radiographic imaging.

These same principles of accurate image projection can be demonstrated by using a flashlight and projecting the shadow of an

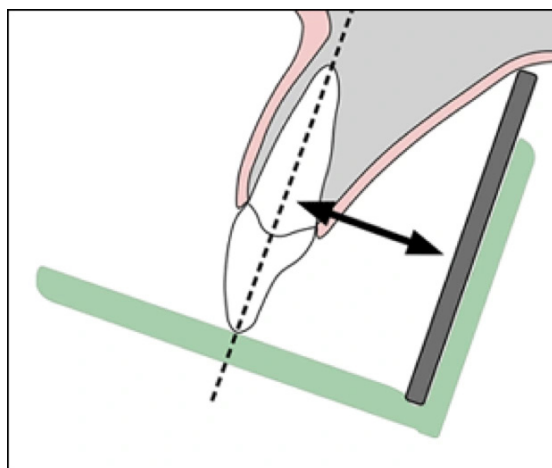


Figure 4: Object-to-Receptor Distance

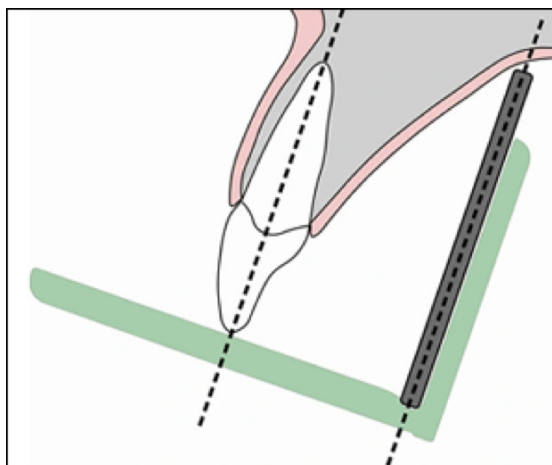


Figure 5: Object-Receptor Parallelism

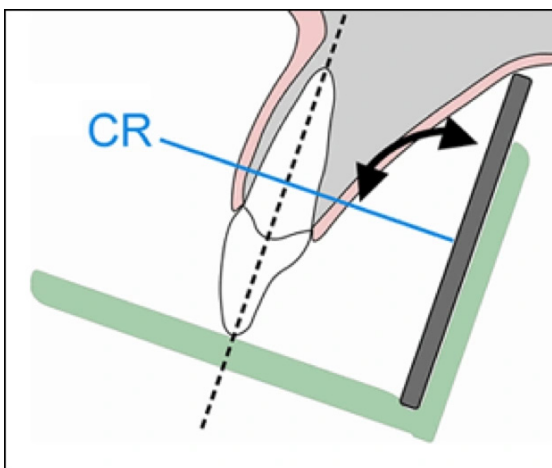


Figure 6: CR Entry

Principles	Outcomes
1. X-rays should be emitted from the smallest source of radiation possible	Improves image resolution Reduces geometric unsharpness
2. X-ray source-to-object distance should be as long as possible	Improves image resolution Reduces geometric unsharpness
3. Object-to-receptor distance should be as short as possible	Improves image resolution Reduces geometric unsharpness
4. Receptor and long axis of the tooth should be parallel to each other	Improves anatomic accuracy Reduces shape distortion
5. X-ray beam should be directed perpendicular to the tooth and the receptor	Improves anatomic accuracy Reduces shape distortion

Table 1. Principles of Accurate Image Projection Summary.

object or objects onto a wall in a dark room. Completing this simple exercise may help the novice radiographer better understand how to apply these principles and their role in producing an accurate image. Also, it provides insight into how and why technical errors occur when these principles are violated.

The “perfect” radiographic technique incorporates all five principles of accurate image projection simultaneously. Unfortunately, an ideal technique which meets all the requirements for accurate image projection has not been identified. The paralleling technique, which typically utilizes receptor-holding devices, is the preferred intraoral technique because it follows four of the five principles of accurate image projection listed above.

Intraoral Radiographic Techniques

Prior to presenting technique errors and the means to troubleshoot them, a clear understanding of technique must be established. Although the bisecting angle technique is still utilized and may be necessary in certain circumstances, the paralleling technique is the method of choice for intraoral radiography. However, the use of bisecting

angle technique remains relevant due to the increasing use of rigid digital receptors for intraoral radiography. Rigid digital receptors are more difficult to place comfortably in the mouth particularly in children and the posterior regions of the mouth in adults.¹³ In addition, rigid receptors are difficult to place truly parallel to the teeth due to their thickness and rigid construction which contributes to a higher rate of retakes. The use of rigid digital receptors produces more retakes due to technical errors than phosphor plate receptors or film.¹⁴ A good understanding of bisecting angle technique is necessary to correct dimensional errors associated with placement difficulties as well as instances when occlusal techniques are utilized for intraoral radiographic imaging particularly with rigid digital receptors.

Paralleling Technique

As previously discussed, the paralleling technique is the most accurate intraoral radiographic technique, meeting four of the five principles of accurate image projection. The paralleling technique does not allow for an as short as possible object-to-receptor distance (Principle Three) as desired. In order to achieve parallelism, it is necessary to place the receptor more lingual to the structures where there is

adequate depth and space to place the receptor. The use of receptor-holding devices helps to standardize and execute this technique but attention to the relationship of the receptor to the object(s) of interest is critical to successful outcomes.

The paralleling technique is accomplished by placing the receptor parallel to the long axis of the tooth. After this parallel relationship has been established, the central ray must be directed perpendicular to both the tooth and receptor. Because the receptor cannot always be placed as close as possible to the tooth due to the receptor-holding device or anatomical obstacles, image magnification may occur. However, this can be compensated for by using an increased source-object distance, which decreases magnification and unsharpness. The paralleling technique, when performed correctly, is superior to the bisecting angle technique because it produces an image with both linear and dimensional accuracy.

Bisecting Angle Technique

The bisecting angle technique is accomplished by placing the receptor as close to the tooth as possible. The central ray of the x-ray beam should be directed perpendicular to an imaginary line that bisects or divides the angle formed by the long axis of the tooth and the plane of the image receptor (Figure 7). Principle Three of accurate image projection is met by using this technique.

Images produced by the bisecting angle method are in true linear relationship. However, this technique does not follow several of the principles of accurate image projection and also requires correct visualization of the bisected angle in order to accomplish it properly. Bisecting angle images are not anatomically accurate and are prone to shape distortion. If the radiographer has difficulty visualizing the bisecting plane, start with placement of the open end of the PID parallel to the vertical plane of the receptor, then reduce the vertical angulation until it is halfway between the plane of the receptor and the teeth. The bisecting angle provides an alternative technique when parallel placement cannot be achieved, or occlusal radiographic techniques are employed.

Occlusal radiographic techniques may need to be utilized when either arch is too narrow to permit placement of the receptor behind the structures of interest or when anatomical obstacles like tori fill the palate or floor of the mouth.

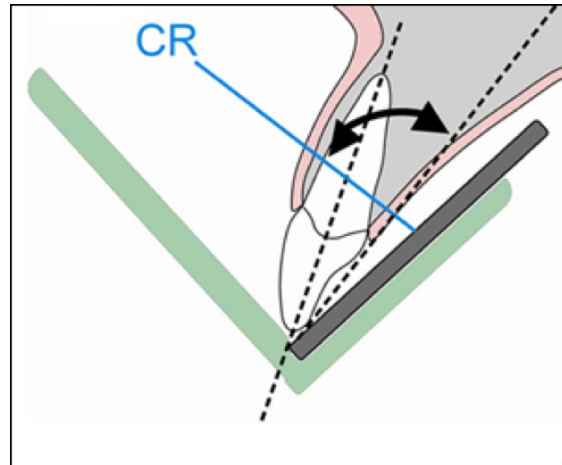


Figure 7: Bisecting Angle Technique

Bitewing Technique

The bitewing radiographic image is used to examine the interproximal surfaces of the teeth and is particularly useful for the detection of dental caries and the evaluation of alveolar bone levels. The receptor is placed into the mouth parallel to the crowns of the maxillary and mandibular posterior teeth. The patient stabilizes the receptor by biting on a tab or bitewing holder. The central ray of the x-ray beam is then directed through the contacts of the posterior teeth in occlusion and at a +5° to +10° vertical angle. Receptor-holding devices or bitewing tabs may be used to stabilize the receptor in the mouth. Receptors may be positioned in the horizontal (Figure 8) or vertical (Figure 9) dimension with this technique, depending upon the area to be examined. Bitewings may be taken in the anterior segments of the dentition as well. Some dentists, particularly periodontists, may prescribe a 7-image bitewing survey consisting of 4 vertical bitewings in the posterior using a size 2 receptor and 3 vertical bitewings in the anterior using a size 1 receptor. This permits evaluation for both alveolar bone loss and caries detection in the anterior and posterior regions of the mouth.

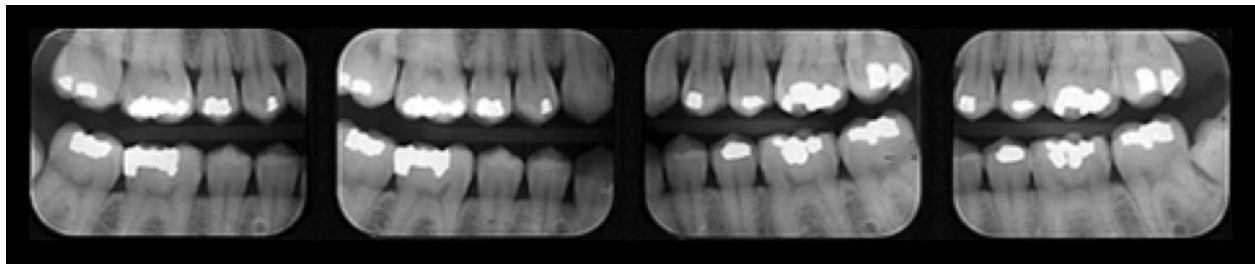


Figure 8: Four Posterior Bitewing Survey

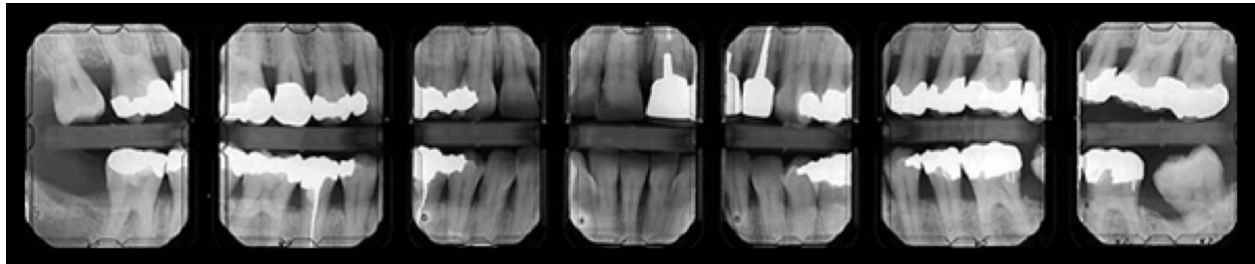


Figure 9: Seven Image Bitewing Survey

Patient Management

Before radiographs are taken, the patient must be informed about the procedure and consent obtained. It is important to provide the patient with clear instructions to prepare them for the task at hand.

Patient Preparation Errors

Dental professionals should always explain the radiographic procedure to the patient and provide instructions as to what the patient can do to help ensure a quality image, avoid retakes, and reduce radiation exposure. The most common error in this category is movement. Factors causing a patient to move include:

- discomfort
- unsupported head position
- gagging and/or swallowing
- patient disability

Discomfort

Discomfort can be addressed by gentle, proper receptor placement, instructing the patient to close slowly, and the use of cushioned edges which can be attached to the receptor (Figure 10). Receptors placed more toward the midline of the palate and toward the tongue on the mandible will make placement more comfortable for the patient. Bending, folding, or creasing film or a digital phosphor plate receptor will produce artifacts that may compromise the diagnostic quality of the radiographic image.




Figure 10: Edge Ease® and Slip Ease®, Strong Dental Products, Crosstex® International

Head Support

The headrest on the dental chair should be placed against the occipital lobe at the base of the back of the head. This will support the head during radiographic procedures and reduce the chance of movement. Proper headrest placement positions the occlusal plane parallel to the floor and the midsagittal plane perpendicular to the floor for maxillary periapicals and bitewings. It is helpful to readjust the head to raise the patient's chin up slightly for mandibular periapicals. This improves visibility into the floor of the mouth for receptor placement and keeps the floor of the mouth more relaxed.

Gagging/Swallowing

The gag reflex is a protective mechanism of the body that serves to clear the airway of obstruction. All patients have gag reflexes, some more sensitive than others. The gag reflex can be stimulated when the receptor contacts the soft palate, base of the tongue, or the posterior wall of the pharynx. For some patients, gagging may be associated with a past negative dental experience. Patience and reassurance are necessary to help the patient overcome their anxiety. When exposing a full mouth survey of radiographic images, it is recommended to begin in the anterior region of the mouth. An anterior placement is less likely to stimulate the gag reflex and will also help the patient become more accustomed and comfortable with the procedure.

To ensure a quick and smooth patient experience, prepare all equipment before the receptor is placed inside the mouth. The exposure time should be set in advance, and the x-ray tubehead should be placed in the approximate area of exposure. It may help to encourage the patient to swallow once before the placement of the receptor. It is best not to mention gagging or to give excessive of tongue instructions. Start placements in the anterior region of the mouth particularly when a complete full mouth survey is indicated. In addition, the patient can be instructed to release the biting pressure or remove the receptor as soon as the exposure is complete. Other recommended procedures to control gagging include deep breathing through the nose or mouth, anesthetizing the mouth with lozenges, mouthwash, topical anesthetic agents, or refocusing the patient's attention.¹⁵ The use of a sprinkle of salt on the tongue; patient self-application of pressure on a point in the palm of the hand, the inner forearm, on the chin, or by tapping the temporal bone near the ear can help reduce the gag reflex.¹⁵⁻¹⁷ Distraction techniques such as instructing the patient to raise one leg, bend the toes toward the body, humming, etc. will focus attention on the task rather than on gagging. When a patient begins to gag, remove the receptor, be confident and reassuring, and try again. A panoramic radiographic image may be a useful adjunct to intraoral radiographic images when the molar projections are extremely difficult for the patient to tolerate or for the clinician to obtain.

Patient Disability

Some patients may need assistance during the radiographic procedure due to physical or cognitive disability, injury, or medical condition. In such circumstances, it may be necessary to ask a family member or guardian to assist in holding the patient in position. Shielding should be provided for both the patient and person providing the assistance. The clinician must consider what technique would work best in the situation. For instance, a patient with Parkinson disease can better tolerate intraoral radiographs, which have short exposure times, rather than a panoramic image which requires a sustained still position and a longer exposure cycle. Familiarity with the bisecting angle and occlusal radiographic techniques may be useful in situations that are less than ideal and require alternative approaches to imaging. Patients who have considerable disability or who are unable to cooperate may best be served and treated by a pediatric dentist.

Technique Errors

Receptor Placement Errors

Correctly exposing intraoral receptors includes four basic steps: receptor placement, vertical PID (cone) angulation alignment, horizontal PID (cone) angulation alignment, and central ray centering. Technique errors can occur if any of these steps are completed improperly. Placement errors will be discussed first as they are the most common of all errors.

Inadequate Coverage/Missing Apices

A common receptor placement error is inadequate coverage of the area to be examined radiographically. This typically occurs in molar projections when the patient has difficulty maintaining or tolerating proper receptor placement. Each periapical and bitewing in a complete survey has established placement criteria which describes the structures of interest that should be recorded on each view. Consistent application of these criteria will minimize this error and ensure coverage of all required structures.

Missing apices can be caused by a receptor placement error (Figure 11). When using receptor holders, the bite block should be placed on the incisal or occlusal aspect of the teeth to be imaged and not on the opposing teeth. If the bite block is placed on the

opposing teeth and the patient is required to bite the receptor into place, a placement error is likely to occur. Placing the receptor more lingual to the teeth where the palate and floor are deeper will make positioning easier and more comfortable for the patient. This is important when placing the receptor for bitewings so that the receptor is not displaced by anatomical structures (Figure 12). Placement of the bite block and receptor in the correct position first and then having the patient slowly bite to maintain the placement is the preferred and most effective approach.

Tilted Occlusal Plane

When the receptor is not placed perpendicular to the occlusal plane, the occlusal plane will appear slanted or diagonal on the recorded image (Figures 13 A and B). When exposing bitewing radiographs, the top edge of the receptor may come in contact with the palatal gingiva or curvature of the palate or the lingual aspect of the mandible. When this occurs, the occlusal plane will appear crooked. The receptor must be placed straight or perpendicular with the occlusal plane or placed farther away from the teeth to avoid this error. For periapicals, always place the bite block in contact with the occlusal or incisal surfaces of the teeth you are imaging rather than on the opposing teeth. Also, this error can occur when the cheek soft tissue is behind the biteblock rather than around it.

Placement on the opposing teeth or too close to the teeth, or with cheek interference will cause the receptor to displace when it contacts bony anatomy. Preferably, the receptor orientation dot or plate marker should be placed toward the crowns of the teeth for periapical images and toward the mandible for bitewing images to reduce interference with viewing the structures of interest on the recorded image.

Backward Placement

The exposure side of any receptor must be directed toward the x-ray source to produce an acceptable image. Backwards placement is unlikely with rigid digital receptors because of the wire attachment on the non-exposure side of the sensor.

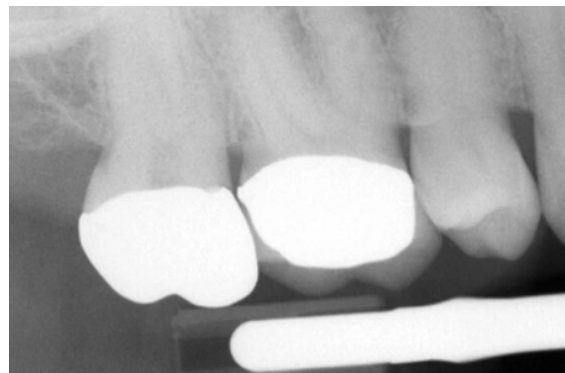


Figure 11: Periapical – Maxillary Apices Cut Off

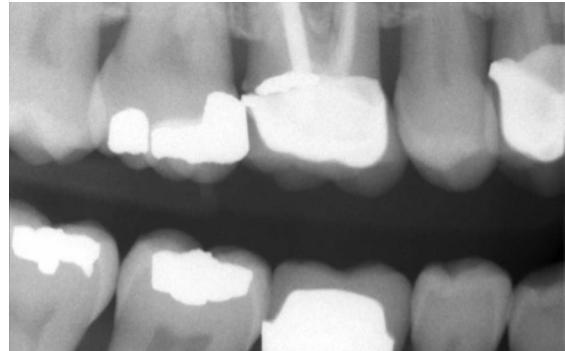


Figure 12: Bitewing – Mandibular Bone Margin Cut Off

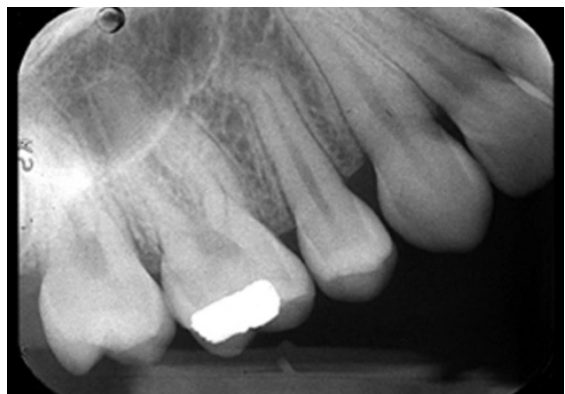

Figure 13A: Tilted Maxillary Occlusal Plane

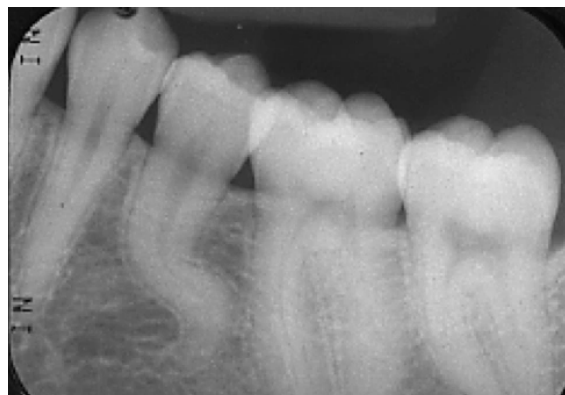

Figure 13B: Tilted Mandibular Occlusal Plane

Backward placement of a film in the mouth causes the lead foil inside the packet to face the radiation source instead of the film directly (Figure 14A). The x-ray beam is attenuated by the lead foil before striking the film. This causes the embossed pattern on the foil, a herringbone or diamond effect, to appear on the processed film (Figure 14B).

This error also results in a lighter image and reversal of the image. This can lead to confusion about the correct anatomical area recorded when mounting the processed film images. Backwards phosphor plate receptor placement (15A) also produces a low density and reversed image.

Bending

Plate or film bending may occur due to contact with the curvature of the palate or lingual arch and/or mishandling of the receptor. These receptors can be flexed but should never be bent. If the receptor is too large for the area, bending or curving can occur. Select a receptor size that will adequately cover the area without producing excessive discomfort to the patient. Crimping, creasing, or folding a plate or film receptor damages the emulsion and compromises the quality of the image (Figures 16 and 17). Careful handling, use of a smaller receptor, and correct placement will address the problems of bending and other receptor distortions that produce image artifacts.

Rigid digital receptors cannot be bent but as previously indicated phosphor plate receptors can be creased, bent, scratched, or folded. These alterations result in permanent damage of the plate and produce artifacts on the current and any subsequent image taken with the marred plate.²

Damaged plates should be replaced when the artifacts interfere with the production of diagnostic images. Tissue cushions are better alternatives than bending or creasing a plate or film receptor.



Figure 14A: Rear Side of Film Packet

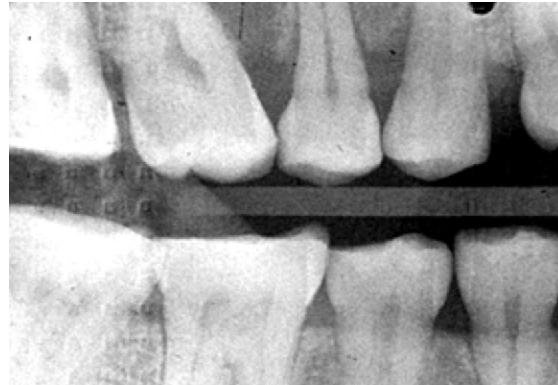

Figure 14B: Backwards Film Image

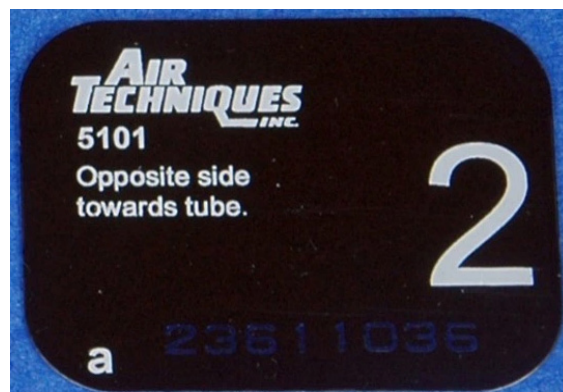

Figure 15A: Rear Side of Plate




Figure 15B: Exposure Side of Plate

Vertical Alignment Errors

Vertical angulation controls the length of the recorded image. When using the paralleling technique and receptor holders, the vertical angulation is dictated by the holding device to direct the x-ray beam perpendicular to both the teeth and receptor. Therefore, it is important that the clinician place the receptor parallel to the teeth to ensure proper vertical angulation. In contrast, when using the bisecting angle technique, the beam is perpendicular to the plane that bisects or divides the angle formed by the teeth and the receptor. Vertical alignment errors often occur with the bisecting angle technique and can result in elongation or foreshortening of the teeth. Other errors that can occur which cause the teeth to appear elongated or foreshortened include:

- receptor position
- patient position

It is important to determine the cause of the error in order to correct it.

Elongation

Elongation or lengthening of the recorded teeth and surrounding structures results from underangulation of the x-ray beam (not enough vertical angle) as seen in Figure 18. When elongation occurs using the paralleling technique, the angulation of the x-ray beam is less than the long axis plane of the teeth (Figure 19B). To correct this error the clinician must increase the vertical angulation. In other words, for the maxillary arch, the positive vertical angulation must be increased (PID pointing down); for the mandibular arch, the negative vertical angulation must be increased (PID pointing up) as demonstrated in Figure 20.

This error can also occur when using the bisecting angle technique. Often the error is caused by the x-ray beam being perpendicular to the long axis of the teeth, rather than bisecting the angle between the teeth and the receptor (Figure 19A).

Foreshortening

Foreshortening or shortening of the recorded teeth and the surrounding structures can also result from improper vertical angulation (Figure 21). Foreshortening is the result of

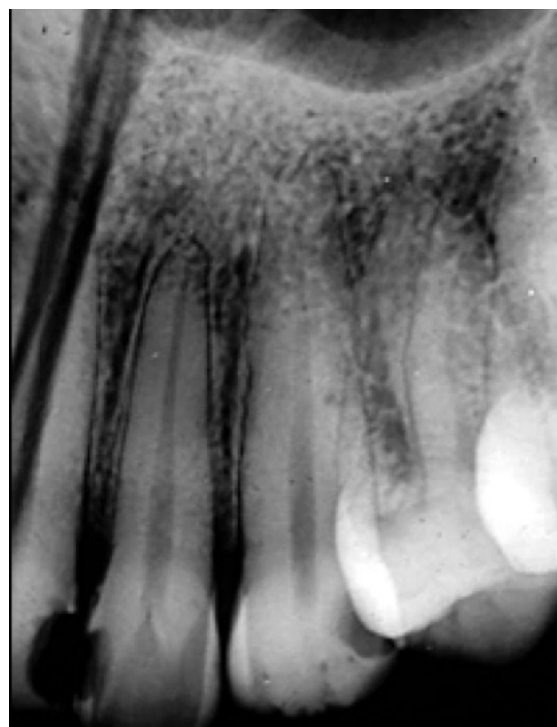

Figure 16: Film Receptor Creasing

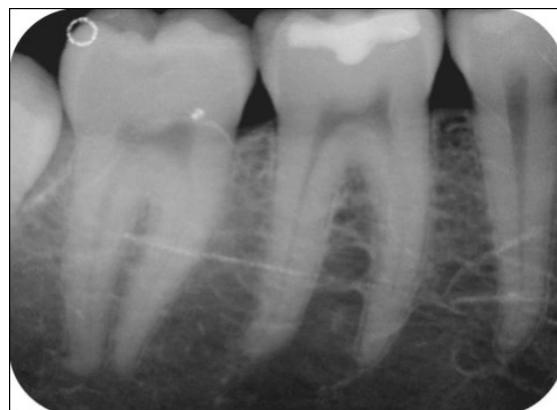

Figure 17: Plate Receptor Scratches

overangulation of the x-ray beam (too much vertical angle) as depicted in Figure 22B. When using the paralleling technique, foreshortening can occur when the angulation of the x-ray beam is greater than the long axes plane of the teeth (Figure 22B). To correct foreshortening when using the paralleling technique, the operator should decrease the positive vertical angulation for maxillary projections and, decrease the negative vertical for mandibular projections. This error can also occur if the receptor is not placed parallel to the long axis of the teeth (Figure 22A).

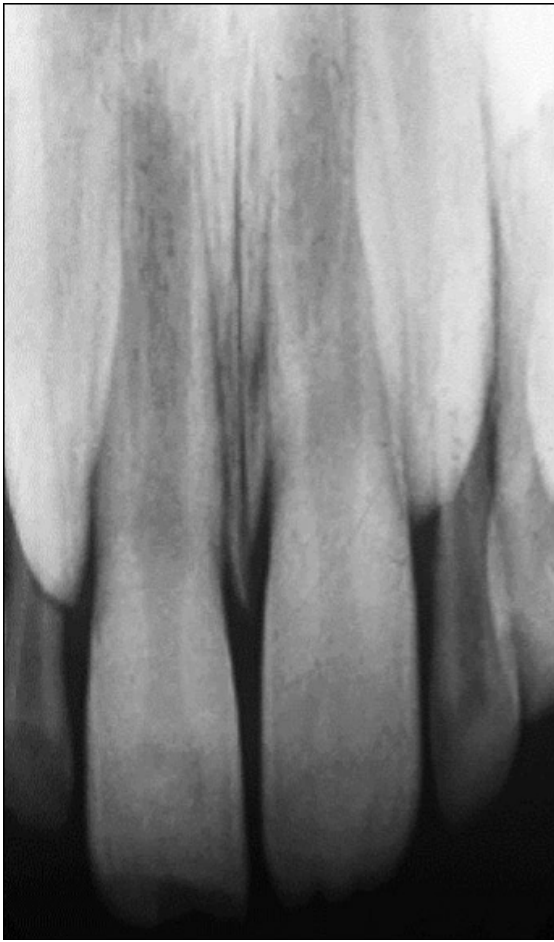

Figure 18: Elongation

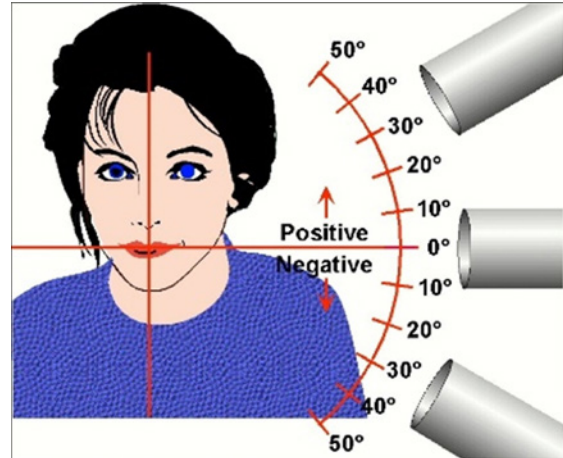


Figure 20: Vertical Angulation

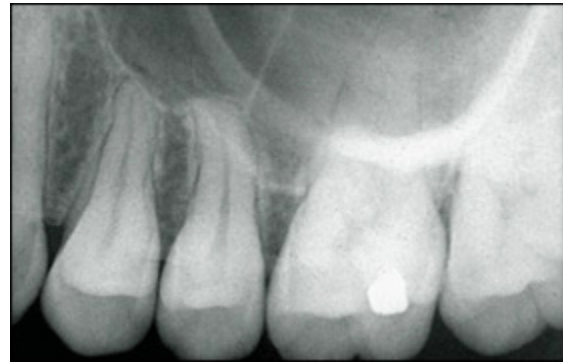

Figure 21: Image Foreshortening

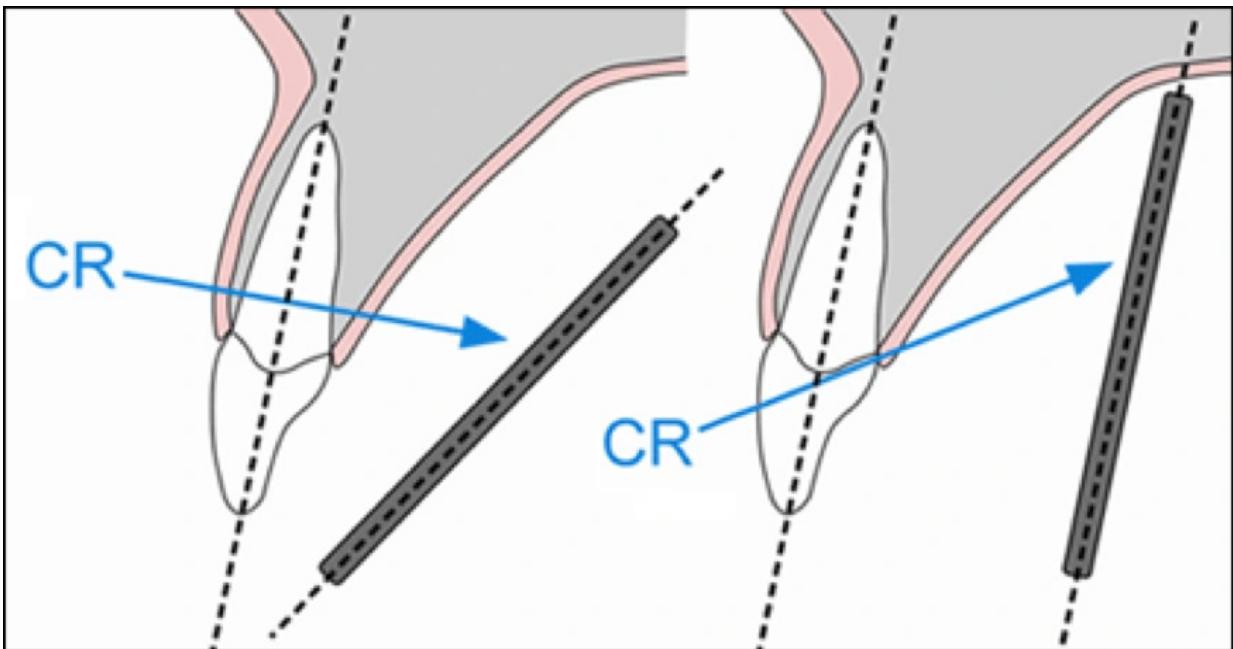


Figure 19A: Receptor Angular

Figure 19B: X-ray Beam Under-Angulated

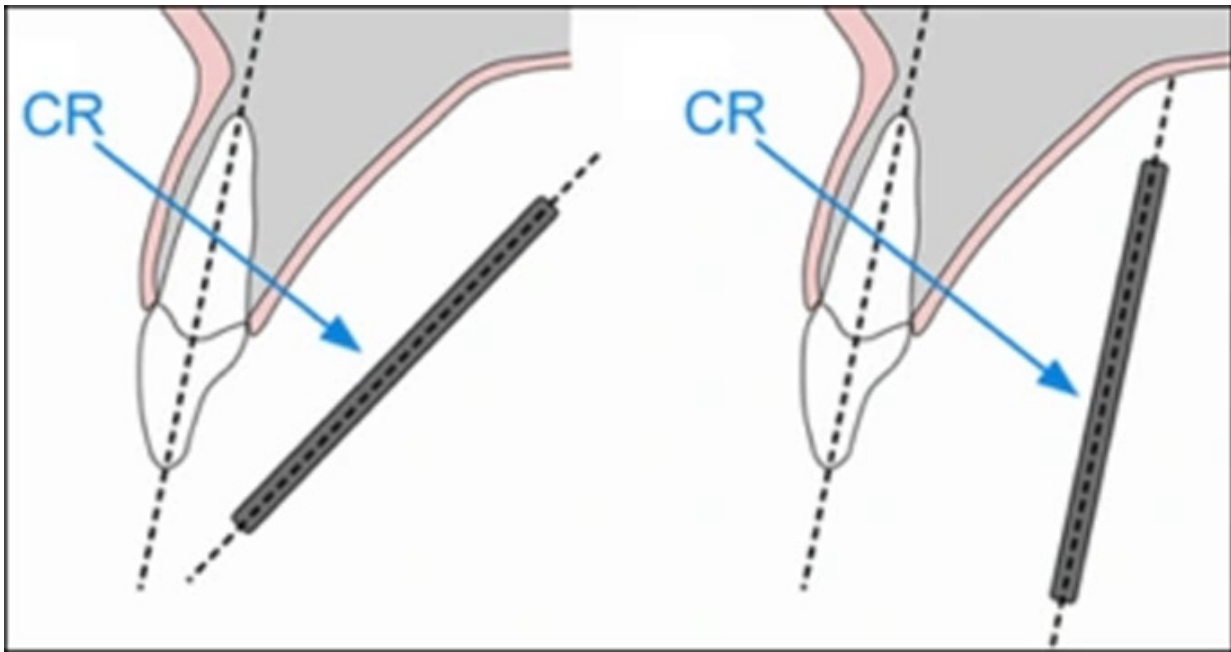


Figure 22A: Receptor Angular

Figure 22B: X-ray Beam Over-Angulated

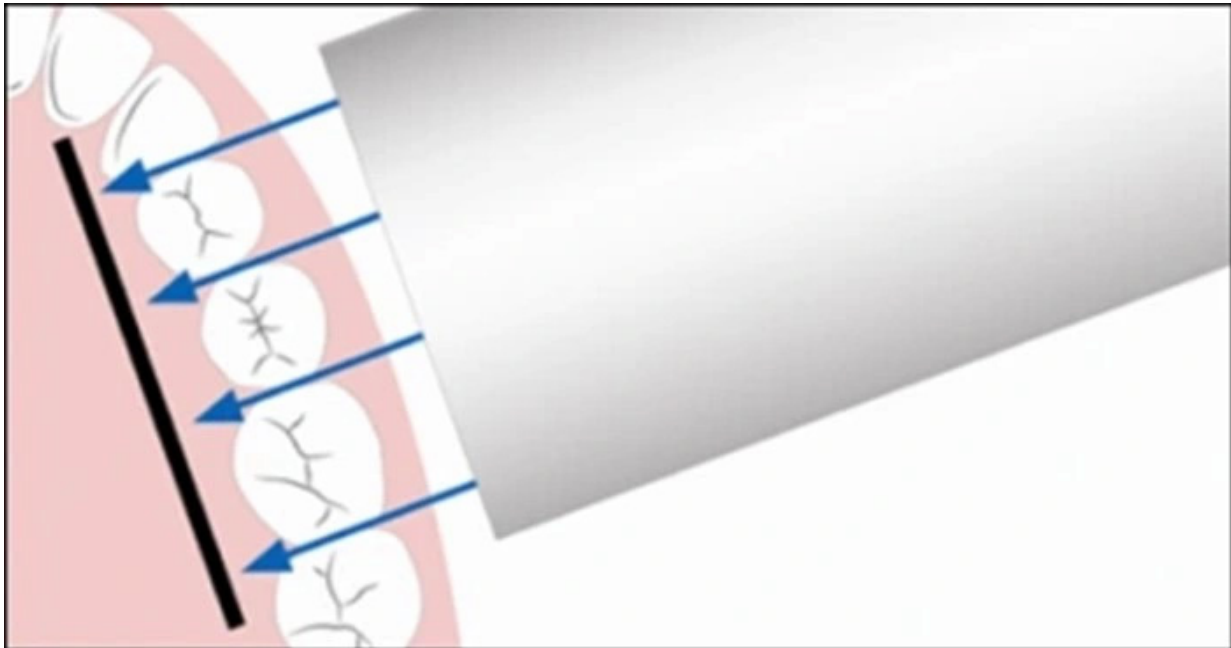


Figure 23: Correct Horizontal Angulation Entry

Horizontal Alignment Errors

Proper horizontal alignment of the x-ray beam will open interproximal contacts and facilitate a thorough radiographic caries evaluation and assessment of alveolar bone levels, both important components of a thorough clinical and radiographic examination. The x-ray beam should be aimed directly between the contact points of the targeted teeth in order

to open the interproximal surfaces (Figure 23). Horizontal alignment errors cause the image to shift anteriorly or posteriorly, resulting in the overlapping of the proximal contacts (Figures 24A and 24B).

To determine if the horizontal angulation is aligned incorrectly, evaluate the extent of the overlap. The Buccal Object Rule can

be used to determine the movement of the buccal and lingual cusps when trying to understand the error. The Buccal Object Rule states: Buccal objects move in the opposite direction compared to the direction of the x-ray tubehead, while lingual objects move in the same direction as the movement of the x-ray tubehead.¹⁹ Application of the Buccal Object Rule to determine the cause of interproximal overlapping requires evaluation of the position of the x-ray tubehead and the direction of the overlapping on the bitewing image. For example, if the x-ray head is placed too posterior in position, the buccal cusps will overlap in an anterior direction as demonstrated in the molar bitewing illustration. By way of comparison, if the x-ray head is placed too anterior in position, the buccal cusps will overlap in a posterior direction. To avoid this error, the central ray must pass through the proximal surfaces of the teeth where the contacts need to be open. To aid in the determination of the correct horizontal angle, the clinician can place the end of a cotton-tip applicator into the contact zone. This method will help visualize the direction the x-rays should be directed to open the teeth contacts.

When using receptor holding devices, horizontal errors can occur by improper horizontal alignment of the receptor. These errors can be avoided by placing the receptor in the same horizontal plane as the teeth so that the x-ray beam travels directly through the contact areas. This will position the receptor parallel to the buccal plane of the teeth as well as parallel to the instrument indicator ring.

Beam Centering Errors

The central ray should be aligned over the center of the receptor with the x-ray beam directed perpendicular to the receptor (Figure 25). When this alignment is not observed, a cone-cut occurs. Cone-cuts appear as a clear zone on traditional radiographs after processing, due to the lack of x-ray exposure of the emulsion. When using digital imaging, the cone-cut appears as an opaque or white zone. The shape of the cone-cut depends on the type of collimator used when exposing the receptor.

For example, if a round collimator is used, a curved cone-cut will appear (Figure 26).

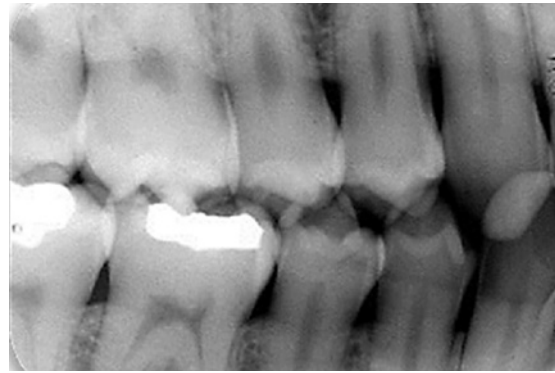


Figure 24A: Overlapped Premolar Bitewing

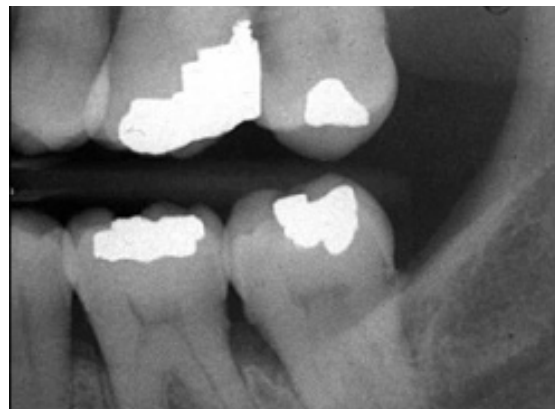

Figure 24B: Overlapped Molar Bitewing

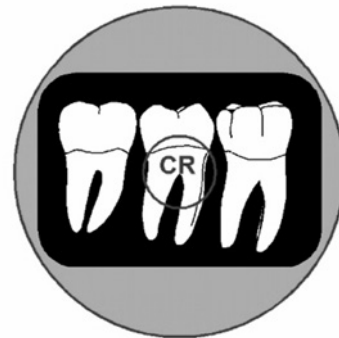

Figure 25: Central Ray Alignment

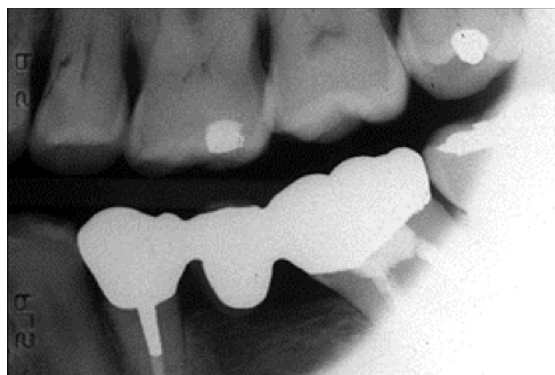

Figure 26. Round Cone Cut

Squarish or rectangular cone-cuts occur when using a rectangular collimator (Figure 27). To correct a cone-cut error, the beam should be re-centered toward the area of non-exposure. Improper assembly of receptor holding devices can also cause cone-cuts. When assembling these devices, make certain that the entire receptor can be seen when looking through the indicator ring.

The technical errors previously discussed are briefly summarized in Table 2.

Exposure and Miscellaneous Errors Time Setting

Incorrect exposure can be caused by many factors; the most common being improper exposure settings. Improper time selection is the most likely error because most intraoral x-ray units have fixed or unchangeable milliamperage (mA) and kilovoltage (kVp) settings. Time and milliamperage control density or the overall darkness of an image while kilovoltage controls contrast or the differences in darkness. The exposure time settings should be based on the receptor

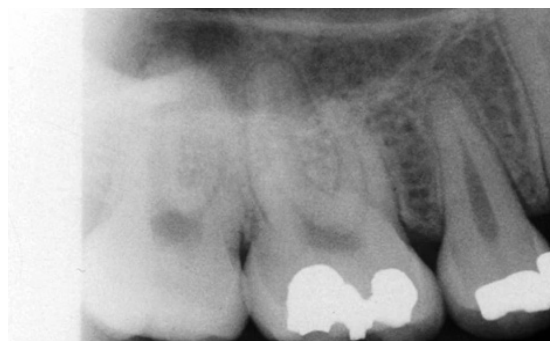

Figure 27: Rectangular Cone Cut

speed or type, the area being exposed, and patient size and stature. Every treatment room should have an exposure factor chart to guide the operator in selecting the appropriate kVp, mA and time setting for each periapical and bitewing. Refer to the manufacturer's manual for the recommended settings for specific intraoral views or projections. Generally speaking, the recommended time setting for each area is based on the size of an average adult patient. Therefore, time adjustments are necessary when the patient's size deviates from the average adult.

Error	Description	Correction
1. Receptor Placement	Inadequate coverage of the Structures radiographed or backwards receptor placement.	Follow established placement criteria for each periapical and bitewing. Expose correct receptor surface.
2. Receptor Handling	Phosphor plate or film with bends, creases, folds that produce artifacts or distort the captured image.	Handle receptors with care and refrain from bending, creasing or marring the emulsion. Use correct receptor size and receptor cushions to improve comfort.
3. Vertical Angulation	Shape distortion in the form of image foreshortening or image elongation.	Decrease the vertical angle to correct foreshortening. Increase the vertical to correct elongation. Ensure proper vertical placement of the receptor in relation to the teeth.
4. Horizontal Angulation	Overlapped or superimposed proximal contacts with image widening.	Direct the x-ray beam through the contact points of the teeth such that the open end of the PID is horizontally parallel to the labial or buccal surfaces of the teeth.
5. Cone cuts	Curved or squarish blank areas where the x-ray beam was not centered over the receptor.	Direct the x-ray beam to the center of the receptor. Ensure proper assembly of receptor-holder.

Table 2. Technical Error Summary.

Improper exposure time settings can also result from an inaccurate evaluation of patient size and stature. The operator should use longer times for larger-than-average patients and shorter times for smaller-than-average patients. Usually one step up for large patients and one step down for small patients will be adequate adjustment for each periapical and/or bitewing. Failing to adjust exposure time will result in images that are either too light or too dark. Typically, child exposure time settings are lower than adult exposure time settings because of the child's smaller size.

Under/Over Exposure

Underexposed receptors result in images that are too light or low in density (Figure 28). Light images can also be caused by an increase in the source-object distance, or not placing the tubehead close enough to the patient's face during exposure. Exposure times are based on the assumption that the tubehead is no more than 2 centimeters away from the face of the patient. Receptors can be underexposed if the exposure switch is not activated for the indicated or correct length of time. In other words, the clinician let go of the exposure button too soon. Overexposure results in a high-density or dark image (Figure 29). The causes include improper exposure factor settings or improper assessment of patient size and stature.

When using digital image receptors, the density can be adjusted by specific density enhancement features of the computer software program. However, images that are too light or low in density make it difficult to visualize the differences in structures and typically cannot be improved by software adjustments.⁴ Digital images that are dark or high in density can usually be salvaged by software adjustments in density unless the image appears totally black.⁴ This adjustment in density should be accomplished prior to printing or archiving the image. Extreme under or overexposure by necessity will result in retakes, thus exposing the patient to unnecessary radiation.

Double Exposure

Double exposure results when the receptor is exposed twice, and two images appear

superimposed onto each other (Figure 30). This error results in two errors; one receptor that was double-exposed and another that was not exposed at all. It is extremely important to avoid this error because it exposes the patient to radiation twice. To eliminate this error, maintain an organized workspace in which exposed receptors are placed in one area or turned over as a means to separate exposed from unexposed receptors.

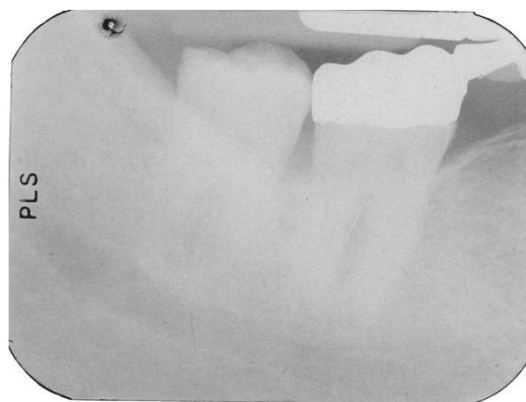


Figure 28: Underexposed Image

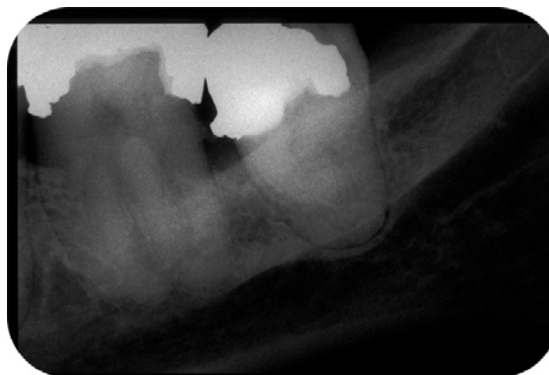


Figure 29: Overexposed Image

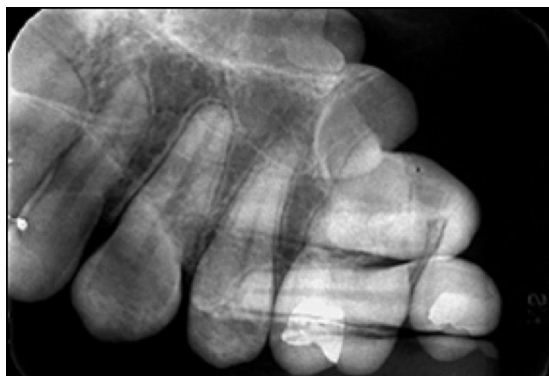


Figure 30: Double Exposure

Double exposure of rigid digital receptors is not possible, but phosphor plate receptors can be double exposed just like film.

Poor Image Definition/Sharpness

Poor image definition or resolution can be the result of patient movement, receptor movement, and/or vibration of the x-ray tubehead. Movement has been discussed previously. Receptor movement may occur when the device is not properly stabilized in the mouth or when the patient moves the receptor because it feels uncomfortable.

To help prevent x-ray tubehead vibration or drifting, place the arm against the wall with the tubehead pointing down after each use. When the arm is fully extended for long periods of time, the joints can become weakened and fatigued, resulting in drifting and vibration. Tubeheads and arms should be professionally serviced if drifting and movement persist.

Miscellaneous Objects

When a removable prosthesis is left in the mouth during exposure, an image of the appliance will appear superimposed over the teeth (Figure 31). Prior to radiographic procedures, ask the patient to take out all removable items from the mouth, such as retainers, partial dentures, complete dentures, and the like.

Eyeglass frames or stems may appear in maxillary periapical radiographs of patients with large eyeglasses and/or when extreme vertical angulation is utilized (Figure 32). Glasses should be removed prior to radiographic

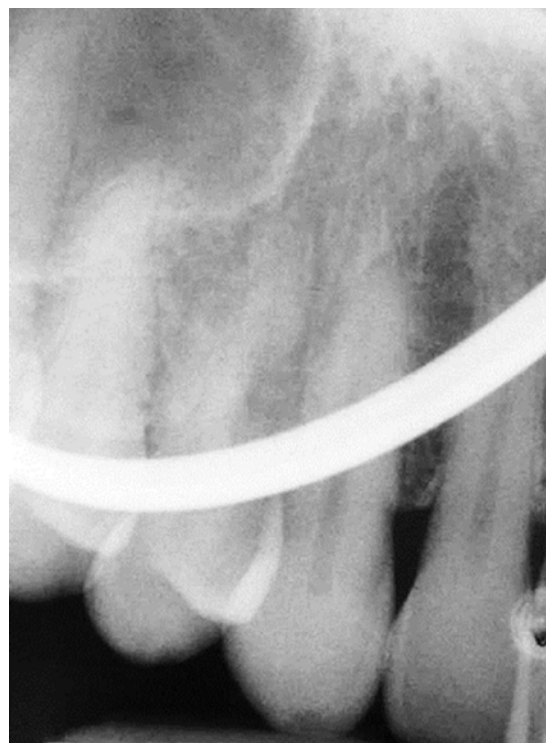

Figure 32: Eyeglasses frame

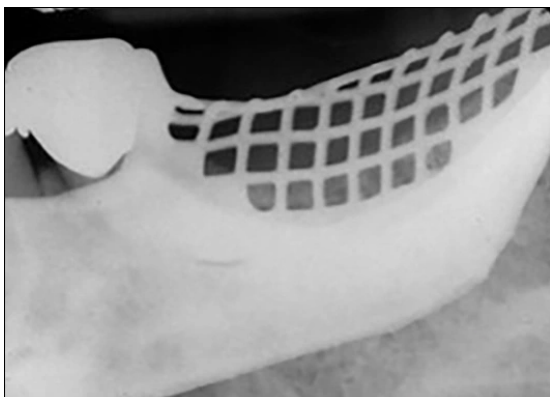


Figure 31: Mandibular Partial Denture

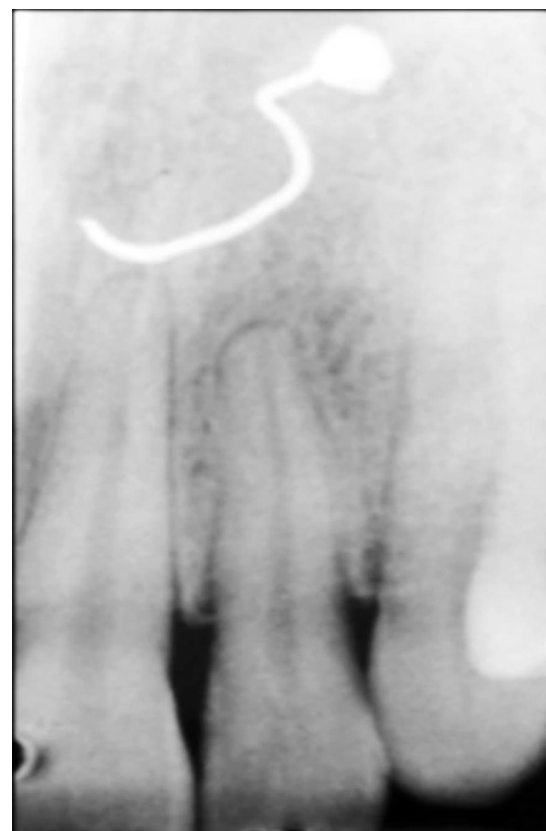

Figure 33: Nose Ring

procedures. Facial jewelry in the path of the x-ray beam should be removed as well to prevent unwanted artifacts and unnecessary retakes (Figure 33). Tongue rings can be left in place during intraoral radiographic imaging procedures.

Thyroid collars (Figure 34) or lead aprons can also be recorded on radiographic images. This is normally caused by the collar being placed too loosely or too high on the neck or when the vertical angulation is so steep that the collar is projected into the path of the x-ray beam.

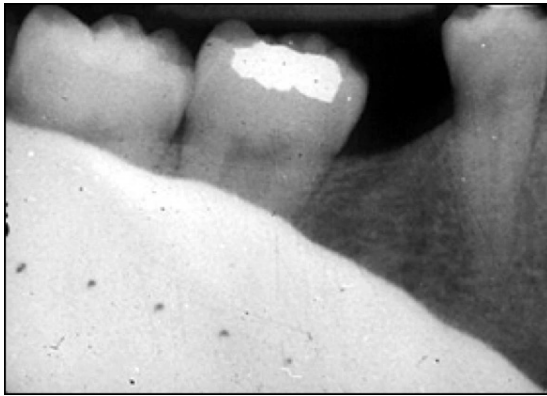

Figure 34: Thyroid Collar

Another error that occurs occasionally is when the receptor yields no image. This error can be caused by mechanical problems such as an electrical failure, a faulty generator, timer inaccuracy, or a faulty exposure switch. Failure to turn on the machine (non-exposure), failure to line-up the x-ray beam, and backwards placement of rigid digital receptor can also produce a blank or white image representative of this error.

Conclusion

Intraoral radiographic imaging is an invaluable tool for proper patient care providing critical information for the diagnosis and treatment of dental disease and other oral conditions. To ensure the production of high-quality diagnostic images, the clinician must attend to the principles of accurate image projection when acquiring intraoral radiographic images. In addition, the clinician must be able to manage the patient effectively during radiographic procedures and be well-versed in the identification and correction of errors when they occur. The clinician is also responsible for eliminating unnecessary retakes and minimizing radiation exposure to the patients under their care.

Course Test Preview

To receive Continuing Education credit for this course, you must complete the online test. Please go to: www.dentalcare.com/en-us/ce-courses/ce559/start-test

1. Which is the most common type of direct digital receptors used for intraoral imaging?

- A. CCD
- B. CMOS
- C. PSP
- D. SPP

2. Which is an apt description of digital imaging enhancement features?

- A. Allow the image to be viewed differently.
- B. Changes always improve image quality.
- C. Impact image storage and duplication.
- D. Result in significant patient dose reduction

3. Which of the following is NOT an advantage of digital radiography?

- A. Captured images can be archived, printed or sent electronically.
- B. Equal or greater dose reduction can be achieved compared to film.
- C. Images can be viewed almost immediately on the computer monitor.
- D. Technical radiographic imaging errors are completely eliminated.

4. Why is rectangular collimation recommended for use with digital receptors?

- A. Affects the number of views that can be taken.
- B. Aligns with the insets on the receptor instrument ring.
- C. Expands the area of exposure decreasing cone cuts.
- D. Reduces scatter radiation and improves the image.

5. Why is the use of a long position-indicating device recommended for intraoral imaging?

- A. Allows x-rays to emerge in a straighter line.
- B. Decreases the number of cone-cutting errors.
- C. Reduces the over-generation of heat.
- D. Restricts blooming of the anode focal spot.

6. Which Principles of Accurate Image Projection are met by the paralleling technique?

- A. Principles 1, 2, 3
- B. Principles 3, 4, 5
- C. Principles 1, 2, 4, 5
- D. Principles 2, 3, 4, 5

7. Which of the following is NOT an accurate description of the paralleling technique?

- A. Allows placement of the receptor in contact with the structures.
- B. Directs the x-ray beam at a right angle to the structures and the receptor.
- C. Produces more accurate images than the bisecting angle technique.
- D. Radiographs are easier to standardize with paralleling technique.

8. Periapicals taken using the bisecting angle technique are prone to _____.

- A. bending errors.
- B. image sharpness.
- C. proximal overlap.
- D. shape distortion.

9. Which patient management strategy is useful in the reduction of the gag reflex?

- A. Have the patient hold their breath during exposure.
- B. Place a sprinkle of salt on the patient's tongue.
- C. Start in the posterior region for the first projection.
- D. Tell the patient that they might gag on the receptor.

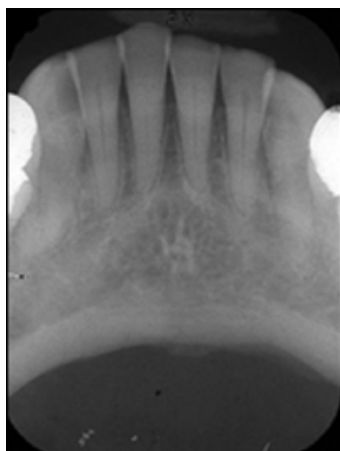
10. Which is the most common error in intraoral radiographic imaging?

- A. Facial jewelry artifact
- B. Horizontal overlapping
- C. Image foreshortening
- D. Receptor placement

11. Which factor controls the length of the structures recorded on a periapical projection?

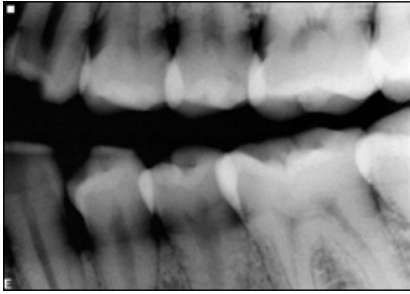
- A. Central ray alignment
- B. Horizontal angulation
- C. Vertical angulation
- D. X-ray beam collimation

12. Which approach would correct the error on this periapical image?



- A. Center the x-ray beam.
- B. Decrease the angulation.
- C. Instruct the patient to sit still.
- D. Realign the horizontal angle.

13. Which type of technical error is present on this bitewing image?



- A. Elongation
- B. Proximal overlapping
- C. Receptor movement
- D. Underexposure

14. A cone-cut is the result of improper _____.

- A. beam centering.
- B. horizontal angulation.
- C. patient instruction.
- D. vertical angulation.

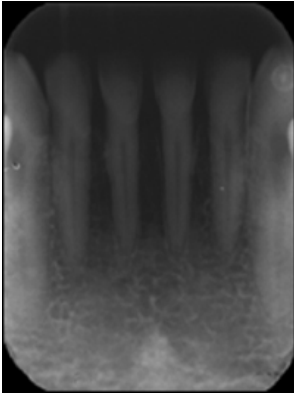
15. Which consideration is the most critical for proper determination of the x-ray exposure?

- A. Instrument selection
- B. Operator preference
- C. Patient gender
- D. Receptor type

16. Which factor would most likely need to be increased when taking radiographs on a patient who is larger than average?

- A. Exposure time
- B. Kilovoltage
- C. Milliamperage
- D. PID distance

17. The error demonstrated on this radiograph is the result of _____

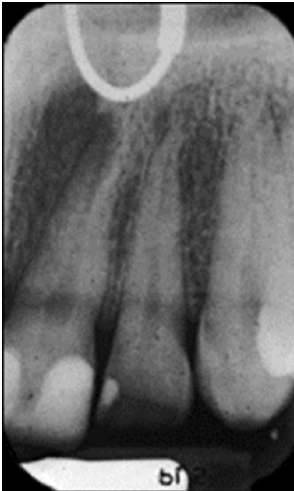

- A. improper vertical angulation
- B. incorrect receptor placement
- C. overexposure to x-radiation
- D. x-ray tubehead movement

18. A double-exposed film or plate receptor results in _____.

- A. image unsharpness.
- B. low-density image.
- C. timer recalibration.
- D. two retakes.

19. The error present on this radiographic image is caused by _____.



- A. improper patient preparation.
- B. incorrect head position.
- C. holder arrangement.
- D. beam malalignment.

20. What would cause a rigid digital receptor image to appear totally white?

- A. Machine vibration
- B. Nonexposure
- C. Thyroid collar
- D. Overexposure

References

1. American Dental Association Council on Scientific Affairs, US Department of Health and Human Services, Public Health Service, Food and Drug Administration. Dental radiographic examinations: Recommendations for patient selection and limiting radiation exposure. Revised 2012. Accessed October 25, 2021.
2. Bedard A, Davis TD, Angelopoulos C. Storage phosphor plates: how durable are they as a digital dental radiographic system? *J Contemp Dent Pract*. 2004 May 15;5(2):57-69.
3. White SC, Pharoah MJ. *Oral Radiology: Principles and Interpretation*, 7th Ed. St. Louis, MO. Elsevier. 2014.
4. Parks ET, Williamson GF. Digital radiography: an overview. *J Contemp Dent Pract*. 2002 Nov 15;3(4):23-39.
5. Gormez O, Yilmaz HH. Image post-processing in dental practice. *Eur J Dent*. 2009 Oct;3(4):343-7.
6. Brett D, Carmichael F. The impact of digital image processing artefacts mimicking pathological features associated with restorations. *Br Dent J*. 2011 Aug 26;211(4):167-70. doi: 10.1038/sj.bdj.2011.676.
7. Gray BM, Mol A, Zandona A, Tyndall D. The effect of image enhancements and dual observers on proximal caries detection. *Oral Surg Oral Med Oral Pathol Oral Radiol*. 2017 Apr;123(4):e133-e139. doi: 10.1016/j.oooo.2017.01.004. Epub 2017 Jan 24.
8. Costa ED, Brasil DM, Gaêta-Araujo H, Oliveira-Santos C, Freitas DQ. Do image enhancement filters in complementary metal oxide semiconductor and photostimulable phosphor imaging systems improve the detection of fractured endodontic instruments in periapical radiography? *Oral Surg Oral Med Oral Pathol Oral Radiol*. 2021 Feb;131(2):247-255. doi: 10.1016/j.oooo.2020.07.013. Epub 2020 Jul 24.
9. Zhang W, Abramovitch K, Thames W, Leon IL, Colosi DC, Goren AD. Comparison of the efficacy and technical accuracy of different rectangular collimators for intraoral radiography. *Oral Surg Oral Med Oral Pathol Oral Radiol Endod*. 2009 Jul;108(1):e22-8. doi: 10.1016/j.tripleo.2009.03.011. Epub 2009 May 22.
10. Versteeg CH, Sanderink GC, van Ginkel FC, van der Stelt PF. An evaluation of periapical radiography with a charge-coupled device. *Dentomaxillofac Radiol*. 1998 Mar;27(2):97-101. doi: 10.1038/sj/dmfr/4600330.
11. Bahrami G, Hagstrøm C, Wenzel A. Bitewing examination with four digital receptors. *Dentomaxillofac Radiol*. 2003 Sep;32(5):317-21. doi: 10.1259/dmfr/14212871.
12. Sommers TM, Mauriello SM, Ludlow JB, Platin E, Tyndall DA. Pre-clinical performance comparing intraoral film and CCD-based systems. *J Dent Hyg*. 2002 Winter;76(1):26-33.
13. Matzen LH, Christensen J, Wenzel A. Patient discomfort and retakes in periapical examination of mandibular third molars using digital receptors and film. *Oral Surg, Oral Med, Oral Pathol, Oral Radiol, Endod*. 2009;107:566-572.
14. Wenzel A, Møystad A. Work flow with digital intraoral radiography: a systematic review. *Acta Odontol Scand*. 2010 Mar;68(2):106-14. doi: 10.3109/00016350903514426.
15. Iannucci JM, Howerton LJ. *Dental Radiography Principles and Techniques*, 4th Ed. St. Louis, MO. Elsevier. 2012.
16. Scarborough D, Bailey-Van Kuren M, Hughes M. Altering the gag reflex via a palm pressure point. *J Am Dent Assoc*. 2008 Oct;139(10):1365-72. doi: 10.14219/jada.archive.2008.0048.
17. Shriprasada S, Shilpashree H.S. Gag reflex: No more a gag to a dentist the behavioral techniques, pharmacological techniques, acupressure and acupuncture in controlling the gag reflex - A review. *Bangladesh Journal of Medical Science*, v11 n1 (2012 02 23): 12-17.
18. Frost RA. Temporal Tapping. *Touch for Health International Journal* 1990;7:55-58. Accessed October 25, 2021.
19. Miles DA, Van Dis ML, Williamson GF, et al. *Radiographic Imaging for the Dental Team*, 4th Ed. St. Louis, MO. Saunders. 2009:139-52.

Additional Resources

- No Additional Resources Available

About the Authors

Gail F. Williamson, Professor Emerita



Gail F. Williamson is Professor Emerita of Dental Diagnostic Sciences, Department of Oral Pathology, Medicine and Radiology at Indiana University School of Dentistry in Indianapolis, Indiana. She received an AS in Dental Hygiene, BS in Allied Health, and MS in Education, all from Indiana University. A consummate educator, Prof. Williamson has received numerous awards for teaching excellence during her academic career including the 2013 Outstanding Teacher of the Year Award from the Indiana University School of Dentistry and the 2018 Gordon J. Christensen Lecturer Recognition Award from the Chicago

Dental Society. She is a co-author of several radiology textbooks and author/co-author of multiple book chapters, journal articles and continuing education monographs. She has held numerous positions in several professional organizations including the American Academy of Oral and Maxillofacial Radiology and the American Dental Education Association.

Email: gwilliam@iu.edu