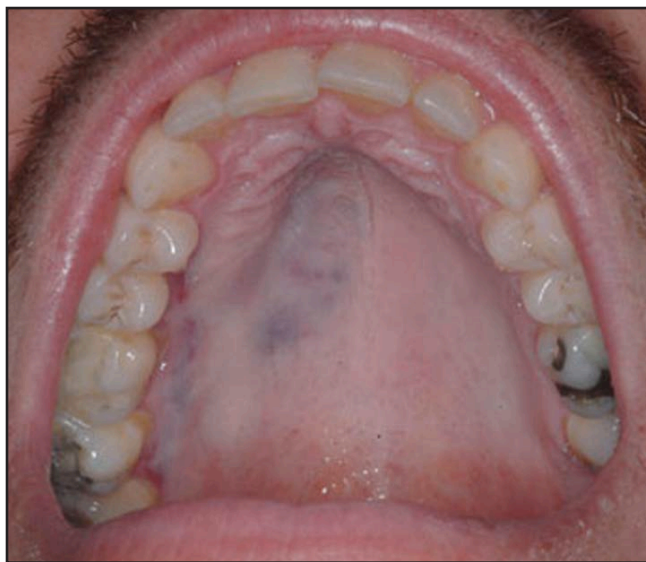

## A Blue-Grey Lesion of the Palate

Jessica Shireman, DMD; Alice E. Curran, DMD, MS;  
John M. Crestetto DDS, MD; Ricardo Padilla, DDS



The following Case Challenge is provided in conjunction with the American Academy of Oral and Maxillofacial Pathology.

### **Case Summary**

A 33-year old man presented with an asymptomatic blue-grey lesion of the hard palate.

After you have finished reviewing the available diagnostic information, make the diagnosis.

## Diagnostic Information

### Medical History

The patient has a positive history of tobacco use. He denies risk factors for HIV. The patient has reported a recent history of epistaxis on the right side. He does not note any swelling or pain in the mouth.

### Dental History

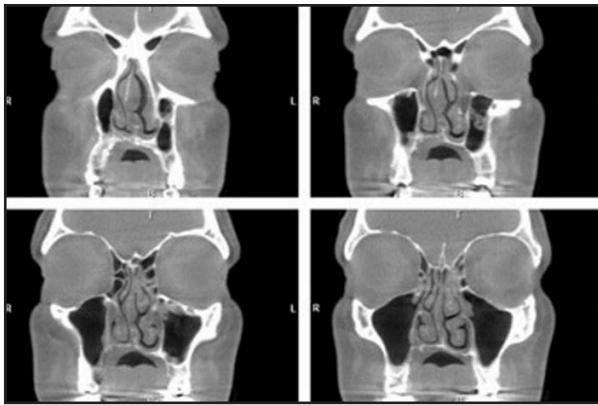
Additional clinical findings: The lesion feels slightly elevated and spongy upon palpation. No bruit or pulsation was detected.

### Laboratory Data

None reported

### Radiographic Findings

The lesion is present in the maxillary bone and soft tissues of the palate. Please see CT scan image (Figure 1).



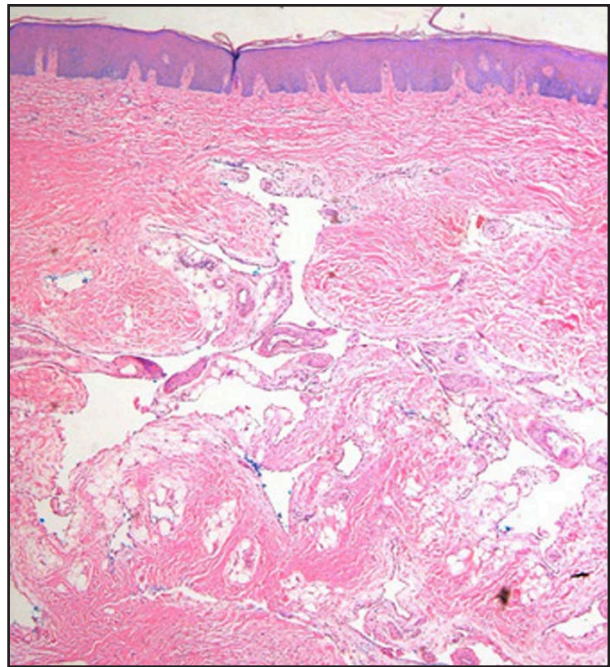
**Figure 1.** Representative serial coronal CT sections demonstrate erosion of maxillary bone with a thickening of the overlying palatal soft tissues.

### Surgical Findings

Incisional biopsy of the area was uneventful.

### Histopathology

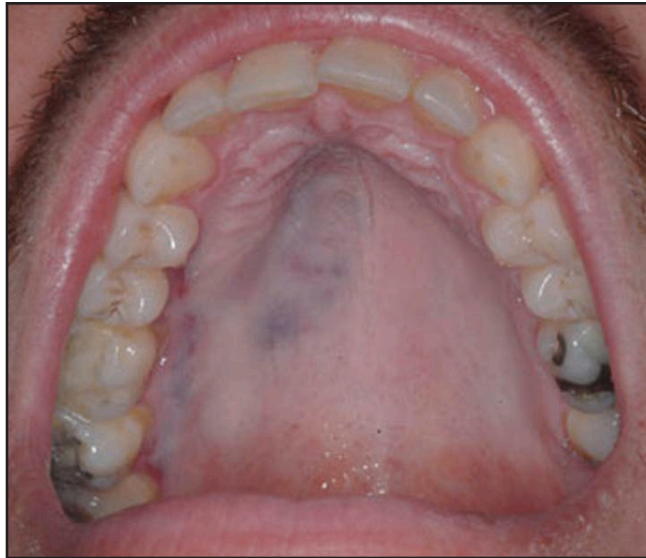An incisional biopsy of the oral mucosa was procured. The specimen is surfaced by stratified squamous epithelium with a regular pattern of maturation. The connective tissue is remarkable for several large, dilated vascular channels lined by thin, widely-spaced, flattened endothelial cells. Some blood and clear-filled fluid is identified within the lumina, and small capillaries are present in the area. Mature adipose tissue is seen throughout the deep portion of the specimen.



**Figure 2.** Incisional biopsy of the oral mucosa the overlying palatal soft tissues.

### Can you make the diagnosis?

A 33-year old man presented with an asymptomatic blue-grey lesion of the hard palate.



### Select the Correct Diagnosis

- A. Drug-induced Pigmentation
- B. Melanoma
- C. Hemangioma
- D. Kaposi's sarcoma

## Drug-induced Pigmentation

**Choice A. Sorry, this is not the correct diagnosis.**

This lesion closely mimics the clinical appearance of drug-induced mucosal pigmentation. However, this diagnosis can be eliminated because the patient takes no medications and has no history of local administration of any medicament. In addition, mucosal pigmentations associated with medications are flat and this lesion exhibits a slightly elevated surface that is depressible upon palpation.

Please re-evaluate the information about this case.

## Melanoma

**Choice B. Sorry, this is not the correct diagnosis.**

The clinical presentation of melanoma may resemble this lesion; however, a melanoma this size would likely have texture and or surface alterations. The diagnosis of melanoma can be excluded after histological evaluation of the biopsy specimen.

Please re-evaluate the information about this case.

## Hemangioma

**Choice C. Congratulations! You are correct.**

### Discussion

The incisional biopsy of this lesion shows a benign proliferation of vascular channels lined by endothelial cells within the connective tissue. In foci of this lesion there are some vessels filled with blood and others with clear-fluid filled lumens. Hemangiomas make up a significant portion of tumors in infancy and childhood. The head and neck is a common location for these tumors, but an extensive lesion such as this one on the hard palate is rare. Histologically this lesion exhibits prominent areas typical hemangioma, but also some areas suggestive of lymphangioma due to their lymph fluid-like content.

Cavernous hemangiomas are a component of many systemic diseases such as Sturge-Weber syndrome and von Hippel-Lindau disease.<sup>1</sup>

The current case is unusual because the patient presented at an older age than the average, and because hemangiomas of the palate are rarely reported in the literature.<sup>2</sup> The differential diagnosis of this lesion would also include other benign and malignant lesions due to its red/pigmented presentation and bone erosion. This case demonstrates how sometimes the clinical presentation of a lesion can mimic many disease processes and histopathological examination is necessary to establish a definitive diagnosis. Due to the combined clinical, radiographic and histopathological findings in the this case a final diagnosis of lympho-hemangioma may be most appropriate.<sup>3,4</sup>

## Kaposi's sarcoma

**Choice D. Sorry, this is not the correct diagnosis.**

Kaposi's sarcoma is common in this anatomic location and may share clinical features with this lesion. This patient has no history of any risk factors for HIV infection or of immunosuppression. However, the only way of excluding this diagnosis is by histopathologic examination of the tissue.

Please re-evaluate the information about this case.


## References

1. Robbins and Cotran. Pathologic Basis of Disease. 8th edition. 2004.
2. Neville BW, Damron DD, Allen CM, et al. Oral and Maxillofacial Pathology. Philadelphia, PA Saunders, 2009.
3. Pratap A, Tiwari A, Pandey RS, Agrawal B, Paudel G, Adhikary S, Kumar A. Giant cavernous hemangiolympangioma of the bladder without cutaneous hemangiomas causing massive hematuria in a child. Journal of Pediatric Urology. 3: 326-329. 2007.
4. Zacharia, TT, Ittoop A, Perumilichira JJ, Chavhan G. Sonographic Appearance of a Congenital Parotid Gland Hemangiolympangioma Simulating Malignancy in an Infant. Journal of Clinical Ultrasound. 31: 493-496. 2003.

## About the Authors

*Note: Bio information was provided at the time the case challenge was developed.*

### Jessica Shireman, DMD



Dr. Shireman is a resident in University of North Carolina-Chapel Hill's Oral and Maxillofacial Pathology Graduate Program.

E-mail: shireman@dentistry.unc.edu

### Alice E. Curran, DMD, MS



Dr. Curran is an Associate Professor at the University of North Carolina School of Dentistry-Chapel Hill. She is a Fellow of the American Academy of Oral and Maxillofacial Pathology and a Diplomate of the American Board of Oral and Maxillofacial Pathology.

### John M. Crestetto DDS, MD



Dr. Crestetto is an Oral and Maxillofacial Surgeon in private practice and a Diplomate of the American Board of Oral and Maxillofacial Surgery. He practices in Rocky Mount, NC.

### Ricardo Padilla, DDS



Dr. Padilla is a Clinical Assistant Professor and at the University of North Carolina School of Dentistry-Chapel Hill. He is a Fellow of the AAOMP and a Diplomate of the ABOMP.

E-mail: padilla@dentistry.unc.edu