

Evaluating and Establishing Ideal Smile Esthetics : Beauty is More than Skin Deep



Course Author(s): Maria L. Geisinger, DDS, MS

CE Credits: 2 hours

Intended Audience: Dentists, Dental Hygienists, Dental Assistants, Dental Students, Dental Hygiene Students, Dental Assistant Students

Date Course Online: 04/14/2022

Last Revision Date: NA

Course Expiration Date: 04/13/2022

Cost: Free

Method: Self-instructional

AGD Subject Code(s): 490, 370, 780

Online Course: www.dentalcare.com/en-us/professional-education/ce-courses/ce649

Disclaimer: Participants must always be aware of the hazards of using limited knowledge in integrating new techniques or procedures into their practice. Only sound evidence-based dentistry should be used in patient therapy.

Conflict of Interest Disclosure Statement

- Dr. Geisinger reports no conflicts of interest associated with this course. She has no relevant financial relationships to disclose.

Introduction – Forensic Dentistry

An ideal smile is composed of individual components that interact in a harmonic manner. The three primary aspects of an ideal smile are: the teeth, lips, and gingiva. While beauty may be in the eye of the beholder, there are established guidelines to which we should adhere when assessing and creating overall ideal smile esthetics. This course seeks to describe the current evidence assessing ideal smile components as well as the impact of age, gender, and race/ethnicity on how smiles are judged as attractive or unattractive.

Course Contents

- Overview
- Learning Objectives
- Introduction
- Components of An Ideal Smile
- Teeth
 - Tooth Shade
 - Tooth Shape
 - Anterior Tooth Inclination
 - Occlusal Plane Orientation
 - Dental Midline
 - Buccal Corridor Fill
- Lips
 - Lip Length
 - Lip Mobility
 - Lip Curvature
 - Lip Volume
- Gingival Scaffold
 - Gingival Color/Texture
 - Papillary Fill
 - Gingival Contour
 - Gingival Display
- Relationships Between Smile Components
 - Smile Symmetry
 - Smile Arc
- Assessment of Smile Esthetics
- Cultural Influences on the Perceptions of Smile Esthetics
- Addressing Compromised Smile Esthetics
 - Excessive Gingival Display - “Gummy Smile”
 - Smile Asymmetry
- Conclusion
- Course Test
- References
- About the Author

Overview

“A smile is the shortest distance between two people.” -Victor Borge

A smile has widely been labeled as a universal greeting that transcends languages and customs. Smiling individuals are viewed as more pleasant and trustworthy, where individuals who experience facial neuromuscular disorders that impair their ability to smile demonstrate more severe self-reported depressive symptoms. The act of smiling releases endorphins that have been shown to improve the mood of both the person who smiles and individuals who see them smiling! Given these widespread social, physical, psychological, financial, and other impacts, a smile is critical to an individu-

al’s wellbeing and is a fundamental component to perceived beauty. As dental healthcare professionals, the impact that we can have on our patients through the creation, maintenance, and enhancement of their smiles is powerful and our understanding of the current and evolving “gold standards” of beauty is critical to our ability to impact our patients and their esthetics positively.

An ideal smile is composed of individual components that interact in a harmonic manner. The three primary aspects of an ideal smile are: the teeth, lips, and gingiva. While beauty may be in the eye of the beholder, there are established guidelines to which we should adhere when assessing and creating overall ideal smile esthetics. Factors that contribute to smile assessment include:

- Tooth width/height ratio
- Tooth shape
- Tooth position
- Quality and color of restoration(s)
- Tooth alignment
- Lip fullness and position
- Buccal corridor display
- Tooth display
- Gingival display

While all these factors are important individually, their overall interaction and harmony is critically important when assessing ideal esthetics. This course seeks to describe the current evidence assessing ideal smile components and the impact of age, gender, and race/ethnicity on how smiles are judged as attractive or unattractive.

Learning Objectives

Upon completion of this course, the dental professional should be able to:

- List the oral components and characteristics that contribute to optimal smile esthetics.
- Discuss methods of assessment of smile esthetics, including utilization of static and dynamic methods to assess tooth and gingival display and lip position and mobility.
- Understand how individual, patient-based characteristics may impact how smile esthetics are perceived.
- Discuss methods available to achieve an ideal smile for patients with compromised esthetics.

Introduction

Many scientists agree that a smile can positively impact patients and those who interact with them. A smile is generally considered to be a key component of an individual's attractiveness and, further, can positively impact social and psychological well-being. Evolving beauty standards as well as the impact of media and digital editing have thrust optimizing smile esthetics to the top of patient requests among dental procedures for many more patients. Combined with a decline in the incidence of dental caries in adults have resulted in overall increases in patient's dissatisfaction with smile esthetics. The American Association of Orthodontists evaluated patient satisfaction with their smile esthetics and found that more than one-third of US adults are unhappy with the way that their smile looks. They also found that 36% of those who were unhappy with their smile believe that improved smile esthetics would positively impact their social life. These impacts were more pronounced in younger individuals. 48% of younger Americans (18-24 years old) report that they have untagged a picture of themselves on social media due to a negative perception of their smile!

The three main components of the smile, the teeth, lips, and gingival scaffold, and their perceived harmony are the critical building blocks of a pleasing smile. Factors associated with these three primary components that contribute to smile assessment include: 1) tooth width/height ratio, 2) tooth shape, 3) tooth position, 4) quality and color of restoration(s), 5) tooth alignment, 6) lip fullness and position, 7) buccal corridor display, 8) tooth display, and 9) gingival display. The harmony and balance between these factors contribute to whether a smile is considered attractive or unattractive. This course will evaluate the current evidence regarding the perception of an esthetic smile and assess how the characteristics associated with smile esthetics and their interaction create ideal esthetics.

Components of An Ideal Smile

Smile esthetics involve oral tissues--teeth, lips, and gingivae—in harmony with one another. Individuals who report dissatisfaction with their smiles noted issues with all these individual tissues. Overall, the most common complaint

amongst those who did not like their smile was tooth color (27.9 %). Other components reported by individuals were tooth size (19.2 %), tooth position (16.2 %), tooth shape (15.0 %), and lip shape (11.2 %).

Because each patient is unique and myriad complaints have been associated with compromised esthetics, approaching smile esthetics from an interdisciplinary standpoint is often required to achieve optimal results. Multidisciplinary assessment and care allow for a combinatorial approach to rehabilitation of poor esthetics, which often have multiple underlying causes. Employing a diverse armamentarium, including restorative dental care, orthodontic tooth movement, periodontal plastic surgical procedures, and/or facial esthetic procedures can often produce ideal results and address the multifactorial causes of less than ideal smile esthetics. As dental healthcare professionals, understanding the individual components that make a smile esthetic and the potential treatments available to improve smile esthetics.

As show in Figure 1, a comprehensive patient assessment is necessary to identify all underlying causes for esthetic concerns. Clinical, photographic, videography, and radiographic analysis tools can be used to determine the etiologies that can be addressed during multidisciplinary care.

Teeth

The most common complaints associated with decreased smile esthetics were associated with the teeth themselves.⁷ It is critical to understand how individual characteristics of teeth contribute to esthetics and their relative importance in the creation of an ideal smile.

Tooth Shade

Less than ideal tooth color is the most common complaint amongst individuals unhappy with their smile.⁷ The Munsell color system is used in dentistry to describe tooth color.⁸ The system characterizes the hue, value, and chroma to capture the dimensions of tooth color (Figure 3).⁸ Hue distinguishes between different families of color (i.e., blue versus yellow). Value characterizes the lightness of a color within that particular hue. Chroma describes the degree of

Figure 1.

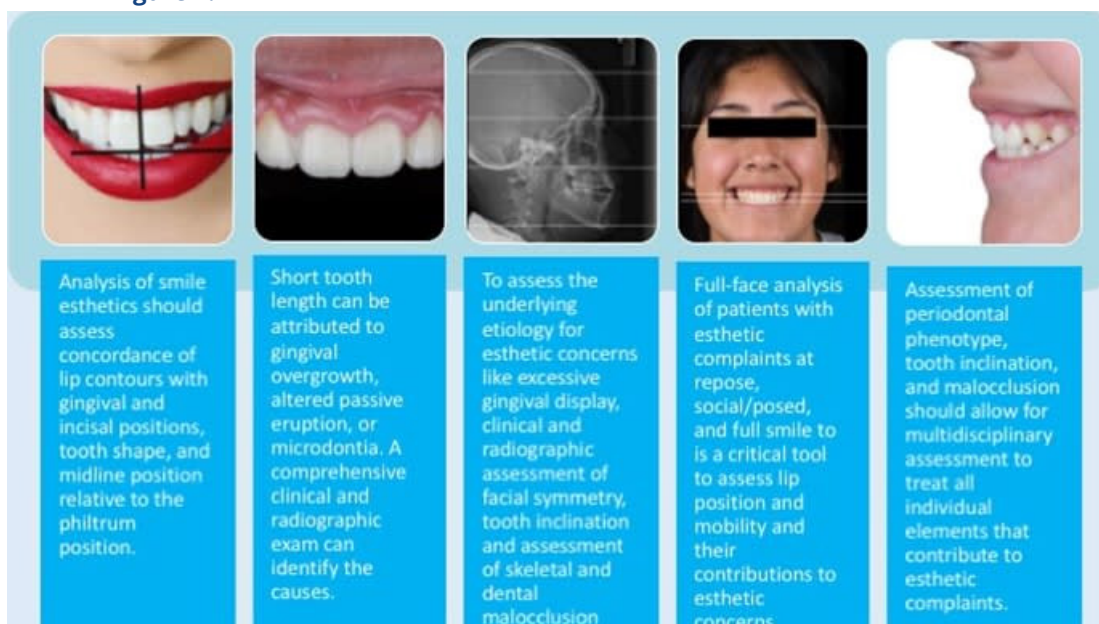
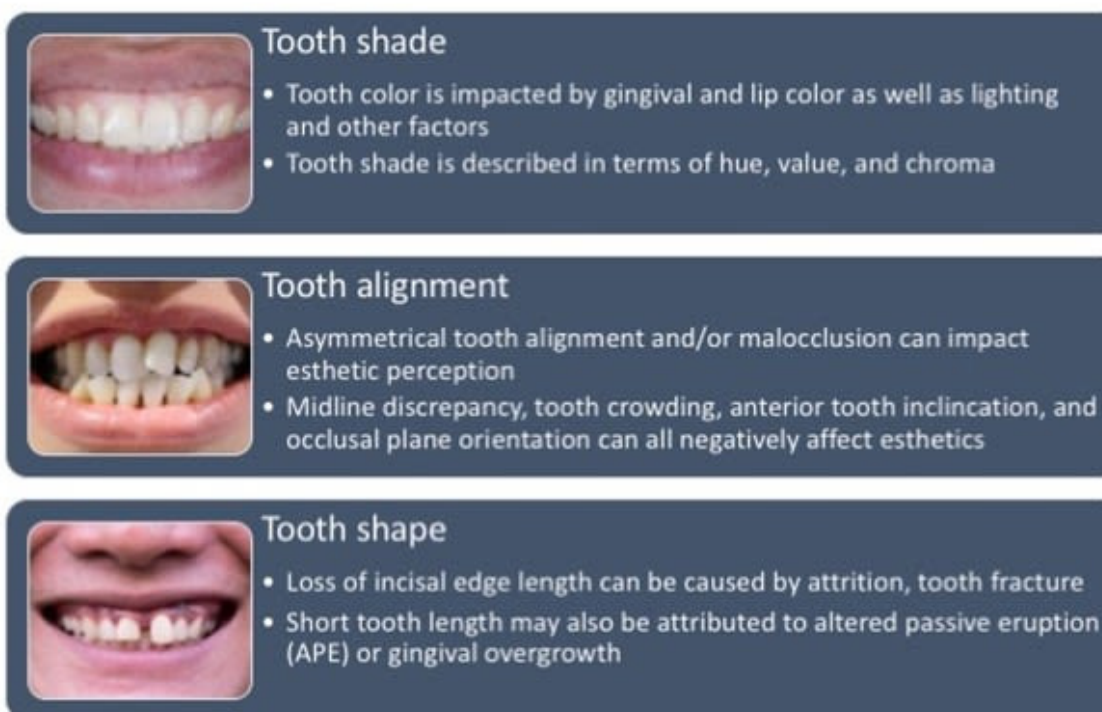



Figure 2: Examples of tooth-related factors and their impacts on smile esthetics



color saturation, or brilliance. In dentistry, the hue has been denoted as A through D. While to the untrained eye teeth may all appear to be shades of white, the underlying colors are captured in the description of hues. Shade A describes an underlying reddish brown hue, Shade B is a reddish yellow hue, Shade C is a

gray color, and Shade D is a reddish-gray color. Untreated teeth, on average, demonstrate an A3 hue and B1 is considered to be the lightest naturally occurring shade.⁸ Darker tooth shade is associated with increasing age and male gender.^{9,10} Most patients judge a lighter tooth shade as more esthetic, but perception

Figure 3: A three-dimensional representation of the Munsell color system describing hue, value, and chroma within color families.^{8,87}



of shade may be influenced by skin and lip color, patient age and gender.^{11,12} It is also well-established that factors that influence light reflection, including material translucency, fluorescence, and opalescence can alter the perception of shade.^{11,12}

Tooth Shape

While both short and long teeth compromise esthetics, the width:length ratio of teeth also influences the perception of smile esthetics. The average vertical dimension of maxillary central incisors is 10.6mm and 9.8mm in males and females, respectively.^{13,14} Short clinical crowns can be a result of tooth fracture, attrition, altered passive eruption, or gingival overgrowth. Longer clinical crowns may be caused by gingival recession, improperly designed dental restorations, or other anatomical concerns. The golden proportion (1.618) is conserved throughout nature and can also be applied to teeth. In dentistry, the mean width:length ratio for teeth is 78% and a range of 75-80% judged as esthetically pleasing.¹⁵

Anterior Tooth Inclination

Proclined maxillary incisors generally reduce the incisor display, compared to uprighted and retroclined maxillary incisors which increase incisor display. In this way, tooth inclination

may contribute to inadequate or excessive tooth display, both of which can negatively impact perceived esthetics.¹⁶

Occlusal Plane Orientation

A cant of occlusal plane impacts the relationship between the maxillary teeth and the border of the lower lip both at rest and during full smile.¹⁶ A cant of the maxillary occlusal plane directed upward and anteriorly will result in maxillary incisal edges that do not follow the curvature of the lower lip, reducing esthetics during smile. When evaluating layperson perception of facial esthetics in individuals with a commissure line cant, laypeople express a preference for occlusal plane with a transverse occlusal plan with a similar and coincident cant.¹⁷ This preference may be due to the resultant concordance of the maxillary incisal edges with the lower lip and symmetry of incisal edges and gingival margins.

Dental Midline

The dental midline can be considered the focal point of an esthetic smile.¹⁸ Ideally, the dental midline should correspond with the facial midline—a line from the nasion to the base of the philtrum, or “cupid’s bow.” It should be noted that for dentists and laypeople to judge a smile as unattractive a significant deviation in midline position is necessary.¹⁹ Mild midline discrepancies

may be present and a patient's smile can still be assessed as acceptable in cases when other esthetic smile components and a vertically-oriented interproximal contact between the maxillary central incisors are present.¹⁹ In these cases mild midline discrepancies may be acceptable if other aspects of smile esthetics are present (Figure 4).

Buccal Corridor Fill

The negative or empty space between the buccal surfaces of the posterior teeth and the commissures of the mouth during smile is called the buccal corridor.^{20,21} The literature is unclear on the impact of the buccal corridor space on smile esthetic perception. Complete fill of the buccal corridor in patients with a complete maxillary denture results in a less esthetic and less natural in appearance, but in patients who have received orthodontic therapy complete fill of the buccal corridor, resulting in display of teeth #3-14 is considered optimal.²¹⁻²³ Transverse arch dimension can influence buccal corridor fill; a broad arch generally results in more complete fill of the buccal corridor space than a constricted arch.²² The relative antero-posterior position of the maxilla within the frame of the lips can also impact buccal corridor (Figure 5).^{16,20}

Lips

The upper and lower lips make a frame around the teeth, gingiva, and the oral cavity to form the external border of a smile and the shape and mobility of the lips can influence the amount of tooth and gingival display. Research has established that individuals with different training weigh the relative value of lips and teeth on esthetics of a smile. Orthodontists

rated teeth and lips equally in relation to smile esthetics, whereas restorative specialists are more influenced by the lips than the teeth.²⁴ In contrast, laypersons failed to identify the esthetic details and component of the smile.²⁴

Lip Length

Mean lip length is 23mm in males and 20mm in females and generally increases with age.¹¹ Lip length should be measured in repose from the sub-nasal to the most inferior visible portion of the upper lip at the midline. In a harmonious smile, lip length is nearly equivalent in length to commissure height. When an individual smiles, the commissures of the mouth move outward and upward and create an arched lip form. This shape is considered ideally esthetic. It should also be noted that decreased upper lip length can lead to lip incompetence, excessive gingival display, and/or a reverse resting upper lip line, which can all negatively impact perceived smile esthetics.²⁵

Lip Mobility

When a patient smiles, the upper lip will elevate and display the maxillary incisors. Symmetry of movement in this case allows for uniform display and is considered esthetic.²³ Mean lip mobility results in a reduction of 80% of the original lip length and a subsequent display of maxillary anterior teeth of approximately 10mm with a natural smile.²³ Physiologic lip mobility ranges from 2-12mm, but considerable heterogeneity is present among individuals.²⁶ Lip mobility is greater in women compared to men and women are more likely to have excessive lip mobility.²³ Such excessive lip mobility may cause excessive gingival display during full smile despite normal lip length (Figure 6).

Figure 4: Example of a smile with a midline discrepancy and a vertically-oriented interproximal contact between #8 and #9

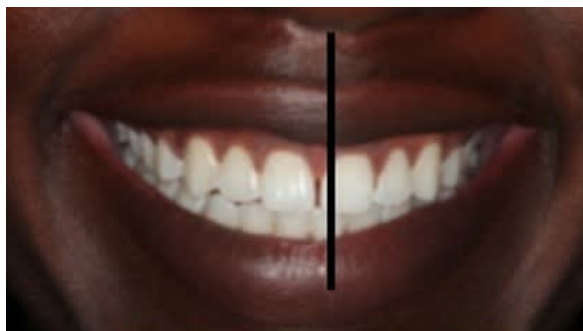
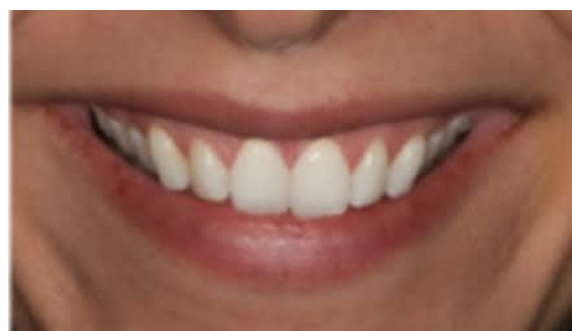
Figure 5: Incomplete buccal corridor fill related to transverse arch dimension.



Lip Curvature

Lip curvature may be upward, straight, or downward and is assessed by evaluating the position of the midline upper lip compared to the position of the commissure during full smile.^{22,27,28} Both straight and upward lip curvatures were assessed by laypersons and dentists as more esthetic than downward lip curvatures.²² Facial musculature is the primary determinant of lip curvature, so interventions that do not address the musculature may be limited in addressing a downward lip curvature (Figure 7).

Lip Volume

Lips with high volume generally result in more exposure of the maxillary incisors at smiling, rest and while speaking.²⁹ While the importance of lip volume in smile esthetics has evolved over time and has been impacted by the prevalence of facial fillers and social media, higher lip volume is considered the current standard of esthetics.²⁹ Anatomical variations in lip size, cosmetic interventions, and the anteroposterior positioning of teeth all influence lip volume.³⁰ Both younger age and female gender are associated with higher lip volume.³⁰

Gingival Scaffold

The gingival tissues frame the teeth and influence the perceived shape and shade of teeth. The gingival components of the smile are the color, contour, texture, and height of the gingiva (Figure 8).

Gingival Color/Texture

Gingival inflammation, as seen in periodontal diseases, including gingivitis and periodontitis, can cause alterations in color, texture, and contour of the gingiva.³¹ Healthy gingiva is generally considered to be coral pink in color and in many cases has a stippled (or “tufted”) appearance. Gingival edema, erythema, and/or rolled gingival margins are considered unesthetic and can impact the overall perception of attractiveness and health.³²

Papillary Fill

Papillary contours can be classified with the Jemt index:³³ Papillary fill that completely fills the space from the interdental contact point to the level of the surrounding gingival tissues (Jemt index 3) is considered most esthetic. Papillary overfill (Jemt index 4), seen in cases of significant gingival inflammation, and missing

Figure 7: Comparison of an upward and downward lip curvature.

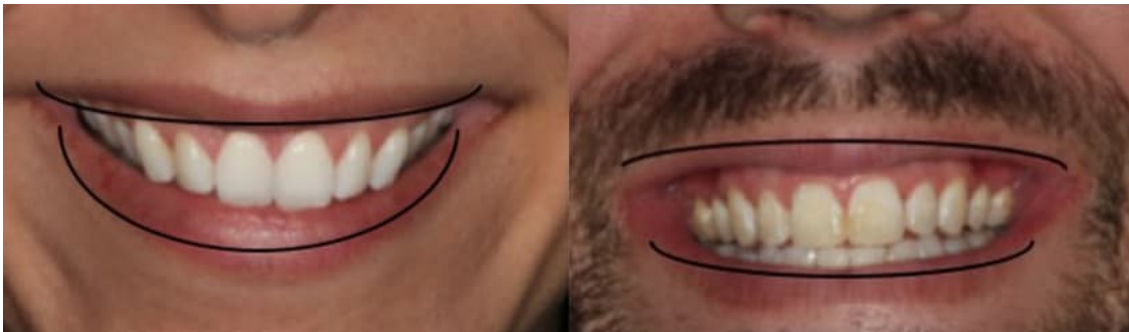

Figure 8: The gingival scaffold, including gingival color/texture, gingival contours/recession, and papillary fill can impact perceived esthetics.

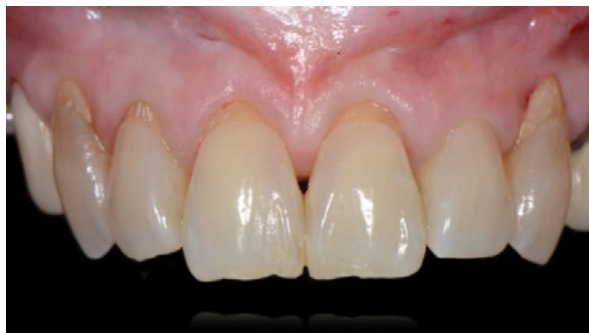
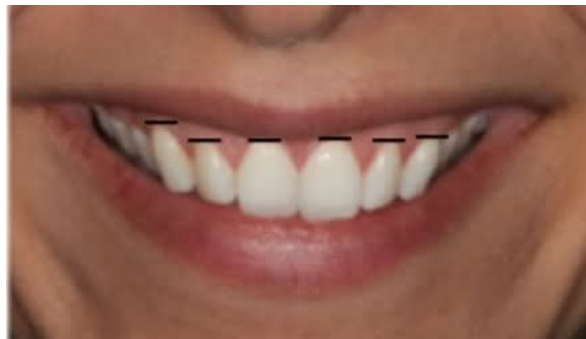
Figure 9: Gingival margin positions demonstrating less than ideal positioning that results in perceived smile asymmetry.



Jemt Index Category	Description of papillary appearance
Index 0	Absence of interproximal dental papilla
Index 1	Presence of gingival papilla, measuring less than half the distance between the imaginary line and the interdental contact point
Index 2	Presence of gingival papilla, measuring at least half the distance between the imaginary line and the interdental contact point, but without filling the entire interdental space
Index 3	Presence of gingival papilla filling the entire interdental space
Index 4	Hyperplastic gingival papilla, covering part of the crown or prosthetic crown adjacent to the studied area.

or blunted gingival papillae (Jemt index 0-2) are both considered suboptimal esthetically.³² Incomplete papillary fill is sometimes referred to as a “black triangle” and may be caused by interproximal bone loss, triangular tooth form, root divergence, open interdental contacts, or because of inflammatory periodontal disease and/or its treatment with resective periodontal surgery. It is well-established that papillary fill is related to the distance from the interdental contact point to the crest of the interproximal bone. When the distance from the contact point to the crest of the alveolar bone is ≤ 5 mm, papillae are present 100% of the time, but when the distance between the contact point and the interproximal crest is 6mm is papillae are only present 56% of the time.³⁴

Gingival Contours

The relative position of the gingival margins of anterior teeth and their relationship to one another contributes to overall smile esthetics.³⁵⁻³⁷ Further, an arched gingival contour with a height of contour slightly into the distal third of an incisor tooth.³⁵⁻³⁷ The central incisors generally have gingival margins that correspond to the canines and the lateral incisors are approximately 1-1.5mm more coronal to a line between the heights of

contour of the central incisors and the canines. Discrepancies in the position of the gingival margins may be caused by incisal attrition, ankylosis, altered passive eruption, tooth malposition, dental malocclusion, or gingival recession (Figure 9).³⁵⁻³⁷

Gingival Display

When the upper lip is concordant with the gingival zeniths of the central incisors at full smile, this is considered no gingival display.^{28,38,39} A “gummy smile” or excessive gingival display as well as a low smile line where teeth are not fully displayed can compromise smile esthetics. Gingival display may be categorized into one of five classes. In class 1, the lip is positioned well above the cervical portion of the maxillary teeth at full smile and in class 5 the lip is positioned to provide full coverage of the maxillary teeth during the natural smile. While the ideal amount of gingival display is not uniform among populations, many investigators state that a lower margin of the upper lip that aligns evenly with the gingival margin of the maxillary central incisors is considered optimally esthetic.^{28,38,39} However, there are studies that suggest that in some populations, a combination of maxillary incisor visibility and gingival display up to

Forensic Relationships Between Smile Components

Smile esthetics contributes to overall facial attractiveness through the interaction of the individual components of smile esthetics, smile and facial symmetry, and cultural/gender influences on external perception.^{42,43} Increases in facial attractiveness, including smile esthetics, has been shown to be related to an improved quality of dating partners.⁴⁵⁻⁴⁸ Furthermore, attractive individuals are perceived to be more intelligent and nicer than those assessed as less attractive.⁴⁵⁻⁴⁸ It is very difficult, however, to create a single standard for facial attractiveness and to quantify the contribution of individual components to overall attractiveness. There are also significant differences in the variation of what is perceived attractive between dental healthcare professionals and laypersons.⁴⁹ In general, increased facial and smile symmetry and individuals who meet associated gender norms is associated with and increased in the perception of attractiveness.^{50,51}

Smile Symmetry

Facial and smile symmetry is generally considered to increased perceived esthetics.^{50,51} The static symmetry of individual components of the smile, including tooth size and gingival contours, and the dynamic symmetry of lip movement during smiling and speaking contribute to overall esthetic perception.⁵² A difference in lateral incisor width of > 1mm between contralateral teeth was judged to be unesthetic by both dentists and laypersons. However, when the width of both lateral incisors was altered by that amount, the reduction in esthetics was not judged as harshly by either group.⁵³ Negative esthetic assessment is also associated with unilateral differences in the relative vertical positioning of the corners of the mouth during full smile, which can be related to variations in facial musculature of partial facial paralysis.^{54,55} Furthermore, an oblique commissural line that is off-parallel with the interpupillary line, can reduce perceived esthetics and may give the illusion of skeletal asymmetry and/or a transverse cant of the maxilla.¹⁶

Smile Arc

When the maxillary incisal edges align with the inner contour of the lower lip at full smile, it

is considered ideal. This positioning is often described as “consonant”.⁵⁶ Younger individuals tend to display a more pronounced curvature of the incisal edges and lips during smiling and can straighten with age.⁵⁷ This association with youth may lead to the perceived desirability of such a relationship for optimal esthetics.⁵⁷ Orthodontic treatment has also been associated with flatter smile arcs than those found in individuals with untreated dentition and normal occlusions.¹⁸ This flattening of the smile arc may inadvertently compromise overall esthetics post-orthodontic therapy.^{18,28,58}

Assessment of Smile Esthetics

Assessment of smile esthetics begins with an understanding of what defines an esthetic smile. While Margaret Wolfe Hungerford first stated that “beauty is in eye of the beholder”, as dental healthcare professionals, we also need to identify standards of optimal esthetics so that we can aim to create the best results for our patients. During the assessment process, dental healthcare providers must critically assess individual smile components and their relationships to each other and the overall facial structure. Both static and dynamic evaluations should be utilized to allow for capturing all aspects of ideal smile esthetics. Full facial photographs at rest, in a social or posed smile, and in full smile in a 1:1 image ratio can allow for measurements of dental midline alignment, lip length, lip mobility, gingival display, buccal corridor fill, smile cant, and consonant/non-consonant smile arc. Intraoral measurements of tooth length and width:length ratios can be made with a periodontal probe and/or a Chu esthetic gauge (Hu-Friedy, Cary, NC). Further, gingival position (gingival recession/overgrowth), gingival color/contour, clinical signs/symptoms of inflammation, and Jemt classification of papillary fill should also be recorded during a comprehensive intraoral examination. Lastly, utilization of videography to assess lip movements during smiling and speech may be helpful in patients with high esthetic concerns.

Emerging technologies to improve esthetic assessment, including machine learning and three-dimensional stereophotogrammetry, have been proposed to improve esthetic assessment and eliminate perception bias.⁵⁹

⁶¹ While these technologies are not widely used currently, their incorporation into future research may be critical to develop these novel tools.

Cultural Influences on the Perceptions of Smile Esthetics

We know from artwork and historic references that ideals of attractiveness have changed over time and may vary based upon cultural norms. While we may identify certain factors as universally appealing, facial attractiveness and smile esthetics are influenced by the individuals judging the ultimate result—the patients. Dental healthcare professionals, including surgeons, orthodontists, and restorative dentists, and plastic surgeons have a higher standard for facial esthetics than laypersons with similar demographics and socio-economic status.^{62,63} Other factors that influence whether individuals are perceived as having facial attractiveness include age, gender, geographic local esthetic norms, and cultural norms. It is well-established that men and older individuals being more tolerant of certain deviations from esthetic standards than women and younger individuals.⁶⁴⁻⁶⁹ Patients' self-perception and their social reference groups, including peer groups and social media, affect preferences regarding the importance of smile esthetics. These influences are weighted more heavily than the opinion of dental healthcare providers.⁷⁰ Lastly, even in our modern age, esthetic ideals continue to evolve and parameters of ideal smile esthetics can be influenced by mass media, including television, films, magazines, fashion, advertisements and social media.^{71,72} For example, trends in facial plastic surgery indicate that the mean age for many facial plastic surgery techniques is decreasing, which has been attributed to the increased popularity of selfies and filters on social media.⁷³ The popularity of lip fillers in younger populations has resulted in an increase in the number of individuals with an “over-enhanced” appearance to their lips.⁷³

Many things influence the perception of facial attractiveness; thus, it is critically important for dental healthcare providers to thoroughly assess patients' chief complaints and consider reversible and/or technological interventions

to demonstrate potential outcomes prior to irreversible interventions. Because ideal attractiveness is difficult to define, assessment of individual patient satisfaction with likely outcomes of therapy and management patient expectations to ensure that they are in line with predictable results is critical to ensure that patients expectations are met.

Addressing Compromised Smile Esthetics: Multidisciplinary Dental Interventions

We have reviewed the individual components of an ideal smile. However, it is important to note, that it is rare that an individual would have all those components prior to intervention. Comprehensive assessment of the patient's current conditions and the deviations from the ideal is the initial step in creating a multidisciplinary treatment plan to address esthetic concerns. Further, an in-depth understanding of individualized patient needs, and desires is necessary to allow for development of a patient-centered and interdisciplinary treatment plan to address patient concerns.

Patient complaints limited to tooth shape and/or shade can generally be addressed with bleaching and/or restorative therapies. Many other complaints can have more complex underlying etiologies and require a more robust evaluation to determine the best ways to address those concerns. For example, short clinical tooth crowns may be associated with tooth fracture or wear, gingival overgrowth, or altered passive eruption. Thorough investigation of incisal display and lip position at rest and in full smile is necessary to allow to determine if orthognathic, orthodontic, restorative, or periodontal surgical interventions, or a combination of these, would be required.^{2,74} In cases were the patient presents with little to no incisor display at rest with a normal lip line during full smile, this is generally associated with limited crown height incisally and the crowns may be extended using restorative techniques. Conversely, if the short clinical crowns are associated with excessive gingival display and normal incisor display at rest, the patient will likely require resective surgical intervention to

perform a gingivectomy or a crown-lengthening procedure, depending upon the classification of altered passive eruption. Two common esthetic concerns, the methods to determine the proper diagnosis, the interventions to address these concerns are discussed here.

Excessive Gingival Display / “Gummy Smile”

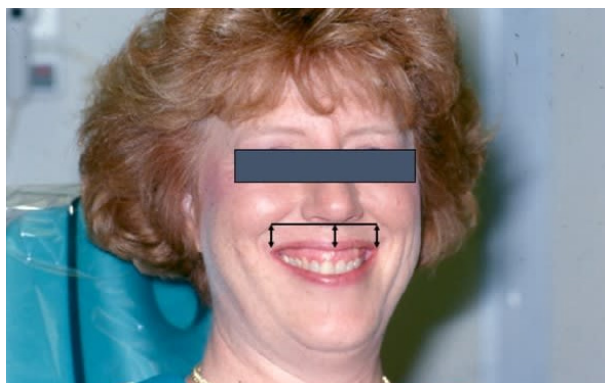Excessive gingival display, also referred to as a “gummy smile”, can be attributed to one or more of the following factors: 1) gingival overgrowth, 2) altered passive eruption, 3) vertical maxillary excess (VME), 4) short upper lip, 5) hypermobile upper lip, and 6) dentoalveolar extrusion.⁷⁵ Careful clinical examination can distinguish between these underlying conditions. It is critical that the dental healthcare professional is able to assess clinical crown height, lip length and mobility, and vertical facial third symmetry to identify one or more contributing factors for excessive gingival display.^{76,77} If the excessive gingival display is associated with gingival overgrowth or altered passive eruption, patients will present with short clinical crowns and either excessive gingival tissues or excessive gingiva and alveolar bone, respectively.² Patients with altered passive eruption have a periodontal attachment apparatus at a position that is more coronal than anatomic norms, which can be determined radiographically and through bone sounding. These patients should be treated with resective surgical interventions—generally gingivectomy or esthetic crown lengthening—and they should also have an evaluation of potential underlying systemic conditions or medications that may contribute to gingival overgrowth.⁷⁸ Both VME and a short upper lip may present with lip incompetence, but lip length will be normal in cases of VME.² VME is associated with a lengthening of the lower facial third, which can be assessed in a facial photograph at rest. VME may be addressed with orthognathic surgery and a short upper lip would require a lip lengthening surgery to reduce gingival display.⁷⁷ Individuals with excessive gingival display related to lip hypermobility present with normal lip length with increased mobility during dynamic lip movement. This can be assessed using video capture of a patient

smiling and/or speaking. Addressing this may require lip repositioning surgery and/or treatment with botulinum toxin to reduce facial muscle hyperfunction.⁷⁷⁻⁷⁹ Dentoalveolar extrusion occurs due to over-eruption of maxillary incisors. In addition to excessive gingival display, patients with dentoalveolar extrusion present with increased clinical crown length, potential lip incompetence, and alteration of tooth arch curvature.⁷⁷ Treatment should include orthodontic intrusion of the supraerupted incisors. In some cases, patients may present with multiple underlying etiologies for excessive gingival display and coordinated interdisciplinary care may be necessary to achieve optimal results.⁷⁷

Smile Asymmetry

Symmetry of oral structures in both static and dynamic smile analysis has been associated with increased perceived facial attractiveness.^{80,81} It is important in cases where patients are concerned about asymmetry and/or when esthetic concerns are related to a lack of symmetry that dental healthcare providers understand the chief complaint so that therapy can be targeted to meet patient needs. Asymmetry associated with tooth shape may be addressed restoratively but could also potentially require orthodontic tooth movement to establish space and proper tooth positioning to then allow for ideal restoration of teeth. Asymmetry associated with midline, smile arch, or smile cant may require treatment with orthodontic and/or orthognathic means.⁸² Gingival contour asymmetry may be due to gingival recession or gingival overgrowth. Comprehensive periodontal examination, including accurate recording of the gingival margin position in relation to the cemento-enamel junction, and documentation of patient complaints as well as clinical findings is necessary to best address concerns of asymmetry. For individuals whose gingival contour asymmetry is associated with gingival recession, periodontal plastic surgery procedures to achieve root coverage, either alone or in combination with restorative therapies can be used to reestablish appropriate gingival contours.⁸² Conversely, in the case of individuals who demonstrate gingival contour asymmetry associated with

Figure 10: Excessive Gingival Display may be due to 1) gingival overgrowth, 2) altered passive eruption, 3) vertical maxillary excess (VME), 4) short upper lip, 5) hypermobile upper lip, and 6) dentoalveolar extrusion.



gingival overgrowth, assessment to determine if resective procedures involving gingival tissues only or gingival tissues and underlying alveolar bone should be performed. Lip asymmetry may be associated with volume and/or mobility. Asymmetry associated with lip volume may be addressed with dermal fillers^{83,84} and myofascial exercises may be helpful to strengthen weakened muscles leading to asymmetrical lip movement.⁸⁵

Summary

The average woman in the US smiles 62 times daily and a smile can convey so much about a person and their mood.⁸⁶ Many factors individually and their interaction contribute to smile and facial esthetics. It is important that clinicians can identify the factors that may be contributing to a patient's complaint of compromised esthetics and to understand the ideal multidisciplinary interventions that can allow establishment

Figure 11: Symmetrical smiles and facial contours are considered to be more esthetic than asymmetry. Identification of the underlying causes of perceived asymmetry allows the dental healthcare provider to address a patient's esthetic concerns more fully.



of a more harmonious esthetic environment! A thorough assessment is necessary to identify all the underlying etiologies that may contribute to reduced esthetics. This should include identifying address individual patient's perceived esthetic challenges. Further, clinicians should understand the likely predictable outcomes of common treatments for esthetic concerns. Finally employing digital technologies and/or reversible interventions to demonstrate likely treatment outcomes can allow patients and dental healthcare providers to develop an understanding of the achievable outcomes of treatment. In many cases of esthetic compromise, more than one factor is contributing to the reduction in perceived esthetics and the engagement of an interdisciplinary team is ideal to deliver solutions for such patients that address multifactorial etiologies that underpin compromised smile esthetics in those cases.

Course Test Preview

To receive Continuing Education credit for this course, you must complete the online test. Please go to: www.dentalcare.com/en-us/professional-education/ce-courses/ce649/start-test

- 1. According to the American Association of Orthodontics, what percentage of US adults are unhappy with their smile?**
 - A. 25%
 - B. 33%
 - C. 50%
 - D. 75%
- 2. _____% of younger Americans (18-24 years old) report that they have untagged a picture of themselves on social media due to a negative perception of their smile.**
 - A. 12%
 - B. 26%
 - C. 35%
 - D. 48%
- 3. The most common complaint reported by individuals who reported to be dissatisfied with their smile was:**
 - A. Tooth color
 - B. Tooth size
 - C. Tooth position
 - D. Lip shape
- 4. Consider the following two statements: Hue distinguishes between different families of color (i.e., blue versus yellow). Chroma characterizes the lightness of a color within that particular hue.**
 - A. Both statements are true
 - B. The first statement is true, the second statement is false
 - C. The first statement is false, the second statement is true
 - D. Both statements are false
- 5. Untreated teeth, on average, demonstrate a _____ hue.**
 - A. B1
 - B. C2
 - C. A3
 - D. D4
- 6. What is the width:length ratio range that is considered esthetically pleasing?**
 - A. 60-65%
 - B. 67-72%
 - C. 75-80%
 - D. 80-88%
- 7. Mean lip length, as measured from the sub-nasal to the most inferior visible portion of the upper lip at the midline, is _____mm in males and _____mm in females and generally increases with age.**
 - A. 23; 20
 - B. 25; 22
 - C. 27; 23
 - D. 28; 25

8. **Consider the two following statements: Physiologic lip mobility ranges from 2-12mm, but considerable heterogeneity is present among individuals. Lip mobility is greater in women compared to men and women are more likely to have excessive lip mobility.**
- A. Both statements are true
 - B. The first statement is true, the second statement is false
 - C. The first statement is false, the second statement is true
 - D. Both statements are false
9. **Which Jemt papillary fill index is considered optimally esthetic?**
- A. Jemt Index 0
 - B. Jemt Index 1
 - C. Jemt Index 2
 - D. Jemt Index 3
10. **Gingival positions and contours associated with optimal esthetics include: central incisors with gingival margins that correspond to those of the canines and the lateral incisors with positions approximately _____ more coronal to a line between the heights of contour of the central incisors and the canines.**
- A. 0.5mm
 - B. 1-1.5mm
 - C. 1.5-2mm
 - D. 2.5mm
11. **All the following influence the amount of gingival display considered ideal EXCEPT one. Which one is the exception?**
- A. subject age
 - B. subject gender
 - C. societal norms within individual communities
 - D. tooth color
12. **A unilateral difference in lateral incisor width of _____mm between contralateral teeth was judged to be unesthetic by both dentists and laypersons, but bilateral alterations by the same amount did not impact esthetic perception as significantly.**
- A. > 1mm
 - B. >1.5mm
 - C. >2mm
 - D. >3mm
13. **Consider the following two statements: When the maxillary incisal edges overlap by 1mm with the inner contour of the lower lip at full smile, it is considered to be ideal. This positioning is often described as “consonant”. Older individuals tend to display a more pronounced curvature of the incisal edges and lips during smiling.**
- A. Both statements are true
 - B. The first statement is true, the second statement is false
 - C. The first statement is false, the second statement is true
 - D. Both statements are false

14. Consider the following two statements:
Full facial photographs should be taken in full smile only in a 1:1 image ratio. Such photographs can allow for assessment of dental midline alignment, lip length, lip mobility, gingival display, buccal corridor fill, smile cant, and consonant/non-consonant smile arc.
- A. Both statements are true
 - B. The first statement is true, the second statement is false
 - C. The first statement is false, the second statement is true
 - D. Both statements are false
15. **Excessive gingival display, also referred to as a “gummy smile”, can be attributed to one or more of the following factors EXCEPT one. Which one is the exception?**
- A. gingival overgrowth
 - B. lack of lip mobility
 - C. altered passive eruption
 - D. vertical maxillary excess (VME)
16. Consider the following two statements:
Both VME and a short upper lip may present with lip incompetence, but lip length is within normal ranges in cases of VME.
VME is associated with a shortened the lower facial third, which can be assessed in a facial photograph at rest.
- A. Both statements are true
 - B. The first statement is true, the second statement is false
 - C. The first statement is false, the second statement is true
 - D. Both statements are false
17. **Lip asymmetry may be associated with _____ and, based upon the underlying etiology, asymmetry can be address with dermal fillers, botulinum toxin, and/or myofascial exercises.**
- A. volume and mobility
 - B. volume and curvature
 - C. mobility and color
 - D. volume and length
18. **The average US woman smiles ____ times each day.**
- A. 8
 - B. 22
 - C. 50
 - D. 62

References

1. American Academy of Orthodontists Press Releases. November 11, 2014, "A Good Smile Can Lead to Improved Love, Social and Professional Success, According to the American Association of Orthodontists" Accessed February 2, 2022.
2. Garber DA, Salama MA. The aesthetic smile: diagnosis and treatment. *Periodontol* 2000 1996; 11:18-28.
3. Preston JD. The golden proportion revisited. *J Esthet Dent* 1993; 5:247-251.
4. Levin EI. Dental esthetics and the golden proportion. *J Prosthet Dent* 1978; 40:244-252.
5. Qualtrough AJ, Burke FJ. a look and dental esthetics. *Quintessence Int* 1994; 25:7-14.
6. Zawawi KH, Malki GA, Al-Zahrani MS, Alkhiary YM. Effect of lip position and gingival display on smile and esthetics as perceived by college students with different educational backgrounds. *Clin Cosmet Investig Dent* 2013; 5:77-80.
7. Afroz S, Rathi S, Rajput G, Rahman SA. Dental esthetics and its impact on psycho-social well-being and dental self-confidence: a campus-based survey of north Indian university students. *J Indian Prosthodont Soc.* 2013;13(4):455-460.
8. Munsell, Albert H. A Pigment Color System and Notation. *Am J Psychol.* 1912; 23(2): 236-244.
9. Hasegawa A, Ikeda I, Kawaguchi S. Color and translucency of in vivo natural central incisors. *J Prosthet Dent.* 2000; 83: 418-423.
10. Esan TA, Olusile AO, Akeredolu PA. Factors influencing tooth shade selection for completely edentulous patients. *J Contemp Dent Pract.* 2006; 7: 80-87.
11. Niaz MO, Nasseem M, Elcock C. Ethnicity and perception of dental shade esthetics. *Int J Esthet Dent* 2015; 10(2): 286-298.
12. Söderfeldt B, Palmqvist S, Arnbjerg D. Factors affecting attitudes toward dental appearance and dental function in a Swedish population aged 45-69 years. *Community Dent Health* 1993; 10: 123-130.
13. Peck S, Peck L, Kataja M. Some vertical lineaments of lip position. *Am J Orthod* 1992; 101: 519-524.
14. Gillen RJ, Schwartz RS, Hilton TJ, Evans DB. An analysis of selected normative tooth proportions. *Int J Prosthodont* 1994; 7: 410-417.
15. German DS, Chu SJ, Furlong ML, Patel A. Simplifying optimal tooth-size calculations and communications between practitioners. *Am J Orthod Dent Orthop* 2016; 150(6): 1051-1055.
16. Sarver DM, Ackerman MB. Dynamic smile visualization and quantification: Part 2. Smile analysis and treatment strategies. *Am J Orthod* 2003; 124: 116-127.
17. Silva BP, Jiménez-Castellanos E, Finkel S, Macias IR, Chu SJ. Layperson's preference regarding orientation of the transverse occlusal plane and commissure line from the frontal perspective. *J Prosthet Dent.* 2017; 117(4): 513-516.
18. Lombardi RE. The principles of visual perception and their clinical application to denture esthetics. *J Prosth Dent* 1973; 29: 358-382.
19. Kokich VG, Kiyak H, Shapiro PA. Comparing perceptions of dental and lay people to altered dental esthetics. *J Esthet Dent* 1999; 11: 311-324.
20. Sarver DM. The importance of incisor positioning in the esthetic smile: The smile arc. *Am J Orthod* 2001; 120: 98-111.
21. Frush JP, Fischer RD. The dynesthetic interpretation of the dentogenic concept. *J Prosth Dent* 1958; 8: 558-581.
22. Dong JK, Jin H, Cho HW, Oh SC. The esthetics of the smile: A review of some recent studies. *J Prosthodont* 1999; 12: 9-19.
23. Rigsbee OH, Sperry TP, BeGole EA. The influence of facial animation on smile characteristics. *Int J Adult Orthod Orthog Surg* 1988; 3: 233-239.
24. Farzanegan F, Jahanbin A, Darvishpour H, Salari S. Which has a greater influence on smile esthetics perception: Teeth or Lips? *Iran J Otorhinolaryngol.* 2013; 25(73): 239-244.
25. Ackerman MB, Ackerman JL. Smile analysis and design in the digital era. *J Clin Orthod* 2002; 36: 221-236.

26. Zachrisson BU. Esthetic factors involved in anterior tooth display and the smile: Vertical dimension. *J Clin Orthod* 1998; 32: 432-445.
27. Phillips E. The classification of smile patterns. *J Can Dent Assoc* 1999; 65: 252-254.
28. Hulsey CM. An esthetic evaluation of lip-teeth relationships present in the smile. *Am J Orthod* 1970; 57: 32-44.
29. Machado AW. 10 commandments of smile esthetics. *Dental Press J Orthod*. 2014; 19(4): 136-157.
30. Machado AW, Santos TC, Araujo TM, Gandini LG. Integração Ortodontia e Dermatologia na busca da excelência na estética labial. *Rev Clin Ortodon Dental Press* 2010; 9(3): 47-56.
31. Orban B. Histology and Physiology of the Gingiva. *J Am Dent Assoc* 1952; 44(6): 624-628.
32. Morley J, Eubank J. Macroesthetic elements of smile design. *J Am Dent Assoc* 2001; 132: 39-45.
33. Jemt, T. Regeneration of gingival papillae after single-implant treatment. *Int J Periodont Res Dent* 1997; 174: 326-333.
34. Tarnow DP, Magner AW, Fletcher P. The effect of the distance from the contact point to the crest of bone on the presence or absence of the interproximal dental papilla. *J Periodontol*. 1992;63(12):995-996.
35. Sabri R. Treatment of a Class I malocclusion with an ankylosed maxillary central incisor. *Am J Orthod* 2002; 122: 557-565.
36. Dolt AH, Robbins JW. Altered passive eruption: An etiology of short clinical crowns. *Esth Dent* 1997; 28: 363-372.
37. Loe H, Ånerud Å, Boysen H. The Natural History of Periodontal Disease in Man: Prevalence, Severity, and Extent of Gingival Recession *J Periodontol* 1992; 63(6): 489-495.
38. Ahmad I. Geometric considerations In anterior dental aesthetics: restorative principles. *Pract Periodontics Aesthet Dent* 1998; 10: 813-824.
39. Mackley RJ. An evaluation of smiles before and after orthodontic treatment. *Angle Orthod* 1993; 63: 183-190.
40. Geron S, Atalia W. Influence of sex on the perception of oral and smile esthetics with different gingival display and incisal plane inclination. *Angle Orthod* 2005; 75: 778-784.
41. Ackerman MB, Brensinger C, Landis JR. An evaluation of dynamic lip-tooth characteristics during speech and smile in adolescents. *Angle Orthod* 2004; 74: 43-50.
42. Hunt O, Johnston C, Hepper P, Burden D, Stevenson M. The influence of maxillary gingival exposure on dental attractiveness ratings. *Eur J Orthod* 2002; 24: 199-204.
43. Keating CF. Gender and the physiognomy of dominance and attractiveness. *Soc Psychol Quart* 1985; 48: 61-70.
44. Bashour M. History and current concepts in the analysis of facial attractiveness. *Plast Reconstr Surg* 2006; 118: 741-756.
45. Cunningham MR. Measuring the physical in physical attractiveness: quasi-experiments on the sociobiology of female facial beauty. *J Personal Soc Psychol* 1986; 50: 925-935.
46. Cunningham MR, Barbee AP, Pike CL. What do women want? Facialmetric assessment of multiple motives in the perception of male facial attractiveness. *J Personal Soc Psychol* 1990; 59: 61-72.
47. Riggio RE, Widaman KF, Tucker JS, Salinas C. Beauty is more than skin deep: components of attractiveness. *Bas Appl Soc Psychol* 1991; 12: 423-439. Accessed February 21, 2022
48. Shaw WC. The influence of children's dentofacial appearance on their social attractiveness as judged by peers and lay adults. *Am J Orthod* 1981; 79: 399-415.
49. Foo P, Sampson W, Roberts R, Jamieson L, David D. Facial aesthetics and perceived need for further treatment among adults with repaired cleft as assessed by cleft team professionals and laypersons. *Eur J Orthod* 2013; 35(3): 341-346.
50. Rhodes G, Sumich A, Byatt G. Are average facial configurations attractive only because of their symmetry? *Psychol Sci* 1999; 10(1): 52-58. Accessed February 21, 2022
51. Mealey L, Bridgstock R, Townsend GC. Symmetry and perceived facial attractiveness: a monozygotic co-twin comparison. *J Personal Soc Psychol* 1999; 76(1): 151-158.
52. Hönn M, Göz G. The ideal of facial beauty: a review. *J Orofac Orthop Fortschr Der Kieferorthopädie* 2007; 68(1): 6-16.

53. Alsulaimani FF, Batwa W. Incisors' proportions in smile esthetics. *J Orthod Sci.* 2013; 2(3): 109-112.
54. Rubin LR. The anatomy of a smile: Its importance in the treatment of facial paralysis. *Plast Reconstr Surg* 1974; 53: 384-387.
55. Paletz JL, Manktelow RT, Chaban R. The shape of a normal smile: Implications for facial paralysis reconstruction. *Plast Reconstr Surg* 1994; 93: 784-789.
56. Sarver DM, Ackerman MB. Dynamic smile visualization and quantification: Part 1. Evolution of the concept and dynamic records for smile capture. *Am J Orthod* 2003; 124: 4-12.
57. Miller CJ. The smile line as a guide to anterior esthetics. *Dent Clin N Am* 1989; 33: 157-164.
58. Ackerman JL, Ackerman MB, Brensinger CM, Landis JR. A morphometric analysis of the posed smile. *Clin Orthod Res* 1998; 1: 2-11.
59. Gan J, Li L, Zhai Y, Liu Y. Deep self-taught learning for facial beauty prediction. *Neurocomputing* 2014; 144: 295-303. Accessed February 21, 2022
60. Xie D, Liang L, Jin L, Xu J, Li M (2015) SCUT-FBP: a benchmark dataset for facial beauty perception. In: 2015 IEEE international conference on systems, man, and cybernetics IEEE, pp. 1821-1826.
61. Ras F, Habets LL, van Ginkel FC, Pahl-Andersen B. Quantification of facial morphology using stereophotogrammetry--demonstration of a new concept. *J Dent* 1996; 24(5): 369-374.
62. Proffit WR, Sarver DM, Ackerman JL. Diagnosis and treatment planning. In: Proffit WR, Fields HW, Sarver DM, editors. *Contemporary orthodontics*. Ed. 4. St. Louis: Mosby Elsevier; 2007. pp. 167-233.
63. Kiyak HA. Does orthodontic treatment affect patients' quality of life? *J Dent Educ* 2008; 72(8): 886-894.
64. Iores-Mir C, Silva E, Barriga MI, Lagravere MO, Major PW. Lay person's perception of smile aesthetics in dental and facial views. *J Orthod* 2004; 31(3): 204-209.
65. McLeod C, Fields HW, Hechter F, Wiltshire W, Rody W, Christensen J. Esthetics and smile characteristics evaluated by laypersons. *Angle Orthod* 2011; 81(2): 198-205.
66. Ioi H, Kang S, Shimomura T, Kim SS, Park SB, Son WS, et al. Effects of vertical positions of anterior teeth on smile esthetics in Japanese and Korean orthodontists and orthodontic patients. *J Esthet Restor Dent* 2013; 25(4): 274-282.
67. Ker AJ, Chan R, Fields HW, Beck M, Rosenstiel S. Esthetics and smile characteristics from the layperson's perspective: a computer-based survey study. *J Am Dent Assoc* 2008; 139(10): 1318-1327.
68. Tüzgiray YB, Kaya B. Factors affecting smile esthetics. *Turk J Orthod* 2013; 26(1): 58-64. Accessed February 21, 2022
69. Sriphadungporn C, Chamnannidiadha N. Perception of smile esthetics by laypeople of different ages. *Prog Orthod.* 2017;18(1):8.
70. Flores-Mir C, Silva E, Barriga MI, Lagravere MO, Major PW. Lay person's perception of smile aesthetics in dental and facial views. *J Orthod* 2004; 31(3): 204-209.
71. Russello S. The impact of media exposure on self-esteem and body satisfaction in men and women. *J Interdisciplinary Undergrad Res* 2013; 1(1): 1-12. Accessed February 21, 2022
72. Patnaik VVG, Singla R, Bala S. Anatomy of 'A beautiful face and smile' *J Anat Soc India* 2003; 52: 74-80. Accessed February 21, 2022
73. American Academy of Facial Plastic and Reconstructive Surgery. AAFPRS 2018 Annual Survey Reveals Key Trends in Facial Plastic Surgery. Accessed February 21, 2022
74. Kokich VG. The orthodontic-periodontic restorative connection. *Semin Orthod* 1996; 2: 21-30.
75. Silberberg N, Goldstein M, Smidt A. Excessive gingival display--etiology, diagnosis, and treatment modalities. *Quintessence Int.* 2009; 40(10): 809-818.
76. Dym H, Pierre R 2nd. Diagnosis and Treatment Approaches to a "Gummy Smile". *Dent Clin North Am.* 2020; 64(2): 341-349.
77. Abou Arraj RV, Souccar NM. Periodontal treatment of excessive gingival display. *Sem Orthod* 2013; 19(4): 267-278.

78. Dinker S, Anitha A, Sorake A, Kumar K. Management of gummy smile with Botulinum Toxin Type-A: A case report. *J Int Oral Health*. 2014; 6(1): 111-115.
79. Penton-Voak IS, Jones BC, Little AC, Baker S, Tiddeman B, Burt DM, Perrett DI. Symmetry, sexual dimorphism in facial proportions, and male facial attractiveness. *Proc R Soc Lond* 2001; B268: 1617-1623.
80. Grammer K, Thornhill R. Human (*Homo sapiens*) facial attractiveness and sexual selection: the role of symmetry and averageness. *J Comp Psychol* 1994; 108: 233-242.
81. Thiesen G, Gribel BF, Freitas MP. Facial asymmetry: a current review. *Dental Press J Orthod*. 2015;20(6):110-125.
82. Jati AS, Furquim LZ, Consolaro A. Gingival recession: its causes and types, and the importance of orthodontic treatment. *Dental Press J Orthod*. 2016;21(3):18-29.
83. Vedamurthy M, Vedamurthy A. Dermal fillers: Tips to achieve successful outcomes. *J Cutan Aesthet Surg* 2008; 1: 64-67.
84. Dastoor SF, Misch CE, Wang H-L. Dermal Fillers for Facial Soft Tissue Augmentation. *J Oral Implantol* 2007; 33(4): 191-204.
85. Brach JS, vanSwearingen JM. Physical Therapy for Facial Paralysis: A Tailored Treatment Approach. *Physical Therapy* 1999; 79(4): 397-404.
86. LaFrance M, Hecht M, Levy Paluck E. The contingent smile: A meta-analysis of sex differences in smiling. *Psych Bull* 2003; 129(2): 305-334.
87. Munsell Color Three-Dimensional Model. Image Source: https://commons.wikimedia.org/wiki/File:Munsell_1943_color_solid_cylindrical_coordinates.png. Accessed February 21, 2022

Additional Resources

- No Additional Resources Available

About the Author

Maria L. Geisinger, DDS, MS



Implantology from the University of Texas Health Science Center at San Antonio. Dr. Geisinger is a Diplomate in the American Board of Periodontology and a Fellow in the International Team for Implantology. She has served as the President of the American Academy of Periodontology Foundation, as the Chair of the American Dental Association's (ADA's) Council on Scientific Affairs, and on multiple national and regional organized dentistry committees. She currently serves as the Secretary-Treasurer of the American Academy of Periodontology (AAP), as a Board member for the ADA Science and Research Institute, and on numerous AAP and ADA committees and task forces. She has authored over 50 peer-reviewed publications and her research interests include periodontal and systemic disease interaction, implant dentistry in the periodontally compromised dentition, and novel treatment strategies for oral soft and hard tissue regeneration. She lectures nationally and internationally on topics in periodontology and oral healthcare.

Email: miagdds@uab.edu