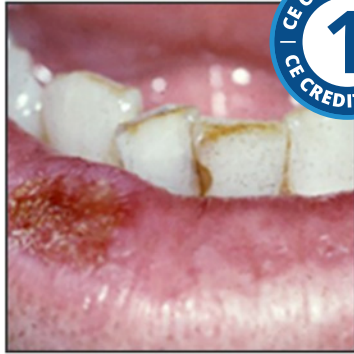

Oral Cancer



Course Author(s): Richard C. Jordan, DDS, PhD, FRCD(C) FRCPath

CE Credits: 1 hour

Intended Audience: Dentists, Dental Hygienists, Dental Assistants, Dental Students, Dental Hygiene Students, Dental Assistant Students

Date Course Online: 11/05/2009

Last Revision Date: 01/26/2025

Course Expiration Date: 01/25/2028

Cost: Free

Method: Self-instructional

AGD Subject Code(s): 730

Online Course: www.dentalcare.com/en-us/ce-courses/ce348

Disclaimers:

- P&G is providing these resource materials to dental professionals. We do not own this content nor are we responsible for any material herein.
- Participants must always be aware of the hazards of using limited knowledge in integrating new techniques or procedures into their practice. Only sound evidence-based dentistry should be used in patient therapy.

Conflict of Interest Disclosure Statement

- The author reports no conflicts of interest associated with this course. He has no relevant financial relationships to disclose.

Introduction – Oral Cancer

Oral Cancer continuing education course presents the important general features of oral cancer, its causes and clinical presentation and how the disease is managed.

Course Contents

- Overview
- Learning Objectives
- General Features
- Risk Factors
- Causes of Oral Cancer
- Clinical Appearance
- Sites of Involvement
- Diagnosis
- Treatment
- Prognosis
- Conclusion
- Course Test
- References
- About the Author

Overview

This course presents the important general features of oral cancer, its causes and clinical presentation and how the disease is managed..

Learning Objectives

Upon completion of this course, the dental professional should be able to:

- Identify the clinical significance of oral cancer, its prevalence and overall survival.
- List the most common risk factors for oral cancer.
- List the causes of oral cancer.
- Describe the most common clinical presentations of oral cancer.
- Describe how oral cancer is treated.

General Features

The most common form of cancer in the mouth is squamous cell carcinoma, which is the sixth most common form of cancer worldwide accounting for approximately 4% of cancers in men and 2% in women.¹ In some countries such as India, as many as one-half of all new cancers are those that arise in the oral cavity. Deaths due to oral and oropharyngeal cancer represent approximately 2% of total deaths in men and 1% of total deaths in women. The total number of annual cases of oral cancer in the US is estimated to be 35,000 and annual deaths as high as 9,500. Unfortunately, despite the relative increases in the survival of patients with cancers at other sites, the 5-year survival rate for oral cancer has remained at about 40% for the past several decades.

Risk Factors

The use of tobacco and alcohol are the two most important risk factors for cancer of the mouth. Cigarette smoking is the single most important risk factor for oral cancer; the use of tobacco and alcohol synergistically increase the risk of oral cancer. Although it has been suggested that chewing tobacco (quid, snuff, chew) is a significant cause of oral cancer, epidemiological studies have shown that the risk is small when there are no other concurrent lit-tobacco habits (e.g. cigarettes).¹ By contrast, the use of paan (areca nut and tobacco mixed with spices and soaked in an alkali solution) is significantly associated with the development of oral cancer. Although a number of other factors have been implicated in the development of oral cancer, such as various bacterial and viral infections, for most oral cancers to date, none have been conclusively proven. For cancer of the lip, the single most important risk factor is heavy exposure to ultraviolet rays of the sun (Figure 1).

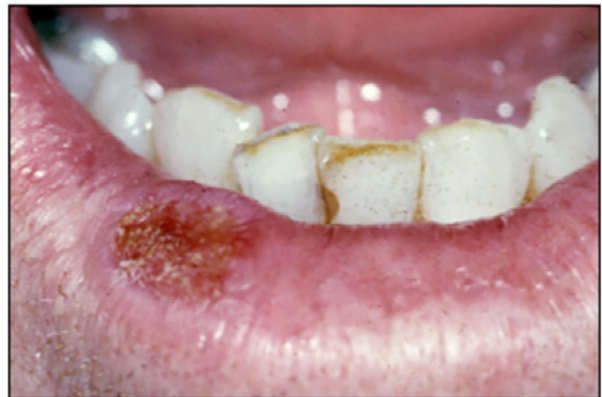

Figure 1. An SCC of the lower lip presenting as an ulcer. Notice the lack of a defined vermillion border and edema consistent with the SCC arising in the setting of actinic (solar) cheilitis.

Causes of Oral Cancer

Two separate lines of research converged to unravel the complex series of events that lead to oral cancer. One area has clearly identified site-specific alterations of oncogenes such as EGFR and tumor suppressor genes such as *p53*. The other is based on epidemiological evidence that linked exposure to exogenous agents to the development of specific forms of cancer. For example, epidemiological studies have strongly

implicated chemical carcinogens, such as those in tobacco with lung and laryngeal cancer. Exposure to ultraviolet (UV) light has been strongly associated with carcinoma of the lower lip. Additionally, evidence was found for the role of specific viruses in cancers such as those arising in hematopoietic and lymphoid tissues, those of the uterine cervix and carcinoma of the oropharynx and nasopharynx.³

1. Chemical carcinogens

Animal studies have shown that the application of certain chemical carcinogens, such as DMBA, to the oral mucosa will induce the formation of squamous cell carcinoma. However, the link between chemical carcinogens that theoretically might be encountered in daily life such as those ingested in drinking water and oral cancer is not known.

2. Tobacco

Cigarette smoking is well established as the most important risk factor in oral cancer. Tobacco smoke contains a large number of chemical carcinogens including aromatic hydrocarbons such as benzopyrene and nitrosamines. These carcinogens have been shown to induce specific genetic changes of the *p53* and *H-ras* genes.

3. Alcohol

All forms of alcohol have been implicated in the development of oral cancer. Importantly, the effects of tobacco and alcohol are additive with alcohol acting synergistically to promote the carcinogenic effects of tobacco products. The mechanism by which alcohol contributes to oral cancer is not well understood but it probably acts directly on the epithelial cells of the oral mucosa by increasing permeability and through its dehydrating effects. In addition, there may also be an indirect effect via altered liver metabolism.⁴ Interestingly, there is some experimental evidence that alcohol might act to alter the *p53* gene directly providing an explanation for the carcinogenicity of alcohol alone.

4. Sunlight

Actinic radiation has long been associated with cancer of the lower lip. Ultraviolet light is a potent DNA damaging agent inducing

DNA cross-linking, single strand and double strand DNA breaks and nucleotide substitution.

5. Viruses

a. Herpes Group

The Herpes group of viruses has been implicated in the development of several cancers in humans for example. Epstein-Barr virus (EBV) has been strongly associated with endemic Burkitt's lymphoma and nasopharyngeal carcinoma. In oral carcinoma, some authors have detected Herpes simplex viral proteins in malignant cells whilst others have shown a co-carcinogenic effect of this virus with other carcinogens in cell culture studies. The precise oncogenic effects of HSV on the pathogenesis of oral cancers however, have not been established.

b. Human Papilloma Virus (HPV)

Over 100 types of human papilloma virus have been identified. The wart (verruca vulgaris) is caused by HPV 2 and 4 and *condylomata accuminata* (genital warts) are caused by HPV 6 and 11. Heck's disease (Focal epithelial hyperplasia) is associated with HPV 13 and 32. Of interest is the finding that HPV, particularly types 16 and type 18 are, associated with most squamous cell carcinomas of the oropharynx (tonsil) and base of the tongue.⁵ Acquisition of high risk HPV16 is linked to sexual activity with a higher risk of cancer in those with a greater number of sexual partners. High risk HPV types (HPV16 and 18) have also been linked to some forms of oral epithelial dysplasia outside of the base of tongue and oropharynx. These are termed "high HPV associated epithelial dysplasia" but the natural history of these lesions is not fully understood.

Clinical Appearance

Carcinoma of the mouth presents in one of four forms (Figures 2, 3, 4):

1. White lesion (leukoplakia)
2. Red lesion (erythroplakia)
3. Red and white lesion (erythroleukoplakia)
4. Non-healing ulcer

Sites of Involvement

Squamous cell carcinoma can arise from the mucosa anywhere in the head and neck. In the mouth the most common site is the tongue followed by the floor of the mouth and then the gingiva (Figure 5).

Diagnosis

It is important to inspect the mouth for the appearance of the lesion, its location and any effect on adjacent tissues. Radiographs may be necessary to establish the tumor effect on the adjacent bone. Although cytology, either by smears or fine needle aspiration (FNA) is commonly used to diagnosis cancer at other sites in the body, its use in oral cancer is limited with exception of the investigation of an enlarged lymph node. If oral cancer is suspected, the most appropriate diagnostic test is a tissue biopsy of the lesion.⁶ In most instances a biopsy of a suspicious lesion can be undertaken using local anesthesia. It is

important that the biopsy is large enough and representative of the lesion. For most lesions it is appropriate to sample the center of the lesion and ensure that it is deep enough to include connective tissue at the base. Placement of the biopsy specimen on a piece of thick paper (connective tissue side down on the paper) helps to support the specimen during fixation, minimize tissue curling and aids orientation for the pathologist.

Treatment

If the pathologist reports the lesion as cancer, then the patient should be referred promptly to a cancer treatment center for assessment and treatment. An important component of the assessment is to establish the stage of the disease. Similar to cancers at other sites in the body, cancer of the mouth is staged using the TMN system where T stands for tumor size, N for the presence or absence of tumor involvement in regional lymph nodes and M for

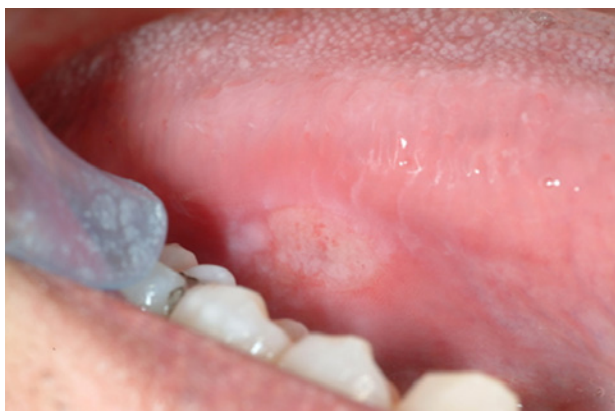

Figure 2. SCC presenting as a small non healing ulcer of the right ventral tongue.

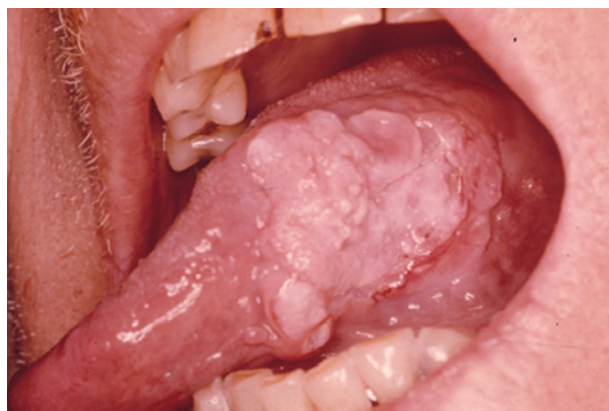

Figure 3. An SCC of the left lateral tongue presenting as a red and white lesion..

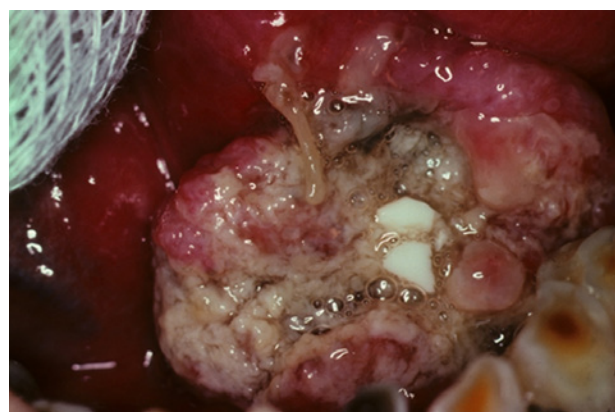


Figure 4. This large ulcerated mass from the floor of the mouth was proven to be an SCC by biopsy.

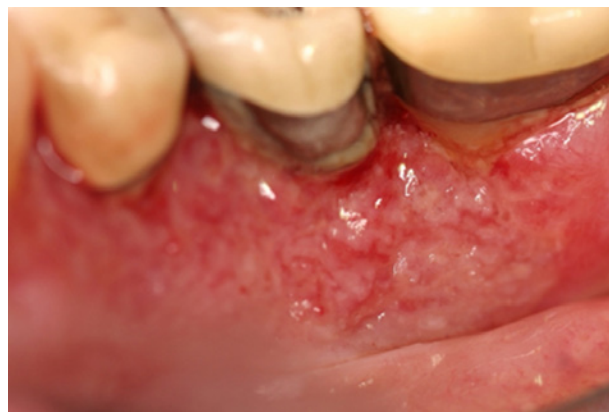

Figure 5. An SCC of the mandibular gingiva presenting as a red/white lesion that is ulcerated.

the presence or absence of distant metastases. Generally, the prognosis is better when the tumor is smaller and has not metastasized to either lymph nodes or other organs. Staging also plays an important role in determining the most appropriate therapy for cancer of the oral cavity. An important exception is that tumors associated with HPV infection have a markedly better survival rate irrespective of stage compared non-HPV related oral cancers.

Cancer of the oral cavity is treated by:

1. Surgery
2. Radiation therapy

Chemotherapy such as cis-platin or carboplatin can be added to either treatment. Adjuvant therapies such the use of antibodies directed against certain cancer associated antigen (e.g. anti-EGFR therapies) and immunotherapies that activate the patient's immune system lymphocytes to target and kill the tumor (so-called check point inhibitors) are increasingly used in many human cancers including those arising in the oral cavity.

For cancers that are restricted to the oral cavity, surgery is generally the preferred treatment modality. Depending on the site, small lesions can be excised and closed primarily. Larger lesions may require more complicated surgical reconstruction using grafting material taken from the arm or the leg. For patients with bulky tumors or for those with tumor in regional lymph nodes, the preferred treatment is

radiotherapy. In these instances, radiation is administered in small daily doses (fractions) of about 2 Grays until a total dose of about 70 Gray has been administered. Radiation therapy has the effect of destroying the salivary glands and reducing the vascularity to the mandible and maxilla. Hence, patients who have had radiation therapy to the head and neck have a life-time risk of developing a form of osteomyelitis, termed osteoradionecrosis of the jaws (Figures 6, 7).

Frequently, osteoradionecrosis is precipitated by dental extractions to an irradiated jaws, therefore, special methods are employed in these individuals when dental extractions are planned.⁷ Usually, any tooth which might be anticipated to need extraction in the future should be extracted prior to radiation therapy. The risk of osteoradionecrosis does not diminish with time after the radiation therapy. Cancer of the lip is usually by surgery alone. Carcinoma of the oropharynx that is associated with HPV responds well to radiation and chemotherapy.

Prognosis

Overall, the five-year survival rate for oral cancer is 40-50%. A general rule of thumb is that the further anterior in the mouth the tumor occurs the better the prognosis. For example, over 90% of patients with cancer of the lower lip can expect a cure. For cancers involving the posterior tongue that are not associated with HPV, the rate can be less than 30%. The presence of tumor in regional lymph nodes further reduces the overall 5-year survival rate by one-half. The continued

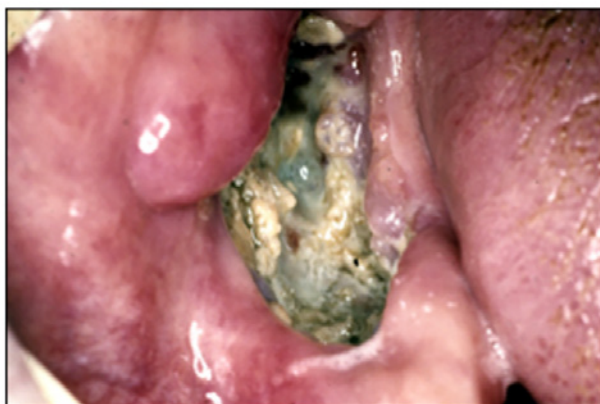

Figure 6. Osteoradionecrosis of the mandible. This patient had received radiation therapy for a tongue SCC in the past.

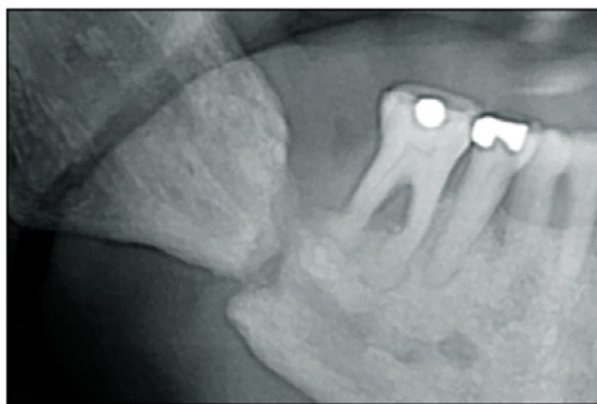


Figure 7. This radiograph shows a pathologic fracture of the right mandible secondary to osteoradionecrosis. The patient had received radiation therapy to the oral cavity in the past for oral cancer.

use of tobacco after treatment for oral cancer increases the risk of recurrence. Patients with HPV associated carcinoma have a higher 5-year survival rate showing excellent response to radiation and chemotherapy provided the patient has a less than 10 pack year history of tobacco use. In addition, all patients who have had cancer of the head and neck have a 5% risk per year of developing another tumor in the head and neck (second primary).

Conclusion

Oral cancer is a common disease mostly associated with tobacco and alcohol use. An emerging form of cancer is that occurring in the base of tongue and oropharynx where the disease is linked to oncogenic HPV infection, typically HPV16. All forms of oral cancer are amenable to detection by dentists and diagnosis by biopsy.

Course Test Preview

To receive Continuing Education credit for this course, you must complete the online test. Please go to: www.dentalcare.com/en-us/ce-courses/ce348/start-test

1. There are several malignancies that occur in the mouth. The most common type is _____.

- A. sarcoma
- B. lymphoma
- C. melanoma
- D. squamous cell carcinoma
- E. basal cell carcinoma

2. The most important risk factor for intra-oral cancer is _____.

- A. alcohol abuse
- B. betel nut
- C. cigarette smoking
- D. chewing tobacco
- E. lack of anti-oxidants

3. _____ is the most important risk factor for cancer of the lip.

- A. Pipe smoking
- B. Cigarette smoking
- C. Sunlight
- D. Alcohol abuse
- E. Herpes simplex infection

4. In relation to oral cancer, the most important role of alcohol is it _____.

- A. acts synergistically with tobacco
- B. interferes with liver enzymes that metabolize carcinogens
- C. results in formation of nitrosamines
- D. plays no role in oral carcinogenesis
- E. acts as a carcinogen

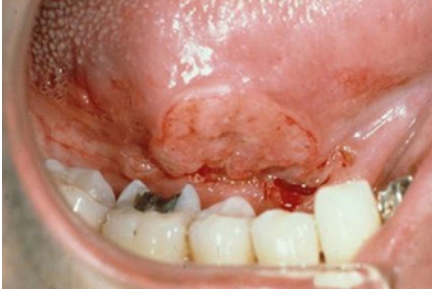5. Epstein-Barr virus is a member of the Herpes group of viruses and is associated with which of the following diseases:

- A. Oral squamous cell carcinoma
- B. Condyloma acuminatum
- C. Nasopharyngeal carcinoma
- D. Heck's disease
- E. Carcinoma of the tonsil

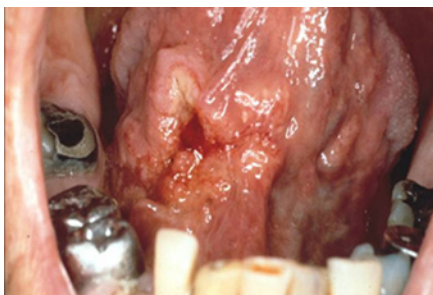
6. Which of the following is NOT associated with Human papillomavirus (HPV)?

- A. not a significant cause of carcinoma of the gingiva
- B. associated with several benign growths in the mouth
- C. associated with carcinoma of the tonsil, oropharynx and base of tongue
- D. the cause of genital warts
- E. the primary cause of nasopharyngeal carcinoma

7. **In almost all cases when a biopsy needs to be taken, the following approach can be used:**
- A. The patient needs to be sedated.
 - B. Can be performed using local anesthesia.
 - C. The patient needs general anesthesia.
 - D. Should not be performed by a general dentist.
8. **Your patient is a 59 year old male patient with a six month duration, painless, hard ulcer on the right lateral border of the tongue. After a medical history and examination, what is your next step?**



- A. Incisional biopsy
 - B. Excisional biopsy
 - C. Refer the patient to his primary care physician for further management
 - D. Smooth the lingual cusps of tooth #30
 - E. Prescribe antibiotics
9. **The most common site for oral cancer is the _____.**
- A. gingiva
 - B. floor of mouth
 - C. tongue
 - D. tonsil
 - E. palate
10. **Your patient is a 65 year old man who smokes who has an ulcer of the right ventral tongue that has been persistently present for 5 months. The differential diagnosis for the ulceration includes all of the following except:**



- A. Squamous cell carcinoma
- B. Deep fungal infection
- C. Chronic "traumatic" ulcer
- D. Recurrent minor aphthous stomatitis (ulceration)

- 11. When a suspicious lesion is identified, the most important diagnostic test is _____.**
- A. cytological examination
 - B. tissue biopsy
 - C. examination under fluorescent light
 - D. toluidine blue staining
 - E. visual examination
- 12. Once a patient is diagnosed with cancer the patient should be _____.**
- A. counseled on smoking cessation practices
 - B. treated in your office
 - C. treated by a community practitioner
 - D. treated by a clinician specialized in the treatment of oral cancer
 - E. None of the above.
- 13. The TNM system for cancer staging refers to _____.**
- A. tumor grade, palpable in lymph nodes and metastases
 - B. tumor size, presence in lymph nodes and metastases
 - C. tumor type, presence in lymph nodes and metastases
 - D. tumor size, palpable lymph nodes and metastases
- 14. For small squamous cell carcinomas localized to the oral cavity (those without spread to the neck), the most common treatment modality is _____.**
- A. surgery
 - B. radiation
 - C. surgery + radiation
 - D. surgery + radiation + chemotherapy
 - E. cryotherapy
- 15. A patient with a squamous cell carcinoma of the floor of the mouth that has spread to the lymph nodes of the neck has an overall 5-year survival rate of approximately _____.**
- A. 100%
 - B. 80%
 - C. 50%
 - D. 25%
 - E. 10%

References

1. Odell E, Kujan O, Warnakulasuriya S, Sloan P. Oral epithelial dysplasia: Recognition, grading and clinical significance. *Oral Dis*. 2021 Nov;27(8):1947-1976. doi: 10.1111/odi.13993. Epub 2021 Sep 14. PMID: 34418233.
2. Boffetta P, Hecht S, Gray N, Gupta P, Straif K. Smokeless tobacco and cancer. *Lancet Oncol*. 2008 Jul;9(7):667-75. doi: 10.1016/S1470-2045(08)70173-6. PMID: 18598931.
3. Lingen MW, Kalmar JR, Karrison T, Speight PM. Critical evaluation of diagnostic aids for the detection of oral cancer. *Oral Oncol*. 2008 Jan;44(1):10-22. doi: 10.1016/j.oraloncology.2007.06.011. Epub 2007 Sep 6. PMID: 17825602; PMCID: PMC2424250.
4. Belcher R, Hayes K, Fedewa S, Chen AY. Current treatment of head and neck squamous cell cancer. *J Surg Oncol*. 2014 Oct;110(5):551-74. doi: 10.1002/jso.23724. Epub 2014 Jul 23. PMID: 25053506.
5. Wong HM. Oral complications and management strategies for patients undergoing cancer therapy. *ScientificWorldJournal*. 2014 Jan 8;2014:581795. doi: 10.1155/2014/581795. PMID: 24511293; PMCID: PMC3910370.
6. Carl W. Oral complications of local and systemic cancer treatment. *Curr Opin Oncol*. 1995 Jul;7(4):320-4.
7. Gillison ML. Human papillomavirus-associated head and neck cancer is a distinct epidemiologic, clinical, and molecular entity. *Semin Oncol*. 2004 Dec;31(6):744-54.

Additional References

- Lerman MA, Almazrooa S, Lindeman N, Hall D, Villa A, Woo SB. HPV-16 in a distinct subset of oral epithelial dysplasia. *Mod Pathol*. 2017 Dec;30(12):1646-1654. doi: 10.1038/modpathol.2017.71. Epub 2017 Aug 11. PMID: 28799537.
- Giraldi L, Collatuzzo G, Hashim D, Franceschi S, Herrero R, Chen C, Schwartz SM, Smith E, Kelsey K, McClean M, Gillison M, Boccia S, Hashibe M, Amy Lee YC, Boffetta P. Infection with Human Papilloma Virus (HPV) and risk of subsites within the oral cancer. *Cancer Epidemiol*. 2021 Dec;75:102020. doi: 10.1016/j.canep.2021.102020. Epub 2021 Sep 9. PMID: 34509873.
- Gillison ML, Chaturvedi AK, Anderson WF, Fakhry C. Epidemiology of Human Papillomavirus-Positive Head and Neck Squamous Cell Carcinoma. *J Clin Oncol*. 2015 Oct 10;33(29):3235-42. doi: 10.1200/JCO.2015.61.6995. Epub 2015 Sep 8. PMID: 26351338; PMCID: PMC4979086.

About the Author



Richard C. Jordan, DDS, PhD, FRCD(C) FRCPath

Dr. Richard Jordan is Professor of Oral Pathology in the Department of Orofacial Sciences School of Dentistry, University of California, San Francisco (UCSF), Professor of Pathology and Professor of Radiation Oncology in the UCSF School of Medicine. He graduated with a DDS degree in 1986 that was followed by specialty training in Pathology, Oral Pathology and Oral Medicine followed by a Master of Science degree in Oral Pathology. All of this was completed at the University of Toronto. He then went on to earn a PhD from the Faculty of Medicine at the University of London (UK) examining early molecular biomarkers of lymphoma development. He was a faculty member at the University of Toronto from 1995 through to 2000 before relocating to UCSF.

Dr. Jordan is currently the Chair of the Division of Oral Medicine, Pathology and Radiology at UCSF. He is the Director of the Oral Pathology section of the UCSF Dermatopathology & Oral Pathology Service, one of the nation's largest and best known diagnostic pathology services in the US. Dr. Jordan's research focus has been oral precancer and cancer where his group has been studying biomarkers of oral cancer development and prognosis. He has authored over 100 research publications, reviews and book chapters. One of his books is the most widely used oral pathology textbook in the world. He has had 30 years of continuous extra-mural funding from several major research funding organizations including the Medical Research Council, National Cancer Institute of Canada and from the National Institutes of Health.

As a pathologist with expertise in the diagnosis of head and neck (H&N)/oral tumors, he is also the Director of the NRG Oncology Biospecimen Banks with biobanking locations in San Francisco, Houston, Pittsburgh and the Nationwide Children's Hospital in Columbus. It is the largest of the 5 NCI funded co-operative cancer groups enrolling patients into late stage phase 2/phase 3 cancer clinical trials. Dr. Jordan has led and contributed to a wide range of scientific investigation from biologically based, mechanistic studies examining the development of oral cancer, lymphoma and salivary gland diseases to epidemiological studies of these and other cancers. He and collaborators established the now widely cited methods to quantify DNA and RNA aberrations in material sourced from paraffin embedded tissues. His specific research interest includes the studying the role of HPV 16 in H&N cancer and the development of more reproducible method to report p16 results for HPV positive H&N cancer.

Email: Richard.Jordan@ucsf.edu