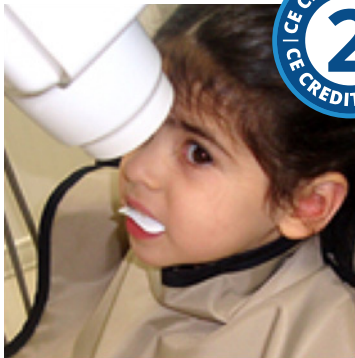

Radiographic Techniques for the Pediatric Patient



Course Author(s):

CE Credits: 2 Hour(s)

Intended Audience: Dentists, Dental Hygienists, Dental Assistants, Dental Students, Dental Hygiene Students, Dental Assistant Students

Date Course Online: 09/15/2004

Last Revision Date: 12/16/2021

Course Expiration Date: 12/15/2024

Cost: Free

Method: Self-instructional

AGD Subject Code(s): 731, 430

Online Course: www.dentalcare.com/en-us/professional-education/ce-courses/ce63

Disclaimers:

- P&G is providing these resource materials to dental professionals. We do not own this content nor are we responsible for any material herein.
- Participants must always be aware of the hazards of using limited knowledge in integrating new techniques or procedures into their practice. Only sound evidence-based dentistry should be used in patient therapy.

Conflict of Interest Disclosure Statement

- Dr. Jayakumar Jayaraman reports no conflicts of interest associated with this course. He has no relevant financial relationships to disclose.
- Dr. Schwartz was a member of the dentalcare.com Advisory Board.

Introduction - Pediatric Radiographic Techniques

The purpose of the Radiographic Techniques for the Pediatric Patient course is to provide information on the guidelines for radiographic exposure with emphasis on the reduction of ionizing radiation and innovative techniques that are helpful in conducting radiographic examinations for the pediatric patient. Furthermore, this topic will provide suggestions for communicating with patients and parents about radiation safety and the importance of radiographs in diagnosis and treatment planning.

Course Contents

- Overview
- Learning Objectives
- The Principles for Proper Radiographic Examination
- Radiographic Techniques and Indications
 - Bitewing Radiographs
 - Periapical/Occlusal Radiographs
 - Panoramic Radiographs
 - Cone Beam Computed Tomography (CBCT)
- Guidelines for Prescribing Radiographs in the Pediatric Patient
- Management Techniques
- Positioning the Radiograph
- Desensitization Techniques
- Conclusion
- Course Test
- References
- About the Author

Overview

Clinicians agree that the foundation of an accurate diagnosis and treatment plan is based on a comprehensive medical and dental history, a thorough clinical examination, and appropriate diagnostic radiographs. Of the three, obtaining diagnostic radiographs in the pediatric dental patient is probably the most difficult to accomplish, not only from a technical standpoint, but because of parental fears and misconceptions.

Learning Objectives

Upon completion of this course, the dental professional should be able to:

- Discuss with patients and parents about radiation safety and the importance of radiographs in diagnosis and treatment planning.
- Understand guidelines for radiographic exposure for young patients with emphasis on reduction of ionizing radiation.
- Use innovative techniques for conducting radiographic examinations for the pediatric patient.

The Principles for Proper Radiographic Examination

Clinicians agree that the foundation of an accurate diagnosis and treatment plan is based on a comprehensive medical and dental history,

a thorough clinical examination, and diagnostic radiographs.¹ Of the three, obtaining diagnostic radiographs in the pediatric dental patient is probably the most difficult to accomplish, not only from a technical standpoint but also because of parental fears and misconceptions.

With the news media reporting daily on the environmental insults experienced by the human body, parents are preoccupied with the effects of diagnostic and treatment procedures on the child's health. Limiting children to the possible deleterious effects of preventive and restorative materials, sterilization protocols, and diagnostic techniques are a concern to parents and dentists.

Parents' resistance to the use of radiographs may be reduced by apprising parents of the need for radiographs to derive an accurate diagnosis, as well as educating them of the newer concepts and techniques for acquiring radiographs. At the time the parent schedules the first appointment, information should be offered explaining that for the dentist to perform a thorough dental examination and derive a correct assessment of a child's dental health, there may be a need for radiographs. Also, when parents and the dentist look at the teeth in a child's mouth, all that is seen is literally the tip of the iceberg. Visual examination reveals only three of the five surfaces of the teeth. In the absence normal physiological spacing, the interproximal surfaces cannot be visualized. The roots of the teeth anchored into the bone cannot be seen, nor the inside of the teeth, or the permanent teeth developing in the jawbone.

Parents should be informed radiographs enable the dentist to detect the start of visually undetectable cavities between teeth, infections of the teeth, gums and bones, the shape of unerupted permanent teeth, missing permanent teeth, future orthodontic problems, cysts, tumors, and a host of other pathological conditions.¹

Parents should be made aware that although excessive radiation exposure can result in cancer, birth defects, and genetic defects, the amount of radiation emitted by the newer x-ray units and the increased sensitivity of the x-ray film used by dentist has significantly reduced the amount of radiation to which patients are exposed. The

newest technique for x-ray exposure, digital radiography, reduces the amount of exposure to a bare minimum.

Along with the above explanation and use of the proper equipment, the dentist should follow guidelines as recommended by a panel comprised of representatives from the Academy of General Dentistry, American Academy of Dental Radiology, American Academy of Oral Medicine, American Academy of Pediatric Dentistry, American Academy of Periodontology, and the American Dental Association.^{2,3}

- X-rays should not be taken routinely. A dentist or hygienist should first examine children's teeth before deciding on the number and types of radiographs. The number and types of radiographs necessary is dependent on the age of the child, the presence of decay that can/cannot be detected visually, the child's and family's history of dental treatment, and spaces between teeth.
- If possible, obtain any prior radiographs (from another office, if available).
- Use only those views needed to complete the diagnostic task.
- The patient should be protected with a lead apron and thyroid collar to reduce body exposure to radiation.
- Follow recommendations to reduce radiation as low as reasonably achievable (ALARA).
- Use the fastest image receptor available.
 - Intraoral: changing from D to F speed film or to digital image receptors reduces dose by factors of at least 2.
 - Extraoral: high speed (400 or greater) rare earth screen film systems or digital imaging systems or equivalent.
- Rectangular collimation: reduces radiation dose by factor of 4 to 5 without adverse influence on image quality.
- Beam receptor alignment devices (e.g., XCP) for routine periapical radiography (only marginally effective for bitewing radiographs).
- Use 70 kvp or higher intraoral radiograph techniques.
- Use leaded apron with thyroid collar whenever possible.

- For conventional radiographs:
 - The highest speed and largest size film the child can tolerate should be used to reduce the number of x-rays needed to obtain the necessary information.
 - Use the proper time and temperature for processing as recommended by manufacturers.
 - Review in an environment free from distraction.
 - Reduce room illumination to level of displayed images.
 - Eliminate glare.
 - Use magnification.
 - Use opaque mount.
 - View with variable illumination.
- For digital radiographs:
 - Use software that permits adjustments of contrast, brightness and negative-positive viewing.²

Parents may have the right to insist the dentist refrain from taking x-rays. However, if the dentist is of the opinion not taking the x-ray compromises the patient's treatment, he has the right to refuse to treat the child. Parents cannot offer to release the dentist from liability from subsequent damages that a radiograph might have prevented.

Radiographic Techniques and Indications

Bitewing Radiographs

Bitewing radiographs are indicated primarily to detect or monitor interproximal caries if the proximal surfaces of the teeth cannot be visually or tactilely examined.⁴ Occlusal caries, crestal alveolar bone level and secondarily for eruption patterns, caries and restoration proximity to pulp spaces, primary molar furcation pathology and developmental anomalies may also be detected with bitewing radiographs. The frequency of bitewing radiographic examination is based on caries risk assessment. As the risk status may change over time, the radiographic recall interval may change. A patient with a high caries risk assessment will require bitewing radiographs more frequently (every 6 months) than a patient with a low caries risk assessment (12-24 months). Orientation of the film packet may be vertically or horizontally positioned.

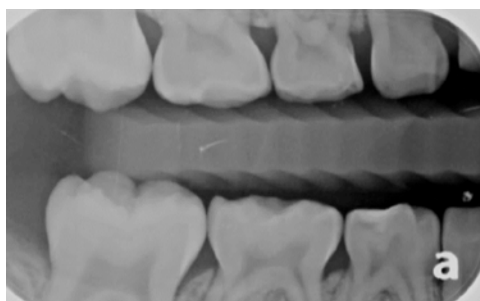

Figure 1.

Placement of the film packet reveals the coronal halves of the maxillary and mandibular teeth, interproximal contacts, and portions of the interdental septa, beginning at distal of the canine and proceeding posteriorly to the mesial half of the last erupted molar (Figures 1,2). One to two films may be necessary depending on the tooth and jaw size.

Periapical/Occlusal Radiographs

Periapical/occlusal radiographs are indicated for identifying or confirming pathology, evaluating dental development, dento-alveolar trauma, deep carious lesions, periapical pathology, and oral involvement of systemic disease.

Occlusal radiographs are also indicated as a supplement for an unsatisfactory panoramic radiograph due to an abnormal incisor relationship, localizing tooth position, assessing the position of supernumerary teeth, pathological lesions, and traumatic injury to bone. They are taken in the primary dentition to detect extension of caries in maxillary and mandibular anterior teeth (Figure 3). Various aids may be used to position radiographs (hemostats, Snap-a-Ray®, XCP).

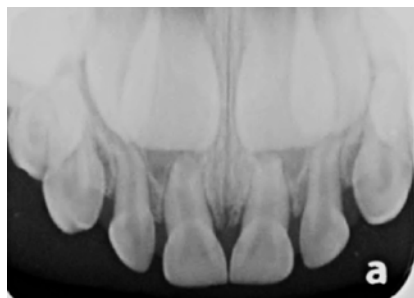


Figure 3.

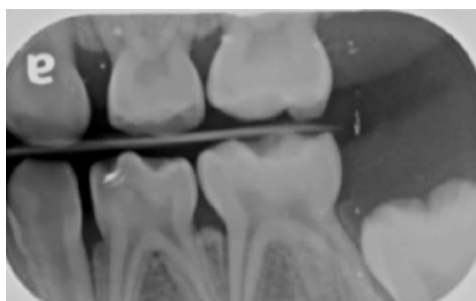


Figure 2.

Panoramic Radiographs

Extra-oral images like panoramic radiographs provide information on several structures in the head and neck region including maxillary sinus, cervical vertebra, and most importantly, teeth and surrounding structures in the maxilla and mandible. It is used to assess development of permanent teeth, stage of eruption, and to identify dental anomalies including hypodontia, hyperdontia, any bony pathologies etc. Panoramic radiographs are indicated in the late mixed dentition stage to assess the eruption pattern of permanent canines, and in permanent dentition to evaluate the position of third molars (Figure 4).

Cone Beam Computed Tomography (CBCT)

The use of CBCT is valuable adjunct in assessing and diagnosing pathology in endodontics, oral pathology, anomalies of the developing dentition like impacted, ectopic, supernumerary teeth, and oral maxillofacial surgery, for example, cleft palate, dental and facial trauma, orthognathic surgery and orthodontics (Figure 5).⁷

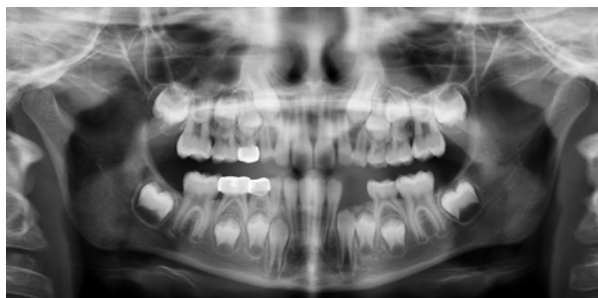

Figure 4.

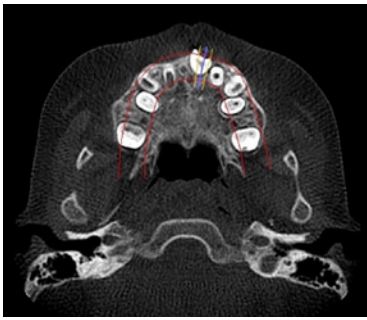

Figure 5.

A CBCT scanner uses a collimated radiation source producing a cone or pyramid shaped beam of radiation in a single, full, or partial revolution around the patient. Two dimensional images are reconstructed into three dimensional images which can be viewed in a variety of ways, including cross-sectional images and volume renderings of the oral cavity.

Although CBCT units produce higher radiation doses than from a single traditional dental radiograph, the radiation dose is delivered is typically less than that produced during a medical computed tomographic scan.

The International Commission on Radiological Protection (ICRP) has updated the methodology of determining effective dose based on the tissue weighting factors.⁸

Table 2 compares estimated radiation doses for common dental radiographs and CBCT imaging.^{9,10}

The use of CBCT should be considered when conventional radiographs are inadequate to complete diagnosis and treatment planning and potential benefits outweigh the risk of additional radiation dose. It is not to be used routinely for diagnosis or screening purposes in the absence of clinical indication. Basic guidelines for the use of CBCT include:

- Use of appropriate image size or field of view
- Assessment of the radiation dose risk
- Minimizing patient radiation exposure
- Professional competency in performing and interpreting CBCT images

A written report of the imaging and full interpretation of the findings is required to be placed in the patient's chart.¹¹

Table 2. Radiation doses for common dental radiographs

Imaging Technique	Estimated Dose (microsieverts)
Conventional radiography	
Four posterior bitewings with phosphor plates or F speed film	5.0
Panoramic radiograph	24.3
Cephalometric radiograph lateral	5.6
Full mouth radiographs	34.9
<ul style="list-style-type: none"> • With phosphor plates or F speed film, rectangular collimation • With phosphor plates or F speed film, round collimation 	170.7
CBCT*	
Dento-alveolar CBCT (small field of view)	103
Maxillo-facial CBCT (medium or large field of view)	175

Table 1. Guidelines for Prescribing Radiographs in the Pediatric Patient.^{2,3}

Type of Encounter	Child		Adolescent
	Primary Dentition <i>(prior to eruption of first permanent tooth)</i>	Transitional Dentition <i>(after eruption of first permanent tooth)</i>	Permanent Dentition <i>(prior to eruption of third molars)</i>
New Patient			
New patient* being evaluated for oral diseases.	Individualized radiographic exam consisting of selected periapical/occlusal views and/or posterior bitewings if proximal surfaces cannot be visualized or probed. Patients without evidence of disease and with open proximal contacts may not require a radiographic exam at this time.	Individualized radiographic exam consisting of posterior bitewings with panoramic exam or posterior bitewings and selected periapical images.	Individualized radiographic exam consisting of posterior bitewings with panoramic exam or posterior bitewings and selected periapical images. A full mouth intraoral radiographic exam is preferred when the patient has clinical evidence of generalized dental disease or a history of extensive dental treatment.
Recall Patient			
Recall patient* with clinical caries or increased risk for caries.**	Posterior bitewing examination at 6-12 month intervals if proximal surfaces cannot be examined visually or with a probe.		Posterior bitewing examination at 6-18 month intervals.
Recall patient* with no clinical caries or increased risk for caries.**	Posterior bitewing examination at 12-24 month intervals if proximal surfaces cannot be examined visually or with a probe.		Posterior bitewing examination at 18-36 month intervals.
Patient (New and Recall) for monitoring of dentofacial growth and development, and/or assessment of dental/skeletal relationships.	Clinical judgment as to need for and type of radiographic images for evaluation and/or monitoring of dentofacial growth and development, or assessment of dental and skeletal relationships.		Clinical judgment as to need for and type of radiographic images for evaluation and/or monitoring of dentofacial growth and development, or assessment of dental and skeletal relationships. Panoramic or periapical exam to assess developing third molars.
Patient with other circumstances including but not limited to, proposed or existing implants, pathology, restorative/endodontic needs, treatment periodontal disease and caries remineralization.	Clinical judgment as to need for and type of radiographic images for evaluation and/or monitoring in these conditions.		

Table 1. Guidelines for Prescribing Radiographs in the Pediatric Patient.^{2,3} (continued)

*** Clinical situations for which radiographs may be indicated include but are not limited to:**

A. Positive Historical Findings

1. Previous periodontal or endodontic treatment
2. History of pain or trauma
3. Familial history of dental anomalies
4. Postoperative evaluation of healing
5. Remineralization monitoring
6. Presence of implants or evaluation for implant placement

B. Positive Clinical Signs/Symptoms

1. Clinical evidence of periodontal disease
2. Large or deep restorations
3. Deep carious lesions
4. Malposed or clinically impacted teeth
5. Swelling
6. Evidence of dental/facial trauma
7. Mobility of teeth
8. Sinus tract ("fistula")
9. Clinically suspected sinus pathology
10. Growth abnormalities
11. Oral involvement in known or suspected systemic disease
12. Positive neurologic findings in the head and neck
13. Evidence of foreign objects
14. Pain and/or dysfunction of the temporomandibular joint
15. Facial asymmetry
16. Abutment teeth for fixed or removable partial prosthesis
17. Unexplained bleeding
18. Unexplained sensitivity of teeth
19. Unusual eruption, spacing or migration of teeth
20. Unusual tooth morphology, calcification or color
21. Unexplained absence of teeth
22. Clinical erosion
23. Peri-implantitis

**** Factors increasing risk for caries may be assessed using the ADA Caries Risk Assessment forms (0–6 years of age⁵ and over 6 years of age⁶).**

Management Techniques

One of the most challenging tasks for the clinical staff is to obtain diagnostic quality radiographs on a young patient, (particularly those under three years of age) without causing psychological trauma. Radiographs are rarely taken for infants, for example, eruption cyst associated with natal or neonatal teeth. In such situations, the infant is held comfortably by the parent seated in the dental chair (Figure 6).

For toddlers, it is preferred to desensitize the child to the dental experience by explaining to the child what you plan to do in words easily comprehended by the child. Using a “tell, show, do” technique, the clinician explains to the child a tooth picture will be taken of the child’s tooth with tooth film and a tooth camera. The child is allowed to touch and examine the radiographic film and camera. The child is positioned to gain maximum cooperation. In the child less than three years of age it may be necessary for the child to sit in the parent’s lap while the radiograph is exposed (Figure 7).

Such positioning reduces the child’s anxiety to such a degree that minimal restraint may be needed to successfully take the radiograph. The child is seated in the parent’s lap with the parent resting their arms around the child’s upper body and their legs wrapped around the child’s lower body. Not only does this provide additional emotional security for the child and, thus, increased cooperation but also enables the parent to adequately restrain the child should there be any unexpected sudden movements.

A positioning device such as a Snap-A-Ray can be used to aid the parent in positioning and securing the film (Figure 8). Be sure to adequately protect the parent and child with lead aprons to reduce radiation exposure. Obtaining the least difficult radiograph first (such as an anterior occlusal) desensitizes the child to the procedure (Figure 9). Since many children have difficulty keeping the film in their mouth for extended periods of time, be certain the correct settings are made on the apparatus and the x-ray head is properly positioned before placing the film in the child’s mouth. Once the child feels acclimatized with the setting, additional radiographs including

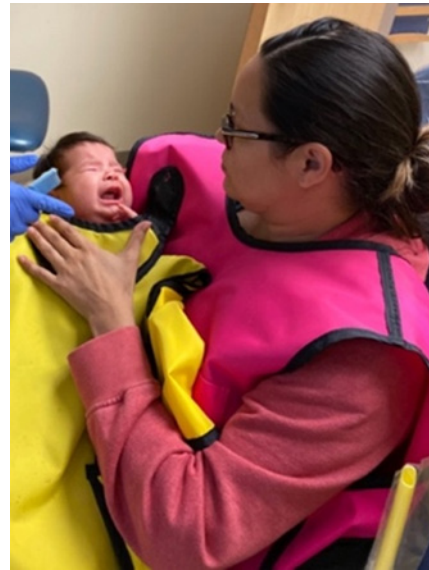

Figure 6.

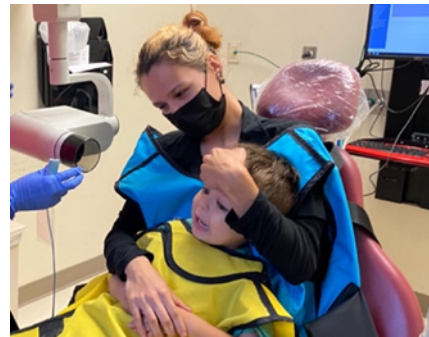

Figure 7.

left bitewing (Figure 10) and right bitewing can be obtained (Figure 11).

If the child is uncooperative, then additional restraint by a second adult may be necessary to successfully obtain the radiograph. With the first adult restraining the child as described previously, a second adult stabilizes the child’s head with one hand while the other hand positions the x-ray holder in the patient’s mouth. Under no circumstances should staff be asked to perform this task.

If a second adult is not available, it may be necessary to place the child in a mechanical restraining device (Papoose Board) to adequately restrain the child (Figure 12). This frees the parent to stabilize the child’s head and properly position the radiograph in the child’s mouth. This approach is particularly




Figure 8.

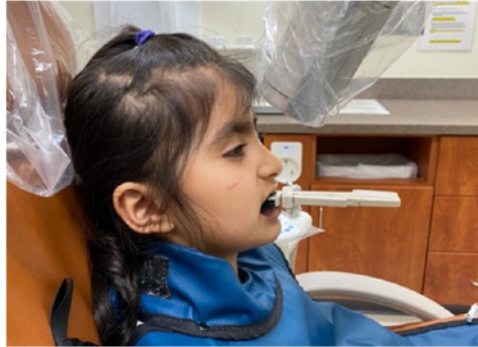

Figure 9.

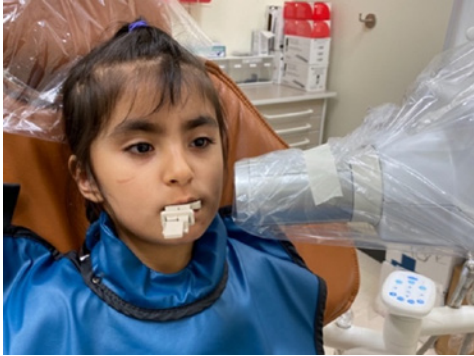

Figure 10.

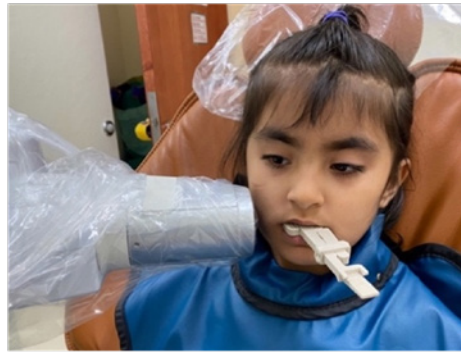

Figure 11.

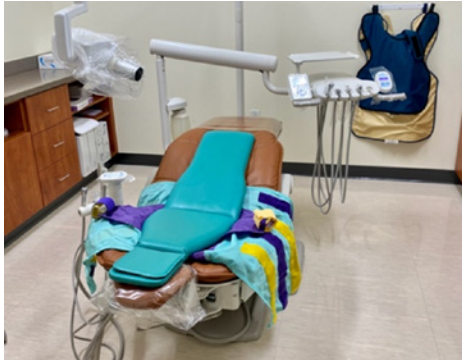

Figure 12.



Figure 13.




Figure 14.

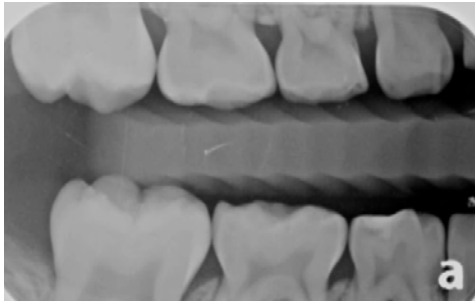


Figure 15.

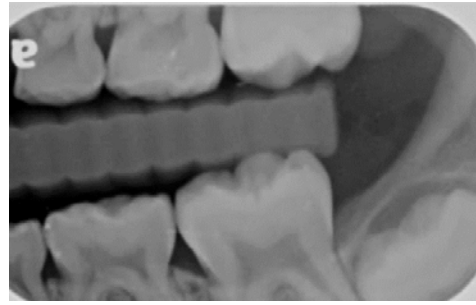


Figure 16.



Figure 17.

useful on an uncooperative child in emergency conditions like dental injury or facial abscess following dental infection. In such situations, diagnostic radiograph could be followed by treatment rendered whilst the child is still seated in the restraining device. This would potentially avoid placing child repeatedly in the restraining device.

If the child is still too uncooperative, it may be necessary to manage the child pharmacologically with inhalation, oral, or parental sedatives. Older children may also be uncooperative for a variety of reasons. These can range from the jaw being too small to adequately accommodate the radiograph, fear of swallowing the radiograph, fear of the procedure itself, or the patient exhibits a severe gag reflex. There are numerous techniques to overcome these problems. For the child with the small mouth, use the smallest size film available which is size 0 film followed by size 1 and size 2 films (Figure 13). Sometimes, rolling the film to avoid sharp bends can allow the film to accommodate the shape of the jaw and not impinge on the soft tissues (Figure 14).

Use of the Snap-A-Ray as a bitewing tab will reduce impingement on the soft tissue but unfortunately will reduce the amount of detectable tooth structure on the radiographs (Figure 15, 16).

This approach is particularly useful when conventional films are used which is relatively thinner compared to bulkier digital sensors (Figure 17).

Positioning the Radiograph

Positioning the radiograph vertically in the mouth for both periapical and bitewing radiographs reduces the distal extension of the radiograph and may result in greater tolerance by patients, especially those with a mild gag reflex. The vertical bitewing radiograph provides greater detail of the periapical area. A self-sticking sponge tab may also reduce impingement of the radiograph on the intraoral soft tissue.

Desensitization Techniques

Desensitization is defined as gradually exposing the child to new stimuli or experiences of

increasing intensity. An example of this is introducing the patient to x-rays by initially taking an anterior radiograph, which is easier to tolerate than a posterior radiograph.

Some patients, young and old, have an exaggerated gag reflex. The etiology of an exaggerated gag reflex had been attributed to psychological and physical factors. There are numerous techniques to control the gag reflex during the radiograph procedure. The easiest is through diversion and positive suggestion. The operator suggests to the patient the gag reflex can be reduced by concentrating on something other than the procedure (Figure 18). The patient can look at a mirror, count fingers, raise and lower legs on a count, or employ audio-video distraction. However, this technique is not always successful so other techniques must be brought into play.

An alternative is the use of nitrous oxide analgesia. One of the effects of nitrous oxide analgesia is it reduces the gag reflex, but unlike general anesthesia it does not affect the cough reflex. Another alternative is to place the radiograph in such a manner to not contact the palate or tongue. This is accomplished by either extraoral placement of the film or placing the film between the cheek and the tooth and exposing the film from the opposite jaw. In the reverse radiograph the film is placed on the buccal surface of the tooth between the tooth and the cheek. The film side of the packet (the solid color side) is facing the buccal surface of the tooth.

The x-ray head is placed at the opposing side, and the cone is positioned under the angle of the ramus on the opposite side. The radiation is directed through the tongue, through the tooth structure, and onto the film. As the x-ray beam is traveling a longer distance to the film than in the typical positioning, it is necessary to double the exposure time. The prevalence of dental trauma in children is estimated at around 18%. Following trauma resulting in tooth fracture and concurrent lip laceration, it is always important to obtain a radiograph of the soft tissue to rule out any impregnation of tooth fragments inside the soft tissue. For this purpose, the exposure

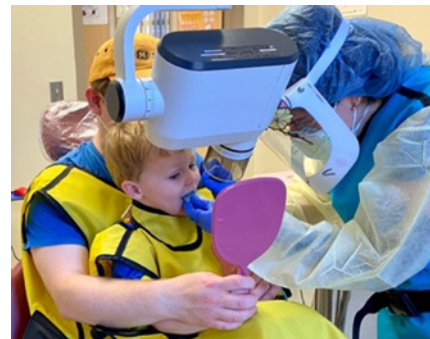

Figure 18.

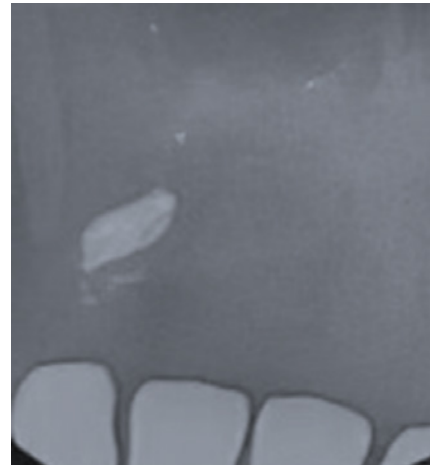


Figure 19.

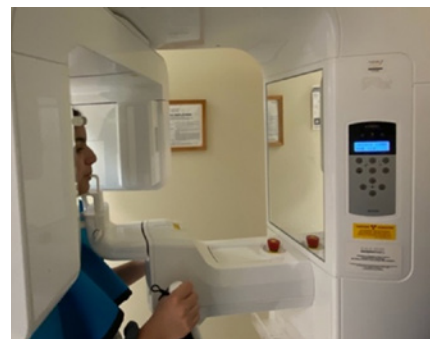

Figure 20.

time is reduced to one fourth of the original exposure (Figure 19).

Some of the newer digital panoramic radiographic units, i.e., Planmeca Promax, Sirona Panorex have programs that can take bitewing radiographs through extraoral techniques. This has shown to have better

patient compliance, easy patient positioning, and faster appointments using less radiation than conventional radiographs yet providing images of diagnostic quality (Figure 20).

Conclusion

Radiographs serve as an excellent tool in the diagnosis and treatment planning of various dental conditions in children. Several modified radiographic techniques are available for the dentist and staff to obtain good quality radiographs. The goal is to eliminate unnecessary repeated radiographic exposure and provide maximum comfort for the pediatric patient.

Course Test Preview

To receive Continuing Education credit for this course, you must complete the online test. Please go to: www.dentalcare.com/en-us/professional-education/ce-courses/ce63/start-test

- 1. If the foundation of an accurate diagnosis and treatment plan are a comprehensive medical and dental history, a thorough clinical examination, and diagnostic radiographs, the most difficult to obtain is _____.**
 - A. a comprehensive medical and dental history
 - B. a thorough clinical examination
 - C. diagnostic radiographs
 - D. They all exhibit the same difficulty.
- 2. A parent's resistance to the use of radiographs may be reduced by _____.**
 - A. apprising parents of the need for radiographs to derive an accurate diagnosis
 - B. educating parents of the newer philosophies and techniques for acquiring radiographs
 - C. insurance companies not paying benefits without them
 - D. A and B
- 3. Radiographs are necessary because _____.**
 - A. visual examination reveals only three of the five surfaces of the teeth
 - B. if the child's teeth are close together you cannot see the interproximal areas
 - C. the insides of neither the teeth nor the permanent teeth developing in the jawbone can be seen
 - D. All of the above.
- 4. According to guidelines issued by various dental associations, _____.**
 - A. radiographs should be taken routinely every 6 months
 - B. children's teeth should be first examined by a dentist or hygienist before deciding on the number and types of radiographs
 - C. every patient should have a full mouth series of radiographs at the initial visit
 - D. the dentist should not rely on radiographs from another office even if they are recent
- 5. If a parent refuses to have their child undergo radiographic examination, _____.**
 - A. the dentist may refuse to treat the child if the child's treatment may be compromised by not taking radiographs
 - B. the parent may offer to release the dentist from liability from subsequent damages that a radiograph might have prevented
 - C. the dentist should treat only the problems that are visual
 - D. the dentist should treat all suspicious areas
- 6. For a new patient in the primary dentition, the prescription of radiographs should be limited to _____.**
 - A. individualized radiographic examination consisting of periapical/occlusal views and posterior bitewings or panoramic examination and posterior bitewings
 - B. posterior bitewings, at the minimum, in all situations
 - C. individualized radiographs consisting of posterior bitewings and selected periapicals and a full mouth radiographic examination
 - D. None of the above.

7. **For a new patient in the transitional dentition, the prescription of radiographs for assessment of dental disease should be limited to _____.**
- A. posterior bitewing examination, if proximal surfaces of primary teeth cannot be visualized or probed
 - B. individualized radiographic exam consisting of posterior bitewings with panoramic exam or posterior bitewings and selected periapical images
 - C. individualized radiographs consisting of posterior bitewings and selected periapicals and a full mouth radiographic examination
 - D. None of the above.
8. **For a new adolescent patient with a permanent dentition prior to eruption of third molars, the prescription of radiographs for the assessment of dental disease should be limited to _____.**
- A. individualized radiographic exam consisting of panoramic radiograph.
 - B. individualized radiographic exam consisting of posterior bitewings.
 - C. individualized radiographic exam consisting of posterior bitewings with panoramic exam or posterior bitewings and selected periapical images.
 - D. individualized radiographic exam consisting of periapical images.
9. **For a recall patient in the primary dentition exhibiting clinical caries or high risk factors for caries, the prescription of radiographs should be limited to _____.**
- A. posterior bitewing examination at 6-12 month intervals if proximal surfaces cannot be examined visually or with a probe
 - B. posterior bitewing examination at 12 month intervals or until no carious lesions are present
 - C. posterior bitewing examination at 18 month intervals
 - D. posterior bitewing examination at 24 month intervals
10. **For a recall patient in the transitional dentition exhibiting clinical caries or high risk factors, the prescription of radiographs should be limited to _____.**
- A. posterior bitewing examination at 6-12 month intervals if proximal surfaces cannot be examined visually or with a probe
 - B. posterior bitewing examination at 12 month intervals or until no carious lesions are present
 - C. posterior bitewing examination at 18 month intervals
 - D. posterior bitewing examination at 24 month intervals
11. **For a recall patient in the primary dentition exhibiting no clinical caries or no risk factors for caries, the prescription of radiographs should be limited to _____.**
- A. posterior bitewing examination at 6 month intervals
 - B. posterior bitewing examination at 12-24 month intervals if proximal surfaces cannot be examined visually or with a probe
 - C. No radiographs should be taken.
 - D. None of the above.
12. **For a recall patient in the transitional dentition exhibiting no clinical caries or no risk factors for caries, the prescription of radiographs should be limited to _____.**
- A. posterior bitewing examination at 6 month intervals
 - B. posterior bitewing examination at 12-24 month intervals if proximal surfaces cannot be examined visually or with a probe
 - C. posterior bitewing examination at 18-36 month intervals
 - D. No radiographs should be taken.

- 13. For a recall patient in the permanent dentition exhibiting no clinical caries or no risk factors for caries, the prescription of radiographs should be limited to _____.**
- A. posterior bitewing examination at 6 month intervals
 - B. posterior bitewing examination at 12-24 month intervals
 - C. posterior bitewing examination at 18-36 month intervals
 - D. No radiographs should be taken.
- 14. All of the following are true of CBCT, EXCEPT one. Which one is the exception?**
- A. The median exposure dose of radiation is greater than four posterior bitewing radiographs.
 - B. The median exposure dose of radiation is greater than a panoramic radiograph.
 - C. The median exposure dose of radiation is greater than a cephalometric radiograph.
 - D. The median exposure dose of radiation is less than a cephalometric radiograph.
- 15. If a patient is uncooperative, which of the following is NOT performed?**
- A. The parent restrains the child while seated in his/her lap.
 - B. The parent restrains the child's body while a friend or family member restrains the child's head and stabilizes the radiograph.
 - C. The parent restrains the child's body while a staff member restrains the child's head and stabilizes the radiograph.
 - D. The child is restrained in a mechanical restraining device and the parent stabilizes the radiograph.
- 16. Which of the following is effective in reducing hyper gag reflex problems in children while taking radiographs?**
- A. Place the radiograph in a vertical position.
 - B. Allow the child to watch in a mirror.
 - C. Administer nitrous oxide during radiographic exposure.
 - D. All of the above.
- 17. Starting with an anterior radiograph is an example of _____.**
- A. desensitization
 - B. bribery
 - C. reward
 - D. punishment
- 18. In the "Reverse Radiograph Technique" the exposure time is _____.**
- A. the same
 - B. halved
 - C. doubled
 - D. tripled
- 19. Following trauma, to diagnose any tooth fragment impregnated into the soft tissue, the exposure time is _____.**
- A. the same
 - B. one fourth
 - C. doubled
 - D. tripled

References

1. Jayaraman J, Hoikka A, Cervantes MJ, Hajishengallis E. Radiographic Diagnosis in the Pediatric Dental Patient. *Dental Clinics of North America*. 2021; 65: 643-667.
2. American Dental Association. Accessed November 30, 2021.
3. American Academy of Pediatric Dentistry. Accessed November 30, 2021.
4. Kamburoglu K, Kolsuz E, Murat S, Yüksel S, Ozen T. Proximal caries detection accuracy using intraoral bitewing radiography, extraoral bitewing radiography and panoramic radiography. *Dentomaxillofacial Radiology*. 2012; 41: 450-9.
5. American Dental Association. Caries risk form (Ages 0-6 years). Accessed November 30, 2021.
6. American Dental Association. Caries risk form (Over 6 years). Accessed November 30, 2021.
7. Nowak AJ, Casamassimo PS, American Academy of Pediatric Dentistry. *The handbook of pediatric dentistry*, 4th ed. Chicago, Academy of Pediatric Dentistry, 2011; 75-82.
8. International Commission on Radiological Protection. The 2007 recommendations of the International Commission on Radiological Protection. ICRP publication 103. *Ann ICRP*2007; 37: 1-332.
9. Ludlow JB, Davies-Ludlow LE, White SC. Patient risk related to common dental radiographic examinations: the impact of 2007 International Commission on Radiological Protection recommendations regarding dose calculation. *Journal of American Dental Association*. 2008; 139: 1237-43.
10. Ludlow JB, Timothy R, Walker C, Hunter R, Benavides E, Samuelson DB, Scheske MJ. Effective dose of dental CBCT-a meta analysis of published data and additional data for nine CBCT units. *Dentomaxillofacial Radiology*. 2015; 44: 20140197
11. American Dental Association Council on Scientific Affairs. The use of cone-beam computed tomography in dentistry: an advisory statement from the American Dental Association Council on Scientific Affairs. *Journal of American Dental Association*. 2012; 143: 899-902.

About the Authors

Jayakumar Jayaraman, BDS, MDS, FDSRCS, MS, PhD



Dr. Jayaraman is a Pediatric Dentist with clinical and research training from India, Hong Kong, England and the United States. He obtained master's degrees in Pediatric Dentistry from the University of Hong Kong and the University of Texas Health San Antonio. Dr. Jayaraman also received his Diploma in Pediatric Dentistry and Fellowship at the Royal College of Surgeons of Edinburgh, United Kingdom where he also serves as an Examiner. For the past 10 years he has taught Pediatric Dentistry and supervised research projects for pre-doctoral, post-doctoral and PhD students in different countries. His research involves topics in Evidence-Based Dentistry, Forensic Dentistry, Human Biology & Anthropology. Dr. Jayaraman has published over 50 peer-reviewed scientific articles and reviewed articles for several leading pediatric, forensic, and multi-disciplinary journals. He serves as an Associate Editor for the *Frontiers in Dental Medicine Journal* and an Editorial Board Member of the *International Journal of Pediatric Dentistry*. Dr. Jayaraman is currently Associate Professor of Pediatric Dentistry at Virginia Commonwealth University, Richmond.

Email: jayakumar83@hotmail.com

Steven Schwartz, DDS



The P&G team wishes to express its sadness over the loss of our colleague and friend, Dr. Steven Schwartz, who passed away on October 25, 2018. He was a tremendous help on impacting thousands of dental professionals through CE, making dentalcare.com one of the best CE providers in the world. He was a wonderful person! We will miss him.

Dr. Steven Schwartz was the former director of the Pediatric Dental Residency Program at Staten Island University Hospital and was a Diplomate of the American Board of Pediatric Dentistry.

Email: N/A