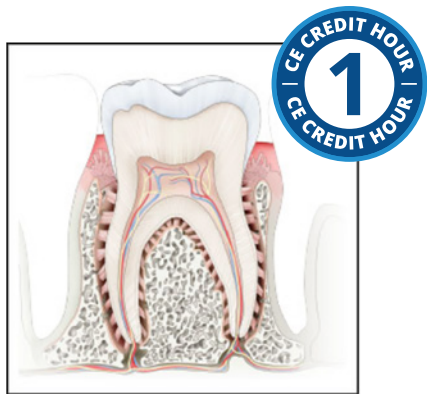

An Overview of Dental Anatomy



Course Author(s): Vickie Parrish Foster, RDH, MEd
CE Credits: 1 hour
Intended Audience: Dental Hygienists, Dental Assistants, Dental Hygiene Students, Dental Assistant Students
Date Course Online: 03/16/2016
Last Revision Date: 03/13/2025
Course Expiration Date: 03/12/2028
Cost: Free
Method: Self-instructional
AGD Subject Code(s): 10

Online Course: www.dentalcare.com/en-us/ce-courses/ce500

Disclaimer: Participants must always be aware of the hazards of using limited knowledge in integrating new techniques or procedures into their practice. Only sound evidence-based dentistry should be used in patient therapy.

Conflict of Interest Disclosure Statement

- The author reports no conflicts of interest associated with this course.

Introduction - Dental Anatomy

An Overview of Dental Anatomy will provide an overview of dental anatomy, including the primary and permanent dentitions, normal facial and intraoral anatomy and the anatomy of the periodontium. This information can be used as a review in order to compare findings outside of the normal.

Course Contents

- Overview
- Learning Objectives
- Glossary
- Normal Anatomic Landmarks of the Head Neck and Oral Cavity
 - Bone Structure of the Face
 - Facial Landmarks
 - Landmarks in the Oral Cavity
- Teeth in the Oral Cavity
 - Types of Teeth, Structures, Location and Functions
 - Divisions and Components of the Teeth
 - Types of Teeth and their Functions
 - Surfaces of the Teeth
- Dentitions
 - Primary Dentition
 - Permanent Dentition
- Occlusion
- Anatomy of the Periodontium
- Conclusion
- Course Test
- References
- About the Author

Overview

This course will provide an overview of dental anatomy, including the primary and permanent dentitions, normal facial and intraoral anatomy and the anatomy of the periodontium. This information can be used as a review in order to compare findings outside of the normal.

The oral cavity and its surrounding and supporting structures not only affect our digestive processes, but also affect our speech and appearance. In order to identify problems in the oral cavity, the dental professional must first recognize normal anatomy as well as the normal appearance of the surrounding areas. In addition, it is essential the dental professional be able to evaluate the health of the teeth as well as the supporting tissues and periodontium. Even if they are not the one responsible for diagnosis, all dental professionals should be able to recognize deviations from normal in order to determine the need for further investigation.

Learning Objectives

Upon completion of this course, the dental professional should be able to:

- Recognize and describe the normal anatomical structures of the oral cavity and the head and neck.
- Recite the name, Universal number and function of each type of tooth, both primary and permanent.
- Differentiate between the tissues of the teeth.
- List where each type of tooth is located in the mouth.
- Explain the types of occlusion and the significance of each.
- Identify the components of the periodontium and the importance of each.

Glossary

anterior – Forward, toward the front of the mouth and the midline.

apical – Toward the root of the tooth; apex of the tooth.

bifurcated – Single tooth with two roots.

buccal – The surface that is facing the cheeks in the back of the mouth.

cementum – The tissue covering the root of the tooth.

cementoenamel junction (CEJ) – The line where the enamel and the cementum of the tooth join.

cingulum – A small bump near the cervical third of an anterior tooth on the lingual side.

crown – The portion of the tooth above the gumline starting at the cementoenamel junction.

cuspid – The top portion of the tooth; the tip or point.

deciduous teeth – The first set of teeth, also known as primary teeth.

dentin – The tissue of the tooth between the pulp and the enamel and cementum; the majority of the tooth.

dentition – A set of teeth.

dentoenamel junction (DEJ) – The junction where the enamel meets the dentin.

distal – Surface of the tooth away from the midline of the face.

dorsal – The top surface.

embrasure – The space between the teeth that begins at the contact area and widens down toward the gingiva. The interproximal gingival (interdental papillae) usually fills this space.⁴

enamel – The tissue covering the crown of the tooth; the hardest substance in the body.

epithelial attachment – At the base of the sulcus where the epithelial tissue is attached to the tooth.

facial – Toward the lips or cheeks. In the back of the mouth the term buccal may be utilized, and in the front of the mouth the term labial may be utilized.

fissure – A natural groove in the tooth.

fossa – A shallow depression in the tooth.

furcation – In multi-rooted teeth, the area where the roots divide.

gingiva – The tissue that surrounds the teeth; also known as gums.

groove – A depression in the tooth that is narrow and linear.⁴

incisal – Toward the cutting edge of the anterior teeth. This is the end opposite the apex of the tooth.

interdental – Space between two adjacent teeth.

interproximal – Between the adjacent surfaces of two teeth.

keratinized – Firm stippled texture, such as the tissue of the attached gingiva.

labial – Facial side; typically used in reference to anterior teeth.

lateral – Sides.

lingual – Toward the tongue.

mandibular – Referring to the lower jaw.

maxillary – Referring to the upper jaw.

mesial – Surface of the tooth facing toward the midline of the face.

midline – An imaginary line that divides the body into equal right and left halves.

mucogingival junction – An area where the mucosa meets the attached gingiva.

mucosa – The soft tissue that is non-keratinized and covers the cheeks, floor of the mouth, soft palate, alveolar processes and other structures.

occlusal – The chewing surface of the posterior (back) teeth.

occlusion – A term used to define how the upper and lower teeth meet when closing the jaws.

palate – Roof of the mouth. It is divided into two parts: the hard palate and the soft palate.

papillae – A small projection of tissue; often nipple-like.

periapical – Around the apex of the tooth.

periodontal ligaments – A thin series of fibers that connect the tooth to the bone.

periodontium – The surrounding and supporting structures of the teeth.

posterior – Toward the back of the mouth, behind.

pulp – The inner most part of the tooth that contains the blood vessels and nerves.

quadrant – The mouth is divided into 4 quadrants; 2 in the maxillary and 2 in the mandibular.

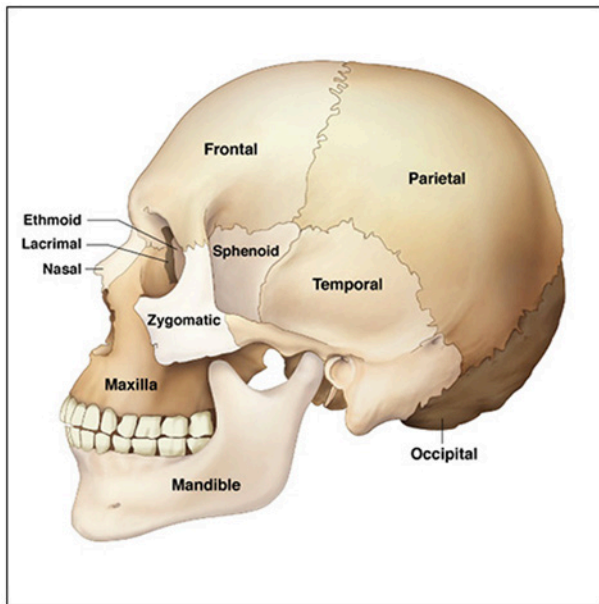


Figure 1. Human Skull.

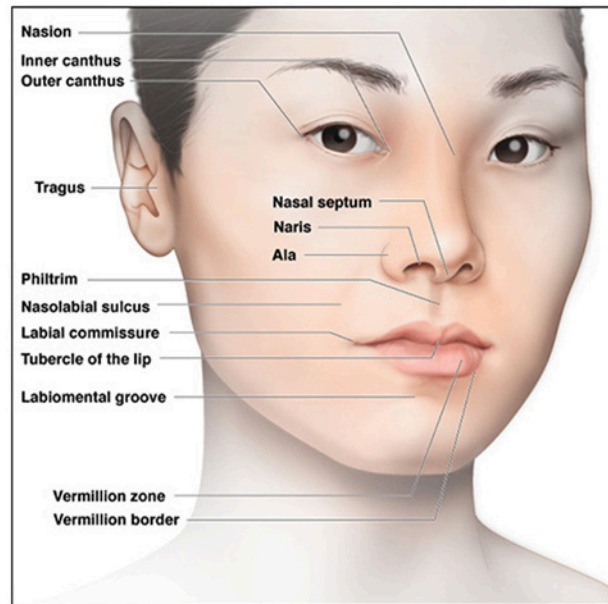


Figure 2. Facial Landmarks.

ridge – A rounded, elevated, linear area on the enamel of the tooth. There are 5 types of ridges on the teeth: marginal, triangular, oblique, transverse and cingula.⁴

succedaneous – The permanent teeth that replace the 20 primary teeth.

sulcus – The area formed by the free gingiva (non attached) lying next to the tooth. It is a trough area and can also be known as the gingiva crevice.

ventral – Toward the bottom surface; the underside of the tongue is known as the ventral surface.

Normal Anatomic Landmarks of the Head, Neck and Oral Cavity

Bone Structure of the Face

Figure 1 identifies the various bone structures of the head and face. Correctly visualizing the bone structures of the face and head aids in palpation techniques when conducting a head and neck examination on the patient.

- **Ethmoid** – Midline cranial bone.
- **Frontal** – Bone that forms the forehead.
- **Lacrimal** – Paired bones that form the wall of the orbit.

- **Mandible** – Bone that forms the lower jaw.
- **Maxilla** – Bone that forms the upper jaw.
- **Nasal** – Paired bones that form the bridge of the nose.
- **Occipital** – Bone that forms the posterior portion of the head.
- **Parietal** – Paired bones at the top of the skull. They articulate with each other and other bones in the skull.
- **Sphenoid** – Midline bone that has several processes associated with it.
- **Temporal** – Paired bones that form the lateral walls of the skull and articulate with the mandible at the temporomandibular joint.
- **Zygomatic** – Paired facial bones that form the cheeks.

Facial Landmarks

The facial landmarks can be visualized in Figure 2. These landmarks also form a benchmark for determining normal facial anatomy when performing an extraoral examination on a patient.¹

- **Ala** – Wing of the nose.
- **Inner canthus of the eye** – The inner corner of the eye.
- **Labial commissures** – Corners of the mouth.
- **Labiomental groove** – Area that separates the lower lip and the chin.

- **Naris** – Nostril.
- **Nasal septum** – Vertical separation of the nasal cavity.
- **Nasolabial sulcus** – Groove that runs upward from the commissures of the mouth and the ala of the nose.
- **Nasion** – Midline junction between the eyes just below the eyebrows.
- **Outer canthus of the eye** – The outer corner of the eye.
- **Philtrum** – Vertical groove or depression in the midline above the upper lip.
- **Tragus** – Triangle flap of cartilage that is at the external opening of the ear.
- **Tubercle of the lip** – Midline of the upper lip that has a small tissue projection.
- **Vermillion border** – Where the skin and lips meet.
- **Vermillion zone** – The reddish portion of the lips.

Landmarks in the Oral Cavity

Oral Tissues and Structures

Landmarks of the oral tissues include the palate, tongue, cheeks and floor of the mouth. It is significant to recognize the normal appearance of these structures during an intraoral examination of the patient.

- **Fauces** – Passageway from oral cavity to pharynx.
- **Frenum** – Raised folds of tissue that extend from the alveolar and the buccal and labial mucosa.
- **Gingiva** – Mucosal tissue surrounding portions of the maxillary and mandibular teeth and bone.
- **Hard palate** – Anterior portion of the palate which is formed by the processes of the maxilla.
- **Incisive papilla** – A tissue projection that covers the incisive foramen on the anterior of the hard palate, just behind the maxillary central incisors.
- **Maxillary tuberosity** – A bulge of bone posterior to the most posterior maxillary molar.
- **Maxillary/Mandibular tori** – Normal bony enlargements that can occur either on the maxilla or mandible.
- **Mucosa** – Mucous membrane lines the oral

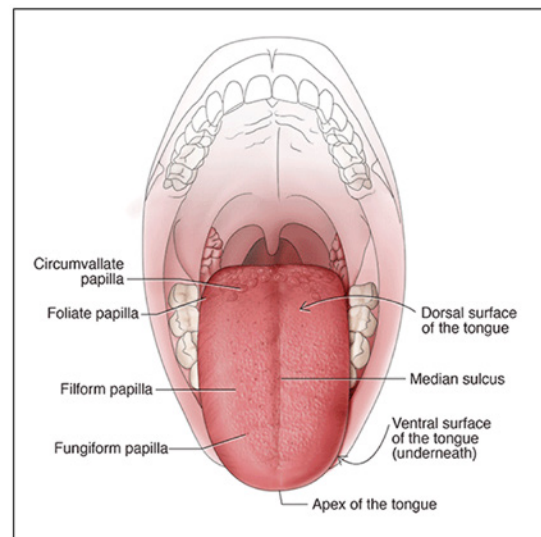
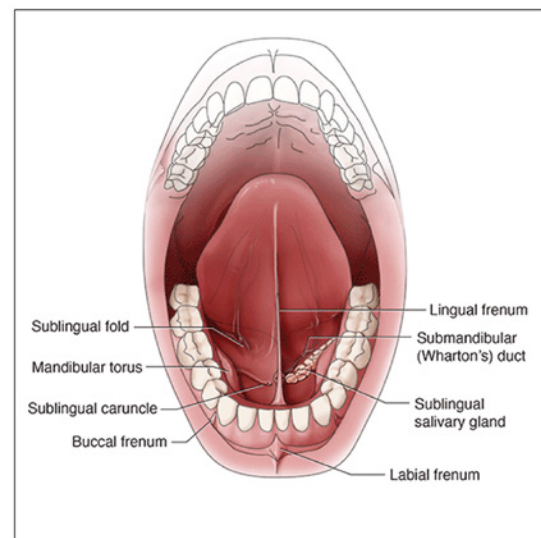
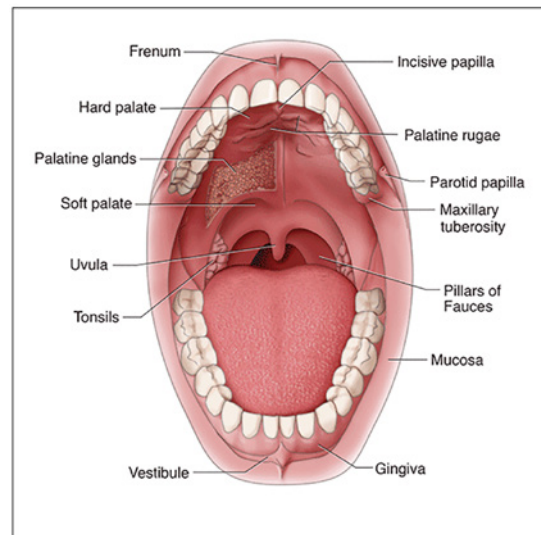


Figure 3. Landmarks of the Mouth and Tongue.

cavity. It can be highly keratinized (such as what covers the hard palate), or lightly keratinized (such as what covers the floor of the mouth and the alveolar processes) or thinly keratinized (such as what covers the cheeks and inner surfaces of the lips).

- **Palatine rugae** – Firm ridges of tissues on the hard palate.
- **Parotid papilla** – Slight fold of tissue that covers the opening to the parotid gland on the buccal mucosa adjacent to maxillary first molars.
- **Pillars of Fauces** – Two arches of muscle tissue that defines the fauces.
- **Soft palate** – Posterior portion of the palate. This is non-bony and is comprised of soft tissue.
- **Sublingual folds** – Small folds of tissue in the floor of the mouth that cover the openings to the smaller ducts of the sublingual salivary gland.
- **Submandibular gland** – Located near the inferior border of the mandible in the submandibular fossa.
- **Tonsils** – Lymphoid tissue located in the oral pharynx.
- **Uvula** – A non-bony, muscular projection that hangs from the midline at the posterior of the soft palate.
- **Vestibule** – Space between the maxillary or mandibular teeth, gingiva, cheeks and lips.
- **Wharton's duct** – Salivary duct opening on either side of the lingual frenum on the ventral surface of the tongue.

Tongue

Landmarks of the tongue include the:

- **Apex of the tongue** – The tip of the tongue.
- **Circumvallate papillae** – Two v-shaped rows of larger, flat, cup shaped papillae on the posterior dorsum of the tongue. Each contains taste buds.
- **Dorsal surface** – The top surface of the tongue.
- **Filiform papillae** – Fine, small, cone shaped papillae covering most of the dorsum of the tongue. They are responsible for giving the tongue its texture and are responsible for the sensation of touch.

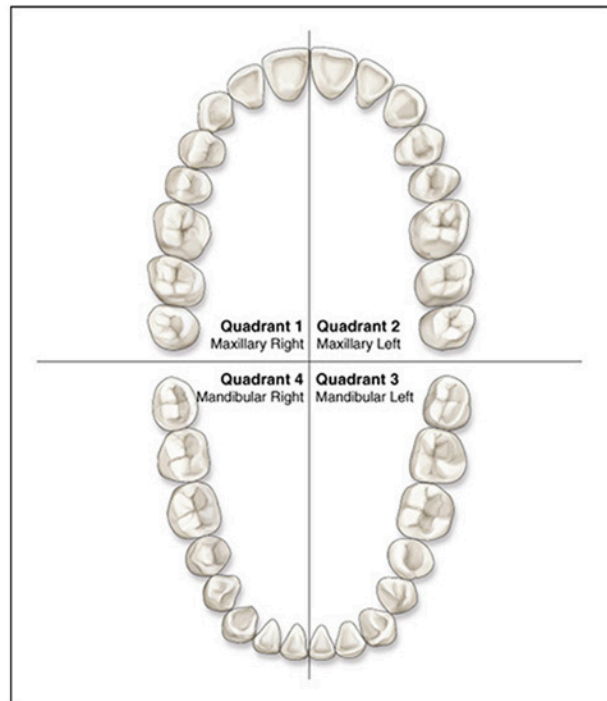


Figure 4. Dental Quadrants.

- **Foliate papillae** – These papillae are large, red and leaf-like. They are located on the posterior, lateral surfaces of the tongue. They contain some taste buds.
- **Fungiform papillae** – Deep red in color and are distributed over the dorsum of the tongue. Each one of these mushroom shaped papillae contains a taste bud.
- **Median sulcus** – Slight depression in the middle of the dorsum of the tongue running from the tip to the base of the tongue.
- **Ventral surface** – The underside of the tongue.

Teeth in the Oral Cavity

Types of Teeth, Structures, Location and Functions

The oral cavity plays an integral role in the functions of the human body. Not only does it aid in chewing, digestion, and nutrition, it also plays a significant role in appearance, speech and sensation. The teeth are arranged in the mouth in 2 arches that contain 2 quadrants each (16 teeth in each arch, 8 teeth in each quadrant in the permanent dentition). The top arch is the maxillary arch and it is fixed. The bottom arch is the mandibular arch and it is capable of movement through the temporomandibular joint.

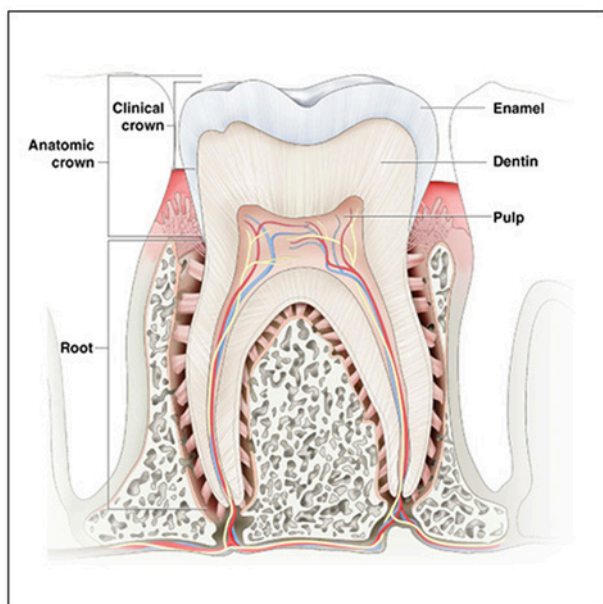


Figure 5. Basic Tooth Anatomy.

Divisions and Components of the Teeth

In addition to having very specific functions each tooth has a specific location and contains specific shapes that aid in its function. All teeth, though different in shape, have the same anatomical parts. Each tooth has a **clinical crown** (crown that is exposed to the oral cavity), **anatomic crown** (from the CEJ to the cusps), and **root(s)**. The tooth is attached to the underlying alveolar bone with fibers known as the periodontal ligaments.

Each tooth is made up of the same four components: enamel, dentin, cementum and pulp.

Enamel is the substance that covers the anatomic crown of the tooth, is the hardest substance in the body and is somewhat translucent. It is created by cells known as ameloblasts. The enamel is the first line of protection for the tooth. It can withstand biting pressure but does not have the ability to regrow once fully formed. If there has been minor demineralization (become more porous) occurring, it can remineralize (harden) and thus stop the tooth decay process with proper nutrition and oral care.

The **dentin** is the substance that lies beneath the enamel and the cementum in

the tooth. Dentin is created by cells known as odontoblasts. It is not as hard as enamel and it makes up the major portion of the tooth. The dentin is comprised of microscopic tubes known as dentinal tubules. There are three types of dentin. *Primary* dentin is what is present when the tooth erupts. *Secondary* dentin continues to form during the life of the tooth. Reparative dentin can form in response to inflammation/irritation or trauma. The color of the dentin reflecting through the enamel is what is responsible for the color (hue and tint) of the tooth. Because dentin is softer than enamel, if decay passes through the enamel (demineralization) and invades the dentin, it can spread very rapidly here. The enamel and the dentin meet at an area known as the DEJ or dentoenamel junction.

The **cementum** is the substance that covers the root of the tooth. It is also very thin and not as hard as the enamel but has a similar hardness to bone. Cells known as cementoblasts form cementum. There are fibers that project from the cementum and attach it to the alveolar bone. The cementum can be abraded by such things as the bristles of a stiff toothbrush. Also, if the cementum becomes exposed to the oral cavity through gingival recession, this surface can become very sensitive to temperature changes in the mouth (hot and cold). The enamel and cementum meet at an area known as the CEJ or cementsenamel junction.

The **pulp** is the final component, and it is where all the nerves and blood vessels that supply the tooth are housed. The pulp is divided into two areas: the pulp chamber, located in the crown of the tooth; and the pulp canals, which are located in the root(s) of the tooth. If the pulp area becomes exposed to decay, a bacterial infection can occur and may require root canal therapy in order to save the tooth. When the teeth first erupt, the pulp chamber and canals are very large, but as secondary dentin forms, the pulp area decreases.

Types of Teeth and Their Functions

There are 4 types of teeth in the oral cavity:

- **Incisors** – The four front teeth in both the upper and lower jaws are called incisors. Their primary function is to cut food. The two incisors on either side of the midline are

known as central incisors. The two adjacent teeth to the central incisors are known as the lateral incisors. Incisors have a single root and a sharp incisal edge. The incisors are developed from 4 lobes, in contrast to posterior teeth which develop from 4 to 5 lobes. When first erupted, the incisors have 3 mamelons, or bumps on the incisal edge which are remainders of the lobes from which the tooth developed. The cingulum is remainder of the 4th mamelon and can have a pit formed in it where it meets the lingual surface of the tooth. These incisal edge mamelons are usually worn away shortly after eruption with normal biting function. Central incisors have sharper and more acute incisor angles than lateral incisors. The maxillary central incisors are also unique in that they are larger than mandibular central incisors. Maxillary lateral incisors often vary the most in their shape. Sometimes maxillary lateral incisors can have a peg-like shape and are thus referred to as "peg laterals." The maxillary lateral incisors may also be congenitally missing. The mandibular central incisor is the smallest tooth of all the incisors.⁴

- **Canines** – There are four canines in the oral cavity. Two in the maxillary arch and two in the mandibular area. They are behind and adjacent to the lateral incisors. Their main function is to tear food. They have a single, pointed cusp and a single root. They have the longest root of any tooth. They also serve to form the corners of the mouth. The canines have very prominent cingulum, but the maxillary cingulum is more prominent than the one on the mandibular canines and it rarely has pits. The lingual is formed by a single lingual ridge that lies between two lingual fossae.⁴
- **Premolars (Bicuspid)** – These teeth are located behind and adjacent to the canines and are designed to crush and grind food. There are eight premolars in the oral cavity. There are two in each quadrant of the mouth. The one closest to the midline is the first premolar and the one farthest from the midline is the second premolar. These teeth can have 2-3 cusps (mandibular second premolar typically has 3). The facial cusp is typically longer and wider than the lingual cusp. In the mandibular 1st premolar, the lingual cusp is very small and usually not

functional. The maxillary first premolar has two roots, and the remaining premolars have a single root. There are no premolars in the primary dentition. The premolars replace the primary molars when they exfoliate. Often the 1st premolar is the tooth that is extracted in orthodontic procedures to make room for crowded teeth to move into place.⁴

- **Molars** – The most posterior teeth in the mouth are the molars. They have broader and flatter surfaces with 4-5 cusps and have the largest crown of any other teeth. They are designed to grind food. Mandibular molars typically have 2 roots. Maxillary molars, which are located behind the second premolars, typically have 3 roots. There are 12 molars in the permanent dentition with three in each quadrant of the mouth. They are named starting with closest to the midline as first molars, second molars and third molars. Although, some people do not fully develop the third molars and thus can vary in size and shape or even be absent. Third molars are often referred to as wisdom teeth and often have fused roots. The primary dentition only contains eight molars. The mandibular molar is the first permanent tooth to erupt in the mouth.⁴

Surfaces of the Teeth

When identifying teeth and referring to specific areas of a tooth, it is necessary to utilize named surfaces and directions designated according to where it is located. Teeth also have number/letter designations. There are several types of designation/identification systems, but the most common is the Universal System where the permanent dentition is numbered from 1-32 beginning with the maxillary right third molar.

- **Distal** – The surface that is away from the midline of the face.
- **Facial** – The surface that faces the cheeks or lips. Can also use the terms:
 - **Labial** – The surface towards the lips.
 - **Buccal** – The surface towards the cheeks.
- **Incisal** – The biting edge of an anterior tooth.
- **Lingual** – The surface that faces the tongue.
- **Mesial** – The surface that is closest to the midline of the face.
- **Occlusal** – The chewing surface of posterior teeth.
- **Proximal** – Tooth surfaces that are next to each other (i.e., distal of lateral incisor and mesial of canine).

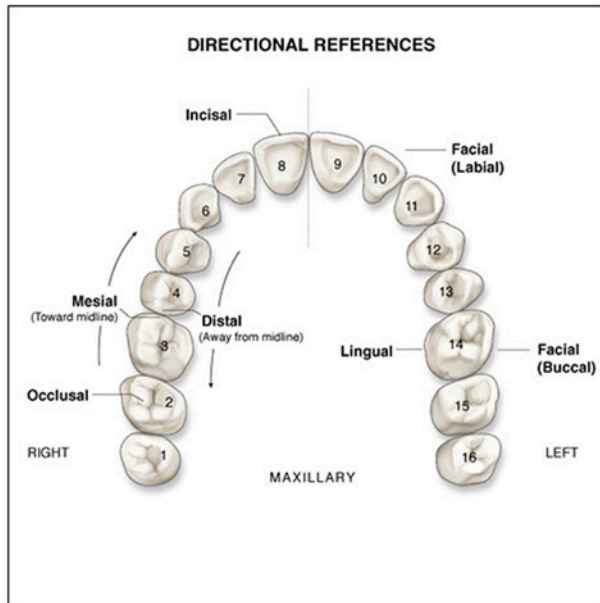


Figure 6. Surfaces of the Teeth.

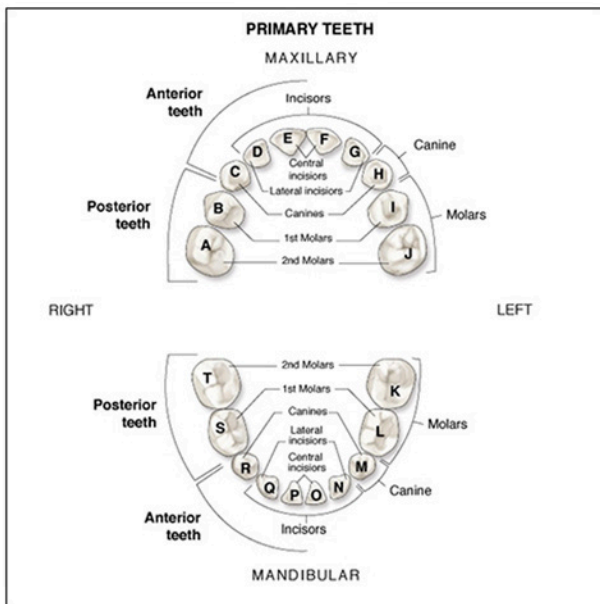


Figure 7. Primary Dentition Teeth Named and Numbered.

Multiple surfaces and directions may be utilized to specify a certain area of a tooth. An example of this is the mesio-lingual surface of #3. This particular example is referring to the surface of the Maxillary right 1st molar, that is closest to the front of the mouth and on the tongue side of the tooth.

Dentitions

Primary Dentition

These are the first teeth to erupt into the oral cavity. The primary dentition is comprised of 20 teeth. Often these teeth are referred to as deciduous teeth. These teeth will be exfoliated (lost) as the permanent teeth erupt. In each arch of the mouth, there are two central incisors, two lateral incisors, two canines, and four molars. The teeth are usually recognized by a letter of the alphabet beginning with "A" (Maxillary right second molar) and ending with "T" (Mandibular right second molar). There are no premolars or third molars in the primary dentition. The approximate eruption and exfoliation dates for the primary teeth are listed in Table 1. By the time a child is 3 years of age, all the primary teeth should be erupted and all the permanent teeth (with the exception of the 3rd molars) are in some stage of development.

Permanent Dentition

The permanent dentition is comprised of 32 teeth. There are 16 teeth in the maxilla and 16 in the mandible. In each arch there are two central incisors, two lateral incisors, two canines, four premolars, and six molars. The permanent central incisors, lateral incisors, canines, and first and second premolars replace the primary dentition. The primary molars are replaced with the permanent premolars, and the permanent molars erupt posterior to those. Table 2 indicates the approximate eruption dates for the permanent molars.

Occlusion

Occlusion is defined as the way the teeth meet when the lower jaw (mandible) and upper jaw (maxilla) come together. It is how the teeth contact in any type of functional relationship. Normal occlusion is desirable as it allows oral functions to operate properly, provides the best esthetics and is helpful in the prevention of disease. Anytime normal occlusion does not occur in the mouth, it is termed malocclusion. Malocclusion can have an effect on dental diseases, chewing, speech and esthetics (especially facial profile) and other functions

Table 1. Primary Dentition.²

Tooth	Eruption Date (Avg.)	Exfoliation Date (Avg.)
Maxillary		
Central Incisor	8-12 Months	6-7 Years
Lateral Incisor	9-13 Months	7-8 Years
Canine	16-22 Months	10-12 Years
1st Molar	13-19 Months	9-11 Years
2nd Molar	25-33 Months	10-12 Years
Mandibular		
Central Incisor	6-10 Months	6-7 Years
Lateral Incisor	10-16 Months	7-8 Years
Canine	17-23 Months	9-12 Years
1st Molar	14-18 Months	9-11 Years
2nd Molar	22-31 Months	10-12 Years

of the oral cavity. Malocclusion can occur for a variety of reasons. These include, but are not limited to, heredity, trauma, diseases, and habits (such as thumb sucking).

Occlusion is designated according to certain classifications. Figure 9 shows the relationship of the teeth and the variations of the malocclusion classifications. It is based on how the maxillary and mandibular first molars come into contact with one another when closing the teeth. The common system used to classify occlusion is termed Angle's classification system. Class I (orthognathic) is considered

Table 2. Permanent Dentition.²

Tooth	Eruption Date (Avg.)
Maxillary	
Central Incisor	7-8 Years
Lateral Incisor	8-9 Years
Canine	11-12 Years
1st Premolar	10-11 Years
2nd Premolar	10-12 Years
1st Molar	6-7 Years
2nd Molar	11-13 Years
3rd Molar	17-21 Years
Mandibular	
Central Incisor	7-8 Years
Lateral Incisor	8-9 Years
Canine	9-10 Years
1st Premolar	10-12 Years
2nd Premolar	11-12 Years
1st Molar	6-7 Years
2nd Molar	11-13 Years
3rd Molar	17-21 Years

normal occlusion. Class II (retrognathic) and III (prognathic) are considered malocclusion. Class II can have different divisions. Division I is where there are protruded anterior teeth and Division II is where there one or more retruded maxillary anterior teeth.

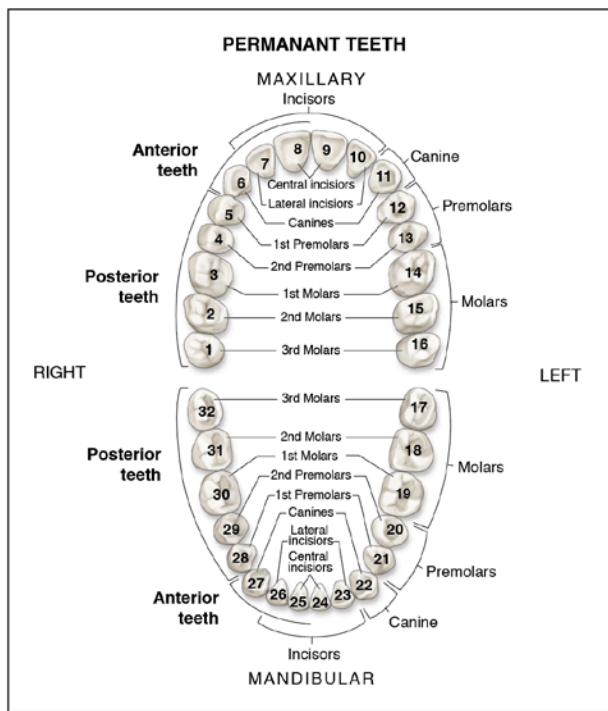


Figure 8. Permanent Dentition Teeth Named and Numbered.

Anatomy of the Periodontium

In order to understand how disease processes can affect the oral cavity, it is important to know the structure of the periodontium. This includes the gingival tissue and its supporting bone. The gingiva usually exhibits one of the first signs of inflammation through redness, bleeding or swelling. Although, this is not necessarily a sign of periodontal involvement it is imperative to understand the underlying structures and how they interact.

Structure of the Gingiva

The normal gingiva may range in color from light coral pink to heavily pigmented. It is normally stippled in appearance (resembling an orange peel). The makeup of the gingival tissue varies according to its location and function. There are two types of gingiva and several important anatomic regions.

- **Alveolar mucosa** – The area of tissue beyond the mucogingival junction. It seems less firmly attached and redder than the

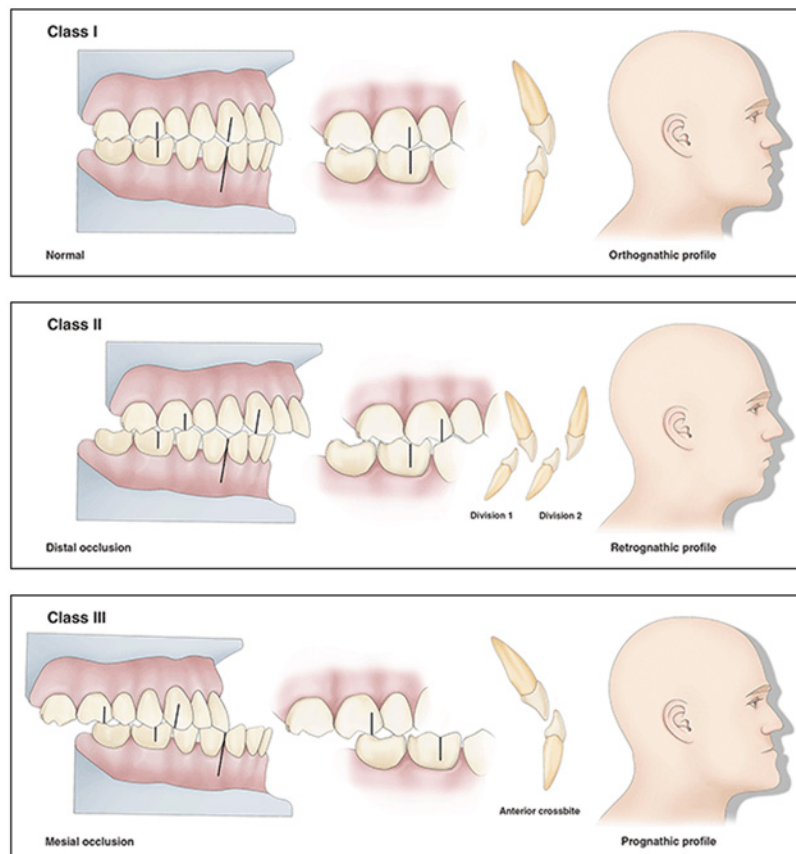


Figure 9. Angles' Classification of Occlusions (animation).

attached gingiva. It is non-keratinized and provides a softer and more flexible area for the movement of the cheeks and lips.

- **Attached gingiva** – This tissue is adjacent to the free gingiva and is keratinized and firmly attached to the bone structure. It can range from 3-12 mm in height.
- **Free gingiva** – This tissue is not attached and forms a collar around the tooth. The trough around the tooth is called the sulcus and its depth is normally 1-3 mm. It is lined with sulcular epithelium and attached to the tooth at its base by the epithelial attachment.
- **Gingival margin** – The border region of the gingiva that touches the tooth.
- **Junctional epithelium** – The part of the gingiva that attaches the connective tissue to the tooth. It is located at the base of the sulcus.
- **Interdental papillae** – The region of gingival tissue that fills the space between adjacent teeth. In a healthy mouth this is usually knife-edged and fills the interdental space.
- **Muco-gingival junction** – The scalloped line that divides the attached gingiva from the alveolar mucosa.

Attachment Mechanism

The attachment of the tooth to the surrounding and supporting structures (bone) is accomplished through the cementum of the tooth, periodontal ligaments and the alveolar bone. The root of the tooth (cementum) is attached to the underlying bone by a series of periodontal fibers that make up the periodontal ligament and allow

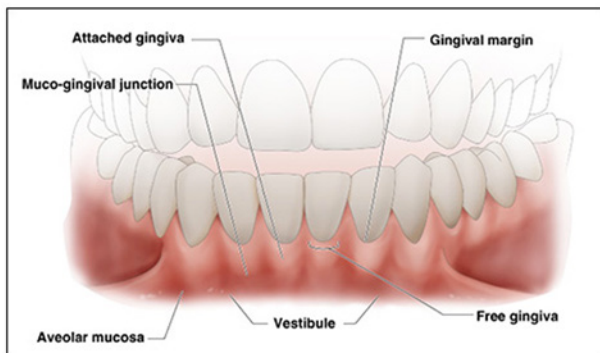


Figure 10. Healthy Gingiva.

for minor movement of the tooth in the socket without damage to the tooth or the underlying structures. These fibers are classified apical, oblique, horizontal, alveolar crest and interradicular fibers.

Bone

The alveolar bone supports the teeth and is covered by gingival tissue. It contains several different types of bone. The inner and outer surfaces of the bone are made up of dense cortical plates. The portion between the cortical plates is called trabecular or cancellous bone. It resembles a sponge in appearance and has many irregular spaces within. The wall of the tooth socket is made of lamina dura, which is a thin, dense bone where the periodontal ligament is attached.

Conclusion

Having a good knowledge of normal head, neck, dental and oral anatomy is essential in providing quality health care to the patient. In order to recognize abnormal or disease states, one must be able to compare what is considered normal to what they are seeing in the patient during examination. This knowledge also provides a basis for effective communication with the dental team and other health care providers in discussing oral conditions of the patient both past and present.

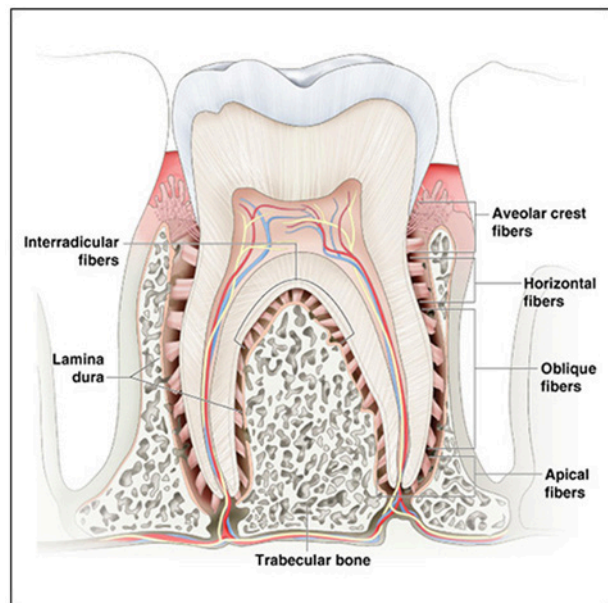


Figure 11. Tooth Anatomy.

Course Test Preview

To receive Continuing Education credit for this course, you must complete the online test. Please go to: www.dentalcare.com/en-us/ce-courses/ce500/start-test

- 1. Which of the following bones form the forehead?**
 - A. Nasal
 - B. Frontal
 - C. Parietal
 - D. Ethmoid
- 2. The midline depression above the upper lip is known as?**
 - A. Philtrum
 - B. Septum
 - C. Labiomenal Groove
 - D. Tubercle of the Lip
- 3. What is the non-bony portion of the palate known as?**
 - A. Hard Palate
 - B. Frenum
 - C. Vestibule
 - D. Soft Palate
- 4. The _____ is a non-bony muscular projection that hangs from the midline at the posterior of the soft palate.**
 - A. Frenum
 - B. Septum
 - C. Tori
 - D. Uvula
- 5. The top surface of the tongue is known as the _____ surface.**
 - A. Ventral
 - B. Dorsal
 - C. Median
 - D. Lateral
- 6. Which arch in the mouth contains 16 teeth?**
 - A. Maxillary
 - B. Mandibular
 - C. Lateral
 - D. A and B
- 7. The area from the CEJ to the cusp tips is known as _____.**
 - A. clinical crown
 - B. anatomical crown
 - C. root canal
 - D. apex of the crown
- 8. What is the hardest substance in the body?**
 - A. Enamel
 - B. Cementum
 - C. Pulp
 - D. Dentin

- 9. Which type of substance in the tooth continues to grow throughout the lifetime of the tooth?**
- A. Cementum
 - B. Enamel
 - C. Secondary Dentin
 - D. Nerves and Blood Vessels
- 10. Which one of the tooth components has an equivalent hardness to bone?**
- A. Cementum
 - B. Enamel
 - C. Dentin
 - D. Dentin tubules
- 11. Which teeth have a cutting edge?**
- A. Incisors
 - B. Premolars
 - C. Bicuspids
 - D. Molars
- 12. Which tooth appears in the permanent dentition but not in the primary dentition?**
- A. Molars
 - B. Lateral incisors
 - C. Central incisors
 - D. Premolars
- 13. Which teeth are responsible for grinding food?**
- A. Primary incisors
 - B. Molars
 - C. Canines
 - D. Premolars
- 14. Which surface is known as the chewing surface of posterior teeth?**
- A. Occlusal
 - B. Lingual
 - C. Mesial
 - D. Distal
- 15. How many teeth comprise the primary dentition?**
- A. 15
 - B. 20
 - C. 30
 - D. 32
- 16. A dentition that is not aligned in a normal functional relationship is termed as in _____.**
- A. nonfunctionability
 - B. malocclusion
 - C. mass occlusion
 - D. dominant occlusion

- 17. Which tissue in the periodontium is not attached to the tooth and forms a collar around the tooth?**
- A. Attached gingiva
 - B. Marginal gingiva
 - C. Free gingiva
 - D. Gingival ligament
- 18. The tooth is attached to the underlying bone through which of the following?**
- A. Periodontal fibers
 - B. Attached gingiva
 - C. Cementum fibers
 - D. Bone projections
- 19. The inter and outer surfaces of the alveolar bone are made up of _____.**
- A. Spongy bone
 - B. Cortical plates
 - C. Cementum
 - D. Oblique fibers
- 20. The wall of the tooth socket is lined by what type of bone?**
- A. Trabecular
 - B. Dentin
 - C. Lamina dura
 - D. Cancellous

References

1. Frehrenbach MJ, Herring SW. Illustrated Anatomy of the Head and Neck, 6th Ed. St. Louis, MO. Saunders Elsevier. 2020.
2. J Am Dent Assoc. 2005 Nov;136(7):1844-1062. Accessed January 6, 2025.
3. J Am Dent Assoc. 2006 Jan;137(1):12-127. Accessed January 10, 2025.
4. Blue CM. Darby's comprehensive review of dental hygiene, 9th ed. St. Louis, MO. Elsevier. 2022.

Additional Resources

- No Additional Resources Available

About the Author

Vickie Parrish Foster, RDH, BS, MEd



Vickie previously served as the Director of the Undergraduate Dental Hygiene program and as an associate professor in the Department of Dental Ecology at the UNC School of Dentistry in Chapel Hill for 32 years. On January 1, 2015, she retired after 40 years in the dental hygiene profession. She received her AAS in dental hygiene from Guilford Technical Community College in Greensboro, NC, her BS in dental auxiliary teacher education at UNC-Chapel Hill in 1981 and a master's degree in adult and higher education at UNC-Chapel Hill in 1983. While at UNC her teaching responsibilities included clinical dental radiology, dental materials, clinical dental hygiene and community dental health. She has presented continuing education courses at the local, state, national and international levels for many years and co-authored a radiology textbook in 1993. Previously, she served on the editorial board for the *Journal of Dental Hygiene*. She also authored the website review column in the *International Journal of Dental Hygiene* for many years.

Email: vickie_overman@unc.edu