

Professional Dental Terminology for the Dental Assistant and Hygienist



Course Author(s): Vickie Parrish Foster, RDH, MED

CE Credits: 2 hours

Intended Audience: Dental Hygienists, Dental Assistants, Dental Hygiene Students, Dental Assistant Students

Date Course Online: 05/01/2018

Last Revision Date: 04/30/2021

Course Expiration Date: 04/29/2024

Cost: Free

Method: Self-instructional

AGD Subject Code(s): 10, 430, 780

Online Course: www.dentalcare.com/en-us/professional-education/ce-courses/ce542

Disclaimers:

- P&G is providing these resource materials to dental professionals. We do not own this content nor are we responsible for any material herein.
- Participants must always be aware of the hazards of using limited knowledge in integrating new techniques or procedures into their practice. Only sound evidence-based dentistry should be used in patient therapy.

Conflict of Interest Disclosure Statement

- The author reports no conflicts of interest associated with this course.

Introduction – Dental Terminology

The Professional Dental Terminology for the Dental Assistant and Hygienist course is designed to introduce dental assisting and hygiene students, and serve as a review to practicing assistants and hygienists, to the professional dental terminology that is utilized in dentistry. Case scenarios are used that represent various members of the dental team speaking with patients and other team members.

Course Contents

- Overview
- Learning Objectives
- Dental Team Members
- Introduction of Students and Dental Team Members
- Case Scenario 1: The Adult Preventive Appointment
 - Adult Teeth
 - Parts of the Tooth
 - Supporting and Surrounding Structures of the Teeth
 - Dental Plaque/Biofilm
 - Dental Calculus
 - Oral Hygiene
 - Critical Thinking Question
- Case Scenario 2: The Pediatric Examination Appointment
 - Primary Teeth
 - Carious Lesions
 - Cavity Prevention
 - Oral Hygiene Instructions
 - Critical Thinking Question
- Case Scenario 3: Gingivitis
 - Characteristics of Gingivitis
 - Causes, Treatment and Prevention
 - Critical Thinking Question
- Case Scenario 4: Periodontal Disease
 - Characteristics of Periodontal Disease
 - Classifications of Periodontal Diseases
 - Causes, Treatment and Prevention
 - Critical Thinking Question
- Case Scenario 5: Restorative and Esthetic Dentistry
 - Amalgam and Composite Restorations
 - Crowns and Bridges
 - Dentures
 - Implants
 - Tooth Whitening
 - Critical Thinking Question
- Glossary of Terms
 - A-C
 - D-F
 - G-I
 - L-O
 - P-R
 - S-Z
- Course Test
- References
- About the Author

Overview

Dental terminology is introduced through explanation of terms, followed by case scenarios that include various team members and patients. The dialogue in the scenarios include the use of professional and lay terminology as applicable. At the completion of each case scenario, there is a question posed to the learner allowing the use of critical thinking skills. This course is an excellent resource for the classroom.

Learning Objectives

Upon completion of this course, the dental professional should be able to:

- Identify the various dental professionals and their roles and responsibilities.
- List the appropriate dental terminology associated with intraoral and extraoral structures, restorations, disease processes and oral care for the patient.
- Explain to a patient the basic dental diseases, their appearance, basic causes, prevention and treatment.
- Utilize appropriate professional dental terminology when addressing patient questions and concerns and speaking with other dental professionals.

Dental Team Members

In a dental practice there are usually three to four different types of dental professionals. The **dentist** must attend four years of dental school (after college), is licensed (DDS/DMD), and is responsible for the diagnosis of dental disease and treatment planning for the patient. The dentist is the one that, most often, carries out the restorative treatment for the patient. The **dental hygienist**, who attended a minimum of two to four years of dental hygiene school, is also a licensed professional (RDH/LDH), and is responsible for the preventive portion of patient treatment. This includes, but is not limited to, oral prophylaxis, oral cancer screening, periodontal screening, and oral hygiene education for the patient. The **dental assistant** can be either on the job trained (OJT) or be a graduate of a dental assisting program. Most dental assisting programs are usually one year in length. The dental assistant, after meeting certain

educational criteria, may take an examination administered by the Dental Assisting National Board (DANB) and have the title of certified dental assistant (CDA). The dental assistant is the office professional that usually assists the dentist during restorative procedures. The assistant also can do many other tasks such as preventive education, making temporary crowns, and removing sutures, to name a few. The tasks of the dental assistant are dependent on the laws of the state and level of education. Each state has a different set of rules.

Other members of the dental team include the **receptionist** and **office manager**. Although these roles do not require a specific education in dentistry, these members provide an essential part in the practice's ability to run efficiently and effectively.

A member of the dental team that usually does not work in the dental office, but in a dental laboratory, is the dental laboratory technician or technologist (DLT). This professional may be trained on the job or attend two to four years of dental laboratory technology education. They are responsible for making crowns, bridges, partial and full dentures as well as other dental appliances following the prescription of the dentist.

There are also several dental team members that are becoming more prevalent in the United States. A **dental therapist** is a licensed member of the dental team who provides preventive and restorative dental care, usually for children, adolescents and tribal communities. Currently 13 states have some sort of dental therapist and 5 more states are considering legislation to adopt this dental profession in the near future. The precise role varies and is dependent on the therapist's education and the various dental regulations and guidelines of each state.

Community Dental Health Coordinators (CDHC) are a new type of community health worker. They connect underserved people with public health resources and dentists who can provide needed treatment. CDHCs often come from the same types of communities in which they work. The **Oral Preventive Assistant** is also a new team member model being proposed by the American Dental Association to provide

a variety of preventive services and oral health education.

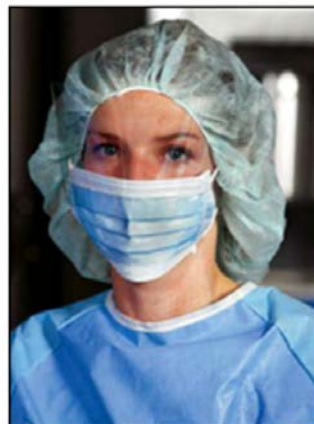There are nine recognized dental specialties within dentistry. These are Dental Public Health, Endodontics, Oral and Maxillofacial Pathology, Oral and Maxillofacial Radiology, Oral and Maxillofacial Surgery, Orthodontics and Dentofacial Orthopedics, Pediatric Dentistry, Periodontics, and Prosthodontics.

Introduction of Students and Dental Team Members

Meet the following dental professional students: Jamie, the dental assisting student and Beverly, the dental hygiene student. Both attend their respective programs at Blue State University School of Dentistry.

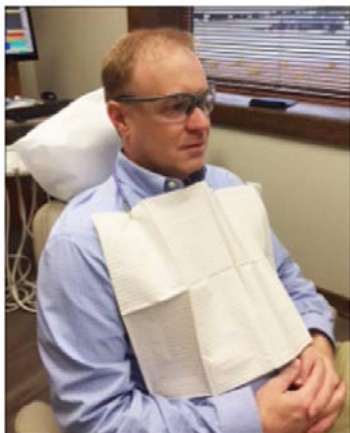

Meet our dental office professional team: Dr. Jay is pictured here and is the dentist (DDS or DMD) in Coastal Gentle Dental Practice. Nikki is the certified dental assistant (CDA), and Jessica is the registered dental hygienist (RDH).



Case Scenario 1: The Adult Preventive Appointment

Today our patient, Jerry Smith, has come to the Blue State University School of Dentistry to have his teeth cleaned. He has no prior periodontal disease, has no significant health problems and does not take any prescriptions or over-the-counter medications. He has been assigned to Beverly, a second-year dental hygiene student. Jamie, a dental assisting student, will be assisting Beverly with the appointment today.



During a preventive appointment, there are a variety of screening procedures performed on the patient. This will include an oral cancer screening, periodontal screening, and recording teeth and restorations present and missing. Usually, the dental hygienist will then perform an oral prophylaxis or cleaning for the patient and give them oral hygiene instructions and demonstrations specifically designed for that patient's needs.

Beverly to Mr. Smith: "Mr. Smith, I am happy to have you here today. I will start with several screening procedures and collecting oral and general health information so we can effectively treat your needs. After I complete the screenings and record the data, I will clean your teeth which will remove any plaque, calculus and stain. After the cleaning, I will go over oral health information that will aid in your home care."

Beverly to Mr. Smith: "I am going to feel around your head, neck and inside your

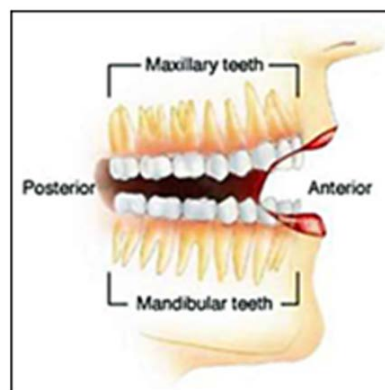mouth. As part of this oral cancer screening, I am looking for any lumps or bumps that are outside of what we consider normal anatomy."

After completing the oral cancer screening examination, Beverly begins to assess Mr. Smith's teeth and surrounding structures.

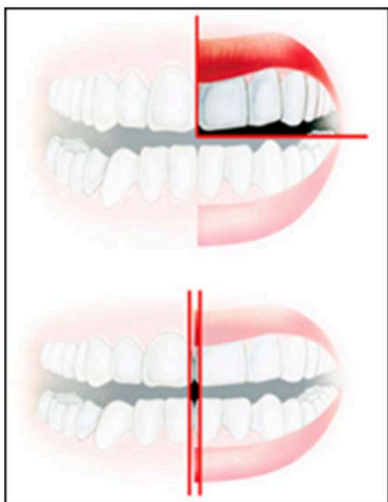
Adult Teeth

All people have two sets of teeth. The primary dentition, (sometimes called "baby teeth" or deciduous teeth) consists of 20 teeth that are eventually lost or exfoliated. They are replaced with a permanent dentition, which starts to erupt around six years of age. There are 32 teeth in the permanent dentition.

The teeth are arranged in a semi-circle (arches) in the mouth both on the top (maxillary) and bottom (mandibular) jaws (arches). The top teeth are referred to as maxillary teeth and the bottom teeth are referred to as mandibular teeth. Both arches have 16 teeth, although some adults may never have had all of their teeth erupt or they may be missing some permanent teeth. A prime example of this is the wisdom teeth (third molars). Many adults have them, but they never erupt into the oral cavity.



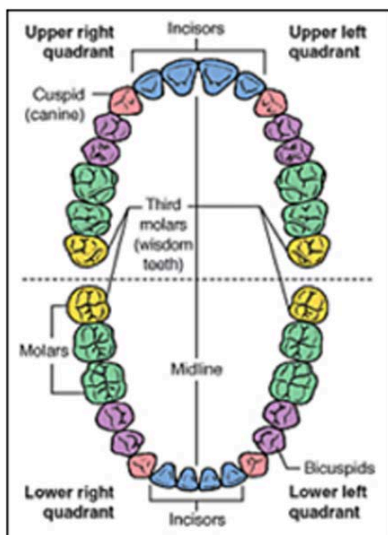
In addition, the maxillary and mandibular teeth are divided into quadrants. There are four quadrants in the oral cavity. There are two quadrants in the maxilla, and two quadrants in the mandible. The quadrants are divided by a midline at the center of the mouth.



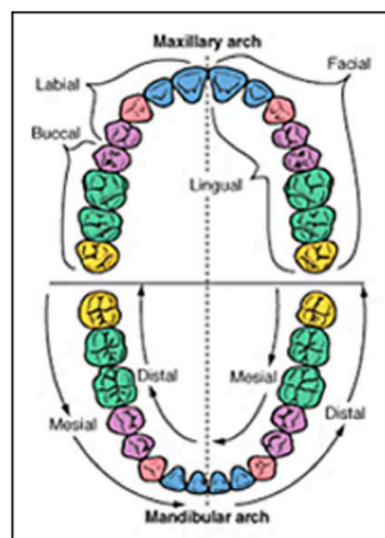
Another distinguishing factor is the teeth in the front of the mouth nearest the lips are referred to as anterior teeth. The posterior teeth are the ones nearest the throat.

When biting the teeth together, we can see the relationship between the maxillary and mandibular teeth. This is referred to as the occlusion. This relationship is one of the determining factors in recommending orthodontics (braces) to correct abnormalities concerning the way the arches come together.

The teeth are recognized by name and either a number (permanent dentition) or letter (primary dentition).



The incisors are the front teeth in the mouth and are responsible for biting and cutting food. There are four incisors in each arch. The two at the midline are referred to as **central incisors**. The ones next to the central incisors, are referred to as **lateral incisors**. The canines, form the corners of the mouth and tear the food. There are four total **canines** (two in each arch). The premolars, which are also referred to as bicuspid, help to crush and chew food. There are four premolars, in each arch (two per quadrant) for a total of eight premolars. The premolars next to the canines are called **first premolars** and the ones behind the first premolars are the **second premolars**. The most posterior teeth in the oral cavity are the molars. These teeth grind our food. There are three molars in each quadrant for a total of 12 molars. They are called the **first, second and third molars**. The third molar is often referred to as a “wisdom tooth.”



Directional descriptions are useful in reference to areas of the oral cavity. One directional description is the surfaces of the teeth that are on the tongue side. These are called lingual surfaces. The surfaces on the cheek side are called facial or buccal surfaces. Sometimes, in the anterior area near the lips, the term labial is used instead of the term facial. The surface next to the lips is the labial. We describe the surfaces that are toward the midline as mesial and away from the midline as distal. The chewing surfaces of the posterior teeth are referred to as the occlusal surfaces. The biting edges of the

anterior teeth are known as the incisal edges. Also, as we look at certain areas of the oral cavity, we can refer to these surfaces with the following terminology. Interproximal refers to the area between two teeth. This area usually is not visible by directly looking at the area. The area referred to as proximal is the area near the interproximal surface that you can see in the oral cavity.

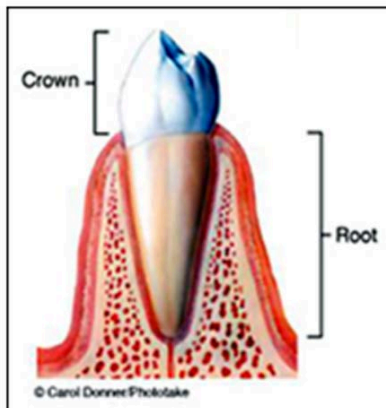
As we look in Mr. Smith's mouth, we see that he has 31 teeth. Three of his third molars are present, but we do not see his maxillary right third molar.

Jamie to Mr. Smith: "Mr. Smith, as I was recording which teeth you have present, I see that you are missing your upper right wisdom tooth. Did you have it extracted?"

Mr. Smith to Jamie: "No, it just never came in."

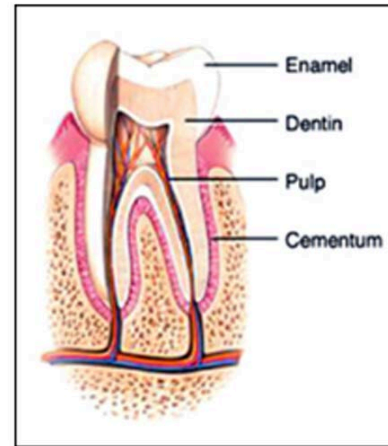
Jamie to Mr. Smith: "OK, I will make a note and when the dentist does your dental examination, he may want to have an x-ray taken of that area to determine if it is present and possibly impacted."

Parts of the Tooth



The tooth consists of two major parts: the crown and the root. In most cases only the crown of the tooth is visible in the mouth. The root is below the gingiva (gumline) and is anchored to the bone. In some cases, when the person has had gum problems or has brushed very hard, a portion of the root may be visible in the mouth. The root contains a center portion known as the root canal. This area can become involved when

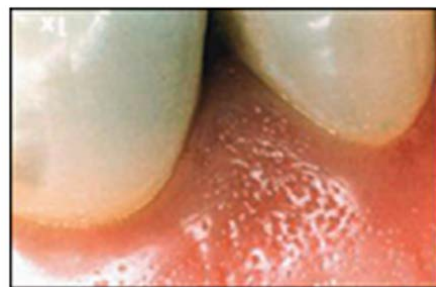someone has a tooth abscess or infection. In this case, the treatment of a root canal abscess is completed (usually by an endodontist) by removing the live canal material and replacing it with a filling material. This saves the tooth from extraction (pulling the tooth).



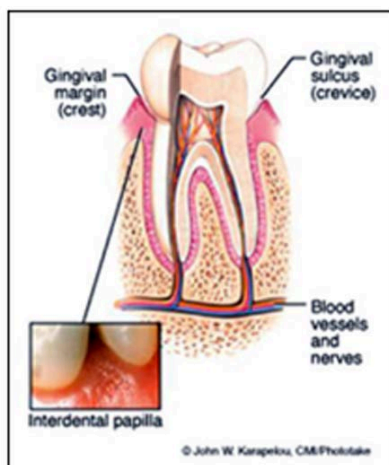
The teeth are made up of four different types of material: the enamel, dentin, pulp, and cementum. The enamel covers the crown of the tooth and is the hardest substance in the body. The cementum is the substance that covers the root of the tooth. The dentin is underneath the enamel and dentin and is much softer. When a cavity forms in the enamel and continues into the dentin, it progresses very rapidly to the pulp, since the dentin is very soft. The pulp is in the center of the tooth (root canal) and contains the nerves and blood vessels that supply the tooth with sensations of tooth sensitivity or pain.

Supporting and Surrounding Structures of the Teeth

There are several supporting areas that surround the teeth, all of which play major roles in the functioning of the teeth and several different systems of the body.



The surrounding and supporting structures of the teeth are referred to as the periodontium. The gingiva, or gum, is an important part of this structure. The gingiva surrounds and supports the tooth (other than the crown) and all of the bone. In a healthy mouth, the gingiva is pink and pebbly looking. People with gingivitis have red, swollen and often bleeding gingiva. There are tiny bundles of fibers (known as periodontal ligaments) that attach the cementum of the tooth to the bone in the jaw. This holds the tooth firmly in place in the socket.



The gingival margin is the top part of the gingiva that surrounds the crown of the tooth. The area of gingiva between two teeth is referred to as the interdental papilla. The gingival sulcus is the space between the gingiva and tooth. It starts where the gingiva is attached to the tooth and continues to the top of the gingival margin. This may also be referred to as the periodontal pocket. Measurements of this space are taken during periodontal screening and recorded for future reference to determine the health of the periodontium. Healthy pockets (or sulcus) will normally measure 3-4 mm in depth. The bone surrounding the tooth is referred to as the alveolar process. Alveolar bone makes up the maxillary and mandibular processes.

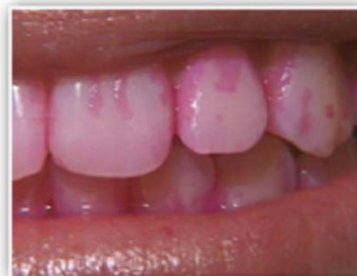Beverly to Mr. Smith: "Mr. Smith, I have completed your periodontal screening and found the data I collected about your periodontal health appears to be within normal limits. We checked the color, tone, and texture of your gums and it is pink, firm and stippled

or pebbly. All of these characteristics are indicators of good gum health.

We measured your periodontal pockets and found all of them to be between 1 to 3 mm. Again, this is an indication that they are within normal limits. The dentist may want to have x-rays taken to confirm the bone levels under your gums and make the final diagnosis of your periodontal health. Overall, it appears you have been doing a good job with your oral hygiene."

Dental Plaque/Biofilm

Dental plaque/biofilm is a soft mass of bacterial colonies made up of normal oral flora. Diet and retentive areas contribute to adherence of this biofilm to the tooth surfaces. Plaque/biofilm contributes, along with fermentable carbohydrate ingestion, to formation of dental caries (cavities). Plaque/biofilm can be both supragingival (above the gumline) and subgingival (below the gumline). Both need to be removed on a daily basis in order to avoid dental diseases.

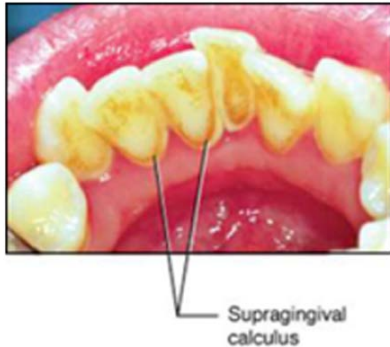


Beverly to Mr. Smith: "Mr. Smith, I want to talk to you about your oral hygiene. Even though your gums look healthy there appears to be some plaque in a few areas of your mouth that became evident when I used the disclosing tablets. These tablets stain the plaque red to make it easier to see. Let me give you this mirror and show you those areas so you can pay particular attention to those areas when you brush and floss your teeth."

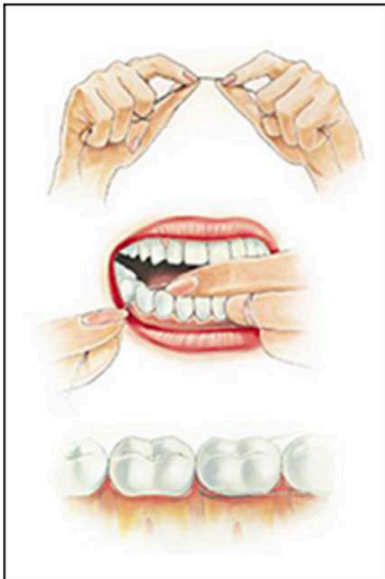
Dental Calculus

Beverly to Mr. Smith: "This is dental calculus and is what many people refer to as tartar. Calculus is primarily made up of 70-90% inorganic salts. Bacterial plaque/biofilm

adheres to the calculus very easily and thus plays a role in periodontal disease as a carrier for the bacteria. I will remove the calculus in order to provide a smooth, slick surface on the crown and root surfaces which are then less likely to attract bacteria.”



Oral Hygiene



Jamie to Mr. Smith: “While Beverly is setting up for the radiographs the doctor prescribed, she asked me to review the dental hygiene instructions she gave you at the beginning of your appointment. I will let you demonstrate the flossing and brushing techniques she showed

you to make sure you feel comfortable with them. I am also going to give you a pamphlet outlining the techniques for you to take home along with the oral hygiene aids she gave you.”

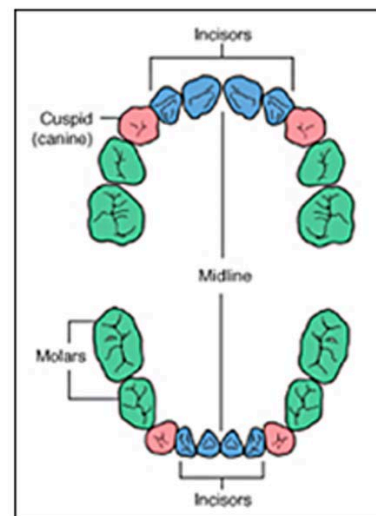
Critical Thinking Question

Mr. Smith returns for a recall/recare appointment in six months. His periodontal screening data remains the same, except three of his posterior periodontal pockets have increased to 4 mm, and he is complaining that his gums are bleeding when he brushes. What questions would you think to ask him about his oral hygiene routine?

Case Scenario 2: The Pediatric Examination Appointment

Primary Teeth

There are ten primary teeth on the maxillary and ten primary teeth on the mandibular. There are central and lateral incisors and two canines in each arch. There are no premolars in the primary dentition and there are only two molars in each quadrant instead of three.



The following chart outlines the eruption and exfoliation dates for each of the primary teeth.

Primary	Eruption Date (Avg.)	Exfoliation Date (Avg.)
Maxillary		
Central Incisor	8-12 Months	6-7 Years
Lateral Incisor	9-13 Months	7-8 Years
Canine	16-22 Months	10-12 Years
1st Molar	13-19 Months	9-11 Years
2nd Molar	25-33 Months	10-12 Years
Mandibular		
Central Incisor	6-10 Months	6-7 Years
Lateral Incisor	10-16 Months	7-8 Years
Canine	17-23 Months	9-12 Years
1st Molar	14-18 Months	9-11 Years
2nd Molar	22-31 Months	10-12 Years

Our six-year-old patient, Sara, has come to Blue University Dental School's Pediatric Clinic. Jamie, the dental assisting student, has been assigned to Sara to collect data, work on oral hygiene and assist the dental student treating Sara.

Jamie to Sara (and her parents): "Hi Sara, my name is Jamie and I am going to be helping you today. After I talk with your parents (about health data), we are going back to my special room so you can sit in my big, fancy chair where I can talk to you about your teeth and how to have a big, bright, happy smile."



After the parents complete the medical and dental history and Jamie reviews it with them, she takes Sara back to the treatment room. She explains to Sara's parents that she will come and get them prior to any treatment.

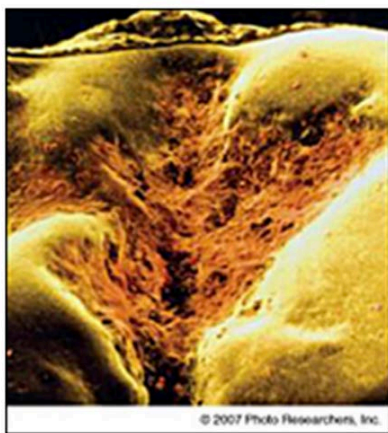
Sara has no significant health problems, takes no medications and is healthy overall. Her parents are concerned because they think she might have cavities and she does not like to brush her teeth.

Jamie to Sara: "Sara, I am going to look in your mouth, count your teeth and then put some information in my computer about your teeth. It is pretty dark inside your mouth. I know you are a big helper and can open your mouth really wide so I can see in there. Open wide - that is perfect Sara."

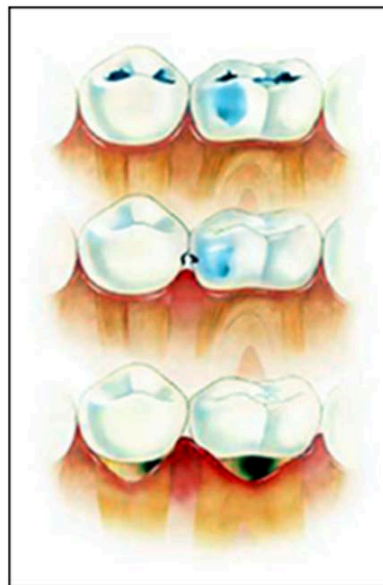
Sara still has all of her primary teeth (20) but has two teeth, the mandibular central incisors, that are loose.

After collecting the oral health data on Sara, Jamie calls the dental student in for the examination of the patient. At this point, Jamie asks Sara's parents to come into the treatment room. The dental student begins by reviewing the data collected by Jamie and then begins the examination. He does find a small area of decay on the occlusal surface of Sara's mandibular first molar. He points this out and begins to explain how he examined her mouth and the way a cavity is formed and how dental decay progresses.

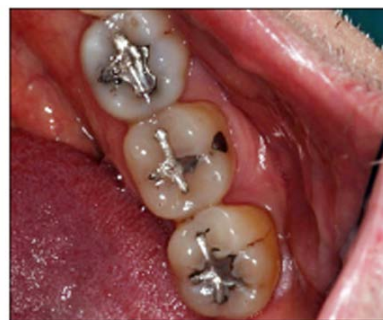Carious Lesions



The Dental Student to Sara's Parents: "Today I examined Sara's teeth. You were correct. Sara does have an area of decay. Sara's area of decay or cavity, also referred to as a carious lesion, (plural form is caries), was probably due to plaque/biofilm remaining on the occlusal surfaces like it is in this magnified picture.



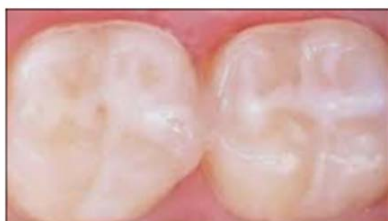In addition, as you can see in the picture here, there are several areas in which decay can occur. The top image is that of occlusal decay. It can be tiny and is hard to determine how far it has advanced without an x-ray. It starts in the pits and grooves on the chewing surface. The middle image is of interproximal decay, or decay between the teeth. This decay is very difficult to detect without an x-ray. The bottom image is of root caries. It usually only occurs when the root of the tooth is exposed due to the gums receding. We usually do not see this type of decay in a child of Sara's age.



Cavities begin on the enamel portion of the tooth usually as a “white spot”, which you can see in the middle image of the drawing above. This is due to demineralization or breaking down of the enamel. If it is left untreated, it forms a cavity, and the enamel cannot be repaired. At this point, it requires the decay to be removed and either an amalgam (photo to the left) or composite (tooth colored) filling material be placed to restore the tooth to its full function. If decay is allowed to progress without intervention, it will cause more tooth structure to be lost and may require a crown to restore it. If it progresses into the pulp, it can cause an infection and require root canal therapy or possible extraction of the tooth.”

Cavity Prevention

The dental student goes on to explain;



“There are several means of preventing decay in the mouth. The two main preventive agents used are pit and fissure sealants and fluoride. Pit and fissure sealants are usually clear or white and are painted on the occlusal surfaces to block the plaque/biofilm from invading the pits and fissures of the occlusal surfaces and thus causing decay.

Fluoride is another means of preventing decay. Fluoridated water, if ingested during the time that the permanent teeth are forming (prior to eruption), is an excellent means of providing strength to the enamel and making it more resistant to demineralization and decay. Also, swishing with a daily fluoride rinse agent, which contains sodium monofluorophosphate or stannous fluoride, can be very effective in preventing decay. The use of acidulated phosphate, neutral sodium fluoride and fluoride varnish in the dental office are very effective in combating the initiation of decay.”

Oral Hygiene Instructions

The ideal means for having a young child do daily oral hygiene is to engage the parent(s) in the process. Children cannot effectively brush their own teeth until about seven or eight years old. Effective flossing usually cannot occur until about 10-12 years of age. Younger children should be allowed to brush and then followed up with the parent thoroughly brushing and flossing the child's teeth. It is imperative that only a small amount of toothpaste (pea sized) be placed on the toothbrush. Children often swallow toothpaste, which contributes to fluoride intake. As with any good thing, too much could be harmful.

As the children age, they can be responsible for their own oral hygiene. This includes brushing (twice daily for two minutes each time), flossing and rinsing with an anti-cavity (fluoride) mouth rinse (which should be expectorated...spit out).



Jamie to Sara and Her Parents: “Sara, I know you told me that you like to eat candy and love sweet things. As we talked about, some of that might be bad for you because it can help cause cavities or little holes in your teeth. I want to show you and your Mom and Dad how to take care of your teeth, so that you don't get any more cavities. We are going to use this little red, cherry flavored tablet (disclosing agent). I want you to chew it up and spit it out. Then we are going to look in the mirror to see if there are sugar bugs on your teeth that we need to clear away.”

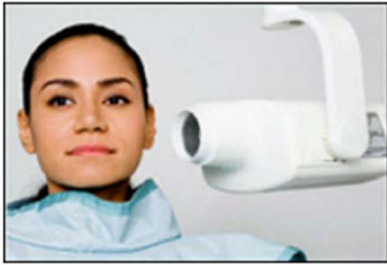They then look at it together and work on brushing the red stains off the teeth.

Critical Thinking Question

If Sara, returns in six months for a recall/recare appointment, and she has two more new cavities, what questions would you ask her and her parents about her diet and her oral hygiene habits? How would you think they might respond?

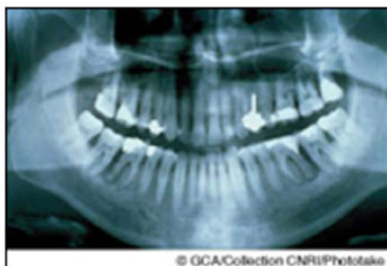Case Scenario 3: Gingivitis

The first patient of the day in Dr. Jay's office is Ms. Patricia Greene. She is 36 years old and the only medication she is taking are birth control pills. She is scheduled for an oral prophylaxis appointment with Jessica, the dental hygienist in the practice. Dr. Jay and Jessica come into the treatment room together to greet Patricia and review her updated medical history.



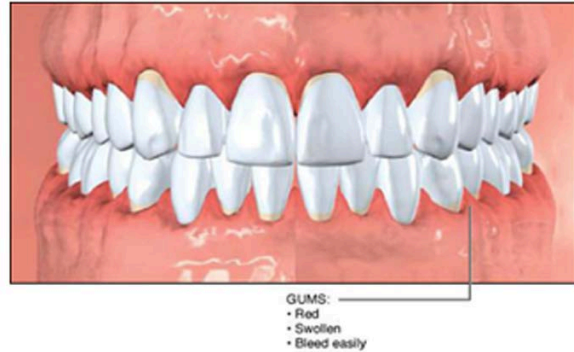Dr. Jay to Ms. Greene: "Good morning Patricia. I was looking over your chart and see that you haven't been in for a check-up in about three years. Before I do my examination, I would like for Jessica to take some x-rays or radiographs. I will need a full mouth series (FMX) and a panoramic image. Do you have any concerns about your mouth before we start?"

Ms. Greene to Dr. Jay: "I am having quite a bit of bleeding when I brush my teeth. I thought that maybe I am just brushing too hard. My gums are very tender when I brush."

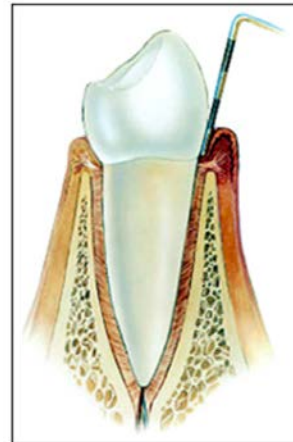


Dr. Jay to Ms. Greene: "When the radiographs are complete, I will do my examination, check on your gums and then Jessica will clean your teeth and give you some oral hygiene instructions to help you out."

Characteristics of Gingivitis



As we exam Patricia's oral cavity we can see that her gingiva is red around the margins, swollen and when we probe or even touch them, they bleed easily. Gingivitis is primarily an inflammation of the gingival margins. It does not involve bone loss and is usually a result of bacterial plaque/biofilm remaining in and around the gingival margins and interproximal areas.



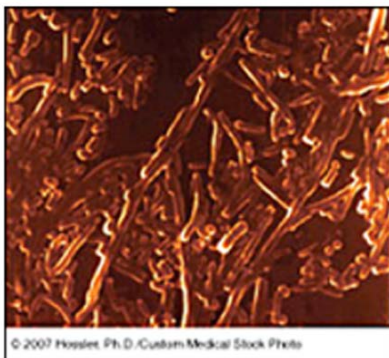
When the area is probed with the periodontal probe, there is usually no evidence of bone loss. The diagram shows a probe inserted into a sulcus around a premolar, it measures 4 mm (each black and silver band represent 3 mm increments). Three millimeters is a normal

reading for this area. But because the marginal gingiva is erythemic (red) and edematous (swollen), the reading has increased by about 1 mm. The lack of bone loss can be confirmed when reviewing the radiographic images.

Causes, Treatment and Prevention

Studies both in vitro (laboratory) and in vivo (in humans) have shown that gingivitis is an inflammatory process. It can be caused by a number of conditions such as poor oral hygiene; gingival abrasion; stress; general illness; uncontrolled diabetes; smoking; or hormonal changes, such as during pregnancy or puberty.

For patients with gingivitis, the ideal treatment is meticulous oral hygiene. This includes twice daily brushing, sulcular cleaning (either with a brush, pick or other device such as a pulsing tool), mouth rinses and flossing.



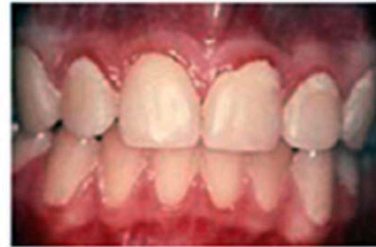There are several agents that can also be employed as topical anti-gingivitis treatments. These include, but are not limited to, toothpastes with stannous fluoride, therapeutic mouthrinses (such as antimicrobials, plaque biofilm reducing agents, and anti-periodontitis agents) and vigorous rinsing with water, such as with a pulsing tool. This reduces the number of active bacteria in the mouth and dilutes the quality of the biofilm.

Dr. Jay to Ms. Greene: “Patricia, after looking at your health data, and the examination findings, you have gingivitis. Gingivitis is inflammation of the gums caused by buildup of bacterial colonies in your mouth. Usually they cause redness, swelling, bleeding and pain. All of these symptoms are your body’s reaction to inflammation or infection. In addition, the

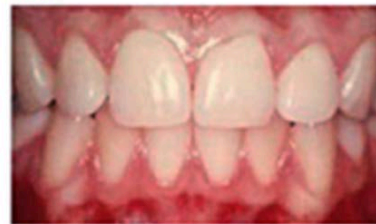changes in your hormones or stress can cause this to worsen. I know that Jessica gave you some specific oral hygiene instructions to follow. Let me emphasize how important these are in resolving this condition. We will see you in six months to follow up with this.”

Critical Thinking Question

Before

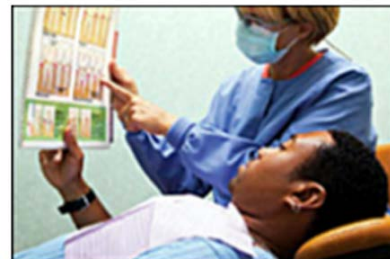

After



Our patient Patricia returns in six months with the same medical history and you compare what her teeth and gingiva look like now to the previous appointment six months ago. Tell me your assessment of her condition, by looking at her teeth and gingiva and having no other dental health data.

Case Scenario 4: Periodontal Disease



The third patient on the hygiene schedule in Dr. Jay's office is Mr. Emmett Davis. He is 46 years old and is a non-smoker. He takes HCTZ for his elevated blood pressure which is well controlled. He complains of bleeding gums, tender and loose teeth.

Dr. Jay to Mr. Davis: “Hello Emmett. Hope you are well today. Last time you were in, your gums were bleeding and swollen. Before I do an examination, I want to have your radiographs updated and have our dental hygienist, Jessica, update your health and dental information, do a thorough cleaning and review the oral hygiene procedures we need for you to follow for your home care.”

Characteristics of Periodontal Disease

Periodontal disease is an irreversible disease of the gingiva that effects the surrounding and supporting structures of the teeth. There is a loss of alveolar bone and it requires professional treatment, often by a periodontist, to preserve the tooth/teeth. Periodontal disease is classified into several different categories.

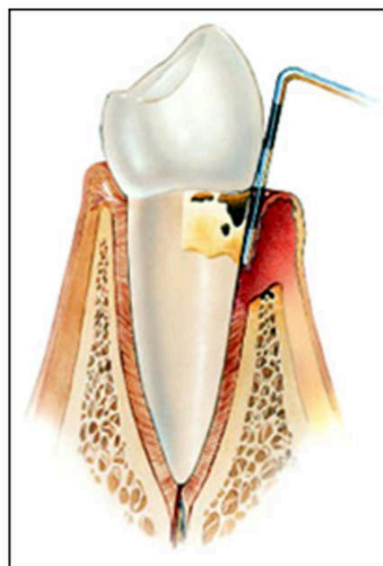
Classifications of Periodontal Diseases

Staging and Grading Periodontitis

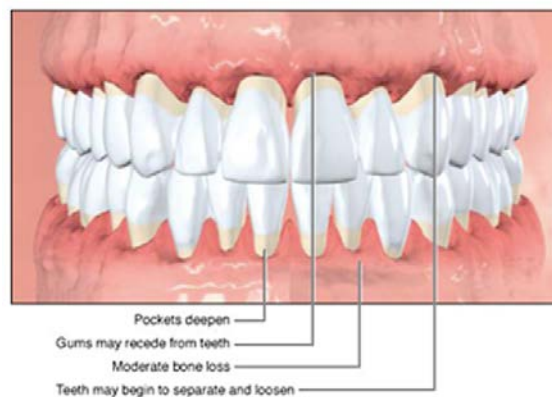
The 2017 World Workshop on the Classification of Periodontal and Peri-Implant Diseases and Conditions developed a classification of periodontitis that includes a staging and grading system. For more complete information visit the website at: perio.org/2017wwdc.

Staging looks at classifying the extent of and severity of periodontal disease in a patient. It utilizes the measurable amount of destroyed or damaged tissue due to periodontitis and to look at specific factors that can contribute to long term case management. Initially, the stage should be assessed using clinical attachment loss (CAL). If that is not available, then radiographic bone loss (RBL) can be used. Tooth loss due to periodontitis can alter the staging. If one or more complexity factors are present, then the stage may go to a higher level.^{1,2}

Grading is a process which rates the progression of periodontitis in a patient and its response to standard treatment and therapies. It also attempts to determine its effect on systemic health. When starting, the clinician should assign a grade of B disease and determine if there are factors with specific evidence in order to shift to a grade of A or C.^{1,2}



Upon performing the periodontal screening on Emmett, Jessica found that his periodontal pocket depths had increased from 2-3 mm to greater than 5 mm in most areas. Jessica completes her scaling and polishing of Emmett’s teeth and updates a plan for his oral health instructions that she will deliver to him after Dr. Jay does her clinical examination.



Dr. Jay to Mr. Davis: “Emmett, I can see from the data Jessica collected, that your periodontal pockets have increased significantly, and in looking at your radiographs, you have some bone loss. This is the reason that some of your teeth are loose and your gums are bleeding and tender. Unfortunately, your condition has progressed from gingivitis to periodontal disease (periodontitis). Have you experienced any bad breath?”

Table 1. Periodontitis: Staging.

Stage	periodontitis	Stage I	Stage II	Stage IV
Severity	Interdental CAL (at site of greatest loss)	1 – 2 mm	3 – 4 mm	≥5 mm
	RBL	Coronal third (<15%)	Coronal third (15% – 33%)	Extending to middle third of root and beyond
	Tooth Loss (due to periodontitis)	No tooth loss		≥5 teeth
Complexity	Local	<ul style="list-style-type: none"> • Max. probing depth ≤4 mm • Mostly Horizontal bone loss 	In addition to Stage II Complexity: <ul style="list-style-type: none"> • Probing depths ≥6 mm • Vertical bone loss ≥3 mm • Furcation Involvement Class II or III • Moderate ridge defects 	In addition to Stage III complexity: <ul style="list-style-type: none"> • Need for complex rehabilitatin due to: <ul style="list-style-type: none"> - Masticatory dysfunction - Secondary occlusal trauma (tooth mobility degree ≥2) - Severe ridge defects - Bite collapse, drifting, flaring - <20 remaining teeth (10 opposing pairs)
	Extent and Distribution	Add To Stage As Descriptor	For each stage, describe extent as: <ul style="list-style-type: none"> • Localized (<30% of teeth involved); • Generalized; or • Molar/incisor pattern 	

This information is from: The 2017 World Workshop on the Classification of Periodontal and Peri-Implant Diseases and Conditions was co-presented by the American Academy of Periodontology (AAP) and the European Federation of Periodontology (EFP).

Tables from Tonetti, Greenwell, Kornman. J Periodontol 2018;89 (Suppl 1): S159-S172.

Table 2. Periodontitis: Grading.

	Progression		Grade A: Slow Rate	Grade B: Moderate Rate	Grade C: Rapid Rate
Primary Criteria	Direct Evidence of Progression	Radiographic Bone Loss or CAL	No Loss Over 5 years	≥2 mm over 5 years	≥2 mm over 5 years
	Indirect Evidence of Progression	% Boss Loss/Age	<0.25	0.25 to 1	>1.0
		Case Phenotype	Heavy Biofilm Deposits with Low Levels of Destruction	Destruction commensurate with biofilm deposits	Destruction exceeds expectations given biofilm deposits; specific clinical patterns suggestive of periods of rapid progression and/or early onset disease
Grade Modifiers	Risk Factors	Smoking	Non-smoker	<10 cigarettes/day	≥10 cigarettes/day
		Diabetes	Normoglycemic/no diagnosis of diabetes	HbA1c <7.0% in patients with diabetes	HbA1c ≥7.0% in patients with diabetes

This information is from: The 2017 World Workshop on the Classification of Periodontal and Peri-Implant Diseases and Conditions was co-presented by the American Academy of Periodontology (AAP) and the European Federation of Periodontology (EFP).

Tables from Tonetti, Greenwell, Kornman. J Periodontol 2018;89 (Suppl 1): S159-S172.

Table 3. Steps in Staging and Grading a Patient.

<p>Step 1:</p> <p>Initial Case Overview to Assess Disease</p>	<p>Screen:</p> <ul style="list-style-type: none"> • Full mouth probing depths • Full mouth radiographs • Missing teeth <p>Mild to moderate periodontitis will typically be either Stage III or Stage II Severe to very severe periodontitis will typically be either Stage III or Stage IV</p>
<p>Step 2:</p> <p>Establish Stage</p>	<p>For mild to moderate periodontitis (typically Stage I or Stage II):</p> <ul style="list-style-type: none"> • Confirm clinical attachment loss (CAL) • Rule out non-periodontitis causes of CAL (e.g., cervical restorations or caries, root fractures, CAL due to traumatic causes) • Determine maximum CAL or radiographic bone loss (RBL) • Confirm RBL patterns <p>For moderate to severe periodontitis (typically Stage III or Stage IV):</p> <ul style="list-style-type: none"> • Determine maximum CAL or RBL • Confirm RBL patterns • Assess tooth loss due to periodontitis • Evaluate case complexity factors
<p>Step 3:</p> <p>Establish Grade</p>	<ul style="list-style-type: none"> • Calculate RBL (% of root length x 100) divided by age • Assess risk factors (e.g., smoking, diabetes) • Measure response to scaling and root planing and plaque control • Assess expected rate of bone loss • Conduct detailed risk assessment • Account for medical and systemic inflammatory considerations

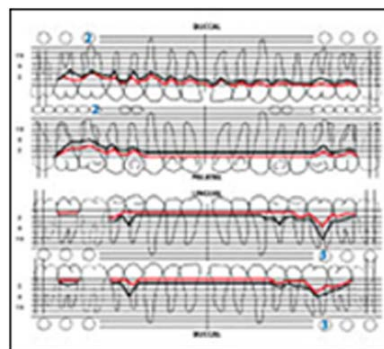
Mr. Davis to Dr. Jay: “Well, yes I have. I just thought it might be something I was eating.”

Dr. Jay to Mr. Davis: “Actually, bad breath can also be a sign of periodontal disease.”

Causes, Treatment and Prevention

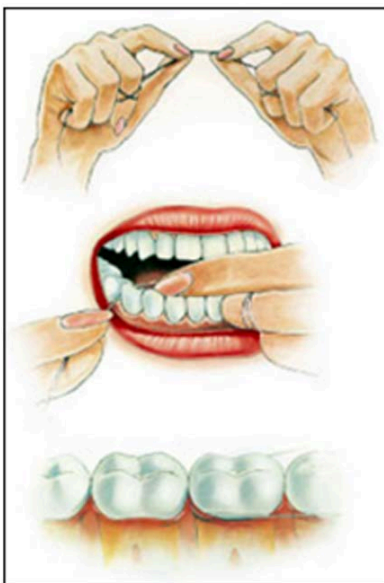
The presence of gram-negative bacteria, such as *Porphyromonas gingivalis*, is one of the identifying factors in periodontal disease, however there are several risk factors to consider. Poor oral hygiene plays a significant role in the development and progression of periodontal disease, but there are also links between oral health and systemic health. For example, there are cases of bacterial infections (such as bacterial endocarditis) caused by transmission of bacteria into the bloodstream during dental procedures. There are also

conditions that can affect oral health, such as pregnancy gingivitis/pyogenic granuloma and diabetes related problems. In addition, there is evidence-based research that shows a link between family history and periodontal disease markers. It is just as important to identify risk factors, as precursors to developing periodontal disease, as it is to treat active disease.

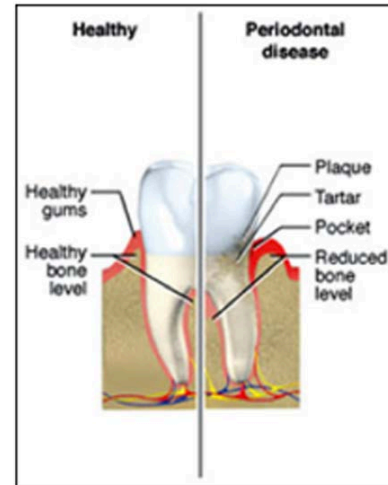


Treatment for periodontal disease must be individualized for each patient. To track the progress of patients, data is collected and compared during appointments. A specialized periodontal chart allows dental professions to record this data for easy comparison.

There are different types of treatment available for the periodontal patient depending on the severity of the disease and how rapidly it is progressing. There are two types of therapy for periodontal disease: non-surgical therapy (may be referred to as initial therapy), and surgical therapy (which includes such things as grafts, flaps and other surgical procedures). Initial therapy for most patients includes scaling and root planing as well as antimicrobial therapy. This type of therapy is similar in some ways to the oral prophylaxis, but that procedure is preventive and initial therapy is meant to be therapeutic. In scaling and root planing all the calculus is removed and the periodontal pocket is debrided from all deposits and the root surface is smoothed to provide less of an area for attachment of bacteria. Often antimicrobial therapy can be placed in the pocket in hopes of regenerating the attachment of the tissue in the pocket at a higher level and thus decreasing its depth. Nonsurgical procedures are minimally invasive and many times can control the periodontal disease process. Often, local anesthetic to numb the area is required.



Jessica to Mr. Davis: "We have gone over the brushing routine I would like for you to follow, but I want to emphasize flossing. One of the reasons periodontal treatment fails and people lose their teeth is not following through on thorough flossing. Be sure you are following the procedure of wrapping the floss around the tooth in a C shape and cleaning all interproximal surface as deep as you can."



Dr. Jay to Mr. Davis: "Emmett, since your periodontal disease has progressed, I will be referring you to a periodontist for treatment. Jessica gave you specific oral hygiene instructions about your condition and this brochure is for you to keep. It shows the difference between a healthy mouth and one with periodontal disease. As you can see, in a healthy mouth, the supporting bone level is high and the gum pockets are not very deep. Usually there is very little plaque or calculus. Poor oral hygiene habits cause plaque and calculus to accumulate, and the periodontal disease process begins. Bacterial infection causes the gum pockets to become inflamed, as they were on your last visit. Over time, the tissue begins to atrophy, gums recede, gingival pockets deepen, and the levels of supporting bone decrease. This is why some of your teeth are loose. If untreated, these teeth and others may fall out."

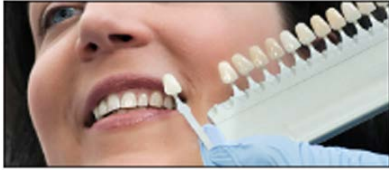Critical Thinking Question

Mr. Davis is seen by a periodontist. Over the next year, he has initial therapy, antimicrobial therapy and surgical therapy. What concerns do you have over Mr. Davis' success in his periodontal treatment? Why?

Case Scenario 5: Restorative and Esthetic Dentistry

During the morning huddle, Nikki, the certified dental assistant in Dr. Jay's practice, reviews the daily patients that are scheduled and what their specific needs are.

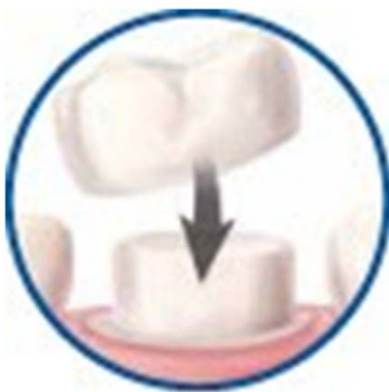Amalgam and Composite Restorations



Amalgam restorations are very strong and typically last for a long period of time. They are only used in the posterior because they are not as esthetically pleasing as a tooth colored restoration, like a composite or veneer. The composite and veneer match the color of the natural teeth but some of them may not be as durable as the amalgam.

Nikki to Group: "Our first patient is Mr. Brian Smith. He has scheduled an amalgam procedure on tooth #3. We explained to him that this would be the strongest type of restoration for that area. He was pleased with that, although he was concerned about the look of a "silver" filling. He also will be having a composite restoration in the anterior on #8."

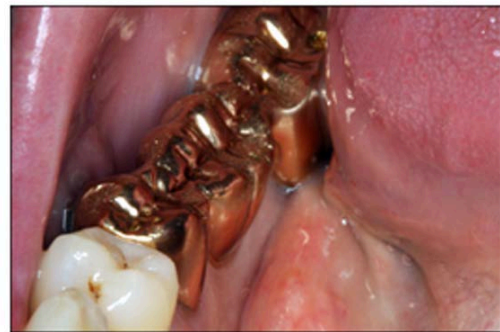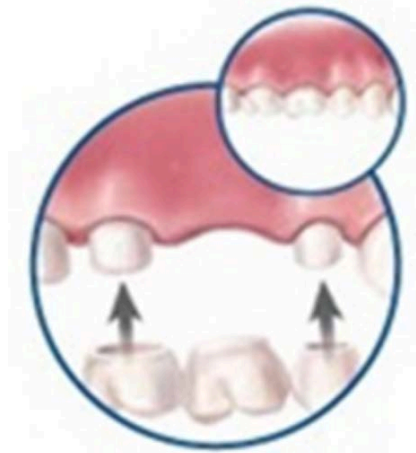
Crowns and Bridges



Typically, dental crowns cover a single tooth that has lost most of its surface due to extensive decay, breakage or root canal therapy. Teeth become brittle and break easily

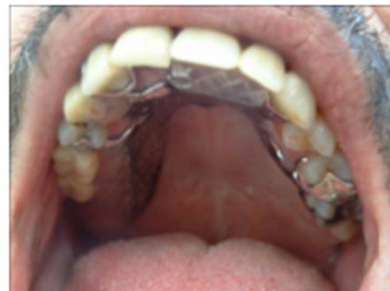after root canal therapy. A bridge can replace a single, or multiple teeth that have been lost.

The pontic or false tooth is connected together and anchored on abutment teeth. Crowns and bridges are usually made of gold or porcelain fused to metal.



Nikki to Group: "Our second patient, Ms. Jackie Black, is scheduled for the delivery of a bridge to replace tooth #10. We also need to talk about the full porcelain fused to metal (PFM) crown she will be having placed on #23."

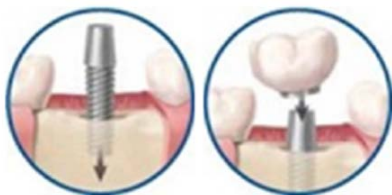Dentures



Both full and partial dentures are made to replace missing teeth and are removable; not a fixed restoration like a bridge or implant.

Nikki to Group: “Our first patient after lunch, will be Mr. Blaine White. We will be delivering a partial denture. Unfortunately, he lost several of his teeth to periodontal disease.”

Implants

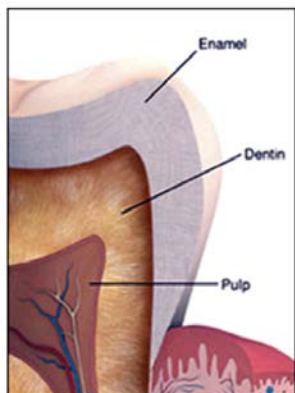


Dental implants are designed to replace missing teeth and restore full function to the area. Implants are held in place by an anchor in the bone and then the crown is screwed into the anchor. Implants can be used to replace a single tooth, multiple teeth or an entire arch.

Nikki to Group: “Our second patient after lunch is Ms. Jacqui Brown. She would like to discuss the possibility of getting an implant to replace her missing #3. Dr. Jay thinks she will be a good candidate for this, and we will probably refer her to a periodontist to do this since she will need a sinus lift in that area as well.”

Tooth Whitening

Tooth color is determined by several factors. Both the enamel and the dentin play roles in the determination of what color is seen in the oral cavity. Both the enamel and the dentin are formed by millions of tiny crystals in a lipid/protein matrix.



As stated earlier, enamel is the hardest substance in the body. The thickness of healthy enamel varies by tooth. Enamel is thinnest on incisors (about 2 mm) and thickest on molars (2.5 to 3 mm).

It is composed primarily (about 95%) of calcium phosphate molecules that are packed so tightly together that they are known as apatite crystals. Apatite crystals have often been called hydroxyapatite, which means it has attached oxygen and hydrogen groups, however pure hydroxyapatite does not really exist. Tooth mineral is more like a contaminated carbonated hydroxyapatite.

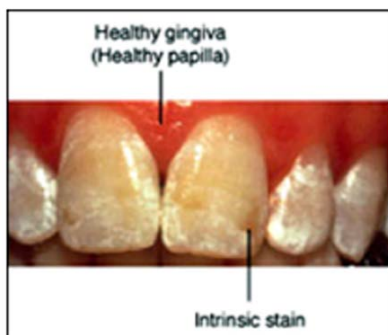If fluoride ions replace some of the oxygen and hydrogen ions in the crystal, it becomes fluorapatite. Fluorapatite forms a stronger crystalline lattice and is more resistant to acid attack.

All these crystals in the matrix line up into a cluster that is perpendicular to the tooth surface and are known as enamel rods. There are tiny spaces between the crystals and fluids fill the spaces (protein, lipids and water) between the rods. Although these spaces are too small for bacteria to enter, other ions such as oxygen, hydrogen, fluoride, and calcium phosphate can enter. If the enamel is demineralized, it provides a more porous area for the carious process.

The natural color of the teeth comes from both the enamel and the underlining dentin. This color can range from a yellowish white to grey. The color of the dentin is a major contributor to overall tooth color. Genetically determined, dentin color ranges from yellowish white to grayish white.

Dentin is the largest tooth structure. It is calcified with tubules filled with plasma-like fluid, much like the enamel. As a living tissue, dentin conducts thermal sensitivity and pain from enamel to the nerve root, resulting in hypersensitivity.

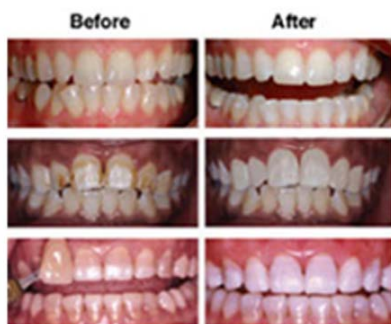Changes in tooth color can occur through several different means. They can be extrinsic or exogenous due to things such as food, drinks, tobacco and drugs. They usually adhere to the tooth deposits but can also adhere to the tooth structure itself.



Intrinsic, or endogenous stains can also cause color changes within the tooth. These include staining from aging, oral disease, trauma, medications, systemic conditions, and heredity.

As teeth grow older, the pulp shrinks and the dentin becomes thicker, which can cause teeth to look more yellow. Oral diseases, such as exposed root surfaces from gingival recession or restorations, also affect tooth color.

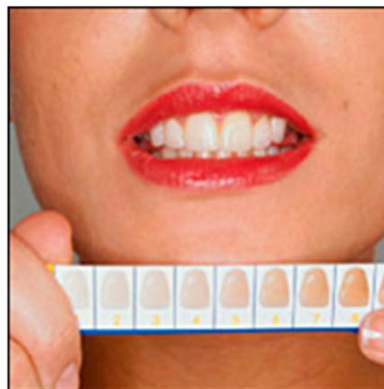During trauma, vital pulp tissue can die. If trauma does not destroy the tooth, bleeding into tooth structures can occur causing darkening over time. Enamel defects can result from trauma during tooth formation or inherited dental disorders, such as amelogenesis imperfecta.



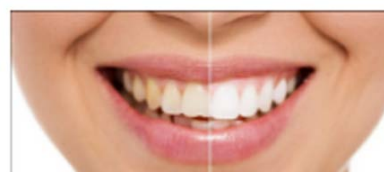Medications taken during tooth formation can result in enamel defects. A common cause is the antibiotic tetracycline. Fluorosis, or excess fluoride consumption, can also cause mottled and spotted teeth, as shown here.

Nikki to Group: "Our last patient of the day is Ms. Daniella Johnson. Ms. Johnson has both

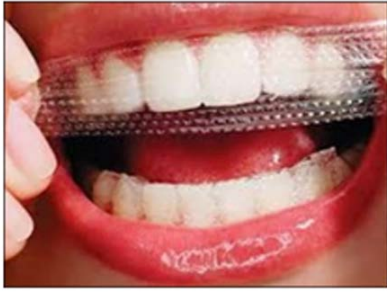intrinsic and extrinsic staining on her teeth. She will be on the hygiene schedule but also would like to talk about the possibility of using a whitening product or having in-office whitening. Jessica will discuss some of the options with her and then she will see Dr. Jay to discuss what she wants to do."



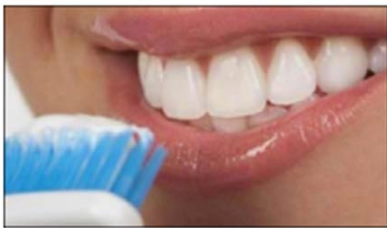Jessica to Daniella: "Daniella, I understand that you are interested in tooth whitening or bleaching. After we complete your cleaning appointment and see what stains remain afterwards, we will discuss the various options and take a look at your tooth color by matching it to a chart and then determine what method is the most appropriate for you. Then Dr. Jay will come in to do the exam and discuss her recommendation with you."



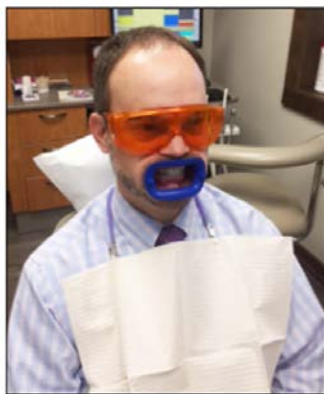Dr. Jay to Daniella: "Your teeth have mostly superficial or extrinsic stains. The tooth whitening procedures available to you will remove the stains on your teeth, leaving them potentially up to five to ten shades whiter. However, we don't know exactly how your teeth will respond to treatment. These before and after photos will give you a better idea of the results that you might expect. Because you are a coffee drinker, you should be aware that whitening will not prevent future staining."



Dr. Jay to Daniella: “There is a spectrum of options for extrinsic stain removal that range from short- to long-term and from low to high efficacy. Some of these you can perform at home, while others are performed here in the office.”



There are several means of removing extrinsic stains at home, such as using a whitening toothpaste or whitening mouth rinse along with the oral prophylaxis in the dental office. Tooth enamel can be further whitened by chemical tooth bleaching using gel trays. This can be done at home over a series of weeks to months. You can also use whitening strips or whitening emulsions (which can also utilize LED lights for enhanced effectiveness) at home, which typically require less time than gel trays and can get similar results. Sometimes bleaching procedures can cause tooth sensitivity. This will usually resolve when you discontinue the bleaching process. A toothpaste to relieve sensitivity may also be helpful.



In-office bleaching usually is done in a separate appointment where the teeth are isolated and a bleaching material is applied. The bleaching effect may be enhanced through the use of a laser or special light.

Critical Thinking Question

Upon examining Daniella’s mouth, Jessica sees that her central incisors have permanent crowns. What considerations would you have in recommending whitening procedures to Daniella?

Glossary of Terms

A-C

abutment teeth – The natural teeth that have been prepared to hold the attachment crowns for a bridge.

acidulated phosphate fluoride – Also known as APF. It works on demineralization of enamel to help it re-mineralize faster by the absorption of fluoride ions. It cannot be used on surfaces that have glass ionomer restorations or any restoration containing glass particles. It has a pH of 3 to 4 and can dissolve glass.

alveolar process – Bone that covers the maxilla and mandible.

amalgam – An alloy that contains mercury, silver and other metals and is used as a posterior restoration.

anterior – Toward the midline or in the front of the mouth. The teeth from the canines forward are considered anterior teeth.

anterior teeth – Teeth from the canines forward.

antimicrobial therapy (Periodontal) – Use of a substance that will kill or inhibit the growth of bacteria. Often, in the oral cavity, this is a solution or gel that is placed in the periodontal pocket.

bridge – A non-removable restoration that replaces a missing tooth or teeth. It is made of either gold or porcelain.

buccal – The tooth surface that is toward the cheeks or face.

calculus – Hard, mineral deposits that form on the teeth. This is what is removed during the scaling process.

canines – The teeth that form the corners of the mouth. These teeth have the longest roots of any tooth type.

caries – Commonly known as cavities or tooth decay.

carious lesion – A single area of tooth decay.

cementum – The substance that covers the outside of the root of the tooth.

composite – One of the materials that can be used for a tooth colored restoration. It is typically made of a resin material.

crown – The portion of the tooth that is covered in enamel. This is the portion of the tooth we see in the oral cavity.

crown (restoration) – A non-removable permanent restoration for a single tooth. This restoration is usually made of either gold or porcelain.

D-F

demineralization – The first breakdown of the enamel surface, usually due to acid attack in the decay process.

dental assistant (CDA) – The dental professional that may be responsible for a variety of duties which may include assisting in restorative or preventive procedures, oral hygiene instructions, and exposing radiographs. A CDA (Certified Dental Assistant) is a dental assistant who has completed a program of study and passed a national certification exam and continues to update their dental education on a specified basis.

dental hygienist (RDH) – The licensed, dental professional that is responsible for the preventive area of the practice. This person has completed at least a two-year accredited program of study and has passed both national and regional board examinations. They must maintain their license usually through continuing education.

dental laboratory technician (DLT) – This dental professional is usually employed in a dental laboratory and is responsible for making both fixed and removable dental appliances that are then delivered to the patient in a dental office. This includes crowns, bridges and dentures. The DLT may complete a two-year program of study.

dental public health – One of the nine recognized dental specialties by the American Dental Association. This specialty concentrates on the promotion of dental health for the public through a variety of means such as public health dental clinics and access to dental care for all populations.

dentin – The tooth structure that is directly below the enamel in the crown of the tooth and the cementum in the root of the tooth. It lies between the enamel and cementum and the pulp. It is much softer than enamel or cementum.

dentist (DDS or DMD) – The licensed dental professional that is responsible for the diagnosis, prevention and treatment of dental disease. This person must complete at least 4 years of professional school after college and pass both national and state/regional examinations to become licensed to practice dentistry. They must maintain their license usually through continuing education.

disclosing agent – This is usually a chewable tablet, or a liquid form (that can be painted on teeth), that stains dental plaque making it visible to the eye.

distal – The surface that is away from the midline or front of the oral cavity.

edematous – Swollen or has edema.

enamel – The hardest substance in the body. Enamel covers the crown of the tooth.

endodontics – This is the recognized specialty in dentistry that deals with root canal therapy and infections of the teeth. A dentist who specializes in this area has three more years of education beyond dental school) and are known as Endodontists.

eruption – Teeth coming through the gingiva.

erythemic – Redness of tissue. This is usually a sign of inflammation.

exfoliation – The loss of teeth. Primary teeth exfoliate as the permanent erupt.

expectorate – To spit.

extrinsic stain (exogenous) – Stain on the tooth surface, caused by coffee, tea, or smoking. Extrinsic stains usually can be removed during the oral prophylaxis by scaling and polishing the teeth. Some toothpastes can also help with minor stains.

facial – The surface toward the cheek or face and lips.

fluorapatite – Improved crystals (due to the incorporation of fluoride ions) within the matrix of the tooth enamel which makes the enamel more resistant to tooth decay.

fluoridation (fluoridated water) – Adding a small percentage of fluoride to water systems to strengthen teeth against tooth decay. This has been named as one of the best public health measures in history.

fluoride – A naturally occurring element. It can provide decay inhibiting factors to the smooth surfaces of the teeth.

fluoride varnish – A type of topical fluoride that is painted on the teeth and provides decay prevention.

fluorosis – An intrinsic stain in the teeth that can come from over exposure to systemic fluoride. This can come from swallowing fluoridated toothpaste on a regular basis as a child or drinking water that has a high concentration of fluoride (usually naturally occurring fluoride in the well water) as a child.

full denture – Also known as “false teeth.” The denture replaces a full arch of teeth that are lost and is a removable appliance.

full mouth series (FMX) – X-rays, or radiographic images, that are taken of all the teeth in the oral cavity. For people that have all their teeth, this could be somewhere between 18 and 22 individual projections.

G-I

general dental practice – This is the type of dental practice that most patients seek to provide for their basic preventive and restorative needs.

gingiva – Also known as the gums.

gingival margin – The edge of the gingiva that touches the tooth. It is usually right at the crown of the tooth.

gingival recession – Sometime due to disease processes or aggressive brushing. The gingiva recedes from the crown of the tooth and portions of the root can be seen.

gingival sulcus – A small ditch-like area between the tooth and gingiva that surrounds the entire tooth. It is only attached to the tooth at its base. It is normally between 1 and 3 mm deep.

gingivitis – An inflammation of the gingiva usually due to retention of plaque/biofilm in the area caused by poor oral hygiene.

hydroxyapatite – What the dental profession refers to as the tooth mineral.

hypersensitivity – Extreme sensitivity (usually pain) in the teeth, often due to hot, cold or sweet exposure.

implant – Permanent replacement appliance in the oral cavity for a single tooth, multiple teeth or a whole arch. It is composed of an implanted base onto which a crown, bridge or full denture is permanently attached.

in vitro – Laboratory tests that are performed outside of the living organism. It is usually done in a test tube or culture dish.

in vivo – Tests that are performed inside a living organism, such as in a human.

incisal edge – The biting edge of anterior teeth.

incisors – The four anterior teeth on both the maxilla and mandible. There are two on either side of the midline.

inflammation – The body's immune response to harmful stimuli. The signs of inflammation are pain, swelling, redness and heat in the tissue.

interdental papillae – The gingiva tissue in between each tooth. It typically fills the area between the adjacent teeth and prevents food impaction.

interproximal – The area between two adjacent teeth.

intrinsic stain (endogenous) – Stain that is incorporated within the tooth structure. It can be due to drugs, hyper-fluoridation, genetics or illness during the formation of the permanent teeth.

L-O

labial – Surfaces towards the lips.

lingual – Surfaces that are towards the tongue.

mandibular teeth – The bottom teeth.

maxillary teeth – The top teeth.

mesial – Surfaces of the tooth that are toward the midline of the face.

midline – The imaginary line that goes vertically down the middle of the face between the two central incisors.

molars – The most posterior teeth that are responsible for grinding food. In the permanent dentition, there are 12 molars (three in each quadrant). The primary dentition has 8 molars (two in each quadrant).

monofluorophosphate – A type of fluoride that is used in some toothpastes.

neutral sodium fluoride – A type of fluoride that is used in many dental offices to prevent decay. It has a neutral pH and, unlike APF, can

be used on patients that have glass ionomer, or other restorations that contain glass, without harm to the restorations.

non-surgical therapy (periodontal) – Periodontal scaling and root planing, and sometimes includes antimicrobial therapy.

occlusal surfaces – The chewing surfaces of the posterior teeth.

occlusion – The relationship between the maxillary and mandibular teeth when they bite together.

oral and maxillofacial pathology – The recognized dental specialty that involves pathological problems in the oral cavity. These specialists are known as Oral Pathologists and have at least three years of education beyond dental school in the area of oral pathology.

oral and maxillofacial radiology – The recognized dental specialty that involves radiology and diagnosis using radiographic procedures. These specialists are known as Oral Radiologists and have at least three years of education in oral and maxillofacial radiology beyond dental school.

oral cancer – Cancer found in the oral cavity and/or the surrounding and supporting structures.

oral cancer screening – The method employed by dentists and dental hygienists to observe and palpate areas within and around the mouth, face, head and neck to look for any abnormalities that might lead to cancer or any other disease entities.

oral maxillofacial surgery – The recognized dental specialty that involves surgery of the head, neck and mouth. These specialists are known as Oral Surgeons and have at least three years of additional education beyond dental school.

oral prophylaxis – Cleaning teeth, which includes scaling and polishing teeth. This procedure can only be done by the dentist or the dental hygienist in the dental office.

oral screening – Term often used to designate a brief examination of the teeth and their surrounding structures to determine if there is disease or carious lesions present.

orthodontics and dentofacial orthopedics – The recognized dental specialty that involves diagnosis and treatment of mal-aligned teeth and treatment of deformities of the mouth and face. These specialists are known as Orthodontists and have at least three years of education beyond dental school.

P-R

panoramic image – A single radiographic image that takes an image of the entire maxillary and mandibular areas. It is used to primarily look at areas such as third molars and abnormalities of the bone surrounding the teeth.

partial denture – A removable appliance for the oral cavity to replace multiple teeth. It uses bars and wires to attach to remaining teeth for stability.

pediatric dentistry – The recognized dental specialty dealing with children, adolescents and special needs children. These dentists are known as Pedodontists or Pediatric Dentists. This specialty requires at least three years of education beyond dental school.

periodontal chart – A specialized chart that allows the dental professional to record such things as probing readings, clinical attachment levels, and bone levels for comparison at each clinical visit to determine presence or progression of any disease or inflammation.

periodontal disease – An oral disease that causes inflammation and bone loss around the teeth. It can be a single tooth, several teeth or through-out the oral cavity. Oral bacteria and genetics play a strong role in this disease development and progression.

periodontal ligaments – Tiny fibers that attach the cementum of the tooth to the surrounding bone.

periodontal screening – An examination procedure that looks at oral tissue health and

periodontal pocket depths to determine if periodontal disease is present or if the patient is at risk for it.

periodontics – The recognized dental specialty dealing with the periodontium and its diseases and treatments. This specialty requires at least three years of education beyond dental school and the specialists are referred to as Periodontists.

periodontium – The surrounding and supporting structures of the teeth.

permanent dentition – The teeth that erupt when the primary teeth are lost. There are 32 teeth in the permanent dentition.

pit and fissure sealants – A resin material that is painted on the pit and fissures of the teeth to provide a barrier to decay.

plaque/biofilm – Bacteria that are in a protective layer that will adhere to the teeth. If they contain a significant number of certain types of bacteria, they contribute to producing demineralization of teeth and ultimately tooth decay.

porcelain fused to metal (PFM) crown – A type of permanent crown that is tooth colored, esthetically pleasing, and is very strong since it has a metal base, covered in porcelain.

posterior teeth – The back teeth. Teeth that are behind the canines are considered posterior teeth.

primary dentition – Often referred to as “baby teeth.” This is the first set of teeth that erupt. There are 20 primary teeth.

prosthodontics – This recognized dental specialty is mainly concerned with replacement of missing teeth (crowns, bridges, full and partial dentures). The specialists are known as Prosthodontists and require at least three years of education beyond dental school.

premolars – The teeth that are located between the canines and the molars in the permanent dentition.

proximal – Surface that is next to another surface, beside.

pulp – The center part of the tooth that contains the blood vessels and nerves.

quadrants – The mouth is divided into four quadrants (upper right, lower right, upper left, lower left).

radiographs – X-rays or radiographic images.

root – The lower portion of the tooth which is typically not visible when looking in the oral cavity. The tooth is made of the crown (above the gingiva) and the root (below the gingiva).

root canal therapy – The process of removing diseased pulp from the tooth and replacing it with a filling material to preserve a tooth.

root planing – Removing deposits from root surfaces and smoothing them using an instrument called a curette or an ultrasonic instrument. Typically, this is done by either a dentist or dental hygienist during initial periodontal therapy.

S-Z

scaling – Removing deposits from the teeth using scaling or ultrasonic instruments. Typically, this is done by the dental hygienist.

sinus lift – A process usually done in the placement of a dental implant in the maxillary posterior area where the sinus has dropped down into the space previous occupied by the lost tooth. An instrument is used to inject bone and subsequently lift the sinus up to provide enough bone in the area to place the implant.

stannous fluoride – A type of fluoride that is used in some toothpastes and mouth rinses.

stippled – Pebbly look. Looks like orange peel texture.

subgingival – Below the gingival margin.

sulcus – A ditch like area between the gingival margin and the base of the pocket that is not attached to the tooth.

sulcular – Within the sulcus.

supragingival – Above the gingival margin.

surgical therapy (periodontal) – Treatment for periodontal disease which can include, but is not limited to creating a flap in the gingiva to expose the root and bone around the tooth to remove diseased tissues. It can also include removing gingiva tissues.

tooth whitening (bleaching) – Use of hydrogen or carbamide peroxides to penetrate the enamel rods and bleach out stains in the teeth. This can be done with in-home products or in the dental office (often enhanced with stronger solutions and lasers or lights).

veneer – An esthetic restoration that covers the facial portion of the tooth.

white spot lesion – The first step in the demineralization of the enamel in the decay process. At this point, the lesion can be re-mineralized and the decay process stopped through means such as fluoride treatments.

wisdom teeth – Third molars.

Course Test Preview

To receive Continuing Education credit for this course, you must complete the online test. Please go to: www.dentalcare.com/en-us/professional-education/ce-courses/ce542/test

- 1. The area where two teeth are touching is known as the _____ surface.**
 - A. Abutment
 - B. Proximal
 - C. Central
 - D. Lingual
- 2. The surface of the teeth that is referred to as the cheek side.**
 - A. Buccal
 - B. Lingual
 - C. Occlusal
 - D. Proximal
- 3. How many teeth are in the primary dentition?**
 - A. 25
 - B. 32
 - C. 20
 - D. 10
- 4. The relationship between the maxillary and mandibular teeth, when the teeth are touching and the mouth is gently closed, is known as what?**
 - A. Occlusion
 - B. Abutment
 - C. Facial alignment
 - D. Sulcus measurement
- 5. Which teeth are responsible for tearing food?**
 - A. Molars
 - B. Premolars
 - C. Incisors
 - D. Canines
- 6. If a demineralization area (white spot lesion) on the enamel of a tooth is not treated, it will develop into a cavity.**
 - A. True
 - B. False
- 7. Which of the following involves only gum tissue and not bone loss around the tooth?**
 - A. Periodontitis
 - B. Gingivitis
 - C. Osteoarthritis
 - D. Osteonecrosis
- 8. Periodontal disease is irreversible and involves bone loss around the tooth.**
 - A. True
 - B. False

- 9. Initial periodontal therapy does not include which of the following procedures?**
- A. Scaling
 - B. Root planing
 - C. Antimicrobial therapy
 - D. Restorations
- 10. Which of the following does not contribute to extrinsic stains on the teeth?**
- A. Food
 - B. Wine
 - C. Tea
 - D. Toothpaste
- 11. What are the tiny bundle of fibers that hold the tooth in the socket?**
- A. Periodontal ligaments
 - B. Periodontal implants
 - C. Periodontal muscles
 - D. Bony fibers
- 12. The space between the gingiva and the tooth that is not attached to the tooth is called?**
- A. Alveolar bone
 - B. Sulcus
 - C. Periodontal ligament
 - D. Gingival margin
- 13. Which are clinical signs of gingivitis?**
- A. Radiographic evidence of bone loss, inflammation, sulcus depth of 3mm.
 - B. No radiographic evidence of bone loss but visible evidence of inflammation and slight sulcus depth.
 - C. Radiographic evidence of bone loss, bleeding, sulcus depth >4mm.
 - D. No radiographic evidence of bone loss.
- 14. Culturing bacteria from the oral cavity in a dish in the laboratory is an example of what type of study?**
- A. In vivo
 - B. In vitro
 - C. In situ
 - D. En vive
- 15. Which of the following restorations is the strongest?**
- A. Veneer
 - B. Composite
 - C. Amalgam
 - D. Plastic
- 16. Bridges can be made of gold or porcelain and are connected to what?**
- A. Gingiva
 - B. Bone
 - C. Abutment teeth
 - D. They need no connection.

- 17. Which of the following crystals are the most resistant to demineralization and decay?**
- A. Hydroxyapatite
 - B. Fluoroapatite
 - C. Calcium apatite
 - D. Lipid apatite
- 18. Tooth whitening or bleaching cannot be accomplished through which of the following method(s)?**
- A. At home whitening strips
 - B. At home bleaching trays and gel
 - C. In office bleaching with lights or lasers
 - D. Whitening chewing gum
- 19. Which clinical signs are associated with periodontitis?**
- A. Bleeding, sulcus depth of <2mm, halitosis
 - B. Painful gums, bleeding, sulci <3mm
 - C. Bleeding, attachment loss, sulcus depth of >4mm
 - D. Bleeding, sulcus depth of <4mm
- 20. Starting anterior and moving posterior, which order of teeth is correct?**
- A. Molar, premolar, bicuspid, canine
 - B. Third molar, premolar, canine central incisor
 - C. Central incisor, premolar, canine, molar, third molar
 - D. Incisor, canine, premolar, molar
- 21. Primary dentition does not include which type of tooth?**
- A. Molar
 - B. Premolar
 - C. Canine
 - D. Lateral incisor
- 22. Which tooth surface is closest to the midline?**
- A. Mesial
 - B. Labial
 - C. Proximal
 - D. Buccal
- 23. Which tooth surface of the anterior teeth is nearest the lips?**
- A. Mesial
 - B. Labial
 - C. Proximal
 - D. Buccal
- 24. Which tooth surface of the posterior teeth is closest to the cheek?**
- A. Mesial
 - B. Labial
 - C. Proximal
 - D. Buccal

- 25. There are several types of fluoride used in the dental office. Which of the following is not a type of fluoride product typically used in the dental office?**
- A. Fluoride varnish
 - B. Acidulated phosphate
 - C. Neutral sodium
 - D. Hydrogen peroxide

References

1. Tonetti MS, Greenwell H, Kornman KS. Staging and grading of periodontitis: Framework and proposal of a new classification and case definition. *J Periodontol*. 2018 Jun;89 Suppl 1:S159-S172. doi: 10.1002/JPER.18-0006. Erratum in: *J Periodontol*. 2018 Dec;89(12):1475.
2. American Academy of Periodontology. Proceedings from the 2017 World Workshop on the Classification of Periodontal and Peri-Implant Diseases and Conditions. Accessed April 22, 2021.
3. Sweeting LA, Davis K, Cobb CM. Periodontal Treatment Protocol (PTP) for the general dental practice. *J Dent Hyg*. 2008 Oct;82 Suppl 3:16-26. Epub 2008 Oct 1.
4. Daniel SJ, Harfst SA, Wilder RS. *Mosby's Dental Hygiene Concepts, Cases and Competencies*. 2nd ed. St. Louis, MO. Mosby/Elsevier. 2008.
5. Dofka CM. *Dental Terminology*. 3rd ed. Delmar Thompson Learning. Clinton Park, NY 2013.

Additional Resources

- No Additional Resources Available

About the Author

Vickie Parrish Foster, RDH, MEd



Vickie previously served as the Director of the Undergraduate Dental Hygiene program and as an associate professor in the Department of Dental Ecology at the UNC Adam's School of Dentistry in Chapel Hill for 32 years. On January 1, 2015, she retired after 40 years in the dental hygiene profession. She received her AAS in dental hygiene from Guilford Technical Community College in Greensboro, NC, her BS in dental auxiliary teacher education at UNC Chapel Hill in 1981 and a master's degree in adult and higher education at UNC Chapel Hill in 1983. While at UNC her teaching responsibilities included clinical dental radiology, dental materials, clinical dental hygiene and community dental health. She has presented continuing education courses at the local, state, national and international levels for many years and co-authored a radiology textbook in 1993. Previously, she served on the editorial board for the *Journal of Dental Hygiene*. She also authored the website review column in the *International Journal of Dental Hygiene* for many years.

Email: voverman@ad.unc.edu