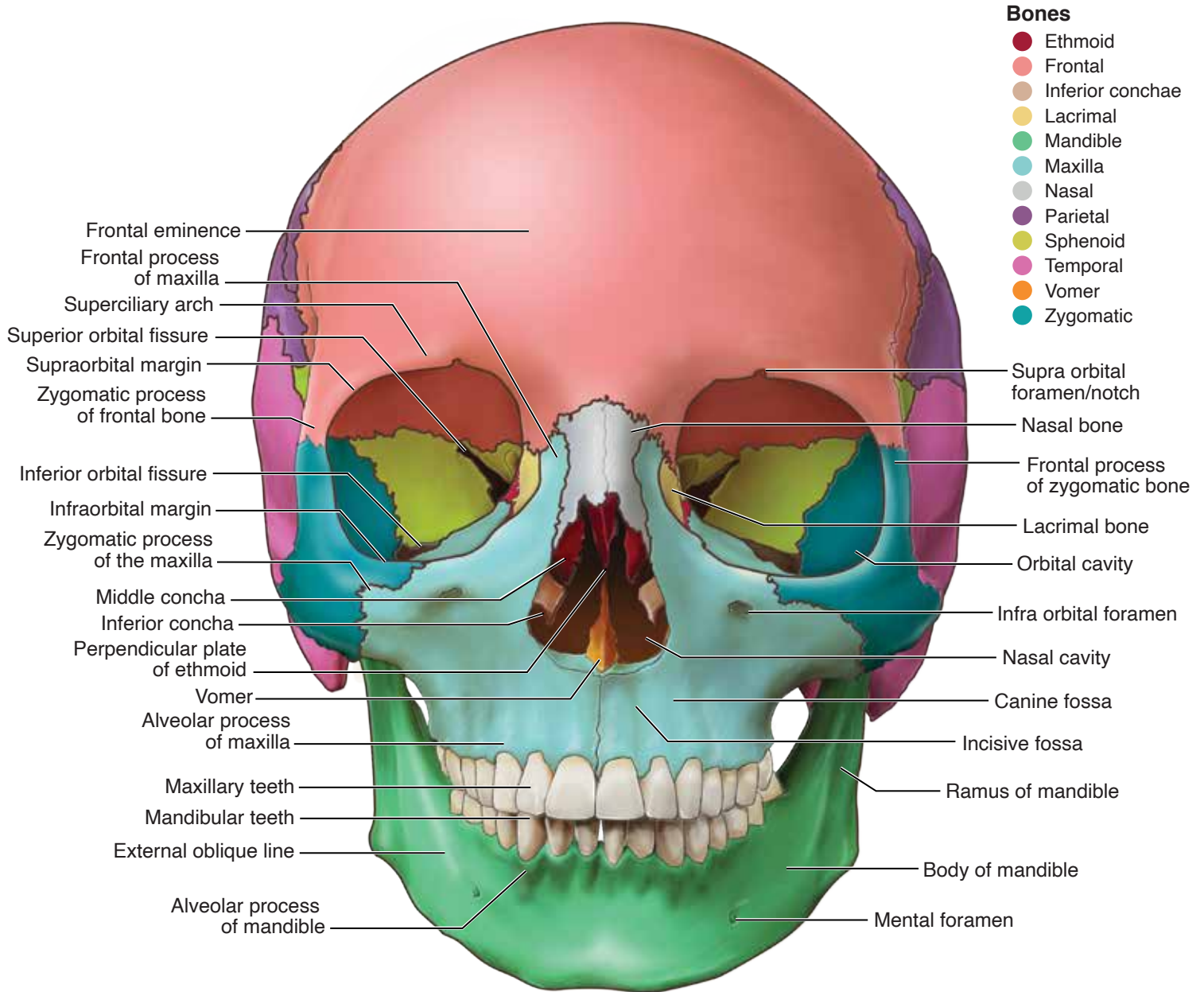
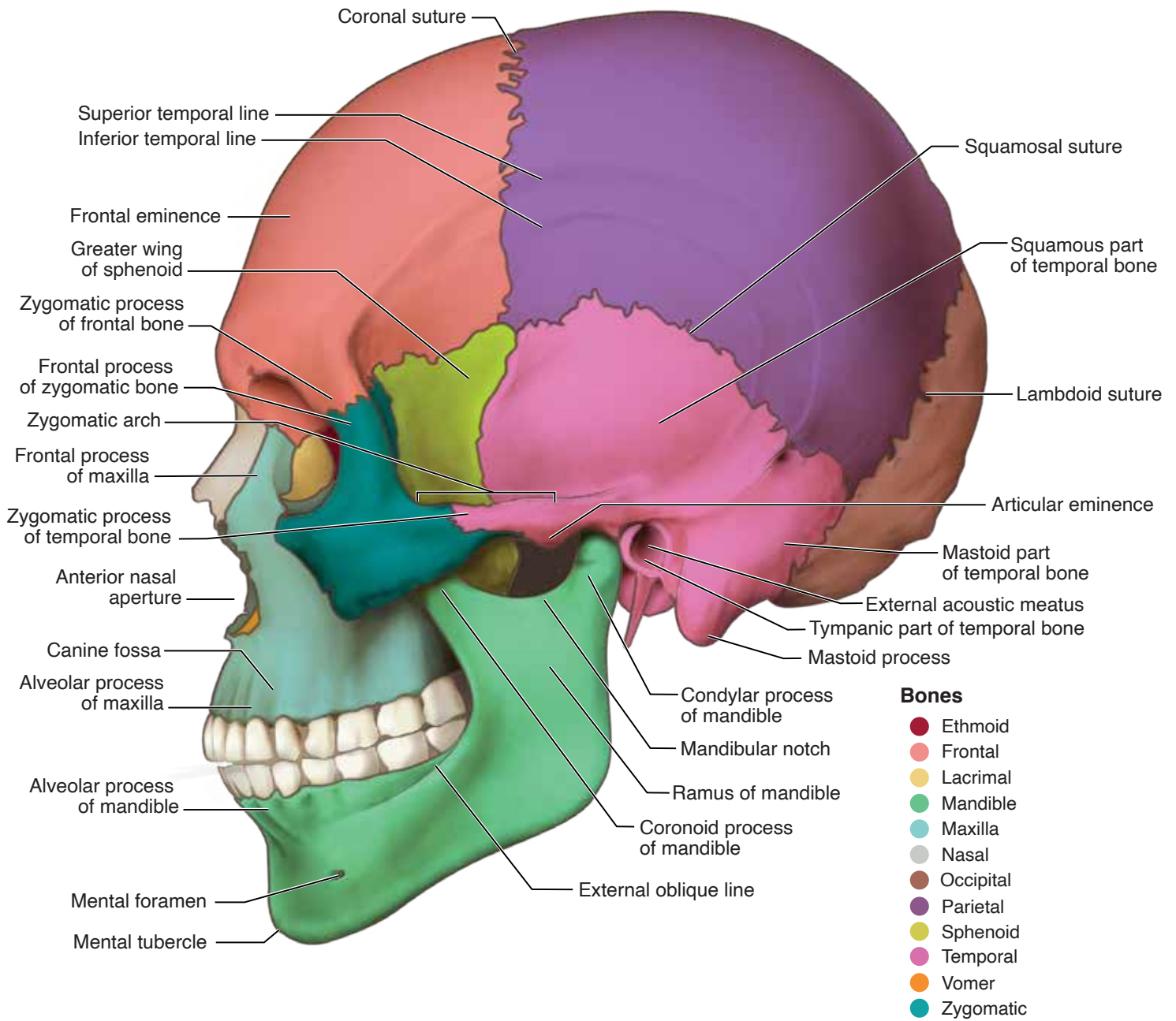


Head and Neck Anatomy: Part I – Bony Structures (ce591)

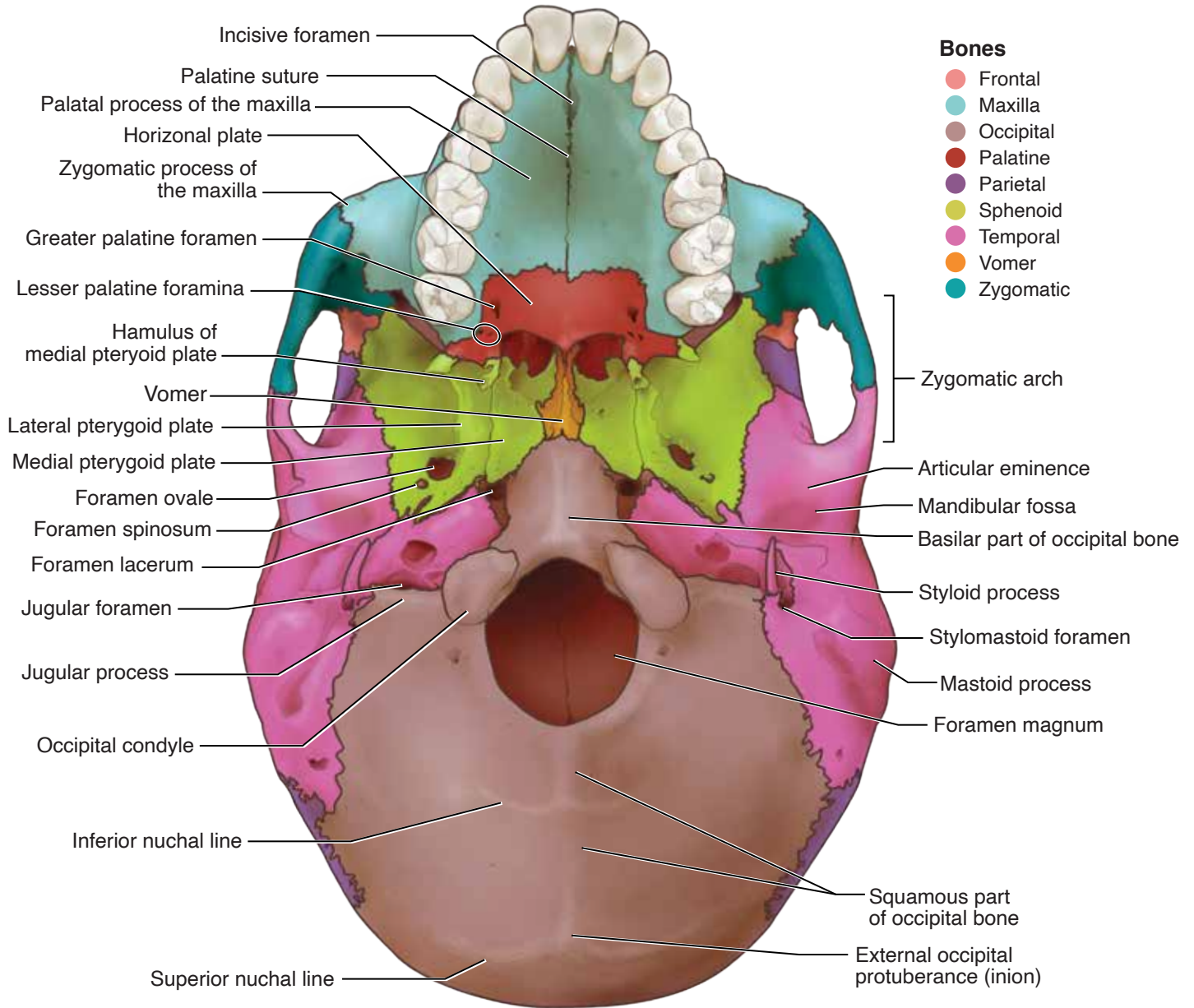
Appendix A



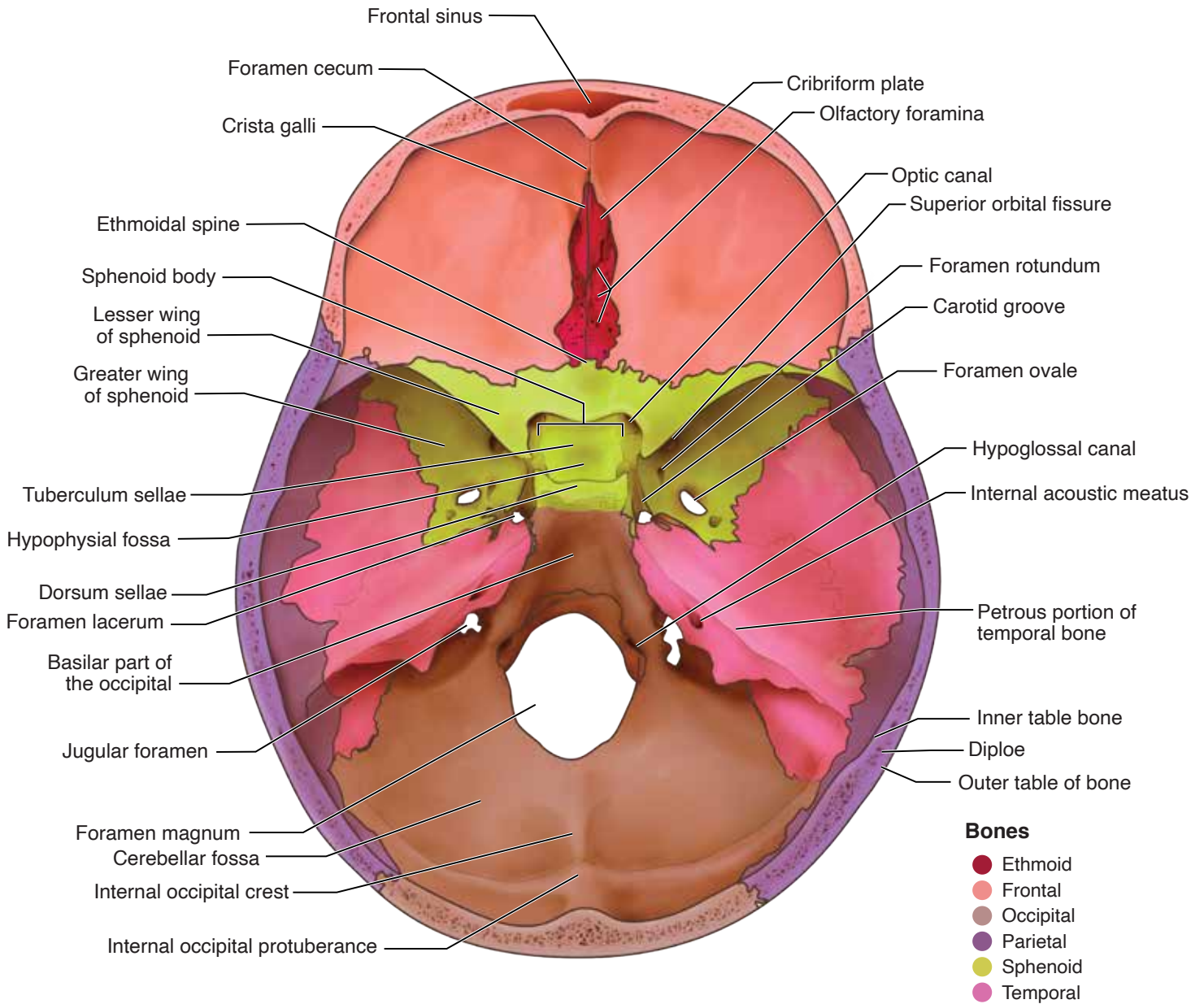
Head and Neck Anatomy: Part I – Bony Structures (ce591)
Appendix B



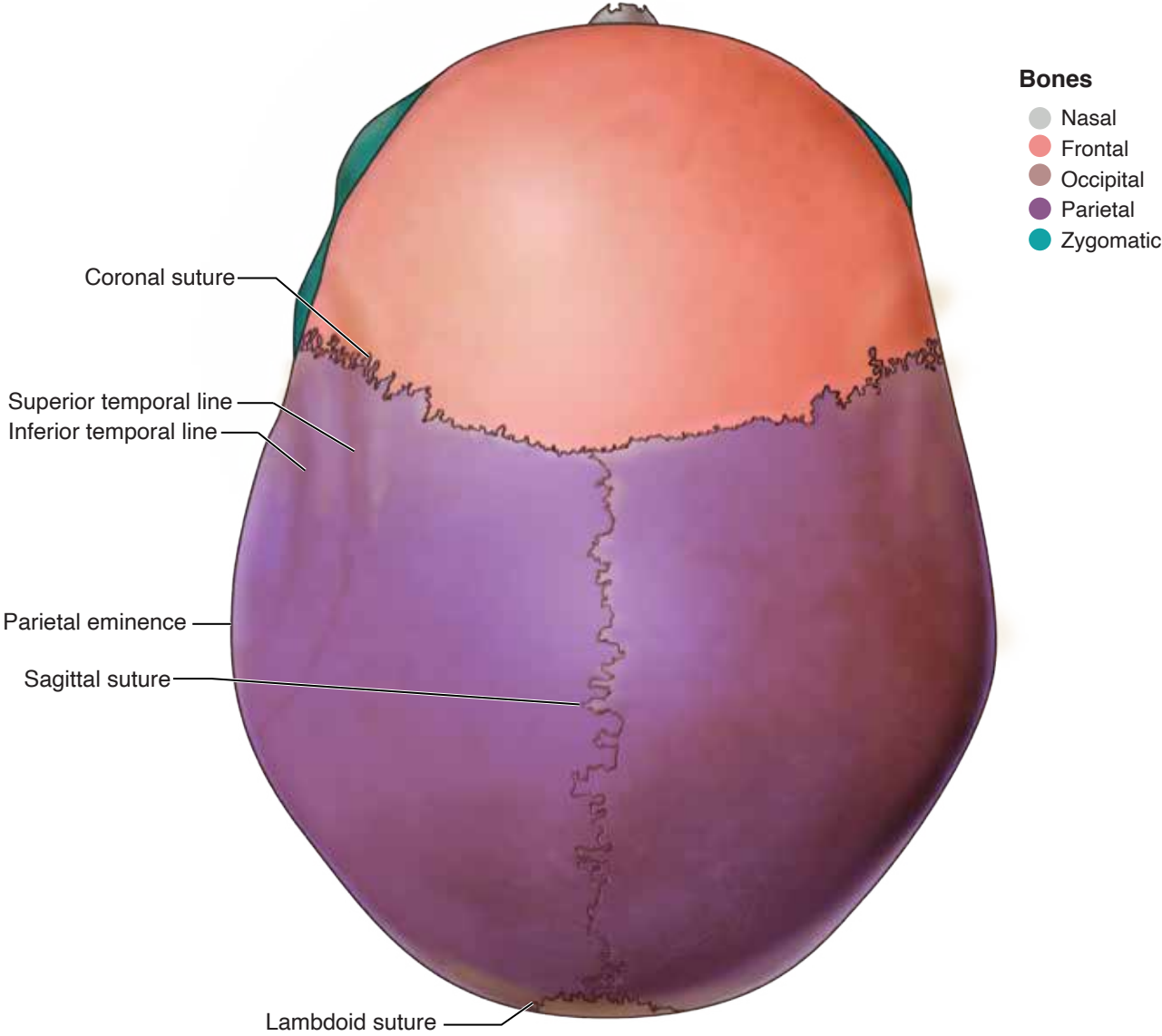
Head and Neck Anatomy: Part I - Bony Structures (ce591)
Appendix C

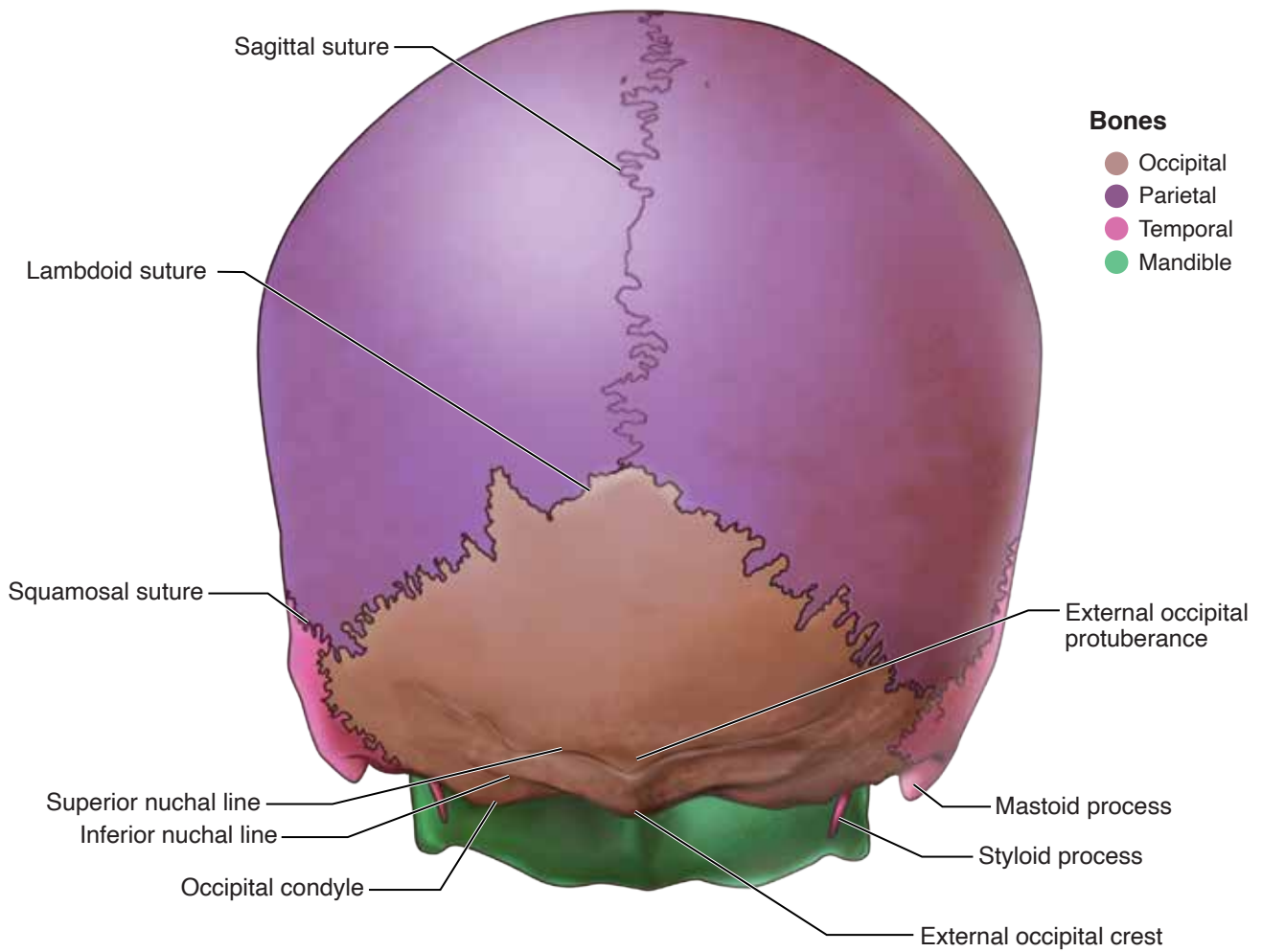


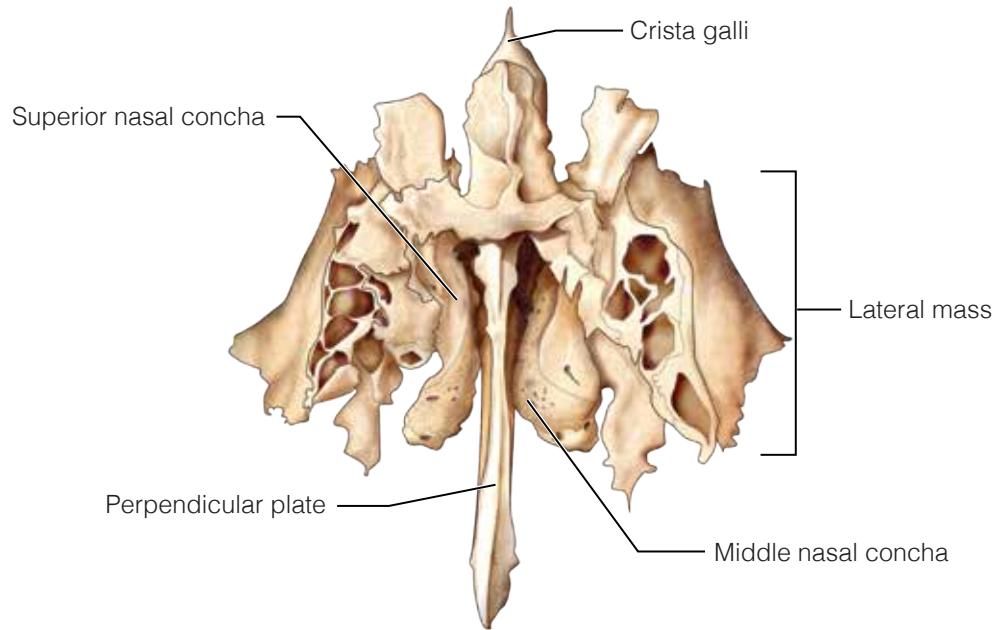
Head and Neck Anatomy: Part I – Bony Structures (ce591)
Appendix D



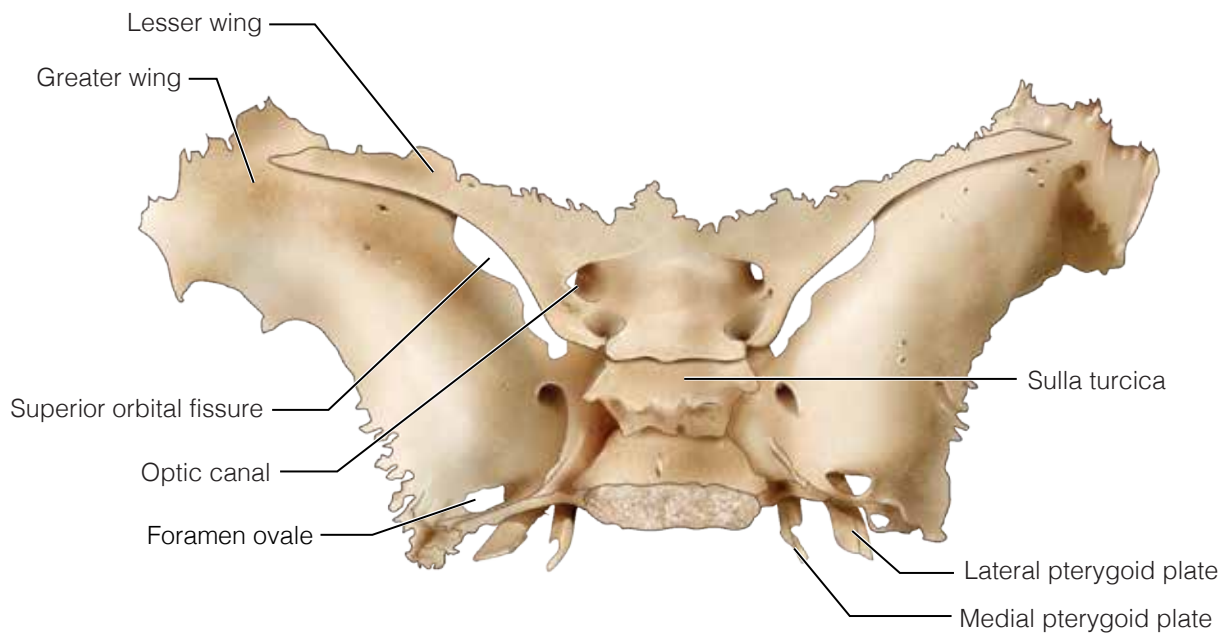
Head and Neck Anatomy: Part I - Bony Structures (ce591)
Appendix E



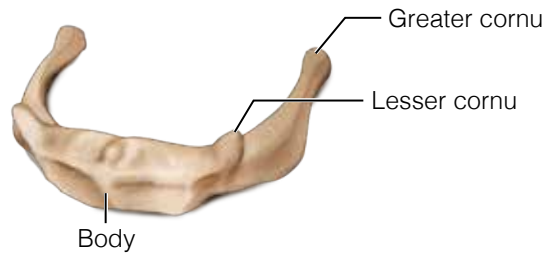




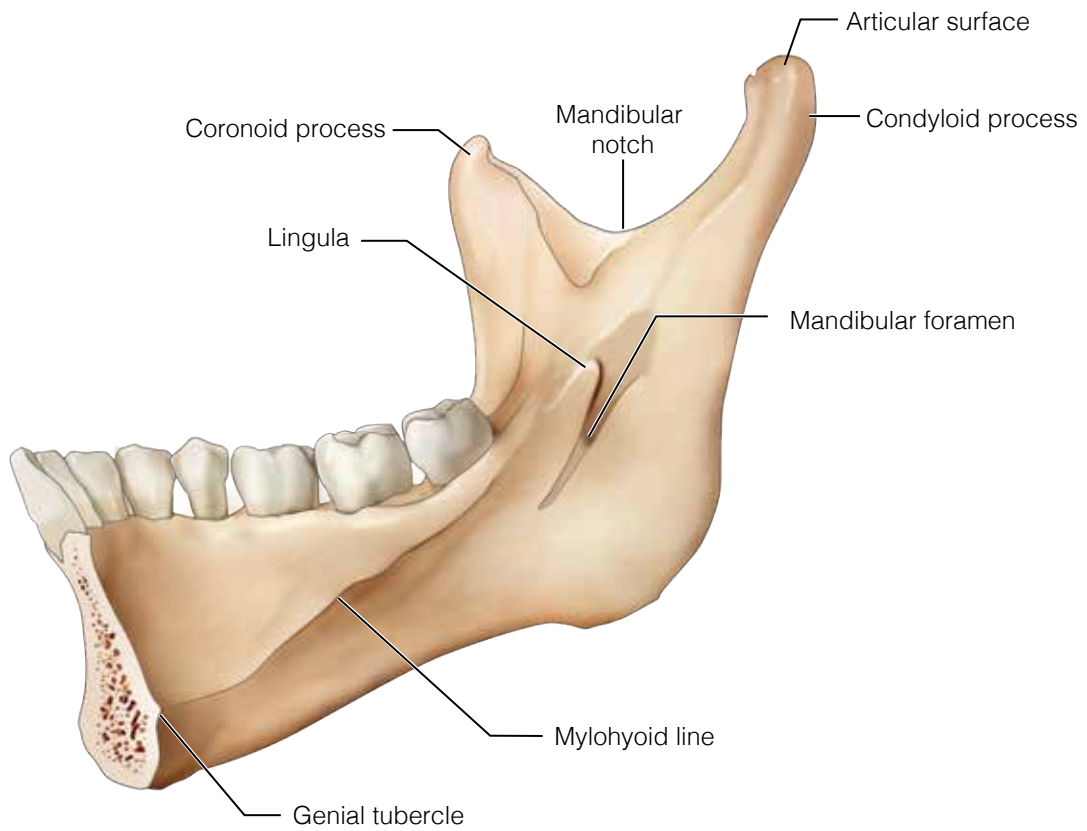
Ethmoid bone, anterior view



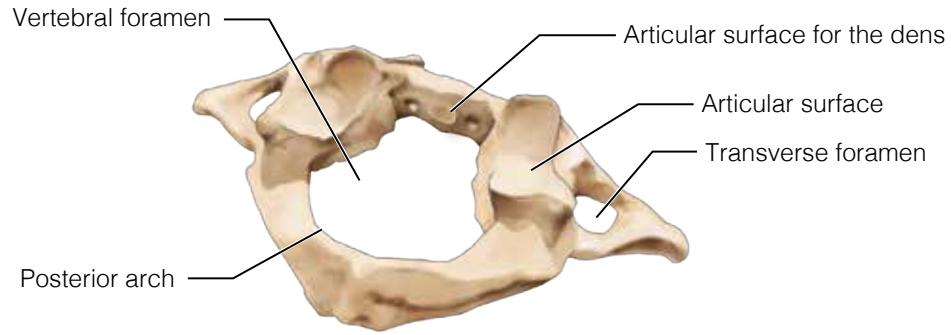
Sphenoid bone, superior view



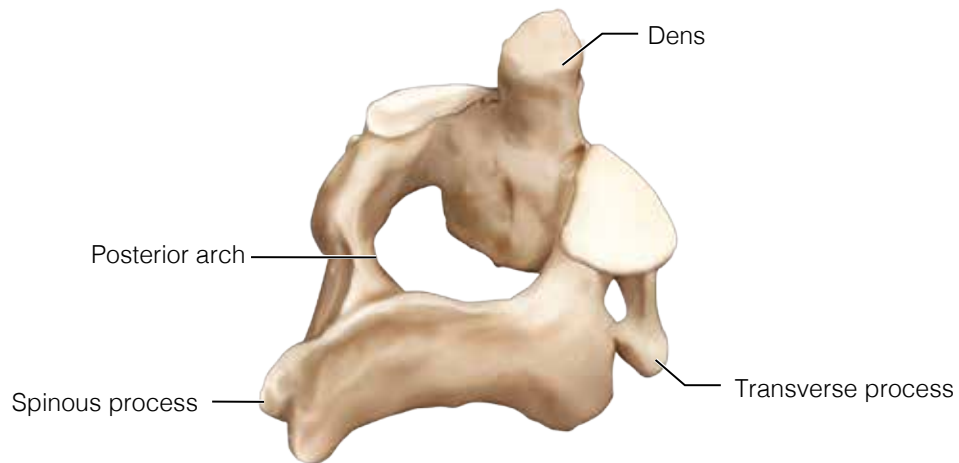
Hyoid bone, oblique anterolateral view



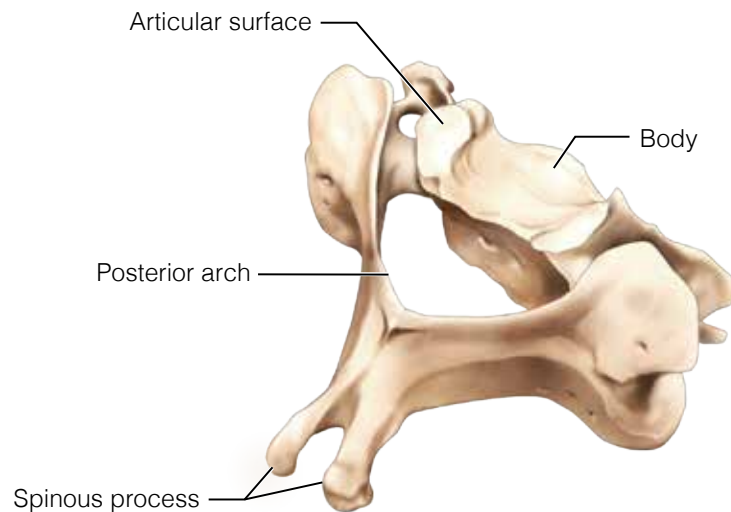
Mandible, medial view (lingual side)



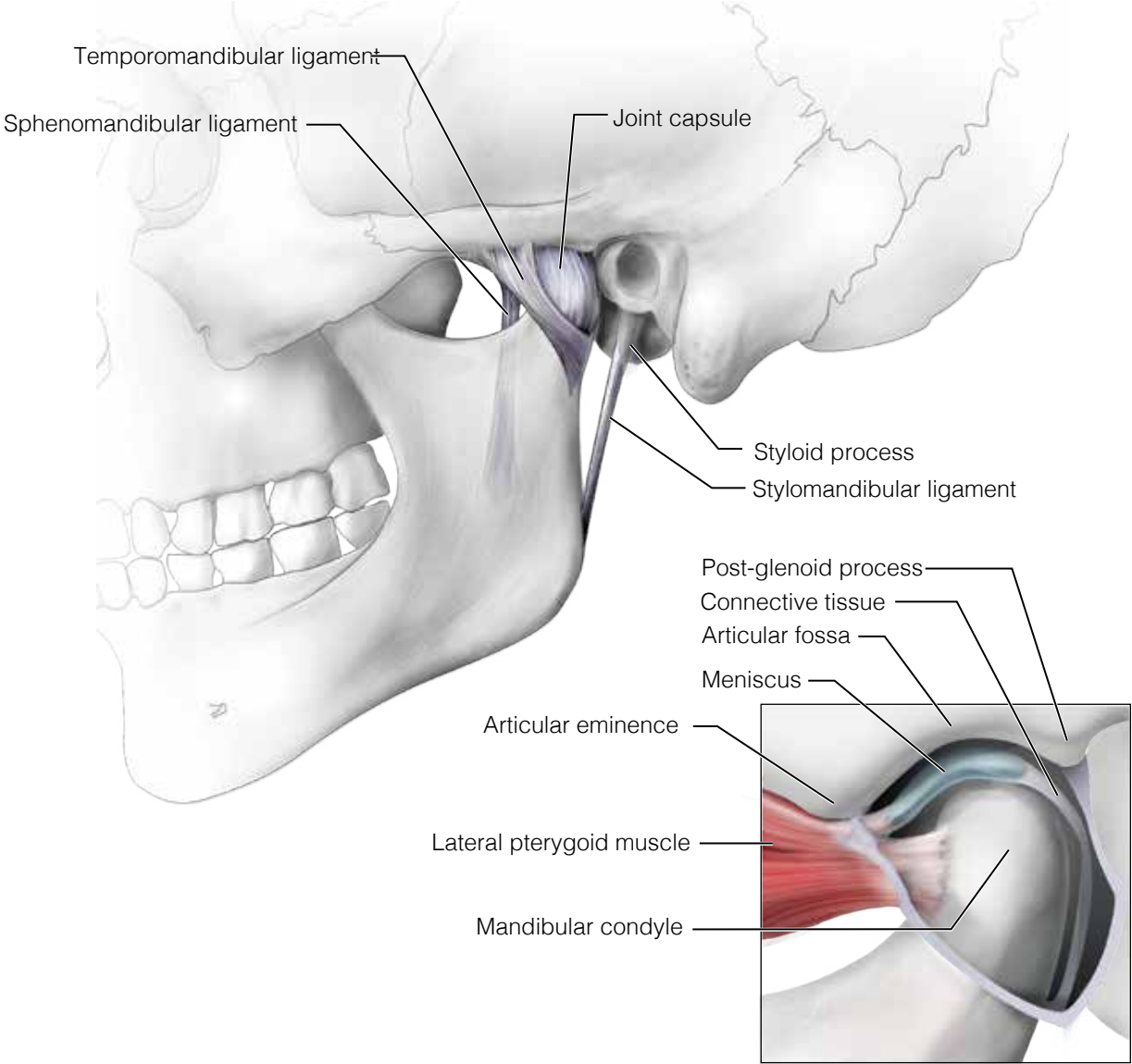
Atlas, oblique posterolateral view



Axis, oblique posterolateral view



**Typical cervical vertebrae (C5),
oblique posterolateral view**



Temporomandibular joint, lateral view