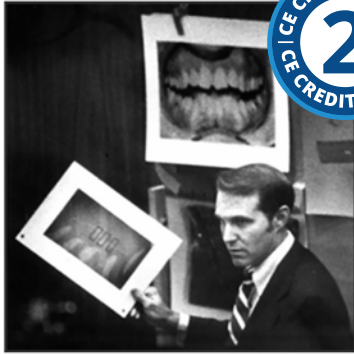

## Forensic Dentistry



**Course Author(s):** Marsha A. Voelker, CDA, RDH, MS

**CE Credits:** 2 hours

**Intended Audience:** Dentists, Dental Hygienists, Dental Assistants, Dental Students, Dental Hygiene Students, Dental Assistant Students

**Date Course Online:** 09/07/2012

**Last Revision Date:** 02/28/2025

**Course Expiration Date:** 02/27/2028

**Cost:** Free

**Method:** Self-instructional

**AGD Subject Code(s):** 145

**Online Course:** [www.dentalcare.com/en-us/ce-courses/ce401](http://www.dentalcare.com/en-us/ce-courses/ce401)

**Disclaimer:** Participants must always be aware of the hazards of using limited knowledge in integrating new techniques or procedures into their practice. Only sound evidence-based dentistry should be used in patient therapy.

### Conflict of Interest Disclosure Statement

- The author reports no conflicts of interest associated with this course.

### Introduction – Forensic Dentistry

Forensic Dentistry is a continuing education course that will provide an overview of forensic dentistry history, various identification methods utilized and how dental professionals can become involved.

## Course Contents

- Overview
- Learning Objectives
- Introduction
- Forensic Dentistry History
- Identification and Methods Utilized
- Forensic Dentistry Areas
  - Bite Marks
  - Abuse
  - Mass Fatality
- Education and Training
- Dental Professional Involvement Opportunities
- Conclusion
- Course Test
- References
- About the Author

## Overview

This continuing education course will provide an overview of forensic dentistry history, various identification methods utilized and how dental professionals can become involved.

In addition, this course provides scientific methods to assist in identification of victims related to crime or accident. To assist with forensic dentistry, dental professionals need to be aware of the importance of keeping accurate, current, detailed and legible dental records for the use of identification.

## Learning Objectives

**Upon completion of this course, the dental professional should be able to:**

- Discuss forensic dentistry history.
- Recognize and describe identification methods utilized in forensic dentistry.
- Explain what constitutes a mass fatality and be aware of federal, regional, and state response teams.
- Discuss the various training requirements and opportunities in forensic dentistry.
- Describe various ways for the dental professional to become involved in forensic dentistry.

## Introduction

After mass fatalities such as the events of September 11, 2001, Hurricane Katrina, and the Oklahoma City Bombings, identification of individuals through dental records has become

increasingly necessary. Forensic dentistry is one mechanism to aid in the identification of unknown victims of mass casualty and criminal incidents. Dental forensics and forensic odontology are terms used interchangeably and they are described as the management, examination, evaluation and presentation of dental evidence in criminal or civil proceedings, in the interest of justice.<sup>1</sup> There is a vast history of various documented ways that dental evidence and records have been utilized to identify victims or convict murderers.

## Forensic Dentistry History

The first forensic dentist in the United States was Paul Revere who was known for the identification of fallen revolutionary soldiers.<sup>2-5</sup> Dr. Joseph Warren, who suffered a severe head trauma during the war, was identified by the small denture that Paul Revere had fabricated for him.<sup>4</sup> Through this identification, it was made possible for Dr. Warren to be buried with full military honors.<sup>2,3</sup>

Dr. George Parkman was a respected professor at Harvard University who also dealt with real estate and lending money.<sup>4</sup> John Webster, a colleague of his at Harvard, who was a chemist, owed Dr. Parkman a considerable amount of money.<sup>4</sup> One evening, Dr. Parkman failed to return home from dinner on November 23, 1849. John Webster's laboratory was searched and a tea chest containing human remains was found. In the furnace, fragments of the maxillary jaw were discovered.<sup>4,6</sup> At the trial for John Webster, Dr. Nathan Cooley Keep, Dr. Parkman's dentist, identified the teeth as part of the maxillary and mandibular dentures he made three years earlier for the victim. This was the first time dental evidence was used to convict a murderer. This case is also a great example of how expert testimony was used in court.<sup>5</sup>

After the shooting of President Lincoln on April 14, 1865, John Wilkes Booth escaped and hid in a barn on a farm in Virginia.<sup>4,6</sup> The United States Calvary found him there on April 26, 1865 and burned the barn.<sup>4-5,7</sup> John Wilkes Booth exited the barn and was shot and killed.<sup>6</sup> However there was rumor that Mr. Booth had escaped. Therefore in 1893, the body was disinterred

and examined to verify that it was John Wilkes Booth.<sup>4,7</sup> The family could not perform a visual identification, but the family dentist was able to recognize his work as well as a peculiar formation of the jaw he had noted in his records during a dental visit for the placement of a filling.<sup>6</sup>

Dr. Oscar Amoëdo returned to Cuba in 1889 after studying at New York Dental College. He was then sent as a delegate to the International Dental Congress in Paris in 1890.<sup>4</sup> He decided to stay in Paris and became a dental instructor and teacher, eventually becoming a full professor. While in Paris, he wrote 120 scientific articles. A tragic fire at a charity event stimulated his interest in dental identification and the field of forensic odontology.<sup>8</sup> While he was not involved with the identification of the victims from the fire, he knew many of the victims who survived and interviewed them. His accounts of the fire were presented in a paper at the International Medical Congress of Moscow and were published in English in 1897.<sup>8</sup> Dr. Amoëdo wrote a thesis entitled "L'Art Dentaire en Medicine Legale,"<sup>9</sup> which earned him a doctorate and served as the basis of his book by the same name published in 1898.<sup>9</sup> The book he wrote was the first comprehensive text on forensic odontology and he is considered by many to be the "Father of Forensic Odontology."<sup>4,9</sup>

After the end of World War II, there were rumors Adolf Hitler had escaped with his wife Eva Braun.<sup>4,5</sup> Actually they had died together in 1945; however their bodies had been burned and then buried by Russian soldiers.<sup>4,5</sup> Due to lack of ante-mortem and post-mortem records, it was a challenge to dispel the rumors they were still alive. Finally pieces of Hitler's mandible were found that revealed remnants of a bridge as well as unusual forms of reconstruction to the mandible with evidence of periodontal disease.<sup>10</sup> Adolf Hitler's identity was confirmed when the work matched the records kept by his dentist, Hugo Blaschke.<sup>10</sup>

Several years after the assassination of John F. Kennedy, an English author named Michael Eddowes began raising suspicion concerning the identification of Lee Harvey Oswald.<sup>4,5</sup> He

believed the body buried in 1963 in Oswald's grave was a Russian spy.<sup>4,5</sup> Therefore, to set the record straight, the body was exhumed and positive identification of Oswald was made on October 4, 1981 with military ante-mortem dental records.<sup>11</sup>

In July of 1979, Theodore "Ted" Bundy was convicted of murder. This may have been the most widely publicized case that involved bite mark evidence. The exhaustive and specific nature of bite registries is to thank, at least in part, for Bundy's incarceration. Ted Bundy was one of the most notorious serial killers in United States History. He could have been responsible for the deaths of as many as 36 young women from Florida to the state of Washington.<sup>12</sup>

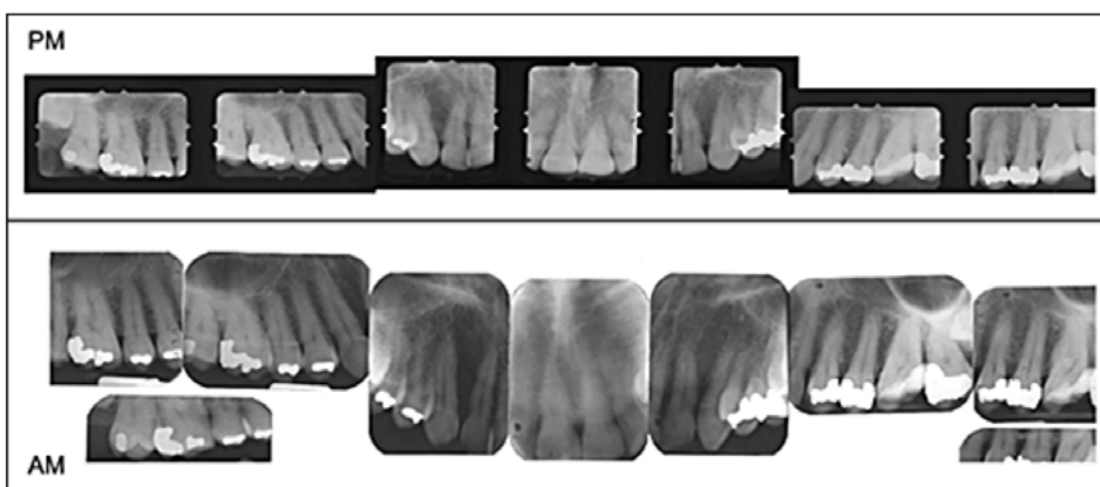
## Identification and Methods Utilized

Dental records are used to aid in the identification of individuals who are victims of criminal acts, murder investigations, mass fatalities or missing persons.<sup>1</sup> The confirmation of a decedent's identity is important for several reasons (Table 1). One of the most important is bringing closure to the immediate family members when tragic or unexpected events occur.<sup>4</sup> Another reason is for legal settlements of estates where a death certificate is needed.<sup>4</sup> In order for a death certificate to be issued, a confirmation of identity is needed.<sup>4</sup> This is why dental identification assumes a primary role in the identification of remains when postmortem changes occur, traumatic tissue injury occurs or there is a lack of fingerprint records which invalidates the use of visual or fingerprinted evidence.<sup>1</sup> Identification is crucial when the deceased is decomposed, burned, dismembered, or skeletonized.<sup>1</sup>

The evidence that can be derived from teeth is the age estimation (i.e., children, adolescents, adults) and identification of the person to whom the teeth belong. This is done using ante-mortem (prior to death) dental records, radiographs<sup>13</sup> and photographs and by comparing them to post-mortem records. It is important for dental professionals to document information in the ante-mortem dental record clearly, correctly, and specifically. Forensic dentistry starts with dental professionals and

**Table 1. Reasons for Identification of Human Remains.**

<b>Criminal</b>	Investigation in criminal death cannot begin until the victim has been positively identified.
<b>Marriage</b>	Individuals from many religious backgrounds cannot remarry unless their partners are confirmed deceased.
<b>Monetary</b>	Payment of pensions, life insurance and other benefits relies upon positive confirmation of death.
<b>Burial</b>	Many religions require that positive identification be made prior to burial in geographical sites.
<b>Closure</b>	Identification of individuals missing for prolong time can bring peace and closure to family members.



**Figure 1. Comparison of Post-mortem (PM) with Ante-mortem (AM) Radiographs.**

Source: Dr. McCunniff.

so, dental professionals are encouraged when documenting to utilize universal abbreviations when needed, and to be detailed about the procedures conducted on patients. A person's teeth change throughout life and the combination of decayed, missing and filled teeth is measurable and comparable at any fixed point in time. Therefore, quality radiographs and accurate charting are the FIRST steps in providing a positive identification.

Teeth have the ability to survive decomposition and withstand extreme temperature changes, which is why dental evidence comparison

is one of the most dependable and reliable methods of identification.<sup>4</sup> This is made possible by comparing features of an unknown individual (post-mortem dental records) with a known individual (ante-mortem dental records). For this reason, it is extremely important an accurate and detailed evaluation of the unknown individual is documented to provide the best possibility of successful comparison with ante-mortem records.<sup>4</sup> The following is collected for post-mortem documentation: photographs (digital or film based) which provide the ability to view specific features without having to review the body, radiographs (full mouth series) (Figure 1), and a complete

dental record for post-mortem and ante-mortem paperwork (Figures 2A & 2B).<sup>17</sup> The primary goal of post-mortem dental records is to locate, identify and document anatomical structures, dental restorations and dental appliances that will assist in the comparison process.<sup>4</sup> The more information documented from the post-mortem examination, the better the possibility for successful comparison.<sup>4</sup>

There are three categories examined when comparing dental records (ante-mortem with post-mortem) for identification, which are the teeth, periodontal tissue, and anatomical features.<sup>13</sup> When conducting a comparison regarding teeth, it is important to determine if they are present (erupted, unerupted, impacted), congenitally missing or lost ante-mortem/post-mortem, tooth type (permanent, deciduous, mixed, retained primary, supernumerary), what the tooth positions are, crown morphology and pathology, and root morphology. Pulp chamber and root morphology may also be considered valuable information in identification. The pulp chamber can be used to distinguish approximate age of the individual, since the chamber size varies from children to adult teeth. The root morphology along with the pulp chambers will assist in determining whether the tooth is from the maxillary or mandibular arch, and distinguishing if it is an anterior or posterior tooth.<sup>14</sup> Incidents such as plane crashes and explosions can damage the coronal surface of the tooth. A positive identification is still possible by comparing the pulp chamber and root morphology.<sup>12</sup> The root surfaces of teeth have unique shapes and bends that just may be the key to a positive identification.

Other factors to look for when conducting a comparison are the periodontal tissues in regards to gingival morphology and pathology, periodontal ligament morphology and pathology, and the alveolar process and lamina dura. In addition to anatomical structures such as the maxillary sinus, anterior nasal spine, mandibular canal, coronoid condylar processes, temporomandibular joint (TMJ), and other pathologies (developmental cysts, salivary gland pathology, trauma, evidence of surgery, metabolic bone disease, reactive/neoplastic, focal or diffuse radiopacities).<sup>14,15</sup>

There are computer identification databases such as WinID® or NCIC that are used today to compare ante-mortem and post-mortem data in the identification of deceased or missing individuals. WinID® is a dental computer system that matches missing persons to unidentified human remains. WinID® makes use of dental and anthropometric characteristics to rank possible matches.<sup>17</sup> WinID® is used by forensic dentists, forensic odontologists, pathologists, coroners, medical examiners, forensic anthropologists and those in the law enforcement and criminal justice systems to identify the unknown.<sup>17</sup> DMORT, which is a federal response team, includes dental team members that are deployed to aid in identifying victims.<sup>18</sup> These teams are currently utilizing WinID® for identification(s) as well as a digital imaging software just for forensic identification that can interact with WinID® entitled DEXIS Forensic (Figure 3).<sup>17</sup> DEXIS Forensic has a computerized receiver that is inserted into a laptop computer. The system utilizes charge coupled device (CCD) sensors that are placed in the victim and exposed to radiation providing an instant radiographic image on the computer screen. In addition, DEXIS Forensic has the capability to scan existing film-based dental records into WinID® for electronic transfer and comparison. This capability is utilized for inputting ante-mortem records into WinID®. WinID® was used for the first time to assist in the identification of Hurricane Katrina victims in the American Southeast in 2005.<sup>18</sup>

The Federal Bureau of Investigation also has a computer database called National Crime Information Center (NCIC) through the Criminal Justice Information Services (CJIS) Division.<sup>4,19</sup> The purpose for maintaining the NCIC system is to provide a computerized database for ready access by a criminal justice agency making an inquiry and for prompt disclosure of information in the system from other criminal justice agencies about missing or unidentified persons, crimes and criminals.<sup>4,19</sup> This information assists authorized agencies in criminal justice and related law enforcement objectives such as apprehending fugitives, locating missing persons, locating and returning stolen property, as well as in the protection of the law enforcement officers encountering the individuals described in the system.<sup>4,19</sup>



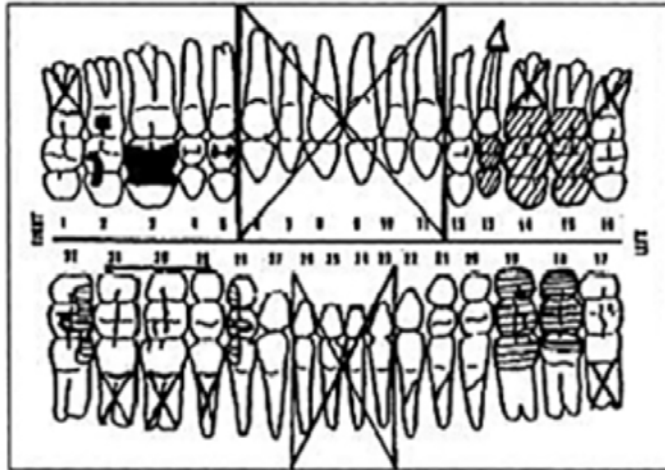
## POSTMORTEM DENTAL RECORD

RECOVERY NUMBER A-713 EST. AGE: UNK RACE: UNK SEX: UNK DATE: 12 DEC 97  
 EXAMINERS: A. B. SMITH, CAPT, DC, USN PLACE OF EXAMINATION: NAVAL AIR  
P. T. BOATE, CDR, DC, USN STATION, PENSACOLA, FL

### DESCRIPTION/COMPUTER CODES

1. X
2. OL-AM; F-AM
3. MODL-AM
4. PN
5. O.O-AM
6. JM
7. JM
8. JM
9. JM
10. JM
11. JM
12. PN
13. FP-CV, RF-AP
14. FP-X
15. FP-CF
16. X
17. X
18. CP
19. CF
20. FX
21. FX
22. FX
23. TA
24. TA
25. TA
26. TA
27. PN
28. DOFL-GI
29. RP-X
30. RP-X
31. RP-X
32. MOFL-GI

### RESTORATIONS & MISSING TEETH



### CAPMI SYMBOLS

AM AMALGAM	CF CROWN FULL
GI GOLD INLAY	CP CROWN PARTIAL
OF GOLD FOIL	CV CROWN VENEER
SS ANY OTHER METAL REST	FP FIXED PARTIAL
CO COMPOSITE RESIN	RP REMOVABLE PARTIAL
JM JAW FRAGMENT MISSING	CD COMPLETE DENTURE
TA TRAUMATIC AVULSION	M MESIAL
FX FRACTURED CROWN	D DISTAL
RT ROOT TIP	O OCCLUSAL
PN PRESENT NOT RESTORED	I INCISAL
RO ROTATED	F FACIAL
RF ROOT CANAL FILLING	L LINGUAL
AP APICOECTOMY	C CARIES
IR INTERMEDIATE REST	U UNERUPTED
CT CROWN TEMPORARY	X EXTRACTED

REMARKS: BILATERAL MANDIBULAR TORI

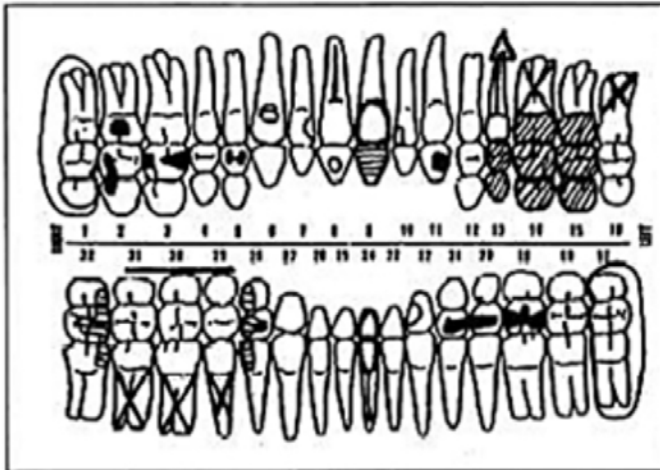
**Figure 2A.** Post-mortem Dental Record Documentation (CAPMI System).

Source: [http://medical.tpub.com/14275/css/14275\\_246.htm](http://medical.tpub.com/14275/css/14275_246.htm)

# ANTEMORTEM DENTAL RECORD

NAME: FROST, JACK, R SSN: 333-33-3333 RANK: LT, USN  
 SEX: M RACE: C AGE: 31 XRAY TYPE & DATE: B/W 10/97 Pano 01/96  
 EXAMINERS: A.B. SMITH, CAPT, DC, USN DATE RECONSTRUCTED: 12 DEC 77  
P.J. BOATE, CDR, DC, USN RECORD SUPPLIED BY: NDC Pensacola FL

## RESTORATIONS & MISSING TEETH



AM AMALGAM  
 GI GOLD INLAY  
 GF GOLD FOIL  
 SS ANY OTHER METAL REST  
 CO COMPOSITE RESIN  
 JM JAW FRAGMENT MISSING  
 TA TRAUMATIC AVULSION  
 FX FRACTURED CROWN  
 RT ROOT TIP  
 PN PRESENT NOT RESTORED  
 RO ROTATED  
 RF ROOT CANAL FILLING  
 AP APICOECTOMY  
 IR INTERMEDIATE REST  
 CT CROWN TEMPORARY

CF CROWN FULL  
 CP CROWN PARTIAL  
 CV CROWN VENEER  
 FP FIXED PARTIAL  
 RP REMOVABLE PARTIAL  
 CD COMPLETE DENTURE  
 M MESIAL  
 D DISTAL  
 O OCCLUSAL  
 I INCISAL  
 F FACIAL  
 L LINGUAL  
 C CARIES  
 U UNERUPTED  
 X EXTRACTED

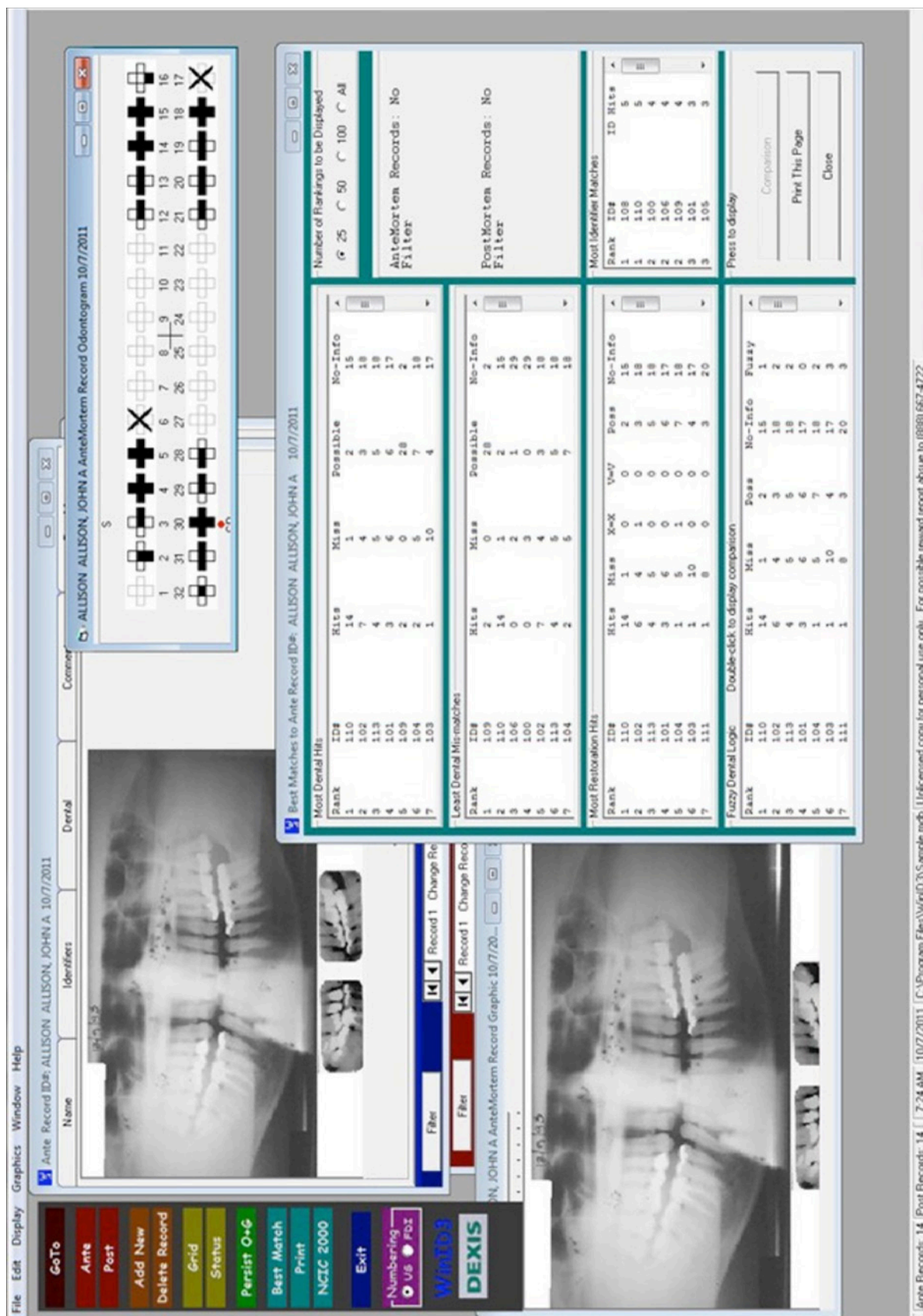
REMARKS: BILATERAL MANDIBULAR TORI

## DESCRIPTION/COMPUTER CODES

1. U
2. OL-AM, F-AM
3. MO-AM, DO-AM
4. PN
5. O.O-AM
6. F-CO
7. M-CO
8. L-IR, RF
9. CV
10. MI-CO
11. D-AM
12. PN
13. FP-CV, RF-AP
14. FP-X
15. FP-CF
16. X
17. U
18. MODL-C
19. MOD-AM
20. Mo-AM
21. DO-AM
22. ML-CO
23. PN
24. CT-RF
25. PN
26. PN
27. PN
28. DOFL-GI
29. RP-X
30. RP-X
31. RP-X
32. MOFL-GI

Figure 2B. Ante-mortem Dental Record Documentation (CAPMI System).

Source: [http://medical.tpub.com/14275/css/14275\\_249.htm](http://medical.tpub.com/14275/css/14275_249.htm)



**Figure 3.** WinID showing best matches and comparison of ante-mortem and post-mortem radiographs.<sup>16</sup>



The National Institute of Justice in 2007 began funding the National Missing and Unidentified Person Systems (NamUs).<sup>4</sup> The NamUs system has two databases, one for unidentified decedents and the other for known missing persons data. In 2009, the NamUs system established a link between the two databases that allowed the comparison of unidentified remains to known missing persons.<sup>4</sup> The database is searchable and accessible by medical examiners, forensic scientists, law enforcement, and the general public.<sup>4</sup>

## Forensic Dentistry Areas

There are several areas of specialty with forensic dentistry, which include the assessment of bite mark injuries, assessment of cases of abuse (child, domestic partner, or family), identification of found human remains and identification in mass fatalities.

### Bite Marks

The use of bite mark evidence began around 1870 with the Ohio vs. Robinson case.<sup>20,21</sup> The case involved A.I. Robinson, a well-regarded member of his community, who was suspected of murdering his mistress. There were five distinct bite marks located on the victim's arm which revealed five maxillary anterior teeth.<sup>22</sup> Robinson happened to only have five maxillary anterior teeth, which Dr. Taft, a dentist, testified in court that Robinson's dentition matched the bite marks from the victim.<sup>22</sup>

A bite mark is known as the registration of the cutting edges of teeth on a substance caused by a jaw closing.<sup>23</sup> The scientific premise regarding bite mark analysis is stemmed from the fact that the human dentition is not identical from person to person.<sup>21</sup> Bite marks are as specific to a person as DNA or fingerprint analyses, similarly, no two individuals will have the exact same dentition in regards to shape, size and alignment of teeth.<sup>21</sup>

Bite marks are either left on the victim (by the attacker), on the perpetrator (by the victim of an attack) or an inanimate object found at the crime scene.<sup>22</sup> Human bite marks on victims are most often found on the skin and soft tissue areas of all parts of the body.<sup>22</sup> Area bite marks on female victims are most often found

on the breasts and legs produced during sexual attacks.<sup>22</sup> On males the bite marks are commonly seen on the arms and shoulders.<sup>24,25</sup> When a person is in defensive circumstances, such as when the arms are held up to ward off an attacker, the arms and hands are often bitten.<sup>14</sup> Bite marks are often found on children who are abused.<sup>20,21</sup>

The duration of a bite mark is determined by the magnitude and how long the victim had been bitten.<sup>23</sup> Human bite marks are described as an elliptical or circular injury that records the specific characteristics of the teeth.<sup>24</sup> The bite mark may be in the shape of a doughnut with characteristics recorded around the perimeter of the mark.<sup>14</sup> Also it may be composed of two U-shaped arches that are separated at their bases by an open space. Typically the diameter of the injury is from 25-40mm.<sup>14</sup> Often the injury has a central area of bruising seen within the bite mark.<sup>14</sup> This is caused by pressure from the teeth as they compress the tissue inward from the perimeter of the mark.<sup>14</sup>

Guidelines have been established for bite mark analyses by the American Board of Forensic Odontology (ABFO) (Table 2) for the ABFO Guidelines.<sup>22,27</sup> When collecting dental evidence, a description of the bite mark in regards to demographics, location, shape, size, color, type of injury and any other information needs to be recorded.<sup>22,26,27</sup> The collection of evidence from the victim includes photographs, salivary swabbing, impressions and tissue samples.<sup>22,26,27</sup> Even collection of evidence from the suspect(s) is needed, which includes history, photos, extraoral examination, intraoral examination, impressions, sample bites and study casts.<sup>22</sup>

Upon collection of dental evidence, the forensic odontologist analyzes and compares the bite marks.<sup>22,27,28</sup> Studies have been performed in an attempt to find the simplest, most efficient and most reliable way of analyzing bite marks.<sup>28</sup> Early forensic investigators analyzed marks left by dental casts in wax, clear overlays, and other mediums.<sup>28</sup> Others attempted to simulate the consistency of human tissue by using articulated dental models to "bite" baker's dough and sponge rubber.<sup>29</sup> The

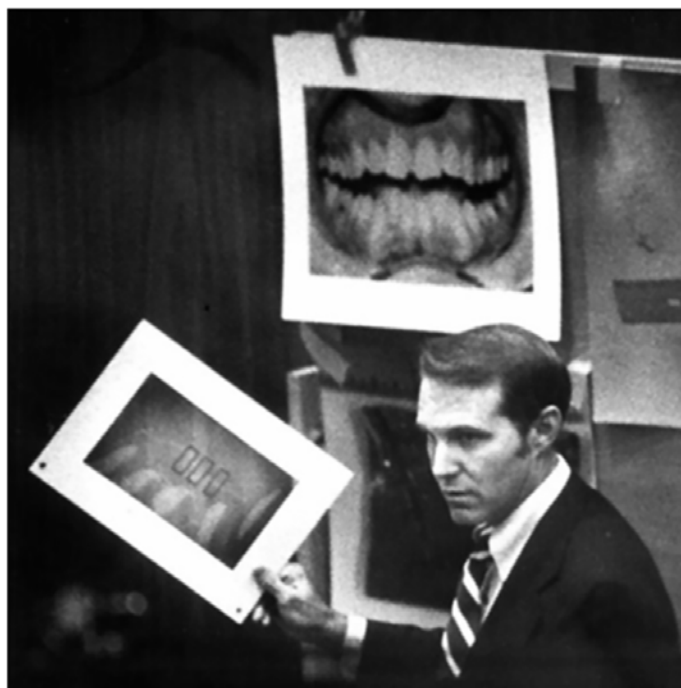**Table 2. ABFO Guidelines for the Collection of Victim Evidence.**<sup>14,30</sup>

- **Photography**  
Orientation and close up photographs should be obtained with and without the presence of a scale placed adjacent to the bite mark. The scale must be positioned within the same plane as the bite mark and should include a linear and circular reference to aid in eliminating possible distortion. The film resolution should be high quality with proper color balance. Serial photographs are recommended in living victims.
- **Salivary Swabbing**  
Saliva swabs should be collected in circumstances in which the bite site area has not been altered from the time when the bite was inflicted.
- **Impressions**  
Impressions of the bite site area should be taken when there is sufficient surface detail which may yield beneficial information. The material used must meet the American Dental Association specifications and suitable support should be included for proper support and reproducibility of the body site contour.
- **Tissue Samples**  
Tissue samples should be retained if it appears it may yield useful information.

ABFO has guidelines established for bite mark methodology to preserve bite mark evidence.<sup>30,31</sup> Considerations that need to be made when photographing and documenting the bite site are lighting and the utilization of a scale in the photo to provide an accurate account of the bite site size.<sup>14,26,27,28</sup> The methods for comparing bite mark evidence are the use of overlays, test bite media, comparison techniques and technical aids employed for analysis.<sup>14,22,30</sup>

There are factors that may affect the accuracy of bite mark identification which include time-dependent changes of the bite mark on living bodies, effects of where the bite mark was found, damage on soft tissue, and similarities in dentition among individuals.<sup>28</sup> Elasticity and the inflammatory process of human tissue hinder the identification process of bite mark registration.<sup>28</sup> Placement of the limb in the exact position when the attack occurred is necessary to recreate the correct bite relationship; this may not always be known in the case of a decedent.<sup>28</sup>

In regards to famous bite mark cases, Ted Bundy the serial killer would be the one that comes to mind. Dr. Richard Souviron was the forensic dentist, who was requested to come to Tallahassee, Florida to examine evidence that had been discovered on the body of one of the victims from the Chi Omega sorority house in January of 1978.<sup>24</sup> Dr. Souviron, by accepting a part in the case, became part of the legal process regarding the case.<sup>21</sup> Therefore, Dr. Souviron was responsible for thorough documentation of the evidence.<sup>21</sup> He found, upon arrival to view the evidence, the tissue was from a breast and buttocks that had been excised and placed in fluid without retaining rings.<sup>24</sup> Though the materials were of limited value, Dr. Souviron was able to determine the person who bit the victim had poorly aligned teeth.<sup>24</sup> This information assisted in establishing probable cause which was necessary in order to obtain a search warrant; this warrant allowed Dr. Souviron to make dental impressions, bite records, and photographs of Ted Bundy's dentition.<sup>24</sup> Then he provided a photograph of the bite injury (Figure 4).<sup>2,24</sup>



**Figure 4.** Dr. Richard Souviron presents evidence at Ted Bundy's appeal trial - Tallahassee, Florida.

Mark Foley - Photographer

Source: <http://www.floridamemory.com/items/show/133904>

In addition, Dr. Lowell Levine and Dr. Norman Sperber also examined independently the evidence and all three examiners concluded the evidence did implicate Ted Bundy as the perpetrator of the bite marks.<sup>12,24</sup> Once the evidence was admissible, Dr. Souviron presented a series of slides to the grand jury and ended up testifying at the trial.<sup>12,24</sup> Ted Bundy was convicted on seven counts and sentenced to death.<sup>12,24</sup>

### Abuse

Abuse can involve children, women, men and the elderly. The dental team can assist in early detection of someone being abused when conducting an exam and looking for anything that may show signs of abuse within the oral cavity. The following are some signs the dental team can look for when conducting an exam:<sup>20</sup>

- **Fractured incisors** – may be due to repeated trauma.
- **Burns on lips** – due to forced feeding of hot food.
- **Bruises on lips** – in children may be due to forced pacifier use.

- **Frenum bruising or tear** – due to forced feeding of a non-ambulatory child, elderly.
- **Oral or perioral syphilis or gonorrhea (pathognomonic of sexual abuse, palatal petechiae or erythema)** – probable sexual abuse.
- **Bite marks** – 65% of bite marks are visible on unexposed areas that are not covered by the child's clothes.<sup>20</sup>

Bite marks on abused children tend to come from individuals who have uncontrollable anger toward the child. Infants that are bitten by the perpetrator are more punitive in nature as the bites are basically driven by a specific behavior by the infant. Overall trends reveal the person who inflicted the bite is usually the abuser of the child.<sup>23</sup>

Dental professionals are called upon to actively participate in crimes related to children, especially if a bite mark is associated with the victim.<sup>23</sup> Child abuse is any act that endangers or impairs a child's physical or emotional health or development. Neglect occurs in


74% of child abuse cases and 74% of child abuse victims die from neglect.<sup>32</sup> Dental neglect is one type of abuse because it is the willful failure by a parent or guardian to seek and obtain treatment for dental problems which cause pain, infection, or interfere with adequate function.

Elder abuse is an issue dental professionals need to be more aware of happening. Each year, millions of elders suffer from maltreatment.<sup>33,34</sup> The elder population of 60 and older is increasing each year, so are the cases for elder abuse.<sup>35</sup> Elder abuse can be put into six categories: physical abuse, sexual abuse, psychological abuse, financial exploitation and violation of rights.<sup>36,37</sup> The United States Department of Justice (DOJ) Elder Justice Roadmap research indicates 10% of adults over 60 in the United States experience some form of abuse each year.<sup>38</sup> Studies have also shown that about two-thirds of elder abuse victims are women.<sup>38</sup> The prevalence of elder abuse may be much higher, as the DOJ Roadmap's research suggest that only one out of 24 cases are reported.<sup>38</sup> Older adults are being mistreated in multiple settings (homes, nursing homes, assisted living facilities) by family members,

friends, neighbors, professionals and strangers. Figure 5, is a chart displaying the types of elder abuse. As you can see in figure 5, financial fraud & exploitation is number one with neglect number two.<sup>38</sup>

Dental professionals may encounter clues that elders are being physically abused by bruises, lacerations, puncture wounds, or injuries with incompatible histories. The head and neck regions tend to be the common site of elder abuse; with other signs being traumatic hair and tooth loss, rope or strap marks indicating physical restraint and multicolored bruises indicating injuries at various healing stages.<sup>4</sup> National Committee for Prevention of Elder Abuse also reports some of the indicators of elder abuse can include:<sup>4</sup>

- Injuries that are unexplained or are implausible.
- Family members providing different explanations of how injuries were sustained.
- A history of similar injuries with numerous hospitalizations.
- Victims brought to different medical facilities for treatment to prevent medical practitioners from observing pattern abuse.
- Delay between onset of injury and seeking medical care.



**Figure 5.** Types of Elder Abuse.

Source: Elder Abuse Statistics Department of Justice Statistics.<sup>38</sup>



Head and neck injuries are common in elder abuse.<sup>4</sup> In fact, it was reported approximately 30% of known elder abuse cases were related to neck and facial injuries.<sup>39</sup> Oral soft tissues, jaw fractures and fractured or avulsed teeth have been reported as indications of elder abuse.<sup>4</sup>

There are many of the indicators mentioned that are very similar to signs and symptoms of abuse and neglect seen in the younger population.<sup>4</sup> It is imperative dental professionals are aware of the signs of intentional trauma that are often seen in the orofacial region.<sup>4</sup> When a dental professional recognizes these signs, documentation is crucial and all the findings should be noted in the dental patient record. A description of the area, shape, size, color should be in the notes, including a picture either using the intraoral camera or digital camera to help with the documentation. This documentation assists the dental professional when determining patterns and also helps with the investigation of abuse cases. In addition, the forensic dentist is regularly consulted when either law enforcement or health care personnel recognize there is dental evidence connected to an incident.<sup>40</sup>

### Mass Fatality

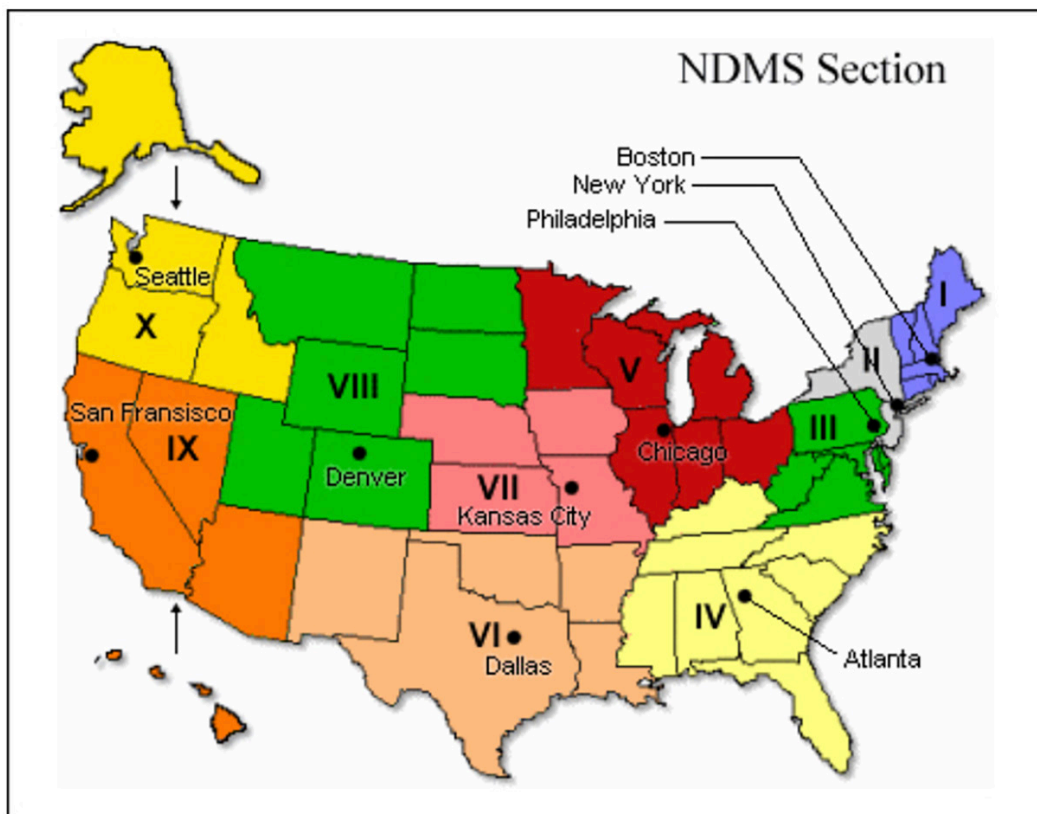
A mass fatality incident can be defined as: 'An incident where more deaths occur than can be handled by local resources'.<sup>18</sup> Mass disasters/fatalities such as transportation accidents, explosions, fires, volcanic eruptions, mass murders and mass suicides often leave many bodies in poor condition for identification. The National Disaster Medical System (NDMS) is a federally coordinated system and is a part of the Department of Health & Human Services that augments the Nation's medical response capability.<sup>41</sup> NDMS has five response teams: Disaster Medical Assistance Team (DMAT), Disaster Mortuary Operational Response Team (DMORT), National Veterinary Response Team (NVRT), National Nurse Response Team (NNRT), National Pharmacy Response Teams (NPRTs).<sup>42</sup>

DMORT is the federal level response team designed to provide mortuary assistance in the case of a mass fatality incident or cemetery

related incident. In the event of flooding, it is sometimes necessary to recover caskets, re-identify displaced individuals and disinter the remains.<sup>18</sup> DMORT works under the local jurisdictional authorities such as Coroner/Medical Examiners, Law Enforcement and Emergency Managers and is only deployed when local authorities request assistance.<sup>18</sup> There are ten regions within DMORT and each region consists of a team from certain states; which is displayed in Figure 6.<sup>18</sup>

The DMORT team is made up of various professions which includes: Medical Examiner/Coroners, Forensic Pathologists, Forensic Anthropologists, Fingerprint Specialists, Forensic Odontologists, Dental Assistants/Hygienists, Funeral Directors/Embalmers, X-ray Technicians, Photographic Specialists, Heavy Equipment Operators, Mental Health Specialists, DNA Specialists, Computer Specialists, Medical Records Technicians, Transcriptionists, Administrative support staff, Security personnel, Investigative personnel, Evidence Specialists, and Facility Maintenance Personnel.<sup>18</sup> This whole team is needed in order to set up the temporary morgue and get it operational to collect post-mortem data and documentation. The dental team is responsible for setting up their area in the morgue and ensuring the equipment is ready to be utilized. For example, is the main computer server working properly for the post-mortem dental computers to communicate with the ante-mortem computers in order to conduct a dental comparison?

The equipment utilized in the dental post-mortem section is a digital camera, laptop computer with WinID and DEXIS Forensic installed, portable radiographic unit (NOMAD), and the armamentarium (mouth mirror, gauze to clean on the teeth, etc.) utilized to view the teeth of the unknown person. Depending on the morgue set up and the disaster, the number of tables being used for dental varies for example: after the Joplin F5 tornado of 2011, there were two dental tables running with three to four people per table. There is a person that enters the data into the computer, a person taking digital photos, a person examining the mouth and calling out



**Figure 6.** DMORT US Regions.<sup>42,49</sup>

dental record information to the computer entry person and another person taking radiographs. Once the information is collected on the unknown individual, the computer entry person calls back the information entered in the computer. This is done to ensure all data entered is done so correctly.

Also, there is an ante-mortem dental station where dental team members are organizing the dental records being submitted. These records are being reviewed by the dental team members and the ante-mortem paper record is utilized to document the dentition and verify before entering into WinID. Any film-based radiographs or printed photos are scanned into the computer. If there are digital radiographs and photos that were submitted electronically, they are also integrated into the ante-mortem record on WinID. Once there are records entered into the computer system then dental personnel can begin making comparisons.

There are state level response teams within each state that function in a similar manner

as DMORT. An example of state teams would be the Missouri Disaster Mortuary Response Team (MO-MORT 1),<sup>43</sup> Missouri Emergency Response Identification Team (MERIT)<sup>43</sup> or Illinois Medical Emergency Response Team (IMERT).<sup>45</sup> In addition there are regional/local teams such as the Kansas City Regional Mortuary Operational Response Group (KCR-MORG).

Dental forensics played a key role in identification of individuals during the Oklahoma City bombings where 70-80% were identified, the Tragedy of 9-11 where 20% were identified,<sup>41</sup> the Asian Tsunami where 90% were identified and about 15-20% were identified after Hurricane Katrina.<sup>31,46</sup> In the case with Joplin, Missouri a lot of dental offices were destroyed when the F5 tornado hit, which made it difficult to locate records, especially if they were paper records. Those dental offices that were destroyed that utilized computerized management systems and had remote computer backup systems were beneficial with supplying ante-mortem records.

## Education and Training

A person interested in forensic odontology needs to become properly educated and trained. A Doctor of Dental Surgery (DDS) or Doctor of Medical Dentistry (DMD) degree is basic, but a traditional dental education does not provide the curriculum and experience that is required to function in this field. There are also opportunities for other dental professionals in the field.<sup>47</sup> Dental hygienists have become involved in dental forensics by volunteering their time with collecting the post-mortem information (radiographs, photos, dental charting, etc.) needed for proper identification of an individual. They also have the opportunity to serve as dental assistants with DMORT.<sup>18,50</sup> Currently, there are 35 dental hygienists serving with DMORT.

The American Academy of Forensic Science (AAFS) is the forum for forensic dental lectures, demonstrations and practical courses that are valuable educational experiences.<sup>47</sup> The AAFS affiliated American Board of Forensic Odontology (ABFO) serves as the credentialing body for dentists who have satisfied experience and training requirements to sit for the challenging ABFO examination.<sup>48</sup>

The American Society of Forensic Odontology (ASFO) meets annually at the AAFS annual meeting.<sup>47</sup> The Armed Forces Institute of Pathology (AFIP) offers week-long dental courses in odontology and pathology.<sup>47</sup> The University of Texas Health Sciences Center, San Antonio provides an annual program and a forensic dentistry fellowship program.<sup>48</sup> The New York Society of Forensic Dentistry and the New York County Dental Society offer introductory courses in Forensic Odontology.<sup>49</sup> Basic courses in forensic science and medicolegal death investigation are strongly recommended, as specialized knowledge is necessary to participate in forensic investigations.<sup>47</sup>

A few dental schools offer an elective or practicum in dental forensics where dental students and dental hygiene students attend local meetings (i.e., Missouri Emergency Identification Response Team (MERIT)),<sup>44</sup> and have guest educators come in to speak about

various topics regarding forensic dentistry and response to mass fatalities. Some students have the opportunity to tour the local medical examiner's office and view autopsies or assist the forensic dentist in an identification case. Also they may have the opportunity to visit the local crime scene investigation lab and meet a cadaver dog and trainer.

There are other avenues to receive further educational opportunities for dental professionals interested in dental forensics or mass fatality response teams by attending continuing education seminars or workshops. There are week-long seminars focusing on medical examiner investigation or 2-3 week classes in crime scene investigation. Those involved with DMORT receive annual training opportunities whether it is an online course or weekend training. State and regional disaster teams are another source of education and involvement.

## Dental Professional Involvement Opportunities

Forensic dentistry roles in the past have traditionally been for dentists, but dental hygienists and assistants are increasingly being utilized as valuable dental personnel in the area of forensic dentistry. Therefore, dental hygienists can have an important role in dental forensics by maintaining accurate dental records on a daily basis to assist with identification of human remains when a disaster occurs. In addition, contact the local medical examiner or coroner's office to find out who the forensic odontologist is and see if they will allow you to assist on any cases. Police departments may need dental professionals to assist with entering dental information into a computer data system. Become involved with the federal DMORT team or the state/regional response teams to help with mass disasters/fatalities.<sup>18</sup> All of these avenues are ways to become involved with assisting in identification of human remains or forensic dentistry.

Researching your local dental professionals who assist the coroner/medical examiner's office and volunteering to assist can be a good way to enter into forensics. Attending forensic seminars and meetings can open

doors that may otherwise be closed. Also, being an active member in your local medical reserve corps or state disaster teams can be a great avenue to get involved in forensics. Forensics is NOT for everyone, assisting in an organized disaster deployment or assisting forensic odontologists that work with the medical examiners or coroner office can be a beneficial test to determine if you can handle the rigors of forensic dentistry.

### **Conclusion**

Throughout history, dental forensics has played a role. As dental professionals, we

can continue to play a key role by keeping quality records on each patient. This is done by keeping records legible, accurate, and current. In addition, when dental professionals perform an extraoral and intraoral examination, document abnormalities even bruising or bite marks. This information will be significant to an investigation of crime or abuse. Those dental professionals interested in assisting with identification of human remains when a mass disaster occurs can do so either at the local, state or federal level. Therefore, all dental professionals do take part in one way or another in forensic dentistry.



## Course Test Preview

To receive Continuing Education credit for this course, you must complete the online test. Please go to: [www.dentalcare.com/en-us/ce-courses/ce401/start-test](http://www.dentalcare.com/en-us/ce-courses/ce401/start-test)

1. **The first forensic dentist in the United States was \_\_\_\_\_.**
  - A. John Webster
  - B. Paul Revere
  - C. John Wilkes Booth
  - D. Oscar Amoëdo
2. **\_\_\_\_\_ records are used to aid in the identification of individuals who are victims of criminal acts, murder investigations, missing persons, or mass fatalities.**
  - A. Dental
  - B. Medical
  - C. School
  - D. Work
3. **One of the most important reasons for confirmation of decedent's identity is?**
  - A. Death certificate
  - B. Insurance
  - C. Closure to family members
  - D. Legal settlements
4. **Teeth have the ability to survive \_\_\_\_\_ and withstand extreme \_\_\_\_\_ changes, which is why dental evidence comparison is one of the most dependable and reliable methods of identification.**
  - A. decomposition
  - B. temperature
  - C. heat
  - D. both A and B
5. **The following is collected for post-mortem records EXCEPT \_\_\_\_\_.**
  - A. digital photos
  - B. radiographs
  - C. CT scan
  - D. dental charting
6. **There are three categories when comparing dental records for identification, which are \_\_\_\_\_.**
  - A. teeth, periodontal tissue, anatomical features
  - B. teeth, pulp, gingiva
  - C. periodontal tissue, TMJ, tragus
  - D. anatomical features, radiographs, teeth
7. **The computer database currently being utilized by DMORT on deployments for dental identification is \_\_\_\_\_.**
  - A. NCIC
  - B. EAGLESOFT
  - C. MIPACS
  - D. WinID

8. The purpose of NCIC system is to provide a \_\_\_\_\_ for ready access by a criminal justice agency making an inquiry and for prompt disclosure of information in the system from other criminal justice agencies about missing or unidentified persons, crimes, and criminals.
- A. paper files
  - B. computerized database
  - C. evidence
  - D. victim list
9. Human bite marks are described as a(n) \_\_\_\_\_ or \_\_\_\_\_ injury that records the specific characteristics of the teeth.
- A. elliptical / rectangular
  - B. elliptical / circular
  - C. round / circular
  - D. round / elliptical
10. Bite marks are often found on \_\_\_\_\_ who are abused.
- A. children
  - B. elders
  - C. men
  - D. women
11. The duration of a bite mark is determined by?
- A. where the victim had been bitten
  - B. the magnitude and how long the victim had been bitten
  - C. how the victim was bitten
  - D. magnitude only
12. An incident where more deaths occur than can be handled by local resources is considered a \_\_\_\_\_.
- A. mass fatality
  - B. mass attack
  - C. massive crowd
  - D. massive collision
13. DMORT stands for \_\_\_\_\_.
- A. Disaster Mandatory Organizational Response Team
  - B. Disaster Mortuary Operational Response Team
  - C. Destruction Mortuary Operational Response Team
  - D. Destroy Mandatory Organization Response Team
14. The National Disaster Medical System is a federally coordinated system and is a part of the \_\_\_\_\_ department that augments the nation's medical response capability.
- A. Organization on Asepsis and Prevention
  - B. Food and Drug Administration
  - C. Health and Human Services
  - D. American Medical Response
15. DMORT works under the \_\_\_\_\_ jurisdictional authorities when deployed.
- A. federal
  - B. regional
  - C. state
  - D. local

16. There are \_\_\_\_\_ regions within DMORT and each region consists of a team from certain states.
- A. 5
  - B. 8
  - C. 10
  - D. 12
17. The American Board of Forensic Odontology serves as the \_\_\_\_\_ for dentists who have satisfied experience and training requirements to sit for the challenging ABFO examination.
- A. credentialing body
  - B. accrediting body
  - C. licensure
  - D. certification
18. Forensics is \_\_\_\_\_ for everyone, assisting in an organized disaster deployment or assisting forensic odontologists that work with the medical examiners or coroner office is a beneficial test.
- A. True
  - B. False
  - C. loved
  - D. fun

## References

1. Avon SL. Forensic odontology: the roles and responsibilities of the dentist. *J Can Dent Assoc.* 2004 Jul-Aug;70(7):453-8.
2. Forbes E. Paul Revere and the world he lived in. Boston: Houghton Mifflin Co. 1943.
3. Ring ME. Paul Revere—dentist, and our country's symbol of freedom. *NY State Dent J.* 1976 Dec;42(10):598-601.
4. Senn DR, Stimson PG. Forensic dentistry. Boca Raton. CRC Press. 2010.
5. Senn DR, Weems RA. Manual of Forensic Odontology. 5th edition, CRC Press: Florida, 2013.
6. Dilnot G. The trial of Professor John White Webster. 1928.
7. Marco BB. A system to assist in the identification of criminals and others by means of their teeth. *Dental Cosmos* 1898; 40, 113-6.
8. Amoëdo O. The role of the dentists in the identification of the victims of the catastrophe of the "bazar de la charite." *Dental Cosmos* 1897; 39-90-912.
9. Amoëdo O. L'Art dentaire en médecine legale. Paris: Masson et Cie, 1898.
10. Highfield R. Dental detective work gets to the root of Hitler mystery. London: Daily Telegraph, 1999. Accessed January 22, 2025.
11. Norton LE, Cottone JA, Sopher IM, et al. The exhumation of identification of Lee Harvey Oswald. *J Forensic Sci.* 1984 Jan;29(1):20. Accessed January 22, 2025.
12. Silver WE, Souviron RR. Dental Autopsy. Boca Raton. CRC Press. 2009.
13. Tohnak S, Mehnert AJ, Mahoney M, et al. Synthesizing dental radiographs for human identification. *J Dent Res.* 2007 Nov;86(11):1057-62.
14. Sweet D, Pretty IA. A look at forensic dentistry--Part 2: teeth as weapons of violence—identification of bite mark perpetrators. *Br Dent J.* 2001 Apr 28;190(8):415-8.
15. Brand RW, Isselhard DE, Satin E. Anatomy of Orofacial Structures. St Louis: Mosby; 2003.
16. Pretty IA. Forensic dentistry: 1. Identification of human remains. *Dent Update.* 2007 Dec;34(10):621-2, 624-6, 629-30.
17. McGivney J. WinID3 Dental Identification System. Accessed January 22, 2025.
18. DMORT. Disaster Mortuary Operational Response Team. Accessed January 22, 2025.
19. Pike J. National Crime Information Center (NCIC) Criminal Justice Information Services. Accessed January 22, 2025.
20. Dudley MH. Forensic Medical Investigation-A Comprehensive Review. Kansas City: Dudley Publishing, 2008. Accessed January 22, 2025.
21. Wright FD, Dailey JC. Human bite marks in forensic dentistry. *Dent Clin North Am.* 2001 Apr;45(2):365-97.
22. Dorion RBJ. Bite mark Evidence. Newy: Marcel Dekker, 2005.
23. Jessee SA. Recognition of bite marks in child abuse cases. *Pediatr Dent.* 1994 Sep-Oct;16(5):336-9.
24. Vale GL, Sognnaes RF, Felando GN, et al. Unusual three-dimensional bite mark evidence in a homicide case. *J Forensic Sci.* 1976 Jul;21(3):642-52.
25. Pretty IA, Sweet D. Anatomical location of bite marks and associated findings in 101 cases from the United States. *J Forensic Sci.* 2000 Jul;45(4):812-4.
26. ABFO. Guidelines for bite mark analysis. American Board of Forensic Odontology, Inc. *J Am Dent Assoc.* 1986 Mar;112(3):383-6.
27. Dorion RB. Bite mark evidence. *J Can Dent Assoc.* 1982 Dec;48(12):795-8.
28. Kubic T, Petraco N. Forensic science laboratory manual and workbook "forensic odontology". 3rd ed. Boca Raton: CPC Press 2009.
29. Rothwell BR. Bite marks in forensic dentistry: a review of legal, scientific issues. *J Am Dent Assoc.* 1995 Feb;126(2):223-32.
30. McNamee AH, Sweet D. Adherence of forensic odontologists to the ABFO guidelines for victim evidence collection. *J Forensic Sci.* 2003 Mar;48(2):382-5.
31. Brunkard J, Namulanda G, Ratard R. Hurricane Katrina deaths, Louisiana, 2005. *Disaster Med Public Health Prep.* 2008 Dec;2(4):215-23.



32. Child Maltreatment 2021. An office of the Administration for Children and Families, a division of U.S. Department of Health and Human Services. Accessed January 22, 2025.
33. Dong X. Medical implications of elder abuse and neglect. *Clin Geriatr Med*. 2005 May;21(2):293-313.
34. Mattoo KA, Shalabh K, Khan A. Geriatric forensics: A dentist's perspective and contribution to identify existence of elder abuse among his patients. *J Forensic Dent Sci*. 2010 Jul;2(2):81-5.
35. Grossman MD, Miller D, Scaff DW, et al. When is an elder old? Effect of preexisting conditions on mortality in geriatric trauma. *J Trauma*. 2002 Feb;52(2):242-6.
36. Collins KA, Sellars K. Vertebral artery laceration mimicking elder abuse. *Am J Forensic Med Pathol*. 2005 Jun;26(2):150-4.
37. Collins KA, Bennett AT, Hanzlick R. Elder abuse and neglect. Autopsy Committee of the College of American Pathologists. *Arch Intern Med*. 2000 Jun 12;160(11):1567-8.
38. The Elder Justice Roadmap: A Stakeholder Initiative to Respond to an Emerging Health, Justice, Financial and Social Crisis. U.S. Department of Justice. Accessed January 22, 2025.
39. Zeitler DL. Domestic violence. *J Oral Maxillofac Surg*. 2005 63(8):20-21.
40. Golden GS. Forensic odontology and elder abuse--a case study. *J Calif Dent Assoc*. 2004 Apr;32(4):336-40.
41. Golden GS. Lessons learned from the WTC disaster: a first-person account. *J Calif Dent Assoc*. 2004 Aug;32(8):675-80.
42. Public Health Emergency. National Disaster Medical System (NDNM). Accessed January 22, 2025.
43. Missouri Department of Public Safety State Emergency Management Team Missouri-1 Disaster Medical Assistance Team/Disaster Mortuary Response Team. Accessed January 22, 2025.
44. Missouri Dental Association. MERIT: Missouri Emergency Response Identification Team. Accessed January 22, 2025.
45. IMERT. Illinois Medical Emergency Response Team. Accessed January 22, 2025.
46. Department of Health & Hospitals. Identification of Katrina Victims Continues. 2005. Accessed January 22, 2025.
47. American Academy of Forensic Sciences. Accessed January 22, 2025.
48. American Academy of Forensic Sciences: Choosing a Career. Accessed January 22, 2025.
49. New York County Dental Society. Accessed January 22, 2025.
50. DMORT Region VII. Accessed January 22, 2025.

### **Additional Resources**

- No Additional Resources Available

## About the Author

### Marsha A. Voelker, CDA, RDH, MS, FADHA



Marsha Voelker is the Director of Oral Health Operations at KC CARE Health Center in Kansas City, Missouri. She continues to serve as adjunct faculty at MCC-Penn Valley Health Science Institute and faculty for graduate instruction at ODU College of Health Sciences. She is a former associate professor and junior clinic coordinator at the University of Missouri-Kansas City in the Division of Dental Hygiene where she taught a broad range of classes and facilitated the forensic dentistry practicum for thirteen years. She attended the University of North Carolina where she obtained a Master of Science degree in Dental Hygiene Education with a minor in Biological Science, a Bachelor of Science degree in Dental Hygiene and certificate in Dental Assisting. She also obtained a Bachelor of Science degree at Pfeiffer College in North Carolina. She served as a Dental Hygiene and Dental Assisting Program Director at Central Carolina Community College (CCCC) in Sanford, North Carolina. During this time, she assisted in obtaining grant funding to develop both dental programs at CCCC as well as developed both programs' curriculums, designed and managed to obtain state of the art equipment for the facility, and obtained Commission on Dental Accreditation "initial" accreditation status for both programs. Other previous experiences include working as a clinical research assistant and certified dental assistant (CDA) both in a private practice, university and hospital. She was deployed to Joplin to assist with identifications in May 2011. She is a member of several organizations including the American Dental Hygienists' Association (ADHA), American Dental Education Association (ADEA), American Society of Forensic Odontology (ASFO), Disaster Mortuary Operational Response Teams (DMORT), Missouri Emergency Response Identification Team (MERIT), Kansas City Regional Mortuary Operational Response Group (KCRMORG), Motivational Interviewing Network of Trainers (MINT), and American Legion Auxiliary (ALA). Her research interests are dental biomaterials, motivational interviewing, and forensic dentistry.

Email: voelkerm7@outlook.com