

Orthodontics: A Review

This course is no longer offered for Continuing Education credit.

Course Author(s): Calogero Dolce, DDS, PhD; Melissa Alfonso, DMD, MS

Intended Audience: Dentists, Dental Hygienists, Dental Assistants, Dental Students, Dental Hygiene Students, Dental Assistant Students

Date Course Online: 12/12/2005 **Last Revision Date:** 01/30/2017 **Course Expiration Date:** 01/29/2020

Disclaimer: Participants must always be aware of the hazards of using limited knowledge in integrating new techniques or procedures into their practice. Only sound evidence-based dentistry should be used in patient therapy.

Introduction

Orthodontics, the first specialty in dentistry, emphasizes proper occlusion and tooth alignment as well as ideal dental and facial esthetics. The American Association of Orthodontists estimates that three-quarters of the US population could benefit from orthodontic care, so it's important for dental professionals to understand the basic elements of orthodontics. This course reviews the need for orthodontic treatment, diagnostic procedures and records, biological factors affecting tooth movement, goals of orthodontic treatment, categories of treatment, popular orthodontic devices and oral hygiene considerations.

Conflict of Interest Disclosure Statement

- The authors report no conflicts of interest associated with this course.

Course Contents

- Overview
- Learning Objectives
- History of Orthodontics
- Need for Orthodontic Treatment
- Orthodontic Diagnosis and Records
 - Facial/Dental Photographs
 - Oral Exam
 - Analysis of Occlusion
 - Panoramic Radiograph
- Goals of Orthodontic Treatment
- The Biology of Orthodontic Tooth Movement
- Categories of Orthodontic Treatment
 - Preventative Orthodontics
 - Phase 1/Interceptive Orthodontics
 - Corrective Orthodontics
- References / Additional Resources
- Test Preview

Overview

Orthodontics, the first specialty in dentistry, emphasizes proper occlusion and tooth alignment, as well as ideal dental and facial esthetics. The American Association of Orthodontists estimates that three-quarters of the US population could benefit from orthodontic care, so it's important for dental professionals to understand the basic elements of orthodontics. This course reviews the need for orthodontic treatment, diagnostic procedures and records, biological factors affecting tooth movement, goals of orthodontic treatment, categories of treatment, popular orthodontic devices and oral hygiene considerations.

Learning Objectives

Upon completion of this course, the dental professional should be able to:

- Discuss the need for orthodontic treatment.
- Describe orthodontic diagnosis, analysis of occlusion and common records.
- Explain the categories of orthodontic treatment.
- Discuss popular orthodontic devices.
- Describe considerations related to oral hygiene and soft tissue.

History of Orthodontics

Orthodontics is the branch of dentistry concerned with the prevention and correction of malocclusions. Appliances for aligning teeth go as far back as the Egyptians. However, the first formal text discussing orthodontics was published in 1879 by Norman Kingsley, titled *A Treatise on Oral Deformities as a Branch of Mechanical Surgery*. At that time, Kingsley introduced extra-oral force to move teeth.

It wasn't until 1900 that orthodontics was first declared a specialty by Edward H. Angle, becoming the first dental specialty. He founded the American Association of Orthodontists (AAO), started the first independent school of orthodontics, and originated the classification of malocclusions.¹ In the early years, the goals of orthodontic treatment were to attain ideal occlusion without the extraction of teeth. Angle believed that if the teeth were placed in ideal position, good facial esthetics would result. Angle opposed the extraction of teeth; consequently, all of his cases were treated non-extraction.

As time went on, and with the introduction of cephalometrics, a number of orthodontists emphasized the importance of the relationship between the teeth and bones as well as soft tissues. In the 1930s, controversy erupted when Calvin S. Case advocated the use of extraction in treatment.² Case also recommended the use of retainers to maintain the achieved results.

Today, orthodontists evaluate a number of patient factors to individualize treatment options. Advances in the field including skeletal anchorage, digital radiography, improvements in bracket systems, and aligner therapy have allowed orthodontists to provide patients with more options and better treatment than ever before. Skeletal anchorage provides the opportunity to make dental changes not previously possible. Mini-implants, also referred to as Temporary Anchorage Devices, and mini-plates are used often today to move teeth more predictably (Figure 1) and even to help modify growth patterns. Advances in cone beam computed tomography (CBCT) allows orthodontists to obtain more information about

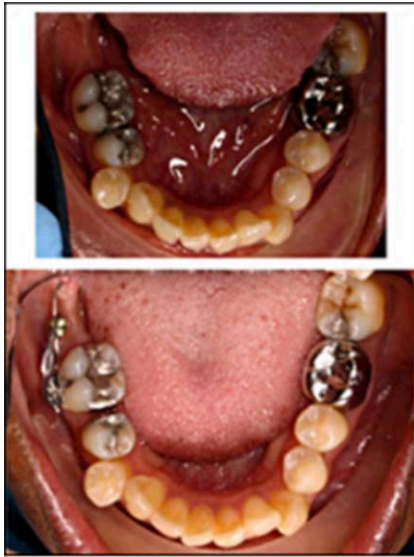

Figure 1. A mini-implant in the retromolar pad is being used to distalize the first molar in order to alleviate the premolar crowding.

tooth position and the craniofacial complex. CBCT can also be used to plan surgical treatments in adults with skeletal problems to achieve optimum surgical outcomes, occlusal relationships and facial esthetics.

Need for Orthodontic Treatment

Orthodontic need and demand varies with social and cultural conditions,³ sex, race, orthodontic status, socioeconomic status, and availability of specialist treatment services.⁴ Wheeler et al. observed orthodontic need to be less in black (35.3%) than in white children (47.2%) and demand in the higher socioeconomic groups greater (11.7%) than in the lower groups (1.8%). Findings from the National Health and Nutrition Examination Survey (NHANES III) show the average overbite to be 2.9 mm, with 8% of the population having severe overjet of 6 mm or more. Excessive overjet has been associated with increased risk of incisor injury.^{5,6}

Orthodontic Diagnosis and Records

Orthodontic Diagnosis

Orthodontic diagnosis begins with determining the patient or parent's chief complaint. Basic orthodontic records include a medical history, extraoral and intraoral exam, facial and intraoral photographs, study models, and panoramic and lateral cephalometric

radiographs. All of the records are now most commonly in digital format. If a CBCT is indicated to provide additional information, the panoramic and lateral cephalometric films should be extracted from it. In addition to their diagnostic value, the pre-treatment records are used as a baseline to evaluate treatment results.

Medical History

As in general dentistry, collecting medical history provides the orthodontist with an idea of a patient's overall medical status. Some medical conditions, such as need for antibiotic prophylaxis and diabetes could affect a patient's ability to undergo orthodontic treatment. Patients should be asked if they have any cardiovascular problems or total joint replacements that may require pre-medication before any dental procedure. Patients with growth disorders may present with more complex treatment needs. It is also important to understand what medical conditions may have sequelae in the craniofacial complex and dentition and to deduce if this might have an effect on orthodontic treatment.

There are few drugs that may complicate treatment, including chronic use of non-steroidal anti-inflammatories (NSAIDs), phenytoin, estrogen supplementation and bisphosphonates. Chronic use of NSAIDs inhibits COX-1 and COX-2 and prevents the synthesis of prostaglandins and the generation of inflammation, resulting in slowed tooth movement.⁷ Anti-epileptic drugs such as phenytoin (Dilantin) may produce gingival hyperplasia, which may slow tooth movement. Although the mechanism of action of bisphosphonates is not fully understood, these drugs tend to slow down bone turnover. Tooth movement has shown to slow proportional to the dosage amounts of bisphosphonates administered.⁷ A young patient taking medication for Attention Deficit Hyperactivity Disorder (ADHD) may have social-behavioral problems. This could be an indication of potential compliance issues in treatment. Some reports also suggest that Ritalin affects growth rates.

Lastly, any allergies should be noted. The most common allergies that may complicate orthodontic treatment are to nickel, since it is found in most wires, and latex, which is found in some elastic materials. Most nickel allergies,

unless very severe, do not generate any allergic reaction as the saliva dissipates the intraoral concentration. For patients that do experience an allergic reaction, options such as nickel-free titanium and ceramic brackets are available. In the case of a latex allergy, latex-free elastics and nitrile gloves should be used. When indicated, one should consult with the patient's physician regarding the medical condition and its implications for orthodontic treatment.

Dental History

One should inquire if the parents or siblings received orthodontic treatment, and if so, what the nature of their malocclusion was. There are some indications that there are genetic influences in many dental and occlusal characteristics, including missing and displaced teeth and certain growth patterns.⁸ It is important to ask if the patient is receiving regular dental care. It is essential for all orthodontic patients to be caries free and in good oral health prior to beginning treatment. This also provides the opportunity to determine the family's awareness of dental health. A question should be asked about whether the patient ever had any traumatic injury involving the teeth or jaws. Trauma to permanent teeth can result in devitalization or root fracture, which should be addressed by an endodontic or general dentist prior to beginning treatment. It could also result in ankylosis of the tooth which would render it unable to move. Traumatized teeth may also be subject to greater rates of root resorption. Trauma to the jaws (for example, a blow to the chin) could also cause asymmetric condylar growth and thus facial asymmetries. Any past or present habits the patient may have should also be discussed including finger habits, mouth breathing, snoring, nail biting, and several other habits. These habits can generate certain malocclusions or wear patterns on the teeth which can affect treatment and result in skeletal changes if gone untreated for extended periods of time.

Facial/Dental Photographs

Standard orthodontic photographs include extraoral and intraoral views. Extraoral photos include two frontal views of the face – one with lips at rest and another while the patient is smiling naturally, and a lateral view of

patient's right side of the face. Five intraoral views are taken: occlusal views of the upper and lower arch and a frontal, right lateral, and left lateral view while occluding. The lateral views should ideally capture the first molar and the overjet of the anterior teeth. If the patient has a shift from Centric Relation (CR) to Maximum Intercuspatation (MI), the frontal and lateral intraoral photos should be taken in both positions for proper evaluation. The patient's bite in CR reveals a more accurate jaw relationship the patient should be treated to in order to minimize interferences and optimize TMJ function.

The frontal view of the face allows a practitioner to evaluate the general shape of the face and its transverse proportions. Ideal facial symmetry in the transverse dimension is depicted in Figure 2 but is rare, as all patients have some degree of asymmetry. Asymmetries should be noted as well as deviations of the nose or chin from the facial midline (Figure 3). If large deviations from normal are noted, this may be indicative of an underlying skeletal abnormality and should be documented with a posterior-anterior cephalometric radiograph.

Facial proportions in the vertical dimension can be determined by the frontal or profile view. Ideal proportions from the frontal view are depicted in Figure 4. A well balanced face can be divided into equal thirds: the upper third is the forehead; the middle third is the area between just above the bridge of the nose (the point is known as glabella) and the base of

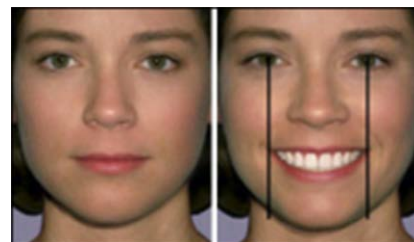

Figure 2. The width of the base of the nose approximates the intercanthal distance. The width of the mouth approximates the distance between the irises. Vertical lines dividing the face at the inner and outer canthus divide the face into balanced thirds that are symmetric around the facial midline.




Figure 3. Asymmetries should be noted from the frontal view, as well as deviations of the nose or chin from the facial midline.

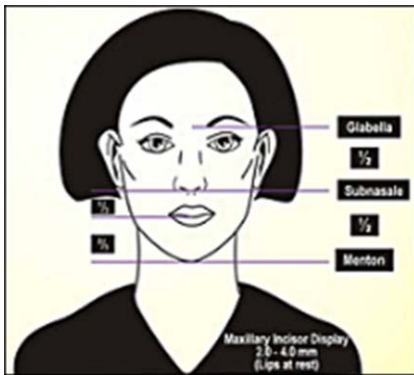


Figure 4. Ideal facial proportions in the vertical dimension.

the nose (subnasale); and the lower third runs from subnasale to the undersurface of the chin (menton). Within the lower third of the face, distance from subnasale to the upper lip should be one-half the distance from the lower lip to menton.

The two frontal views are also used to evaluate the smile and tooth show. When not smiling, the patient should ideally be lip competent, with the lips naturally touching or slightly apart without strain of the mentalis muscle. When the lips are at rest there should be a small amount of maxillary incisal display (approximately 1/3) and no gingival display. Decreased interlabial gap would be noted by drooping of the corners of the mouth at the commissures. This is found with vertical maxillary deficiency, anatomically long upper lip (natural change with aging,

especially in males), or loss of vertical dimension of occlusion in the posterior. On smile, a patient should show full maxillary incisal display with up to 2-3 mm of gingiva beyond the gingival margin of the maxillary incisors. Additional gingival display, often referred to as a “gummy smile,” is a condition that detracts from facial esthetics (Figure 5) and is indicative of an anatomic short upper lip or vertical maxillary excess. Lip incompetency and mentalis strain when closing the lips may indicate a patient has excess vertical dimension, a short upper lip, or excess support of the lips due to tooth protrusion. This becomes obvious upon full smiling.




Figure 5. “Gummy smile.”

The profile view of the face provides antero-posterior discrepancies of the maxilla and mandible in relationship to the rest of the face and to each other. A slightly convex or Class I profile indicates a balance between the maxilla and mandible (Figure 6). Discrepancies between the two jaws can produce a convex profile indicating a skeletal Class II jaw relationship, produced by a prognathic maxilla or deficient mandible (Figure 7). A straight to concave profile might indicate a skeletal Class III jaw relationship (Figure 8) due to a deficient maxilla or prognathic mandible.

The profile view also provides an opportunity to evaluate lip support. A line drawn from the tip of the nose to the tip of the chin is termed the Esthetic- line (E-line). The distance of the lips to this line aids in evaluating their support. Patients with their upper and lower lips closer

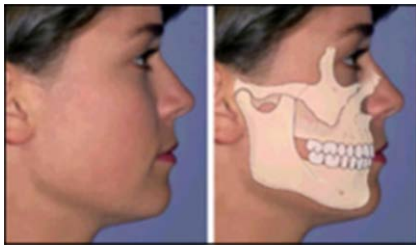


Figure 6. A profile view of the face provides antero-posterior discrepancies of the maxilla and mandible. A slightly convex or Class I profile indicates a balance between the maxilla and mandible.

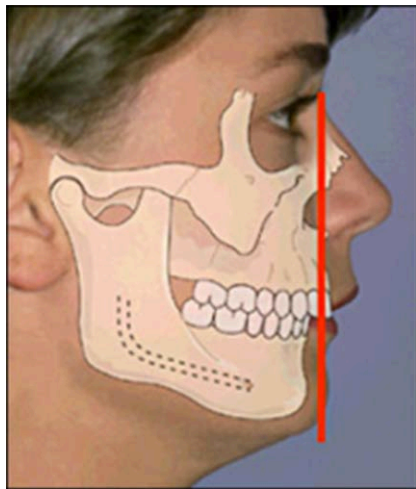


Figure 7. Skeletal Class II jaw relationship.

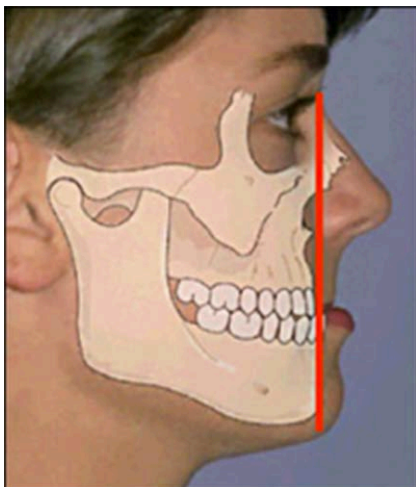


Figure 8. Skeletal Class III jaw relationship.

to this line (2-3 mm away) are often regarded as more attractive than patients with lips farther away.⁹ The nasolabial angle can also be used to evaluate the fullness of the upper lip. This angle

should ideally be around 90°. These angles, of course, need to be taken into consideration with the overall face morphology. The E-line was developed with the ideal Class I face in mind and may not apply to patients with prognathic or retrognathic mandibles. Additionally, the size of the nose may vary and may also alter the usefulness of both the E-line and the nasolabial angle. Additionally, age can play a factor in the soft tissue evaluation. With age, lips tend to get flatter and the nose grows more.¹⁰ Therefore, less support of the lips could be considered normal in an older individual. Other things that could affect the soft tissue evaluation are ethnicity and race. African Americans tend to have thicker soft tissue and more prognathic lips when compared to Caucasians that are often used to determine the norms of measurements.

Oral Exam

The examination includes:

- a. oral hygiene evaluation;
- b. extraoral exam assessing range of motion, temporomandibular joint function, and tenderness upon palpation of the muscles of mastication;
- c. health of the teeth and supporting tissues; and
- d. the relationships of the teeth within the arches and the teeth of the upper and lower jaws in respect to one another. These relationships are assessed in the antero-posterior, transverse and vertical dimensions.

Study Models

Study models are most commonly used in the digital form in orthodontics today. Good impressions of the upper and lower arch (typically with alginate) and a bite registration in centric occlusion can be sent to companies (ex: OrthoCAD) to generate digital models. The preferred material for bite registration is polyvinyl siloxane due to its improved accuracy.¹¹ Several digital scanners (ex: iTero, 3Shape Trios) can also be used to create digital models. The digital models can be used to generate a stereolithography (.stl) file that can be used to 3D print models when needed. Most laboratories accepting digital files can now provide this service for practitioners that do not have 3D printers readily available.

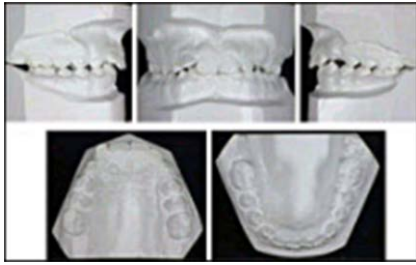

Figure 9. Study models.

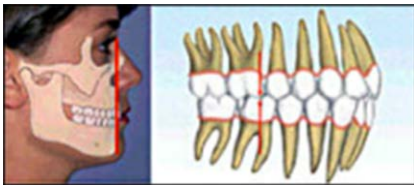


Figure 10. Class I Occlusion

Digital models have served to improve storage capability, communication among dental practitioners, and ease in diagnosis.¹² Research shows similar accuracy of linear measurements using digital models or stone models,¹³ making them useful for evaluation of tooth size and arch discrepancy, occlusal characteristics, and relationships of the teeth within the arch and between the arches (Figure 9). In-office scanners also exist to generate digital models from stone models and impressions, but are expensive and less commonly found in offices. Lastly, CBCT images can be used to generate digital models using companies such as Anatomage or CareStream, although the accuracy of CBCT generated models remains to be fully explored. Alternatively, stone models can be poured from the alginate impressions to perform the analyses. Study models, either digital or stone, are used to validate occlusal characteristics assessed from the intraoral examination and to generate a space analysis.

Analysis of Occlusion

The occlusion is evaluated in the three planes of space: antero-posterior, transverse, and vertical. Many methods have been devised to record malocclusion.¹⁴ The Ackerman and Proffit method is probably the most widely used comprehensive method. It evaluates the malocclusion in the three traditional planes of space, as well as arch perimeter, alignment and facial esthetics. Angle's

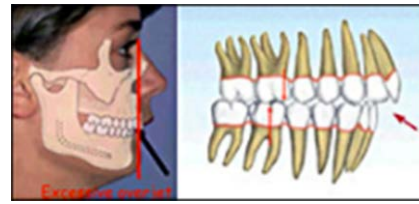


Figure 11. Class II Division 1 Occlusion.

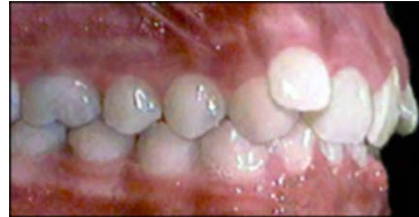

Figure 12. Class II Division 2 Occlusion.

classification of malocclusion, however, is by far the most commonly used for the molars and can be generally descriptive for categorizing of malocclusion. A sagittal evaluation of the dentition focuses on the molar Angle classification and the amount of overjet. Angle's molar classification is based on the relationship of the first molars as follows:

- A. **Class I** – The mesiobuccal cusp tip of the permanent maxillary first molar approximates the buccal groove of the permanent mandibular first molar (Figure 10). This is considered ideal occlusion.
- B. **Class II Division 1** – The maxillary mesiobuccal cusp falls anterior to the buccal groove of the mandibular molar (Figure 11). If the malocclusion is unilateral, the term subdivision is used (i.e., Class II, Division 1, Subdivision right or left). This malocclusion generally presents with excess overjet.
- C. **Class II Division 2** – The molar relationship is Class II, however the upper central incisors are retroclined, the laterals are proclined, and there is increased incisal overbite (Figure 12). When the upper teeth are aligned without any other mechanics, the overjet will become excessive as in Class II Division 1 malocclusions. If the malocclusion is unilateral, the term subdivision is used (i.e., Class II, Division 2, Subdivision right or left).
- D. **Class III** – The maxillary mesiobuccal cusp falls distal to the buccal groove of the mandibular molar (Figure 13). This type of

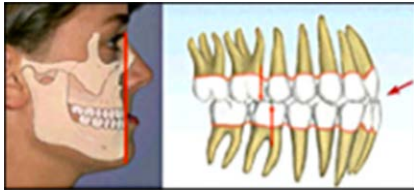


Figure 13. Class III Occlusion.

malocclusion is least common (1-2%) in whites. However, it is more common in Asians. Negative overjet or edge-to-edge incisors are often seen in this malocclusion.

Increments are often added to the classification in an attempt to quantify the severity of the relationship by approximating the fraction of a cuspal width (i.e., one-quarter cusp Class II). In the mixed dentition, a classification of one-half cusp Class II (flush terminal plane) will develop into a Class I relationship in the permanent dentition. The permanent premolars that replace the deciduous molars have a smaller mesio-distal dimension. This extra space is often termed the E space or the leeway space, and is on average about 5 mm in the mandible and 3 mm in the maxilla. This additional space in the mandible allows the permanent mandibular first molars to drift anteriorly to reach a Class I relationship.

Overjet is measured as the distance between the upper and lower incisors at the point of greatest severity. It is measured from the facial surface of the more lingual tooth (usually the mandibular incisor) and the incisal edge of the more facial incisor (usually in the maxilla). A normal overjet is 1-3 mm with the maxillary incisors in front of the mandibular incisors. Excessive overjet and a Class II molar relationship are characteristics of a Class II dental relationship. Negative overjet (anterior crossbite) combined with Class III molars are indicative of a Class III dental relationship. Individual or groups of teeth may also be found to be in anterior crossbites, sometimes referred to as a "scissor bite." This can cause abnormal wear on the teeth and destruction of the periodontal supporting tissues of those teeth. Zero mm of overjet indicates an edge-to-edge relationship. Some patients may demonstrate an edge-to-edge relationship in CR and slide into a Class III with negative overjet in MI. This

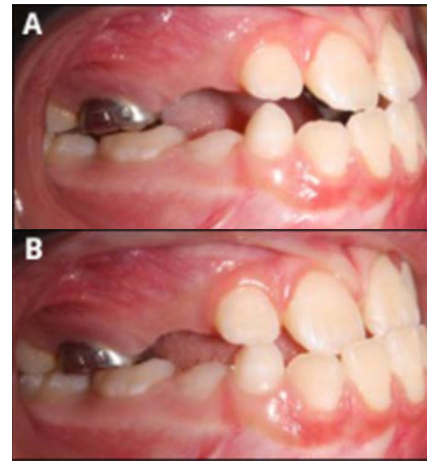

Figure 14. Pseudo Class III in (A) Centric Relation (B) Maximum Intercuspatation.

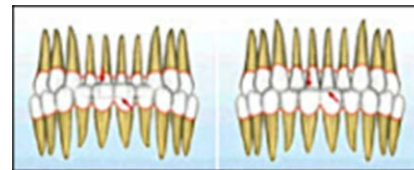


Figure 15. Vertical evaluation of the dentition focuses on overbite.

is called a pseudo-Class III and may result in excess horizontal growth in those with remaining growth, leading to a more severe Class III skeletal relationship, abnormal wear of the incisors, and TMJ discomfort. For these reasons pseudo- Class III's should be treated early with the objective of obtaining positive overjet and eliminating the shift. Vertical evaluation (Figure 15) of the dentition focuses on overbite, or the amount of overlap of the upper and lower incisors, and is usually expressed as a percentage. Ideal overlap is 10-30%. Anterior open bites consist of no overlap, or space, between the upper and lower incisors vertically (Figure 16), and can be indicative of habits such as thumb sucking or tongue thrusts, or of a more serious skeletal imbalance. On the contrary, deep bites (overbite 80-100%) can be found in developing malocclusions. Some deep bites result in impingement of the palate, which can lead to recession on the lingual of the incisors or palatal irritation from the pressure of the mandibular incisors. Many times a patient presenting with deep bite will have

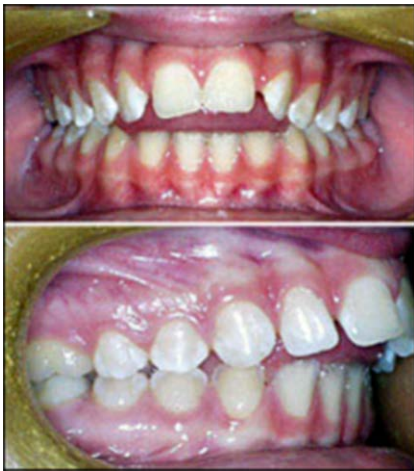

Figure 16. Anterior open bite.

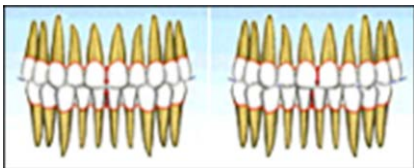


Figure 17. Midline discrepancies.

accompanying pronounced curve of spee, decreased lower facial height, with or without an associated sagittal component of excessive overjet, all of which are indicative of potential severe problems. Determining whether the problem of deep bite is caused by extrusion of the maxillary anterior teeth or minimized eruption of the posterior teeth is important in planning treatment. It is also important to assess the patient for occlusal cants with differing vertical dimensions on one side of the dentition compared to the other. An extraoral photo with the patient biting on a bite stick with the posterior teeth might improve the assessment of how severe the cant may be.

Transverse evaluation of the dentition focuses on midline (Figure 17) discrepancies and posterior crossbites (Figures 18 and 19). A midline discrepancy, in the absence of any mandibular shifts, is typically due to asymmetric crowding in one or more quadrants. Alternatively, a lateral mandibular shift may produce a midline discrepancy in MI. These patients often present with the chin being off to one side in MI, a unilateral crossbite, and asymmetric molar classifications on each side. If the midline and chin are on in CR and

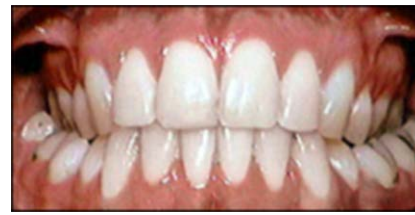

Figure 18. Bilateral posterior crossbite.

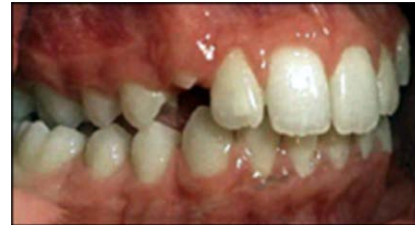

Figure 19. Posterior crossbite.

the crossbite is edge-to-edge or in crossbite bilaterally, this is an indication there is no true skeletal asymmetry and elimination of the shift can address the midline and chin deviation. When found early with growth still remaining, timing of treatment is critical to eliminate the potential for permanent facial asymmetry that could occur from the chin growing more in one direction and reduce abnormal wear of anterior teeth.

Another consideration in the development of a diagnosis is the examination of the maxillary and mandibular arches for crowding and overall position of teeth. In the primary dentition, the best indicator of potential crowding is lack of spaces between the primary teeth. Crowding in the primary dentition almost always guarantees crowding in the permanent dentition.

Orthodontists tend to be more critical when it comes to noting abnormalities in the dentition. Their threshold for noticing a midline discrepancy is lower when compared to lay people and general dentists and orthodontists. While orthodontists were found to tolerate up to a 4 mm deviation, lay people and dentists did not notice it until the midline deviation was greater.¹⁵ Midline diastemas were noted as unaesthetic at 1 to 1.5 mm by orthodontists, while dentists and lay people found it to be unaesthetic once it reached 2 mm.¹⁶ In general, orthodontists are able to detect smaller discrepancies than lay people and general dentists.

Panoramic Radiograph

The panoramic radiograph provides information on the number of teeth present, eruption problems, root form and length, quality of alveolar bone and other pathological conditions. Panoramic radiographs are also often taken during treatment to evaluate the parallelism of the roots and the presence of root resorption or blunting of the root apices. While more than 90% of orthodontic patients experience some degree of root resorption, it is helpful in patients with severe root resorption, consisting of more than 4 mm or one-third the length of the root, to take a 2-3 month pause in treatment to minimize the amount of total root resorption from orthodontic treatment.¹⁷

Lateral Cephalometric Head Film

Cephalometrics consists of the use of specific reference points to generate measurements of the craniofacial complex. These measurements are used to evaluate facial growth and development, as well as treatment outcomes. Lateral cephalograms (Figure 20) are obtained by positioning the patient's head so the median sagittal plane of the head is parallel to the plane of the film and perpendicular to the central ray of the radiation tube. The radiograph enables the orthodontist to determine craniofacial and dentofacial relationships as well as soft tissue relationships. When printed on film 8-10% of magnification exists due to the distance between the patient's head and the anode. These films are now commonly taken with a digital x-ray machine, resulting in a digital image.

Cephalometric Analysis

Cephalometric analysis consists of identifying specific anatomical points on the radiograph and using them to determine specific linear and angular measurements. These measurements are then compared with norms and used to determine skeletal, dental, and soft tissue relationships. Specific analyses have been devised, consisting of specific points and measurements to complete the evaluation. One of the first analyses to be developed was the Downs analysis,¹⁸ based on facial and skeletal proportions of 25 untreated adolescent Caucasians considered to have ideal dental occlusion. Since then many other analyses have been developed. With printed film, the

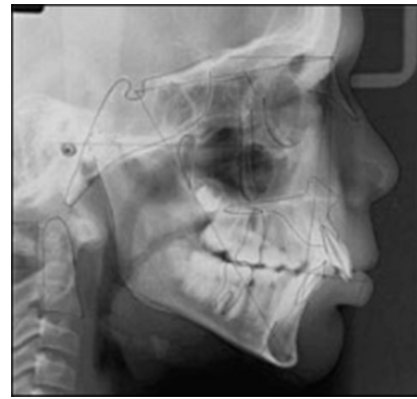

Figure 20. Lateral cephalograms.

cephalometric analysis is done via a tracing on acetate paper laid over the image. With advances in digital radiography, softwares (i.e., Dolphin Imaging, QuickCeph) have been developed to digitally adjust for magnification, choose points, and instantly have several analyses after just a few clicks. Cephalometrics provides information about the maxillary relationship to the cranial base; the mandible's relationship to the cranial base; the maxilla's relationship to the mandible; vertical skeletal relationships; lip protrusion; vertical facial proportions; and the position of the teeth to the underlying jaws.

Cone Beam Computed Tomography

The use of CBCT is indicated in a number of situations including impacted teeth, craniofacial abnormalities, suspected TMJ pathology and skeletal asymmetries.¹⁹ It can provide practitioners with a 3-dimensional image of the location and anatomy of the teeth and of the craniofacial anatomy. CBCT's can be taken in a variety of volumes which can include a group of teeth, a quadrant of an arch, a full arch, part of the head, or the full head. In cases where a CBCT is indicated, an extended view CBCT including the full head may provide less radiation than a limited view CBCT in addition to a panoramic and cephalometric radiograph. The full CBCT can be used to extract the panoramic and lateral cephalometric radiograph, as well as a P-A cephalometric radiograph when needed. Keeping the amount of radiation exposure to patients as low as possible should always be a priority, and specific indications must be present when taking additional radiographs that may increase the exposure to radiation.

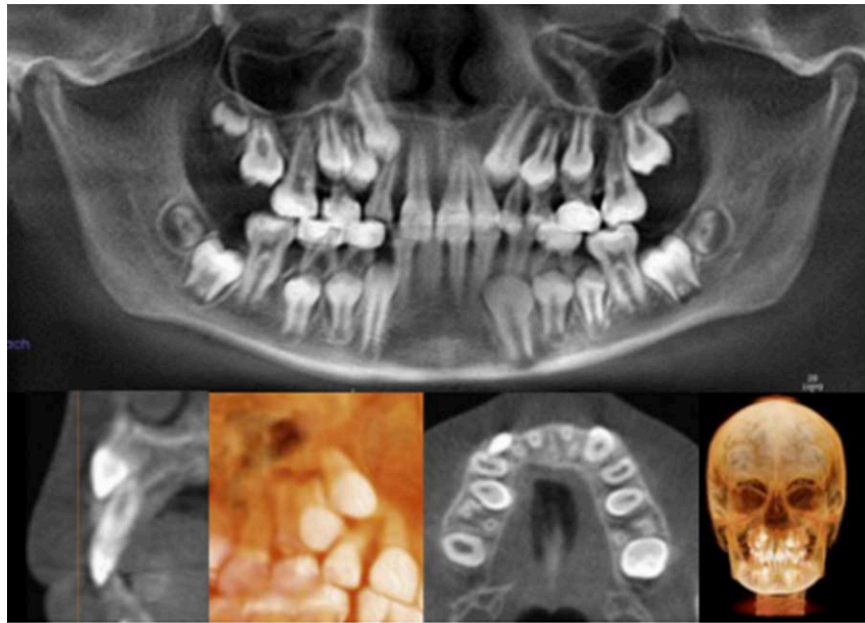


Figure 21. Use of Cone Beam Computed Tomography to locate upper right permanent canine and assess potential root resorption of the upper right lateral incisor.

The radiographic information, together with study casts and the clinical examination indicate to the practitioner what type of occlusal and skeletal correction is necessary.

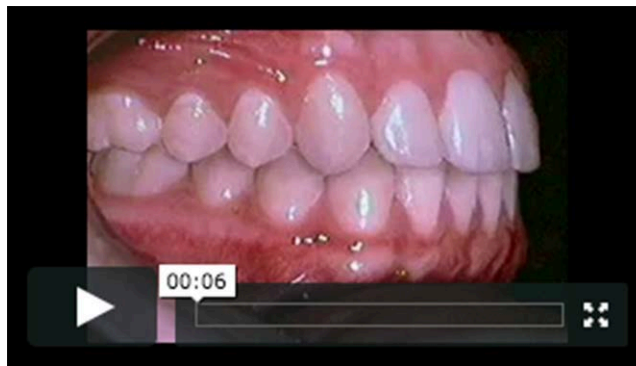
Goals of Orthodontic Treatment

According to Roth, orthodontic treatment goals can be divided into five categories: facial esthetics, dental esthetics, functional occlusion, periodontal health, and stability.²⁰ There is no one standard that can be used to determine ideal facial esthetics. Current desirable characteristics among Caucasians include a slightly convex profile, nasolabial angle of 90° or slightly obtuse, adequate lip support and curl, a symmetrical face, lip closure without strain, 1-2 mm of visible gingiva on smile, and high cheekbones. The contour of the profile should be slightly convex with the soft tissue of the jaws in a Class I relationship.

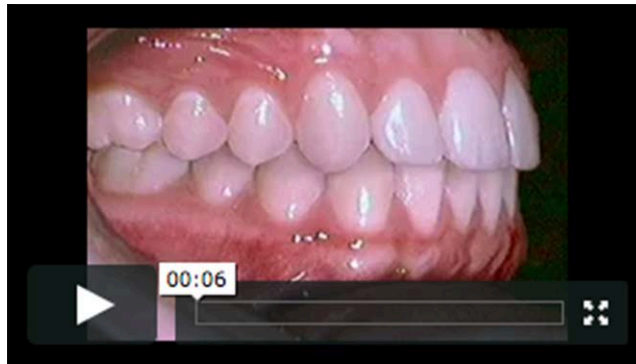
“Ideal” occlusion was first classified by Angle into the molar Class I, II, and III relationships previously discussed. Further dental esthetics were captured by Andrews in his “six keys to normal occlusion.”²¹ The first key is the molar classification, with normal being about the same as Angle’s Class I molar occlusion. Other features of normal occlusion as described by

Andrews includes adequate mesiodistal tip and torque (buccolingual tip) of the teeth; no rotations, crowding or spacing; a flat curve of spee; and central and lateral incisors with flat incisal edges and a pointed cusp tip on the canine. Ideal overbite and overjet should also be obtained. Vertically, incisal edges and the gingival zeniths should be symmetrical and at ideal heights, and the widths of the teeth should follow the golden proportion. Recently the esthetics of the smile indicate that buccal corridors (the dark space between the dentition and the corners of the lips) should be modest or reduced, although not eliminated completely. The curvature created by the incisal edges of the anterior maxillary teeth is most esthetic when following the curvature of the lower lip upon smiling.²²

In a functional occlusion, MI coincides with CR, cusps in the opposing arches are interdigitated, occlusal forces are equally spread among all the teeth, and lateral excursions have canine guidance (seen in Video 1). Group function in lateral excursions may be acceptable in cases with severe wear. No balancing interferences should be present. Protrusion should exhibit anterior guidance with posterior disclusion (Video 2).



Video 1. Cuspid Guidance in Lateral Excursions.



Video 2. Posterior Disclosure on Protrusion.

Periodontal goals include adequate alveolar bone support without dehiscences or fenestrations, good gingival crest height, no pocketing or inflammation of the attachment apparatus, adequate thickness of attached gingiva, no frenum pulls, and optimum crown-root ratios.²⁰

Most orthodontic cases exhibit some form of change or occlusal settling during the retention period after active treatment. This is a result of continued facial growth and tissue rebound. Unwanted changes in the occlusion can be minimized by avoiding unstable movements such as overexpansion of the mandibular arch and extrusion of the anterior teeth. Overcorrecting rotations, flattening interproximal contacts, eliminating undesirable neuromuscular habits, and ensuring adequate retention will also improve the stability.

The Biology of Orthodontic Tooth Movement

Orthodontic tooth movement occurs as a result of a force being placed on a tooth. It

is composed of three phases: initial tipping, lag phase and progressive tooth movement. When the force is placed on the crown of the tooth, initial tipping occurs. The periodontal ligament (PDL) is compressed adjacent to the alveolar bone on the side toward which the force is directed. On the opposite side, away from the force direction, the PDL is widened, experiencing tension. The center of resistance of the tooth is defined as the point at which a direct force would cause the tooth to move completely linearly in the direction of the applied force. Because the force is applied at the crown of the tooth, away from this center of resistance, the tooth tips. The location of the center of resistance changes depending on the length of the root and amount of periodontal bone support, thus changing the exact type of movement that occurs. These factors, in addition to the PDL width and force magnitude, affect the amount of initial tipping that occurs.²³

The lag phase represents a delay in movement, which reflects recruitment of cells and the establishment of a microenvironment that will

allow the PDL and bone to remodel. This is when osteoclasts are recruited to the area and osteoblasts are activated. The length of this phase is partially dependent on the amount of force applied. If excessive forces are applied, the root approaches the alveolar wall more closely on the compression side, and the vasculature to the area is compromised. As a result, a cell-free zone or hyalinized area is formed. The hyalinized tissue must be removed for tooth movement to occur. This occurs via undermining resorption, where osteoclasts present within the adjacent bone marrow spaces and resorb bone adjacent to the cell free area. This lag phase can last from several days to several weeks. The use of light forces can minimize the appearance of hyalinized tissue and therefore reduce the length of this phase.

The final phase represents the actual remodeling of bone, consisting of bone formation in the areas of tension and resorption in the areas of compression. This process results in the movement of the tooth, reduction of the applied strain, and appliance deactivation. In summary, bone resorption occurs on the side of compression in the PDL while formation occurs on the side of tension.

An acute inflammatory response is typically present in the early phase of orthodontic tooth movement. Cytokines, which are secreted by mononuclear cells, are chemical mediators that may interact directly or indirectly with bone cells. Cytokines, such as IL-1, can evoke the synthesis and secretion of numerous substances, including prostaglandins and a variety of growth factors. Prostaglandins have been shown to stimulate bone resorption and increase the rate of orthodontic tooth movement.²³

Categories of Orthodontic Treatment

Preventative Orthodontics

Preventative orthodontics focuses on the elimination of factors, which if left uncorrected, would result in a worsening of the malocclusion. One example would be space maintenance due to premature loss of deciduous teeth, most commonly the canines

and molars. Maintaining space is primarily indicated when permanent tooth eruption will not occur for another six months or more. Depending on the clinical situation, several techniques can be used to maintain space. Early exfoliation of canines or the deciduous molars might be an indication of ectopic eruption patterns or severe crowding and should be carefully evaluated along with the space maintenance. Another example of preventative orthodontics would be habit cessation due to a finger habit or tongue thrust.

Band and Loop Space Maintainer

This appliance is typically used to maintain space when a single primary first or second molar is lost unilaterally. It consists of a band and a wire loop to maintain the space (Figure 22). It can be used in either the maxillary or mandibular arch. If the primary second molar is lost before eruption of the permanent first molar, space maintenance is uniquely accomplished by the distal shoe, which helps to guide eruption of the first permanent molar and maintain space for the second premolar.

Lower Lingual Holding Arch

This appliance is used in the mandibular arch when bilateral space maintenance is required after loss of deciduous canines or molars. It is typically soldered to bands on the first permanent molars (Figure 23). Anteriorly, the wire rests on the lingual surfaces of the incisors. In the case of early loss of a deciduous canine, a wire spur can be soldered distal to the lateral incisor to prevent drifting of the midline. If in doubt about whether to use a Lower Lingual Holding Arch, it is usually best to put one in as there are few to no negative side effects and the potential benefits are great.

Nance Holding Arch and Transpalatal Arch

The Nance Holding Arch is used in the maxilla to maintain space (Figure 24). The wire in this appliance is attached to permanent first molar bands and extends to the anterior palate. An acrylic button along the anterior palate provides resistance to anterior drifting of the molars. The appliance is tolerated well, but soft tissue irritation can be a problem.

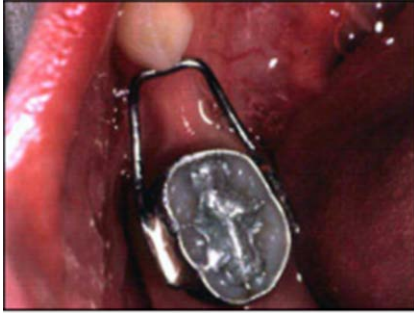

Figure 22. Band and loop space maintainer.

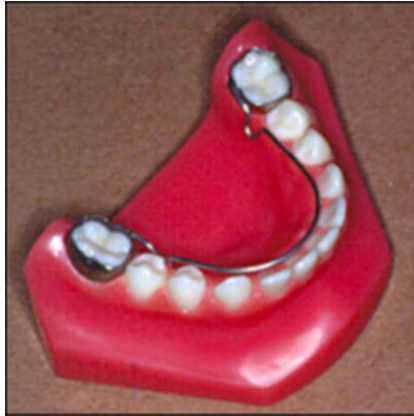

Figure 23. Lingual arch space maintainer.

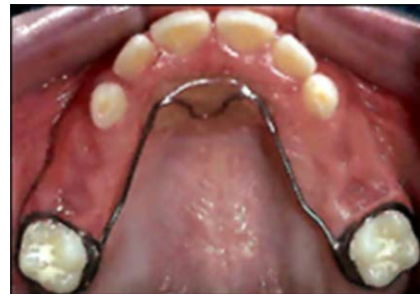

Figure 24. Nance space maintainer.

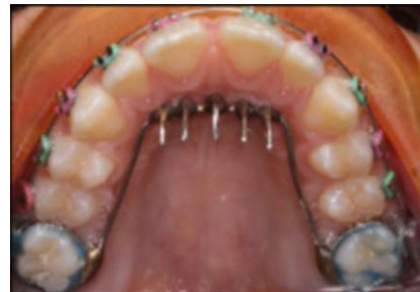

Figure 25. Lingual rake used to break a thumb habit.

Alternatively, some practitioners use a Transpalatal Arch (TPA) for the same purpose. A TPA consists of a rigid wire traversing the palate from one molar to the other with an omega loop in the center. By maintaining the transverse, the TPA maintains the molars in their A-P position as they cannot drift to a narrower part of the arch due to the cortical plate. The TPA is less irritating and easier to keep clean, but some question whether its general concept of space maintenance holds true. In cases where space maintenance is critical, the Nance Holding Arch may be a more reliable option.

Tongue Crib and Tongue Rake

Finger and tongue thrusting habits have the potential to have serious consequences if they continue after the permanent teeth erupt. They can result in open bites and narrowing of the maxillary arch, which left untreated for long periods can result in skeletal changes and require complex orthodontic and possibly surgical intervention. The use of a tongue crib or tongue rake to aid in cessation of the habit early on and correct of the malocclusion can be a simple treatment modality. These appliances consist of bands on the permanent maxillary first molars with soldered wires extending anteriorly. From these wires in the anterior, the crib or rake appliance extends down vertically to the linguo-gingival portion of the lower incisors. The crib serves to keep the tongue out of the interincisal area and as a reminder to the patient to keep their finger out of the mouth. The rake is a sharper appliance that serves as a harsher reminder. When used properly, the bite often closes spontaneously over a period of 6-9 months with good stability if the habit is truly broken. It is important to note that in order to break the habit properly, the patient has to truly understand the problem and want to break the habit. If the habit has been ongoing for a long time, with overeruption of the molars, resulting in excess vertical dimension, and a posterior crossbite, it would be best to refer the patient to an orthodontist for more comprehensive treatment.

Phase 1/Interceptive Orthodontics

The American Association of Orthodontics recommends children have an evaluation by

an orthodontist by the age of 7. Many children require the guidance of dental and facial development as a first phase of orthodontic treatment, commonly called Phase 1 or Interceptive Orthodontics. If indicated, this is typically attempted in the mixed dentition or very early in the permanent dentition. For crowding problems, some lost space can be regained using appliances to reposition teeth to their original positions. Attempts to regain space are usually limited to mild or moderate crowding, depending on a number of variables. In a case with very mild crowding, space regaining can be postponed until the patient is ready for comprehensive orthodontic treatment in the permanent dentition. Some patients have dramatic space shortages due to a general lack of space or space loss. If the crowding amounts to more than approximately 5 mm extraction of permanent teeth must be considered.

When the crowding approaches 10 mm per arch, serial extraction can be attempted if the molars are in a Class I relationship and the teeth present are in good health. The classic serial extraction procedure involves the extraction of the primary canines, which allows alignment of the incisors. The primary first molars then are extracted when the permanent first premolars have at least half of their root development. The permanent first premolars are thus encouraged to erupt before the permanent canines. Once erupted, the permanent first premolars are extracted to create space for the permanent canines. During serial extraction sequence, the patient must be monitored so as to avoid loss of space and ensure the teeth erupt in proper alignment. A form of space maintenance, such as a Lower Lingual Holding Arch or a Nance Holding Arch may be useful and prudent throughout this process.²⁴

The correction of an anterior or posterior crossbite should also be done early on. Crossbites can be of a single tooth or many teeth. A single tooth anterior crossbite can occur due to trauma, a retained primary tooth or crowding. If enough space is present, it is relatively easy to correct. Any appliance that applies a force to the lingual surface of the tooth can be used. One effective appliance is an acrylic removable appliance with a finger spring.

Another treatment option is limited bonding and banding of the affected and adjacent teeth. The upper and lower teeth may need to be disclosed while the crossbite is being actively corrected to avoid occlusal interferences. An anterior crossbite involving more than one tooth is typically indicative of more severe problems. In this case, a determination must be made if the patient initially contacts edge to edge and then slides the mandible forward into the crossbite at full closure, indicating a pseudo Class III malocclusion. Pseudo Class IIIs can be treated with orthodontics alone to correct the crossbite and slide. If there is no slide and the patient is in crossbite in centric relation, then the patient likely has a true skeletal Class III malocclusion, which should be confirmed with a lateral cephalometric radiograph and full records. A true Class III presents a more serious challenge that may require a functional appliance, orthodontics, and even orthognathic surgery in the future. Many of these also have a genetic component in which the Class III malocclusion also may present in one of the parents or siblings as well.

Posterior crossbites present with the buccal cusps of the maxillary teeth lingual to the buccal cusps of the mandibular teeth and can consist of a single tooth or multiple teeth. Whenever a posterior crossbite is present, one should examine for mandibular lateral shifts on closure. Other indications of mandibular lateral shifts are midline deviations without asymmetric crowding and facial asymmetries involving the chin. The severity of the crossbite should be evaluated with the patient in CR and treated to this position. Single-tooth crossbites are typically corrected with a crossbite elastic or with archwires in full orthodontic treatment. A W-arch or quad-helix appliance can be used to correct crossbites of multiple teeth in young children.

Posterior crossbites in the near adolescent or adolescent age groups are typically corrected using a rapid palatal expander (RPE) (Figure 26). Most RPEs consist of a midline screw, attached to bands on the permanent first molars with a heavy wire extending anteriorly along the lingual surfaces of the premolars and possibly the canines. The screw is typically activated

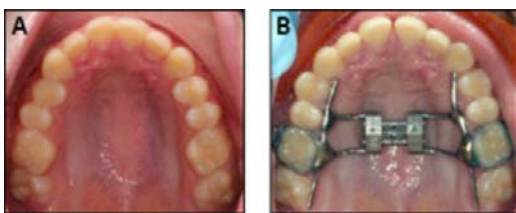


Figure 26. Rapid or slow palatal expander. (A) Prior to rapid palatal expansion (B) After expansion is complete. The expander is been tied off using a stainless steel tie to ensure the screw does not unturn during the 3-6 months of retention.

once or twice per day by the patient using a key. Each turn expands the screw 0.25 mm, and the force produced causes opening of the midline palatal suture. The opening of the diastema between the central incisors is a common sequela of RPE use and is indicative of skeletal expansion of the suture area, although the overall result of using an RPE is a combination of skeletal and dental expansion. The maxillary suture fuses around age 14-15 and occurs in females typically before males. Once this suture fuses, expansion efforts result in mostly dental movements, indicated by buccal tipping of the crowns, lack of diastema opening, and an overall unstable outcome. Once the expansion is sufficient, RPEs should be stabilized with a stainless steel tie or with composite or acrylic to seal the key hole to prevent unturning and thus relapse. All expanders should be maintained for 3-6 months post-expansion for sutural healing and stability.

Early correction of skeletal disharmonies is a great challenge in orthodontics, with the most common being a skeletal Class II malocclusion. The goal of treatment in a skeletal Class II is to redirect the growth of the jaw contributing to the skeletal problem. Early headgear and functional appliance use can result in positive changes in the skeletal positions, but research shows the outcomes are the same if treated in the permanent or late mixed dentition when the patient is ready for full orthodontic treatment.^{25,26} Therefore, early treatment for Class II patients should be reserved for patients with psychosocial concerns, esthetic complaints, or increased risk of trauma to the maxillary incisors due to excess protrusion. Early treatment for Class III problems due to

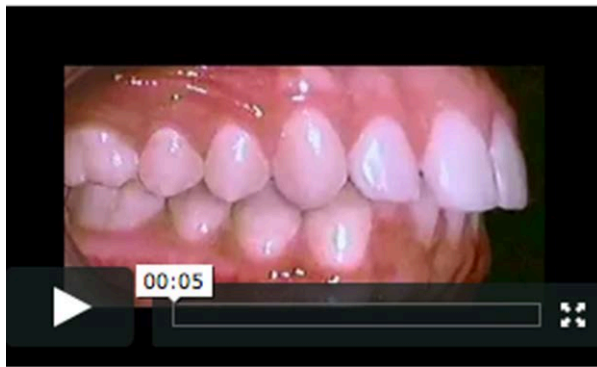
maxillary retrognathia can also be attempted using a facemask or bone anchored maxillary protraction using miniplates in the jaws. The most promising results using facemask are seen when begun prior to age 10. For Class III malocclusions due to mandibular protrusion, early treatment is not recommended.

Corrective Orthodontics

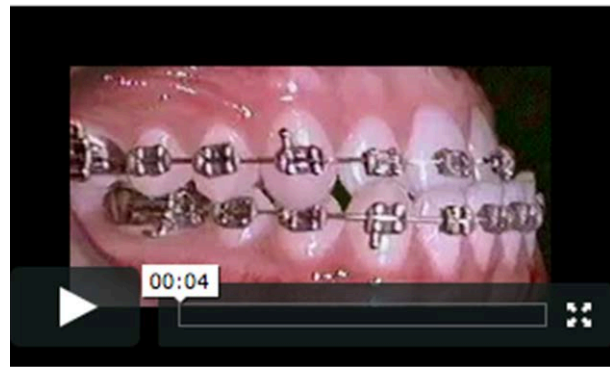Corrective orthodontics is the use of full orthodontic appliances in the permanent dentition to treat a malocclusion in either adolescents or adults. Typical corrections in AP plane include Class I (Video 3) crowding or spacing, Class II (Video 4), and Class III (Video 5) correction. Other types of correction include closing an open bite (Video 6), correcting a deep bite, or expanding the maxillary arch to correct a crossbite (Video 7). In cases with moderate to severe crowding, teeth may need to be extracted to create space. Extraction patterns can vary, including upper first premolars, a combination of premolars in the four quadrants, or even a lower incisor. Determining an extraction pattern is based on a variety of factors the orthodontist considers.

In the past 2 decades, orthodontics has seen a huge shift in patient types and preferences. About 30% of patients are adults with more specific expectations from orthodontic treatment. Patients of all ages expect esthetic options for orthodontic treatment. In response to these evolving attitudes, more esthetic alternatives to the metal brackets have been developed. Ceramic brackets provide a clear alternative that can be used with clear or opaque elastic ties. Esthetic wires and steel ties are also becoming more common. With these brackets, metal wires and ties may still need to be used. Another bracket option is lingual braces, which requires great skill from the treating orthodontist. Advancements in ceramic and lingual braces continue to occur and these systems continue to improve.

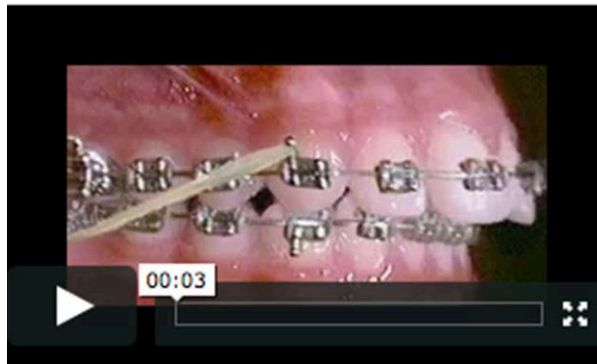
Another option for esthetic orthodontics is clear aligner therapy. A number of companies and laboratories now exist that fabricate clear aligners for orthodontic treatment. The most widely used is the Invisalign® system by Align Technology, Inc. Impressions made



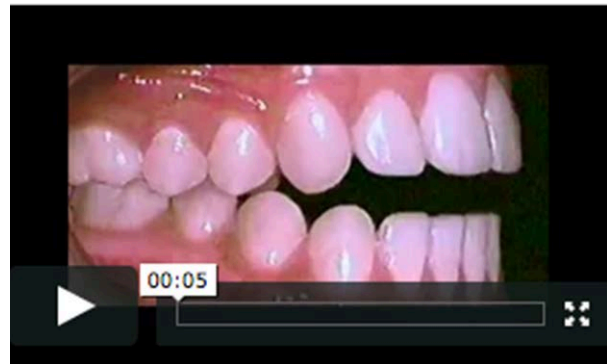
Video 3. Class I Correction.



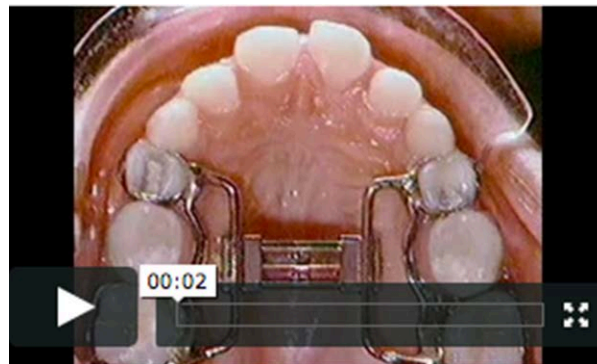
Video 4. Class II Correction.



Video 5. Class III Correction.



Video 6. Open Bite Correction.



Video 7. Maxillary Arch Expansion for Crossbite Correction.

using an intraoral scanner (iTero scanner) or polyvinyl siloxane material are provided and a series of custom made, clear, removable appliances are fabricated to sequentially move teeth. SmartTrack plastic, a proprietary plastic developed by Align Technology, and composite attachments on the teeth are simultaneously used to move teeth. Orthodontic treatment using Invisalign® has improved greatly over

the years, and can now be used with a variety of malocclusions and treatment options. It is important for the practitioner using Invisalign® to fully understand its principles, as well as those behind orthodontic tooth movement in general, to be able to use the system properly and to its full capacity. The best outcomes are seen when patients are compliant, wearing aligners for a minimum of 22 hours per day.

Tissue Considerations and Oral Hygiene during Orthodontic Treatment

Oral hygiene is of paramount importance during orthodontic treatment. The role of dental plaque accumulation in the development of dental caries and periodontal diseases is well documented. While orthodontic appliances do not cause dental caries, they provide increased possibilities for the retention of food debris and plaque. The unwanted effects of enamel decalcification, white spot lesions, and gingival inflammation can be prevented if good oral hygiene is followed. Orthodontic appliances encourage accumulation of microbial flora and food residues and make good oral hygiene much more challenging. Various toothbrush devices, mouth rinses and other home care products are available to help the patient achieve optimum oral hygiene. This added plaque accumulation, in addition to the appliances, can stain patients' teeth, and many patients choose to whiten their teeth after orthodontic treatment for more esthetic results.

Retainers

Once the malocclusion is corrected and the braces are removed, patients enter the retention phase of orthodontics. Once out of orthodontic treatment, the gingival fibers tend

to pull teeth towards their original positions. Retainers serve to hold the teeth and prevent this from occurring. Options for retainers include removable and fixed. Patients are advised to wear the retainers for a certain number of hours daily, and cooperation is very important in order to maintain the results of orthodontic treatment. Common removable retainers include Hawley-type retainers, made of acrylic and wire, and clear, or Essix, vacuum-formed retainers. Other unique retainers also exist for specific malocclusions and retention needs.

Fixed retention usually consists of a bonded wire to the lingual of the incisors. The most commonly fixed lingual retainers are for the mandibular canines and incisors, and can be bonded to only the canines or to each tooth. The initial presentation of the dentition and the orthodontic movements that occurred in treatment are used to determine the best option for the patient. Bonded retention can also be used in the maxillary arch in cases with midline diastemas or severe rotations. While bonded retainers require less patient cooperation, they require increased oral hygiene measures to maintain the cleanliness and periodontal health of the teeth bonded.

Course Test Preview

- 1. Who first declared orthodontics a specialty?**
 - A. Calvin S. Case
 - B. Norman Kingsley
 - C. Stuart Proffit
 - D. Edward H. Angle
- 2. Findings from the National Health and Nutrition Examination Survey (NHANES III) show the average overbite in the U.S. to be ____.**
 - A. 1.2 mm
 - B. 2.9 mm
 - C. 3.8 mm
 - D. 4.6 mm
- 3. Typical orthodontic records include a ____.**
 - A. medical history and oral exam
 - B. facial and intraoral photographs
 - C. panoramic and a lateral cephalogram head film
 - D. All of the above.
- 4. A profile view of the face provides ____ discrepancies of the maxilla and mandible.**
 - A. antero-posterior
 - B. midline
 - C. Both A and B.
 - D. Neither A nor B.
- 5. Discrepancies between the maxilla and mandible can produce a convex profile indicating a skeletal Class II jaw relationship or a straight to concave profile indicating a skeletal ____ jaw relationship.**
 - A. Class I
 - B. Class II
 - C. Class III
 - D. None of the above.
- 6. Within the lower face, the ratio of upper lip to lower lip should equal ____.**
 - A. 1:1
 - B. 1:2
 - C. 2:1
 - D. 1:3
- 7. Additional gingival display, often referred to as a ____ is a condition that detracts from facial esthetics.**
 - A. gummy smile
 - B. overbite
 - C. underbite
 - D. overjet

8. **Which type of malocclusion is considered ideal?**
A. Class I
B. Class II
C. Class III
D. None of the above.
9. **Vertical evaluation of the dentition focuses on overbite or the amount of overlap of the incisors and is usually expressed as a percent. Ideal overlap is ____.**
A. 5-10%
B. 15-25%
C. 10-30%
D. 20-30%
10. **In general, orthodontists are able to detect _____ discrepancies than lay people and general dentists.**
A. fewer
B. smaller
C. greater
D. None of the above.
11. **Angle's classification of malocclusion is the study of the measurements of the head with relation to specific reference points used for evaluation of facial growth and development and treatment including soft-tissue profile.**
A. True
B. False
12. **Which of the choices below is one of the five categories for orthodontic treatment goals?**
A. Periodontal health
B. Stability
C. Functional occlusion
D. All of the above.
13. **During the "lag phase" of orthodontic tooth movement, tissue turnover occurs, which allows reduction of the applied strain terminating in tooth movement and appliance deactivation.**
A. True
B. False
14. **Bone resorption is dominant in _____ areas, and bone formation is dominant in areas of _____.**
A. pressure / tension
B. tension / pressure
C. tension / turnover
D. gingival health / subgingival calculus
15. **A prime example of _____ treatment involves space maintenance from premature loss of teeth.**
A. interceptive
B. corrective
C. retention
D. preventive

- 16. An example of interceptive orthodontics is _____.**
- A. elimination of thumb and finger sucking
 - B. correction of anterior or posterior crossbite
 - C. an adult wearing aligners
 - D. None of the above.
- 17. Single-tooth crossbites are typically corrected with which of the following appliances?**
- A. Rapid palatal expander
 - B. Slow palatal expander
 - C. W-arch
 - D. Retainer
- 18. Esthetic options for orthodontic treatment include _____.**
- A. ceramic brackets
 - B. clear aligner therapy
 - C. lingual braces
 - D. All of the above.
- 19. An alternative to the removable retainer is the _____ often referred to as permanent retainers.**
- A. direct-bonded lingual retainers
 - B. aligners
 - C. band and loop space maintainer
 - D. Hawley-type retainer
- 20. Unwanted outcomes of orthodontic treatment that can be prevented with proper oral hygiene include _____.**
- A. mouth sores
 - B. decalcification (white spot lesions)
 - C. gingival inflammation
 - D. B and C

References

1. Angle EH. Treatment of malocclusion of the teeth and fractures of the maxillae; Angle's system, 6th ed. Philadelphia, PA. White Dental Manufacturing Co., 1900.
2. Case CS. The question of extraction in orthodontics. *Am J Orthod.* 1964;50:658-691.
3. Tulloch JF, Shaw WC, Underhill C, et al. A comparison of attitudes toward orthodontic treatment in British and American communities. *Am J Orthod.* 1984 Mar;85(3):253-9.
4. Wheeler TT, McGorray SP, Yurkiewicz L, et al. Orthodontic treatment demand and need in third and fourth grade schoolchildren. *Am J Orthod Dentofacial Orthop.* 1994 Jul;106(1):22-33. doi: 10.1016/S0889-5406(94)70017-6.
5. Kania MJ, Keeling SD, McGorray SP, et al. Risk factors associated with incisor injury in elementary school children. *Angle Orthod.* 1996;66(6):423-32. doi: 10.1043/0003-3219(1996)066<0423:RFAWII>2.3.CO;2.
6. Shulman JD, Peterson J. The association between incisor trauma and occlusal characteristics in individuals 8-50 years of age. *Dent Traumatol.* 2004 Apr;20(2):67-74. doi: 10.1111/j.1600-4469.2004.00234.x.
7. Bartzela T, Türp JC, Motschall E, et al. Medication effects on the rate of orthodontic tooth movement: a systematic literature review. *Am J Orthod Dentofacial Orthop.* 2009 Jan;135(1):16-26. doi: 10.1016/j.ajodo.2008.08.016.
8. Mossey PA. The heritability of malocclusion: part 2. The influence of genetics in malocclusion. *Br J Orthod.* 1999 Sep;26(3):195-203. doi: 10.1093/ortho/26.3.195.
9. Matoula S, Pancherz H. Skeletofacial morphology of attractive and nonattractive faces. *Angle Orthod.* 2006 Mar;76(2):204-10. doi: 10.1043/0003-3219(2006)076[0204:SMOAAAN]2.0.CO;2.
10. Bishara SE, Jakobsen JR, Hession TJ, et al. Soft tissue profile changes from 5 to 45 years of age. *Am J Orthod Dentofacial Orthop.* 1998 Dec;114(6):698-706.
11. Sweeney S, Smith DK, Messersmith M. Comparison of 5 types of interocclusal recording materials on the accuracy of articulation of digital models. *Am J Orthod Dentofacial Orthop.* 2015 Aug;148(2):245-52. doi: 10.1016/j.ajodo.2015.04.025.
12. Hajeer MY, Millett DT, Ayoub AF, et al. Applications of 3D imaging in orthodontics: part II. *J Orthod.* 2004 Jun;31(2):154-62. doi: 10.1179/146531204225020472.
13. Luu NS, Nikolcheva LG, Retrouvey JM, et al. Linear measurements using virtual study models. *Angle Orthod.* 2012 Nov;82(6):1098-106. doi: 10.2319/110311-681.1. Epub 2012 Apr 24.
14. Tang EL, Wei SH. Recording and measuring malocclusion: a review of the literature. *Am J Orthod Dentofacial Orthop.* 1993 Apr;103(4):344-51.
15. Kokich VO Jr, Kiyak HA, Shapiro PA. Comparing the perception of dentists and lay people to altered dental esthetics. *J Esthet Dent.* 1999;11(6):311-24.
16. Kokich VO, Kokich VG, Kiyak HA. Perceptions of dental professionals and laypersons to altered dental esthetics: asymmetric and symmetric situations. *Am J Orthod Dentofacial Orthop.* 2006 Aug;130(2):141-51. doi: 10.1016/j.ajodo.2006.04.017.
17. Weltman B, Vig KW, Fields HW, et al. Root resorption associated with orthodontic tooth movement: a systematic review. *Am J Orthod Dentofacial Orthop.* 2010 Apr;137(4):462-76; discussion 12A. doi: 10.1016/j.ajodo.2009.06.021.
18. Downs WB. Analysis of Dentofacial Profile. *Angle Orthod* 1956;26:296-309.
19. Kapila SD, Nervina JM. CBCT in orthodontics: assessment of treatment outcomes and indications for its use. *Dentomaxillofac Radiol.* 2015;44(1):20140282. doi: 10.1259/dmfr.20140282.
20. Creekmore TD, Cetlin NM, Ricketts RM, et al. JCO roundtable: diagnosis and treatment planning. *J Clin Orthod.* 1992;26:585-606.
21. Andrews LF. The six keys to normal occlusion. *Am J Orthod.* 1972 Sep;62(3):296-309.
22. Bhuvaneshwaran M. Principles of smile design. *J Conserv Dent.* 2010 Oct;13(4):225-32. doi: 10.4103/0972-0707.73387.
23. Dolce C, Malone JS, Wheeler TT. Current concepts in Biology of orthodontic tooth movement. *Semin Orthod.* 2002;8:6-12.
24. Bahreman A. Early-age orthodontic treatment. Hanover Park, IL. Quintessence Pub. 2013.

25. Tulloch JF, Proffit WR, Phillips C. Outcomes in a 2-phase randomized clinical trial of early Class II treatment. *Am J Orthod Dentofacial Orthop.* 2004 Jun;125(6):657-67. doi: 10.1016/S088954060400160X.
26. Dolce C, McGorray SP, Brazeau L, et al. Timing of Class II treatment: skeletal changes comparing 1-phase and 2-phase treatment. *Am J Orthod Dentofacial Orthop.* 2007 Oct;132(4):481-9. doi: 10.1016/j.ajodo.2005.08.046.

About the Authors

Calogero Dolce, DDS, PhD



Dr. Calogero Dolce is a Professor, Chair and graduate program Director in the Department of Orthodontics at the University of Florida. Dr. Dolce completed his DDS and PhD at State University New York-Buffalo and a certificate in orthodontics at the University of Florida. He is a Diplomat of the American Board of Orthodontics. His research interests are in the biology of tooth movement, the treatment of Class II malocclusion and the repair of cleft lip and palate. He has been involved in three clinical trials funded by NIH/NICDR. Dr. Dolce

has published more than 50 articles related to orthodontics and serves as a reviewer for various journals including the *Journal of Dental Research*, the *American Journal of Orthodontics and Dentofacial Orthopedics* and *Angle Orthodontics*. He has lectured at national and international meetings. Dr. Dolce is involved in teaching orthodontic residents and is part of intramural faculty practice.

Email: cdolce@dental.ufl.edu

Melissa Alfonso, DMD, MS



Melissa Alfonso Sedeño is a practicing orthodontist in Miami, Florida. Dr. Alfonso completed her orthodontic training at the University of Florida, receiving an orthodontic certificate and a Master's in Dental Sciences degree. Her thesis focused on the use of vibration to accelerate orthodontic tooth movement. During her residency, she served as Chief Resident and received the 2016 Charley Schultz Resident Scholar Award from the American Association of Orthodontists. She also presented her research at the 2015 OrthoVoice meeting. Dr. Alfonso

also attended the University of Florida for her Bachelor's of Arts in Political Science and Doctor of Dental Medicine degrees.

Email: malfonso@dental.ufl.edu