

New and Evolving Concepts in Orthodontics

This course is no longer offered for Continuing Education credit.

Course Author(s): Melissa Alfonso, DMD, MS; Calogero Dolce, DDS, PhD

Intended Audience: Dentists, Dental Hygienists, Dental Students, Dental Hygiene Students

Date Course Online: 05/01/2017

Last Revision Date:

Course Expiration Date: 04/30/2020

Cost: Free

Method: Self-instructional

AGD Subject Code(s): 370

Disclaimer: Participants must always be aware of the hazards of using limited knowledge in integrating new techniques or procedures into their practice. Only sound evidence-based dentistry should be used in patient therapy.

Introduction

The field of orthodontics has changed markedly in recent years. This course reviews some of the many advances in orthodontics and their impact on patient care. Some of these advances include the use of clear aligner therapy, use of technology, accelerating orthodontic tooth movement, and use of skeletal anchorage.

Conflict of Interest Disclosure Statement

- The authors report no conflicts of interest associated with this course.

Course Contents

- Overview
- Learning Objectives
- Introduction
- Acceleration of Orthodontic Tooth Movement
 - Optimal Forces
 - Low-Level Laser Therapy and LED
 - Periodontal Procedures
 - AcceleDent
 - Pharmacological Factors
- Considerations in Aligner Therapy
- Skeletal Anchorage
 - Temporary Anchorage Devices, MiniScrews
 - Miniplates
- Technology
- Conclusion
- Course Test
- References
- About the Authors

Overview

The field of orthodontics has changed markedly in recent years. An increase in available clear brackets and clear aligner systems, such as Invisalign® and ClearCorrect®, have contributed to adult electivity, as many patients in this population may oppose the idea of metal braces and wires. There has also been an increase in demand for shortened treatment time, leading research to seek ways to accelerate treatment. Other evolutions in orthodontics include the use of skeletal anchorage to improve control of tooth movement, as well as a surge of technology including digital scanners and cone beam computed tomography. This course reviews some of the many advances in orthodontics and their impact on patient care.

Learning Objectives

Upon completion of this course, the dental professional should be able to:

- Describe the basic biology behind orthodontic tooth movement and how optimal forces improve tooth movement.
- Explain several ways in which orthodontic tooth movement might be accelerated.
- Discuss some of the benefits and limitations of treating orthodontic patients with aligner therapy.
- Describe two types of skeletal anchorage and how they may be used during orthodontic treatment.

- Discuss how technological advances are affecting the orthodontic field.

Introduction

The field of orthodontics has changed markedly in recent years. The most recent Economics of Orthodontics Survey by the American Association of Orthodontists (AAO) in 2014 reported that 28% of all orthodontic patients are adults.¹ This number has gradually been increasing, 14% higher than in 2012, and is markedly higher than 1970 when only 6.9% of patients were over the age of 21.² Adults in the 2014 survey attributed seeking orthodontic treatment for improvements in relationships and careers, and 92% of the respondents reported that they would recommend other adults seek orthodontic treatment.¹ This rise in adult orthodontic treatment is likely also related to an increased emphasis on esthetics in dentistry.

An increase in available clear brackets and clear aligner systems, such as Invisalign® and ClearCorrect®, have contributed to adult electivity, as many patients in this population may oppose the idea of metal braces and wires. Clear aligner therapy also improves the ability to maintain good oral hygiene and healthy gingival tissues. The growth of this patient population has also led to the emphasis on accelerating tooth movement to shorten the overall treatment time. Proposed methods to accelerate orthodontic tooth movement have ranged from pharmacological methods to vibration and will be discussed here. Further evolutions in orthodontics include the use of skeletal anchorage to improve control of tooth movement, as well as a surge of technology including digital scanners and cone beam computed tomography.

Acceleration of Orthodontic Tooth Movement

Optimal Forces

Orthodontic tooth movement (OTM) consists of three phases resulting from cell signaling in the periodontal ligament (PDL) and the interaction of these factors with osteoclasts and osteoblasts within the bone. The initial application of a force displaces the tooth and results in compression of

the PDL on the side of the tooth towards which it is being moved and tension on the opposing side. This is followed by the lag phase during which no movement occurs. Biologically, this period consists of the removal of hyalinization within the PDL which is caused by blood vessel occlusion. The osteoclasts which remove the hyalinized tissue are recruited by the release of receptor activator of nuclear factor kappa-B ligand (RANKL) via the Prostaglandin E₂ pathway, leading to the upregulation of osteoclasts. The layer of necrotic or hyalinization tissue must be removed before OTM can occur. In the final stage of OTM, bone resorption and linear tooth movement occur.³⁻⁵

One proposed method, and the most commonly used to efficiently move teeth, is to apply optimal forces to minimize the amount of hyalinization tissue that occurs as a result of force application. Storey suggested using a light force to minimize the necrosis of cells and tissues in the PDL, leading to smaller areas of hyalinization, faster resorption, improved quality of bone, reduced root resorption and a reduced relapse potential.⁶ The actual amount of this force may vary based on the tooth's root surface anatomy, bone support, location of the tooth in the mouth, and the specific movement being attempted. This concept is now applied almost universally in orthodontic treatment with the evolution of nickel titanium (NiTi) and superelastic copper nickel titanium (CuNiTi) wires for initial leveling and aligning in orthodontic treatment. Furthermore, studies have shown that among nickel titanium wires, heat activated ones deliver force levels that are lighter and more constant compared to traditional nickel titanium wires.⁷

Low-Level Laser Therapy and LED

Use of laser therapy to modify OTM was introduced in 2000 by Kawasaki and Noriyoshi. Using a Ga-Al-As diode laser, OTM in rats was 1.3 times greater than controls with an increase of osteoblasts on the tension side and osteoclasts on the compression side. The laser specifications were 830 nm continuous wavelength and 100mW power used for three minutes at three sites around the experimental tooth.⁸ Several other studies have been conducted in humans subsequently, demonstrating 1.34 to 2 times the rate of OTM following laser treatment⁹⁻¹¹

and reduced pain perception.¹¹ Biological changes have been determined to be increases in osteoblast and osteoclast proliferation, resulting in increased bone remodeling and OTM.¹² Sousa et al. hypothesized a mechanism of increased adenosine triphosphate and thus cell metabolism.¹³ Shirazi et al. used an alternative In-Ga-Al-P laser in rats, showing 2.3 times the amount of OTM and 1.5 times more osteoclasts on the compression side compared to controls.¹⁴

While one study among the extensive literature showed no effect on OTM rate using laser,¹⁵ the majority of studies have shown positive effects in both animal and human models. Conversely, some recent studies have shown that laser therapy failed to accelerate OTM.^{16,17} Some considerations may be the type of laser, frequency, and technique, as well as type of tooth movement attempted. *While this technique is being investigated, a high level of evidence is still lacking to conclude whether or not this technique is effective in accelerating OTM and what procedure may be the most effective.* Properly understanding the mechanism behind the acceleration of OTM with laser therapy may provide an improved understanding of the procedure and encourage practitioners to try it in their practices.

Light Emitting Diode (LED) has been used as an alternative form of photobiomodulation. It has been claimed as less coherent than low level laser therapy and less prone to root resorption. In rats, 0.49mm more OTM was seen over a 3-week period with decreased amounts of root resorption.¹⁸ Another study evaluating canine retraction in human subjects found faster OTM in those using this technology.¹⁹ The OrthoPulse[®] LED device has been developed by Biolux and FDA approved for application of LED in orthodontic patients to help accelerate OTM.

Periodontal Procedures

William Wilcko, an orthodontist, and his brother, Thomas Wilcko, a periodontist, popularized surgical periodontal procedures to accelerate OTM. Corticotomies consist of perforations in the cortical bone over teeth being orthodontically moved in an effort to increase the inflammatory response.²⁰ This procedure works by increasing the amount of inflammation and inflammatory markers in the area which also play a role in

bone turnover, a concept known as Regional Acceleratory Phenomenon, or RAP. Animal studies show that corticotomy can accelerate OTM up to 2-4 times as soon as 2 weeks after the procedure.^{21,22} The inflammatory effect of corticotomies fades over time, so the inflammation should be taken advantage of early on.²¹ Histological evidence shows increases in the number of osteoclasts and in the activity of osteoclasts, fibroblasts, cementoblasts, and osteoblasts. These changes indicate an effect on both the bone forming and bone resorbing portions of the bone remodeling cycle.²¹ Teeth also experienced less undermining resorption, hyalinization and root resorption.²² A human study of corticotomy resulted in 28-33% faster forced eruption of an impacted canine compared to controls, with no adverse side effects on the

periodontium.²³ Long et al., in a systematic review, found that the use of corticotomies resulted in greater distances of tooth movement for up to four months.²⁴ The use of corticotomies, often in conjunction with bone grafting, has been termed Periodontally Accelerated Osteogenic Orthodontics (PAOO), as shown in Figure 1. While the evidence indicates that the use of these surgical procedures may accelerate tooth movement, this effect is primarily seen in the first few months after while the inflammatory response is increased, and consists of lower levels of evidence.²⁵ More research is needed to improve our understanding of the effects of these procedures.

Other, less invasive, variations of this technique used to accelerate OTM are corticision, showing an increase in bone formation,²⁶ and piezopuncture,

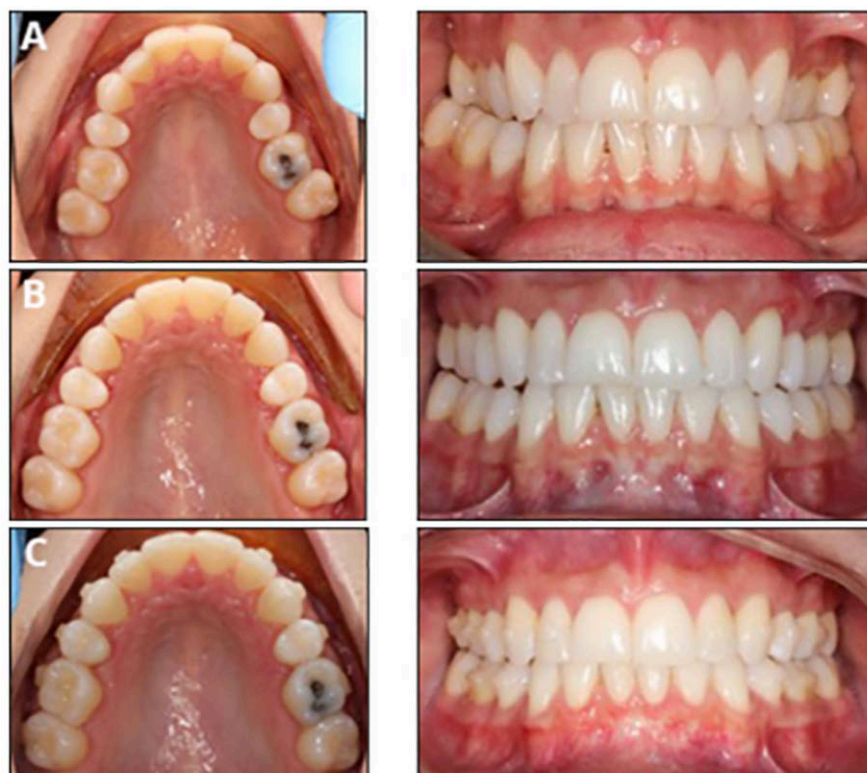

Figure 1. Before and after using PAOO in conjunction with Invisalign® for expansion in the maxilla in an adult patient.

The procedure was used to improve periodontal support and accelerate treatment.

A. Initial photos show maxillary constriction, posterior crossbites, and lack of bone and gingival support buccal to the maxillary posterior segments.

B. Progress photos after fourteen aligners were used in the maxillary arch only over 8 weeks of treatment. These photos were taken just prior to impressions for first set of Additional Aligners.

C. Progress photos after first set of Additional Aligners in preparation for another set of Additional Aligners as a refinement.

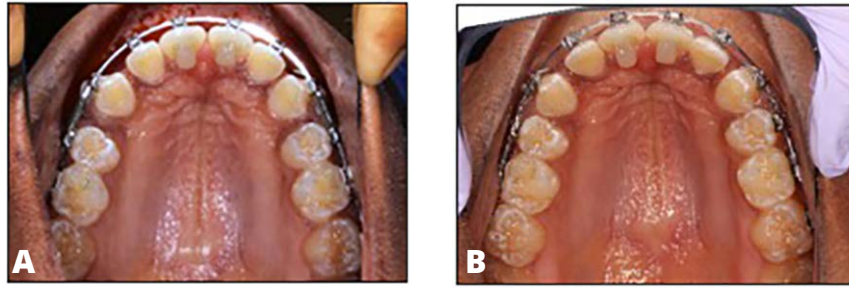


Figure 2. The PROPEL® system used to retract upper canines into extraction spaces after several months of attempted space closure.

A. Day that PROPEL® micro-osteoperforations were placed.

B. Eight weeks after. Left space is completely closed, right space has minor space remaining.

which can accelerate OTM up to 3.26 times.²⁷ Biologically these procedures were shown to reduce the lag phase, decrease hyalinization, and increase bone resorption. Fiberotomy, the removal of the dento-gingival fibers around the crowns, has also been shown to OTM rate by increasing bone resorption.²⁸ While the use of periodontal procedures is encouraging, it is important to recognize that animals have been the main model for studying their use. No studies have been conducted in humans to compare the treatment modalities to one another, and the majority of research evaluates the use of corticotomy, which is also the most invasive. More studies are needed to determine the most advantageous protocol for the purpose of accelerating OTM. The added disadvantage of increased cost of an additional procedure by a different specialist should also be considered,²⁹ as well as the added risks such as infection and inflammation.

The PROPEL® system (Figure 2), used to make micro-osteoperforations in the cortical bone by the orthodontist, was recently found to close maxillary premolar extraction spaces via canine retraction 2.3 times faster. This system increases inflammatory markers, accelerating treatment by 62%, and allows for the orthodontic practitioner to do the procedure instead of needing to refer out to another specialist.³⁰ Additional high level research is also needed to fully understand the effects of this with orthodontic treatment.

AcceleDent®

AcceleDent® Aura is a new device in the orthodontic field which has been marketed to accelerate the rate of OTM. The device consists of

a mouthpiece that the patient bites on, attached to an extraoral activator. The device vibrates at 30Hz, 25g (0.25N) and is intended to be used for 20 minutes daily.^{31,32} The use of vibration to alter bone remodeling is based on research findings which found vibration to enhance bone density³³⁻³⁶ and bone fracture healing,^{37,38} increase amounts of osteoblasts,³⁹ and increase bone remodeling.⁴⁰ In the dental field, vibration has been shown in animals to improve healing and thicken trabeculae of extraction sites in rats,⁴¹ and increase OTM, osteoclasts, and RANKL expression.⁴²

In humans, no increased root resorption was found in subjects using the device during 6 months of orthodontic treatment, confirming the device's safety.³¹ Another clinical trial showed 67% compliance rates and improved satisfaction and discomfort over time, with negative side effects being drooling and noise.³² An initial randomized control trial with subjects using the device 20 minutes daily during the retraction of upper canines into upper first premolar extraction sites showed 0.37mm more OTM per month in the group using the AcceleDent® device, resulting in 48.1% faster OTM in the group with the vibration.⁴³ Another study found a 30% increase in the rate of leveling in the initial orthodontic stages.⁴⁴ Conversely, a randomized trial found no alteration in leveling and aligning rates when using the device.⁴⁵ While the AcceleDent® Aura is currently FDA approved for fixed orthodontic treatment, its efficacy is still unclear.

Pharmacological Factors

Various studies have evaluated the use of injecting cell signaling molecules and hormones to alter

and accelerate the biological mechanism of OTM. With the injection of any substance, consideration needs to be given to the potential systemic side effects that might occur if the substrate is not maintained locally. Injection of parathyroid hormone (PTH), a mediator of bone turnover and osteoclast differentiation in OTM, has been shown in animals to increase the rate of OTM up to 1.6 times,⁴⁶ due to increased osteoclasts, bone resorption, and apposition on the tension side of tooth movement.⁴⁷ Submucosal injections of Prostaglandin E₁ (PGE₁) have been found to increase OTM in humans by a rate of 1.6 to 2 times.⁴⁸ Systemic PGE₁ administration in rats resulted in a higher number of osteoclasts and more bone resorption.^{49,50} Prostaglandin E₂ in rats also showed an increase in OTM.⁵¹ Macrophage colony stimulating factor, a signaling molecule in osteoclast maturation, was shown in mice to increase the recruitment of pre-osteoclasts and the rate of differentiation into mature osteoclasts. One local injection followed by force application for 6 days accelerated OTM by 14%.⁵² This method of accelerating OTM is still in the experimental stages.

Considerations in Aligner Therapy

Aligner therapy is increasing in popularity among patients and practitioners. Several systems now exist including Invisalign®, ClearCorrect®, and Simply 5®. Clear aligners provide patients

the benefits of improved gingival health and oral hygiene,⁵³ but many challenges exist when using aligners for orthodontic tooth movement. Moving teeth with plastic aligners often results in the need for re-assessments in the middle of treatment. The Invisalign® system has titled these re-assessments Mid-Course Corrections or Refinements. OTM using Invisalign® is planned using the ClinCheck™ software. This software and the technology for Invisalign® is constantly changing and evolving. The initial ClinCheck™ is designed by a technician, using the preferences and treatment plan provided by the practitioner. At present, this software allows practitioners to move individual teeth in almost any direction and apply attachments, precision cuts, or interproximal reduction where desired (Figure 3). It is important that general practitioners using this software and system understand the basics of orthodontics in order to provide patients the most optimal treatment. This includes an understanding of diagnosis, ideal occlusion, and the limits of tooth movement and aligner therapy.

Initial studies of Invisalign® reported OTM accuracy to be 41% of the ClinCheck™ predictions. The most predictable movements included lingual constriction, while least predictable movements were tooth extrusion and canine rotation.⁵⁴ Changing aligners every 2 weeks versus every week doubled the likelihood that patients could

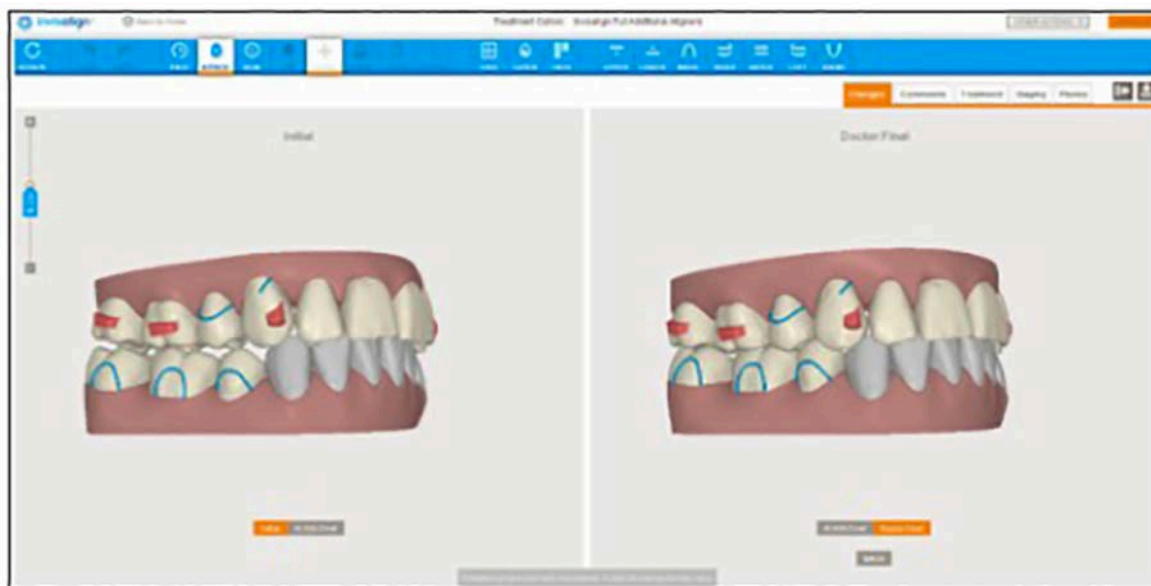


Figure 3. The current ClinCheck™ Pro software allows practitioners to compare initial and predicted final occlusion. The software also offers clinicians almost full control of individual teeth, standard attachments, and elastic cut outs using the 3D Controls toolbar.

complete their treatment without correction⁵⁵ and with improved outcomes.⁵³ A series of studies conducted at University of Florida College of Dentistry Department of Orthodontics found 42 to 62% of prescribed OTM achieved.⁵⁶⁻⁵⁸ These studies found that the majority of OTM occurs in the first week of wear when changing aligners every other week,⁵⁸ that material fatigue was not a factor in OTM using Invisalign® aligners,⁵⁶ and that gender and age might play a role in amount of OTM.⁵⁹ From these studies it can be concluded that factors affecting the amount of OTM achieved using Invisalign® clear aligner orthodontic therapy may include sex, age, the amount of prescribed movement (0.25 to 0.5mm per aligner), frequency of changing the aligner, and the plastic material used to fabricate the trays.

General dentists using Invisalign® and other clear aligner systems should be sure to stay current with evolving technology and evidence based literature regarding the treatment they are providing patients. It is important to critically assess treatment that is initially generated by technicians as they are often based on generic algorithms. Every patient is unique, and their treatment needs and possibilities should also be considered as such. In addition, the limitations of aligner therapy should be understood and considered.

Skeletal Anchorage

Temporary Anchorage Devices, MiniScrews

When moving teeth orthodontically, it is important to identify which specific teeth need to be moved in order to reach the treatment goal. For example, premolar extraction spaces can be closed by moving the posterior teeth forward or the anterior teeth distal. The same can be said about correcting a deep bite, which can be corrected with posterior extrusion or anterior intrusion. Similar considerations can be made for open bites as well. This concept is termed the anchorage requirement. Certain movements require anchorage that cannot be achieved without pre-planning and the use of auxiliaries. Additional anchorage can come in the form of headgear, elastics, use of adjacent teeth, and appliances, many of which rely on patient compliance. The use of implants in orthodontics has evolved through publications

by Gainesforth and Higley in 1945;⁶⁰ Kanomi who introduced the use of mini-implants in 1997;⁶¹ and Costa et al, who described a 2mm titanium implant that could be used for both direct and indirect anchorage in 1998.⁶² Experimental data on Temporary Anchorage Devices (TADs), also known as mini-implants or miniscrews, began being published in 2000. The initial implants used in orthodontics were conventional implants placed in edentulous, palatal, or retromolar spaces.⁶³ Skeletal anchorage has made possible the ability to correct malocclusions without having to rely on patient compliance and with minimal effect of Newton's third law of physics regarding opposite and equal forces.⁶⁴ This type of anchorage is considered absolute anchorage, with no movement of the anchorage unit.⁶⁵ TADs are typically no more than 3mm in diameter and 11mm in length, and their placement is usually facilitated via the use of local or topical anesthetic.⁶⁴

One of the great advantages of using a TAD over a traditional implant is the ability to load it with force shortly after placement. While traditional implants require two months of healing time, TADs are usually loaded immediately or after a short 2-week healing time. This primary stability in the shorter waiting period is a product of the mechanical retention formed between the screw and the bone. Research has demonstrated this stability in forces up 250g.⁶⁶ It is important to maintain 1-2mm between the screw and any vital anatomic structure to prevent damage.⁶⁶ The close proximity of TADs to roots has also led to the concern of potential root damage should a TAD make contact with the root, although several studies have suggested that repair after contact of a TAD and root may be possible after TAD removal.^{64,67} Despite this, root damage may be associated with higher failure rates. The risk of damaging a root is enhanced by improper placement, migration after loading, axial deviation during insertion, anatomic root variation, and tooth contact with TAD in orthodontic treatment.⁶⁷ Proper precaution should be taken to avoid this if possible.

Compared to conventional implants, TADs are typically not expected to osseointegrate more than 25% to enhance the practitioner's ability to remove them. The stability of the screw is related

to its diameter as opposed to its length⁶³ and is based on mechanical gripping to the cortical bone.⁶⁸ Additionally, TADs may be self-drilling, requiring no pilot hole, or self-tapping which do require a pilot hole.⁶⁸ Overall, lower failures have been seen with the use of self-drilling screws and placement in keratinized mucosa.⁶³ A study conducted in 2009 surveyed orthodontic residents and found that 92.03% of them planned on using TADs in their office and 72.26% planned to place them themselves.⁶⁹

Since their development, a number of studies have been published discussing the ability of TADs to assist in difficult orthodontic movements such as uprighting, intruding, and distalizing molars; retracting the anterior segment (Figure 4); closing first molar sites; and correcting midlines without affecting the remaining occlusion or dentition.⁷⁰ A transpalatal arch (TPA) placed 3-4mm away from the palate can be used in conjunction with TADs for molar intrusion, using tongue pressure to aid in the intrusion.⁶⁸ Scheffler et al. successfully demonstrated intrusion of the maxillary molars of 2.3mm, with relapse of 0.5mm occurring mainly in the first year after treatment. When attempting this, it is important to apply a passive force, such as an essix or lower lingual holding arch, to the mandibular molars to prevent their eruption, and thus negating the intrusive effects.⁷¹

Another good use for TADs is retraction of the maxillary anterior dentition when first premolars are extracted in Class II molar patients (Figure 4). With a miniscrew located further apically in the edentulous space, a force can be placed to an attachment also reaching apically to move the teeth in a straight distal vector. A force to a short

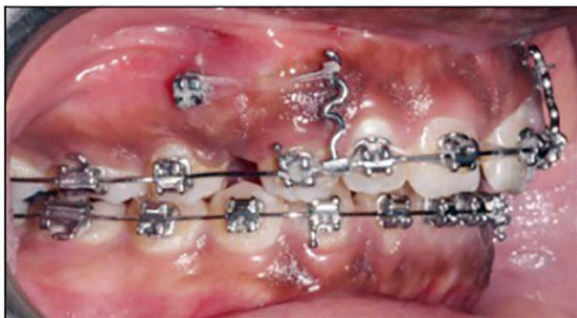

Figure 4. Use of a temporary anchorage device for maximum anchorage to retract the maxillary canine to canine region in to the space created by extracting first premolars.

attachment will provide an intrusive force as well if needed. Improper force vectors can cause unwanted movements, such as extrusion or rotation of the occlusal plane.⁷² TADs can also be used to distalize full maxillary arches, with or without appliances, such as the pendulum appliance. Distalization of the maxillary arch should also involve some intrusion to prevent changes to the vertical dimension of the face. One complication of this procedure is the formation of a pseudopocket distal to the second molar which could potentially require future periodontal surgery to correct.⁷³

The success rate of TADs in published literature has ranged from 61 to 100% depending on the source.⁶⁵ The most common complications are mucosal inflammation, soft tissue hypertrophy and infection. The main cause of failure is placement in non-keratinized tissue, leading to peri-implant inflammation and infection.⁶⁵ Providing proper oral hygiene and care information to patients at the initial placement appointment can reduce the amount of plaque and inflammation of the surrounding tissues.⁷⁴ Potential risk factors for TAD placement include osteoporosis, uncontrolled diabetes, periodontal disease, smoking and bisphosphonates. Factors that may potentially increase their clinical success include greater cortical thickness for improved primary stability, placement in keratinized tissue, and sufficient distance from nearby roots.⁷⁵

Miniplates

Miniplates are another form of skeletal anchorage used in orthodontics. Miniplates are often used when the necessary forces are presumed to be high due to their lower risk for failure when compared to mini-screws.⁷⁶ They are made of titanium or a titanium alloy and typically consist of a head, arm, and body. The body is placed typically by an oral surgeon below the periosteum and is attached to the bone with a series of small screws.⁷⁷ The plates are usually placed in the zygomatic buttress or piriform rim of the maxilla. In the mandible, they can typically be placed anywhere except for on the mental nerve.⁷⁸ The body is connected to an arm that extends into the mouth with a head that is designed to allow placement of force for orthodontic tooth movement.⁷⁷ Potential complications with miniplate use include facial

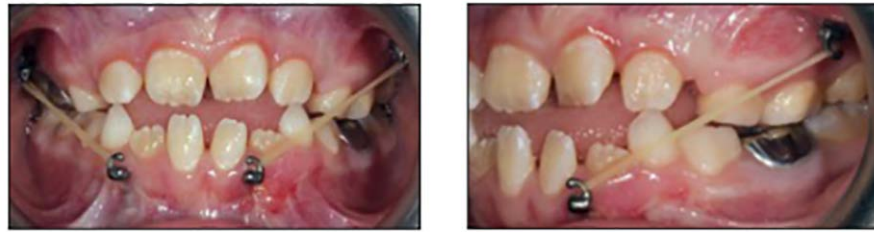


Figure 5. Class III elastic force from maxillary miniplate to mandibular miniplate in a 10 year old patient with a Class III tendency.

swelling directly after surgical placement, plate loosening, plate fracture, and mucosal dehiscence around the plate.⁷⁸

Several of the uses of miniplates are similar to those of TADs. The use of miniplates reduces the concern of proximity to adjacent teeth. One unique application of miniplates is their use in Class III patients for bone anchored maxillary protraction or BAMP (Figure 5). For this use, miniplates are placed bilaterally in the infrazygomatic crests of the maxilla and in the anterior mandible. Elastics are worn on each side from maxillary miniplate head to the mandibular miniplate head. Results of BAMP have shown anterior displacement of the zygoma and maxilla with minimal dental movement, posterior displacement and clockwise rotation of the mandible, and posterior displacement of the glenoid fossa.^{79,80}

Another unique use of miniplates consists of placement on the lateral nasal walls of the maxilla and use as anchorage for facemask elastics in maxillary deficient patients. Research has shown anterior movement of the infraorbital region and maxilla using this protocol in the late mixed dentition.⁸¹ Sar et al. found that the addition of miniplates in this procedure reduced the unwanted side effects of conventional facemask use, including less dental movements, less maxillary rotation, and more maxillary advancement.⁸² This can also be used in patients with cleft palate or cleft lip and palate to treat maxillary hypoplasia commonly seen in these patients.⁸³

Technology

The evolution of technology in dentistry has made a significant impact on orthodontic diagnosis, treatment planning, and treatment. Digital photos, radiographs, and record keeping

have all become commonplace in many orthodontic practices. The use of digital records improves communication between practitioners and makes it easier to store information. Most records taken for orthodontic diagnosis are 2 dimensional, providing limited information to the practitioner. The majority of 3 dimensional information is collected via clinical examination and models.

The use of digital models now provides practitioners the ability to evaluate the dentition in three dimensions, while improving storage capabilities (Figure 6). A number of methods exist for generating digital models including holographic scanning, stereophotogrammetry capture, phase-shifting optical triangulation and cone-beam computed tomography (CBCT). The models can be made by scanning the teeth intraorally, scanning polyvinyl siloxane or alginate impressions and bite registrations, or scanning the actual plaster or stone models. Companies providing such services include OrthoCAD™, RexcanDS™, and OrthoInsight™. OrthoCAD™ uses alginate impressions of both dentitions combined with a bite registration to generate the 3 dimensional digital study models. Digital models have improved diagnosis by making it possible to measure teeth digitally and generate tooth size analyses quicker and with more ease.⁸⁴ Using models generated via laser scanning for tooth size measurements has been found to be similar to measurements on plaster casts.⁸⁵ These models can also be used to fabricate appliances⁸⁴ and for indirect bracket set ups⁸⁶ when appropriate model quality is achieved.

The use of cone beam computed tomography (CBCT) has become increasingly more common in recent years in the orthodontic field. CBCT has been noted as being particularly useful in cases with impacted teeth, skeletal asymmetries,

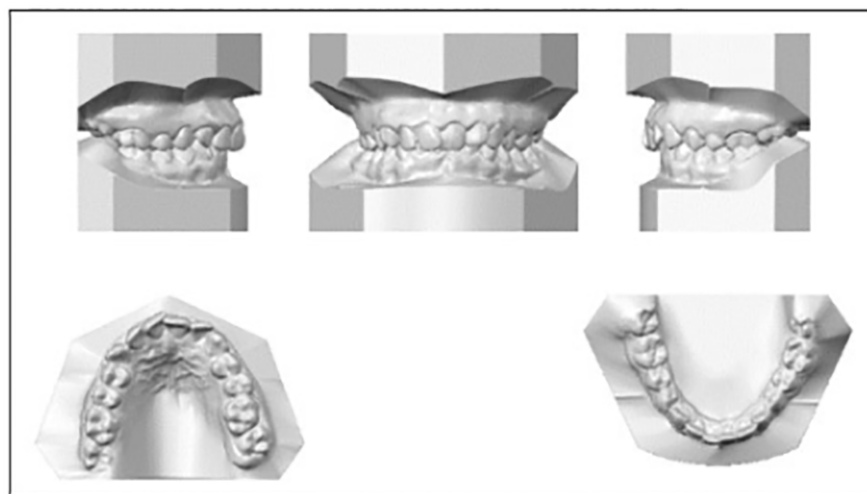


Figure 6. Example of models generated via alginate impressions mailed to OrthoCAD™.

suspected temporomandibular joint changes, suspected airway problems, and various pathologies.⁸⁷ When evaluating airway, CBCT allows a 3 dimensional rendering, allowing one to determine the antero-posterior and transverse dimensions and come up with a volumetric assessment (Figure 7). This is one area with surrounding controversy, as no method has been developed to standardize how this is measured.⁸⁸

CBCT can also be used to evaluate inclination of the teeth and their bony support in the transverse and antero-posterior dimensions by looking at slices of the image. A method has been developed to use CBCT to evaluate the fusion of the midpalatal suture.^{89,90} It has also been determined that while CBCT can be helpful in determining the presence of fenestrations and dehiscences on anterior teeth, it may result in overestimation (Figure 8).⁹¹ CBCT can also be used to develop digital models. The accuracy of models generated from CBCT in orthodontic treatment is unclear and requires further research.⁸⁵ Some literature has claimed that the accuracy of the tooth crown from models generated by CBCT is low in comparison to the accuracy of the roots from CBCT or of the tooth crowns in laser generated models.⁹²

Intraoral scanning is another major area of development in digital orthodontics (Figure 9). Some of the current scanners on the market include the iTero® Element™ by Align Technology,

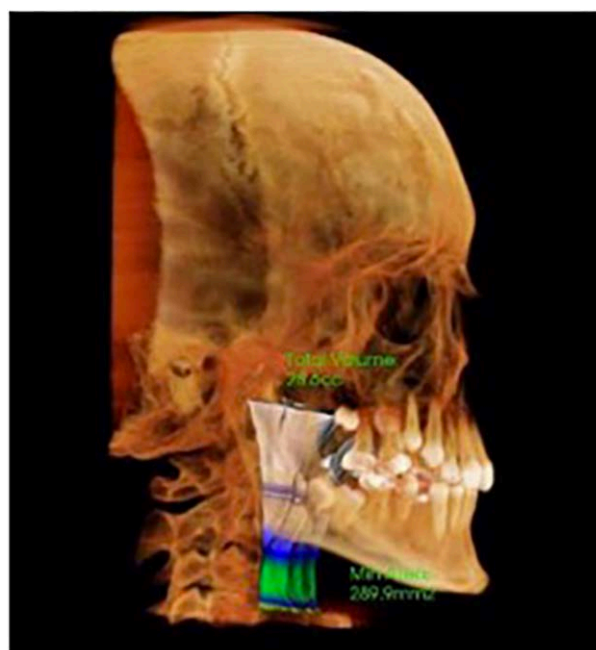


Figure 7. Example of an airway assessment using a CBCT in InVivo™ software.

Trios® by 3shape, and CS 3500 by CareStream. Models generated from intraoral scanners have been found to have similar accuracy to those made from alginate impressions.⁹³ Some of the benefits of using an intraoral scanner include less retakes of impressions, improved patient comfort, and quicker turnaround time for obtaining digital models. Another advantage is the ability to send the model digitally to an orthodontic lab for appliance fabrication, which greatly shortens the

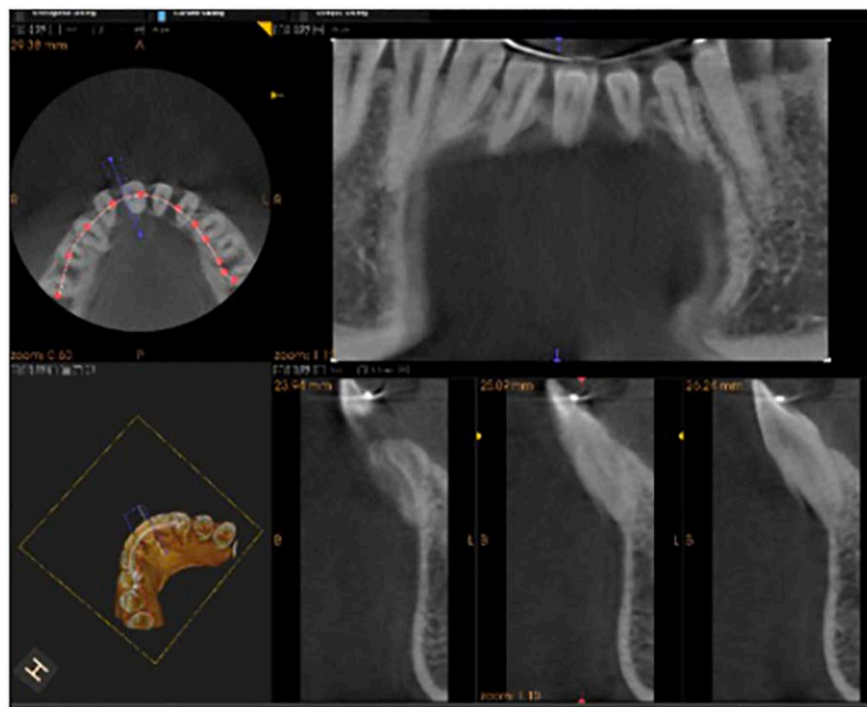


Figure 8. Evaluation of bone support of the lower incisors using a localized CBCT in KODAK™ software.

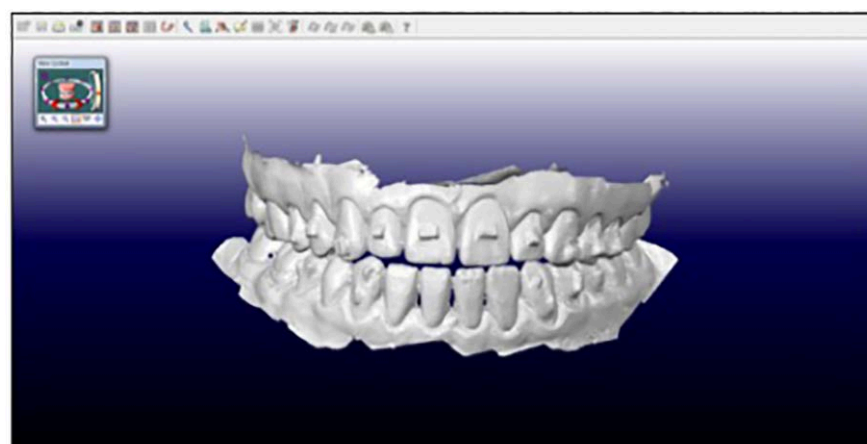


Figure 9. Initial appearance of an iTero® scan prior to processing for Invisalign™.

time needed between appointments. There are currently four different ways that scanners obtain information to generate the digital models. These are triangulation, parallel confocal, accordion fringe interferometry, and three-dimensional in-motion video. Some units also require an extra step of powdering the teeth.⁹⁴

Stereolithographic (STL) files holding the digital model information can be used to 3D print models. Current technology methods used to print include stereolithography, fused deposition

modeling, digital light processing, and polyjet photopolymerization. Currently the Objet30 OrthoDesk, Ultra® 3SP®, and the MakerBot Replicator 2 are 3D printers available for orthodontic office use.⁹⁵ While the cost of these machines and their materials are currently high, several orthodontic laboratories also have the ability to print models for a much smaller fee. 3D printing is projected to become more common and more affordable in the future, and will likely evolve in similar ways to the evolution we have seen thus far with CBCT and intraoral scanners.

Conclusion

The field of orthodontics continues to evolve with continued technological innovations and research. The most recent popular advances have been in these fields of acceleration of orthodontic tooth movement to shorten overall treatment times, orthodontic treatment with aligners, and the use of skeletal anchorage. While exciting, it is important to note that there is still a great amount of research left to be done in order to conclude which modalities can accelerate OTM

effectively. In addition, technology has changed the way orthodontic problems are diagnosed and treated. All of these advances have expanded the patient populations seeking treatment and have improved what clinicians can expect when treating patients. To ensure optimal treatment of patients, it is important for clinicians to continue learning and to keep up with advances as the field progresses as a whole to ensure that all orthodontic patients are treated to the optimal standard of care.

Course Test Preview

- Recent studies show ____ percent of orthodontic patients are adults.**
 - 7
 - 14
 - 28
 - 50
- Optimal forces are thought to enhance orthodontic tooth movement by ____.**
 - increasing the number of osteoclasts
 - minimizing necrosis in the PDL
 - increasing blood vessel occlusion
 - reducing the amount of root surface
- The majority of studies have shown a positive effect of Low Level Laser Therapy on the speed of orthodontic tooth movement.**
 - True
 - False
- The Regional Acceleratory Phenomenon refers to ____.**
 - a form of photobiomodulation
 - an increase in inflammatory markers resulting in increased bone turnover
 - a type of laser to accelerate orthodontic tooth movement
- The system used to create micro-osteoperforations in the cortical bone to accelerate orthodontic tooth movement is called ____.**
 - PROPEL®
 - AcceleDent®
 - OrthoPulse®
- One of the major concerns with the injection of substances to accelerate orthodontic tooth movement is ____.**
 - the tooth may move too fast
 - root resorption may occur
 - potential systemic side effect
- The initial Invisalign® ClinCheck™ is designed by a/an ____ using the preferences and treatment plan provided by the practitioner.**
 - orthodontist
 - technician
 - dentist
- Some of the basic orthodontic considerations that need to be accounted for in treating patients with Invisalign® include understanding of ____.**
 - diagnosis
 - ideal occlusion
 - limits of tooth movement
 - aligner therapy
 - All of the above.

9. The most predictable movements using Invisalign® includes _____ while the least predictable includes _____.
a. canine rotation / tooth extrusion
b. lingual constriction / canine rotation
c. tooth extrusion / canine rotation
d. canine rotation / lingual constriction
10. Factors involved in amount of orthodontic tooth movement using Invisalign® clear aligners do not include _____.
a. age
b. plastic used to fabricate the trays
c. amount of prescribed interproximal reduction
d. amount of prescribed tooth movement
11. The process in which specific teeth that need to be moved to reach the treatment goal are identified is termed the _____.
a. anchorage requirement
b. auxiliary planning
c. Newton's third law of physics
d. Higley's Law
12. The use of implants in orthodontics was first introduced in _____.
a. 1945
b. 1997
c. 1998
d. 2000
13. Temporary Anchorage Devices can be placed anywhere in the oral cavity without consideration to the teeth or other anatomical structures. One of the biggest advantages of using them versus a traditional implant is the ability to load them immediately.
a. Both statements are true.
b. The first statement is true, the second statement is false.
c. The first statement is false, the second statement is true.
d. Both statements are false.
14. TADs typically integrate ____%.
a. <25
b. 40
c. 70
d. 100
15. Helpful tooth movements where TADs can be used include _____.
a. distalization of the maxillary arch
b. uprighting molars
c. intruding molars
d. space closure where maximum anchorage is necessary
e. All of the above.

16. Mini-plates have one unique application in Class ____ patients. They are placed in the infrazygomatic crests of the maxilla and in the anterior mandible and elastics are worn bilaterally to help improve the skeletal relationship.
- a. I
 - b. II, Division 1
 - c. II, Division 2
 - d. III
17. The evolution of digital model use for treatment planning includes all of the following benefits except ____.
- a. improved storage ability
 - b. ability to measure teeth digitally
 - c. ability to evaluate skeletal relationships
 - d. improved communication between practitioners
18. CBCT is useful in cases with all of the following except ____.
- a. Class I malocclusion
 - b. skeletal asymmetries
 - c. airway problems
 - d. impacted teeth
19. Models obtained from intraoral scanners have been found to have similar accuracy to those made from alginate impressions. Using alginate impressions usually results in shortened time needed between appointments compared to digital impressions.
- a. Both statements are true.
 - b. The first statement is true, the second statement is false.
 - c. The first statement is false, the second statement is true.
 - d. Both statements are false.
20. Popular advances in the orthodontic field include ____.
- a. increased interest in acceleration of orthodontic tooth movement
 - b. orthodontic treatment with aligners
 - c. skeletal anchorage
 - d. use of technology in the form of CBCT, intraoral scanners, and 3D printing
 - e. All of the above.

References

1. Economics of Orthodontics Survey Indicates Practice Management Data Mostly Stable with Growth in Adult Patient Population. 2015.
2. AAO survey shows increase in adult patients. *Am J Orthod*. 1970 Nov;58(5):506-8. doi: 10.1016/0002-9416(70)90027-8.
3. Wise GE, King GJ. Mechanisms of tooth eruption and orthodontic tooth movement. *J Dent Res*. 2008 May;87(5):414-34. doi: 10.1177/154405910808700509.
4. Storey E. The nature of tooth movement. *Am J Orthod*. 1973 Mar;63(3):292-314.
5. Reitan K. Clinical and histologic observations on tooth movement during and after orthodontic treatment. *Am J Orthod*. 1967 Oct;53(10):721-45.
6. Masella RS, Meister M. Current concepts in the biology of orthodontic tooth movement. *Am J Orthod Dentofacial Orthop*. 2006 Apr;129(4):458-68. doi: 10.1016/j.ajodo.2005.12.013.
7. Lombardo L, Marafioti M, Stefanoni F, et al. Load deflection characteristics and force level of nickel titanium initial archwires. *Angle Orthod*. 2012 May;82(3):507-21. doi: 10.2319/032511-213.1. Epub 2011 Sep 13.
8. Kawasaki K, Shimizu N. Effects of low-energy laser irradiation on bone remodeling during experimental tooth movement in rats. *Lasers Surg Med*. 2000;26(3):282-91.
9. Cruz DR, Kohara EK, Ribeiro MS, et al. Effects of low-intensity laser therapy on the orthodontic movement velocity of human teeth: a preliminary study. *Lasers Surg Med*. 2004;35(2):117-20. doi: 10.1002/lsm.20076.
10. Genc G, Kocadereli I, Tasar F, et al. Effect of low-level laser therapy (LLLT) on orthodontic tooth movement. *Lasers Med Sci*. 2013 Jan;28(1):41-7. doi: 10.1007/s10103-012-1059-6. Epub 2012 Feb 18.
11. Doshi-Mehta G, Bhad-Patil WA. Efficacy of low-intensity laser therapy in reducing treatment time and orthodontic pain: a clinical investigation. *Am J Orthod Dentofacial Orthop*. 2012 Mar;141(3):289-97. doi: 10.1016/j.ajodo.2011.09.009.
12. Altan BA, Sokucu O, Ozkut MM, et al. Metrical and histological investigation of the effects of low-level laser therapy on orthodontic tooth movement. *Lasers Med Sci*. 2012 Jan;27(1):131-40. doi: 10.1007/s10103-010-0853-2. Epub 2010 Oct 31.
13. Sousa MV, Scanavini MA, Sannomiya EK, et al. Influence of low-level laser on the speed of orthodontic movement. *Photomed Laser Surg*. 2011 Mar;29(3):191-6. doi: 10.1089/pho.2009.2652. Epub 2011 Jan 23.
14. Shirazi M, Ahmad Akhoundi MS, Javadi E, et al. The effects of diode laser (660 nm) on the rate of tooth movements: an animal study. *Lasers Med Sci*. 2015 Feb;30(2):713-8. doi: 10.1007/s10103-013-1407-1. Epub 2013 Aug 7.
15. Marquezan M, Bolognese AM, Araújo MT. Effects of two low-intensity laser therapy protocols on experimental tooth movement. *Photomed Laser Surg*. 2010 Dec;28(6):757-62. doi: 10.1089/pho.2009.2694.
16. Salehi P, Heidari S, Tanideh N, et al. Effect of low-level laser irradiation on the rate and short-term stability of rotational tooth movement in dogs. *Am J Orthod Dentofacial Orthop*. 2015 May;147(5):578-86. doi: 10.1016/j.ajodo.2014.12.024.
17. Kansal A, Kittur N, Kumbhojkar V, et al. Effects of low-intensity laser therapy on the rate of orthodontic tooth movement: A clinical trial. *Dent Res J (Isfahan)*. 2014 Jul;11(4):481-8.
18. Ekizer A, Uysal T, Güray E, et al. Effect of LED-mediated-photobiomodulation therapy on orthodontic tooth movement and root resorption in rats. *Lasers Med Sci*. 2015 Feb;30(2):779-85. doi: 10.1007/s10103-013-1405-3. Epub 2013 Aug 29.
19. Ekizer A, Türker G, Uysal T, et al. Light emitting diode mediated photobiomodulation therapy improves orthodontic tooth movement and miniscrew stability: A randomized controlled clinical trial. *Lasers Surg Med*. 2016 Dec;48(10):936-943. doi: 10.1002/lsm.22516. Epub 2016 Apr 4.
20. Wilcko W, Wilcko MT. Accelerating tooth movement: the case for corticotomy-induced orthodontics. *Am J Orthod Dentofacial Orthop*. 2013 Jul;144(1):4-12. doi: 10.1016/j.ajodo.2013.04.009.

21. Cho KW, Cho SW, Oh CO, et al. The effect of cortical activation on orthodontic tooth movement. *Oral Dis.* 2007 May;13(3):314-9. doi: 10.1111/j.1601-0825.2006.01286.x.
22. Iino S, Sakoda S, Ito G, et al. Acceleration of orthodontic tooth movement by alveolar corticotomy in the dog. *Am J Orthod Dentofacial Orthop.* 2007 Apr;131(4):448.e1-8. doi: 10.1016/j.ajodo.2006.08.014.
23. Fischer TJ. Orthodontic treatment acceleration with corticotomy-assisted exposure of palatally impacted canines. *Angle Orthod.* 2007 May;77(3):417-20. doi: 10.2319/0003-3219(2007)077[0417:OTAWCE]2.0.CO;2.
24. Long H, Pyakurel U, Wang Y, et al. Interventions for accelerating orthodontic tooth movement: a systematic review. *Angle Orthod.* 2013 Jan;83(1):164-71. doi: 10.2319/031512-224.1. Epub 2012 Jun 21.
25. Fleming PS, Fedorowicz Z, Johal A, et al. Surgical adjunctive procedures for accelerating orthodontic treatment. *Cochrane Database Syst Rev.* 2015 Jun 30;(6):CD010572. doi: 10.1002/14651858.CD010572.pub2.
26. Kim SJ, Park YG, Kang SG. Effects of Corticision on paradental remodeling in orthodontic tooth movement. *Angle Orthod.* 2009 Mar;79(2):284-91. doi: 10.2319/020308-60.1.
27. Kim YS, Kim SJ, Yoon HJ, et al. Effect of piezopuncture on tooth movement and bone remodeling in dogs. *Am J Orthod Dentofacial Orthop.* 2013 Jul;144(1):23-31. doi: 10.1016/j.ajodo.2013.01.022.
28. Young L, Binderman I, Yaffe A, et al. Fiberotomy enhances orthodontic tooth movement and diminishes relapse in a rat model. *Orthod Craniofac Res.* 2013 Aug;16(3):161-8. doi: 10.1111/ocr.12014. Epub 2013 Jan 11.
29. Mathews DP, Kokich VG. Accelerating tooth movement: the case against corticotomy-induced orthodontics. *Am J Orthod Dentofacial Orthop.* 2013 Jul;144(1):5-13. doi: 10.1016/j.ajodo.2013.04.008.
30. Alikhani M, Raptis M, Zoldan B, et al. Effect of micro-osteoperforations on the rate of tooth movement. *Am J Orthod Dentofacial Orthop.* 2013 Nov;144(5):639-48. doi: 10.1016/j.ajodo.2013.06.017.
31. Kau CH. A radiographic analysis of tooth morphology following the use of a novel cyclical force device in orthodontics. *Head Face Med.* 2011 Aug 9;7:14. doi: 10.1186/1746-160X-7-14.
32. Kau C, Nguyen J, English J. The clinical evaluation of a novel cyclical force generating device in orthodontics. *Orthod Pract.* 2012;1:10-15.
33. Kasturi G, Adler RA. Mechanical means to improve bone strength: ultrasound and vibration. *Curr Rheumatol Rep.* 2011 Jun;13(3):251-6. doi: 10.1007/s11926-011-0177-7. doi: 10.1007/s11926-011-0177-7.
34. Rubin C, Turner AS, Bain S, et al. Anabolism. Low mechanical signals strengthen long bones. *Nature.* 2001 Aug 9;412(6847):603-4. doi: 10.1038/35088122.
35. Rubin C, Turner AS, Müller R, et al. Quantity and quality of trabecular bone in the femur are enhanced by a strongly anabolic, noninvasive mechanical intervention. *J Bone Miner Res.* 2002 Feb;17(2):349-57. doi: 10.1359/jbmr.2002.17.2.349.
36. Gilsanz V, Wren TA, Sanchez M, et al. Low-level, high-frequency mechanical signals enhance musculoskeletal development of young women with low BMD. *J Bone Miner Res.* 2006 Sep;21(9):1464-74. doi: 10.1359/jbmr.060612.
37. Omar H, Shen G, Jones AS, et al. Effect of low magnitude and high frequency mechanical stimuli on defects healing in cranial bones. *J Oral Maxillofac Surg.* 2008 Jun;66(6):1104-11. doi: 10.1016/j.joms.2008.01.048.
38. Leung KS, Shi HF, Cheung WH, et al. Low-magnitude high-frequency vibration accelerates callus formation, mineralization, and fracture healing in rats. *J Orthop Res.* 2009 Apr;27(4):458-65. doi: 10.1002/jor.20753.
39. Peptan AI, Lopez A, Kopher RA, et al. Responses of intramembranous bone and sutures upon in vivo cyclic tensile and compressive loading. *Bone.* 2008 Feb;42(2):432-8. Epub 2007 Jun 7. doi: 10.1016/j.bone.2007.05.014.

40. Shi HF, Cheung WH, Qin L, et al. Low-magnitude high-frequency vibration treatment augments fracture healing in ovariectomy-induced osteoporotic bone. *Bone*. 2010 May;46(5):1299-305. doi: 10.1016/j.bone.2009.11.028. Epub 2009 Dec 2.
41. Kono T, Ayukawa Y, Moriyama Y, et al. The effect of low-magnitude, high-frequency vibration stimuli on the bone healing of rat incisor extraction socket. *J Biomech Eng*. 2012 Sep;134(9):091001. doi: 10.1115/1.4007247.
42. Nishimura M, Chiba M, Ohashi T, et al. Periodontal tissue activation by vibration: intermittent stimulation by resonance vibration accelerates experimental tooth movement in rats. *Am J Orthod Dentofacial Orthop*. 2008 Apr;133(4):572-83. doi: 10.1016/j.ajodo.2006.01.046.
43. Pavlin D, Anthony R, Raj V, et al. Cyclic loading (vibration) accelerates tooth movement in orthodontic patients: A double-blind, randomized controlled trial. *Seminars in Orthodontics*. 2015;21(3):187-194. doi: 10.1053/j.sodo.2015.06.005. Accessed April 24, 2017.
44. Bowman SJ. The effect of vibration on the rate of leveling and alignment. *J Clin Orthod*. 2014 Nov;48(11):678-88.
45. Woodhouse NR, DiBiase AT, Johnson N, et al. Supplemental vibrational force during orthodontic alignment: a randomized trial. *J Dent Res*. 2015 May;94(5):682-9. doi: 10.1177/0022034515576195. Epub 2015 Mar 10.
46. Soma S, Matsumoto S, Higuchi Y, et al. Local and chronic application of PTH accelerates tooth movement in rats. *J Dent Res*. 2000 Sep;79(9):1717-24. doi: 10.1177/00220345000790091301.
47. Soma S, Iwamoto M, Higuchi Y, et al. Effects of continuous infusion of PTH on experimental tooth movement in rats. *J Bone Miner Res*. 1999 Apr;14(4):546-54. doi: 10.1359/jbmr.1999.14.4.546.
48. Yamasaki K, Shibata Y, Imai S, et al. Clinical application of prostaglandin E1 (PGE1) upon orthodontic tooth movement. *Am J Orthod*. 1984 Jun;85(6):508-18.
49. Kawasaki K, Takahashi T, Yamaguchi M, et al. Effects of aging on RANKL and OPG levels in gingival crevicular fluid during orthodontic tooth movement. *Orthod Craniofac Res*. 2006 Aug;9(3):137-42. doi: 10.1111/j.1601-6343.2006.00368.x.
50. Lee WC. Experimental study of the effect of prostaglandin administration on tooth movement-with particular emphasis on the relationship to the method of PGE1 administration. *Am J Orthod Dentofacial Orthop*. 1990 Sep;98(3):231-41.
51. Seifi M, Eslami B, Saffar AS. The effect of prostaglandin E2 and calcium gluconate on orthodontic tooth movement and root resorption in rats. *Eur J Orthod*. 2003 Apr;25(2):199-204.
52. Brooks PJ, Heckler AF, Wei K, et al. M-CSF accelerates orthodontic tooth movement by targeting preosteoclasts in mice. *Angle Orthod*. 2011 Mar;81(2):277-83. doi: 10.2319/051210-258.1.
53. Clements KM, Bollen AM, Huang G, et al. Activation time and material stiffness of sequential removable orthodontic appliances. Part 2: Dental improvements. *Am J Orthod Dentofacial Orthop*. 2003 Nov;124(5):502-8.
54. Kravitz ND, Kusnoto B, BeGole E, et al. How well does Invisalign work? A prospective clinical study evaluating the efficacy of tooth movement with Invisalign. *Am J Orthod Dentofacial Orthop*. 2009 Jan;135(1):27-35. doi: 10.1016/j.ajodo.2007.05.018.
55. Bollen AM, Huang G, King G, et al. Activation time and material stiffness of sequential removable orthodontic appliances. Part 1: Ability to complete treatment. *Am J Orthod Dentofacial Orthop*. 2003 Nov;124(5):496-501. doi: 10.1016/S0889540603005766.
56. Drake CT, McGorray SP, Dolce C, et al. Orthodontic tooth movement with clear aligners. *ISRN Dent*. 2012;2012:657973. doi: 10.5402/2012/657973. Epub 2012 Aug 14.
57. Chisari JR, McGorray SP, Nair M, et al. Variables affecting orthodontic tooth movement with clear aligners. *Am J Orthod Dentofacial Orthop*. 2014 Apr;145(4 Suppl):S82-91. doi: 10.1016/j.ajodo.2013.10.022.
58. McGorray SP, Dolce C, Kramer S, et al. A randomized, placebo-controlled clinical trial on the effects of recombinant human relaxin on tooth movement and short-term stability. *Am J Orthod Dentofacial Orthop*. 2012 Feb;141(2):196-203. doi: 10.1016/j.ajodo.2011.07.024.

59. Chisari JR, McGorray SP, Nair M, et al. Variables affecting orthodontic tooth movement with clear aligners. *Am J Orthod Dentofacial Orthop.* 2014 Apr;145(4 Suppl):S82-91. doi: 10.1016/j.ajodo.2013.10.022.
60. Gainsforth BL, Higley LB. A study of orthodontic anchorage possibilities in basal bone. *Am J Orthod Oral Surg.* 1945 Aug;31(8):406-17. Accessed April 24, 2017.
61. Kanomi R. Mini-implant for orthodontic anchorage. *J Clin Orthod.* 1997 Nov;31(11):763-7.
62. Costa A, Raffaini M, Melsen B. Miniscrews as orthodontic anchorage: a preliminary report. *Int J Adult Orthodon Orthognath Surg.* 1998;13(3):201-9.
63. Cornelis MA, Scheffler NR, De Clerck HJ, et al. Systematic review of the experimental use of temporary skeletal anchorage devices in orthodontics. *Am J Orthod Dentofacial Orthop.* 2007 Apr;131(4 Suppl):S52-8. doi: 10.1016/j.ajodo.2006.05.033.
64. Rossouw PE, Buschang PH. Temporary orthodontic anchorage devices for improving occlusion. *Orthod Craniofac Res.* 2009 Aug;12(3):195-205. doi: 10.1111/j.1601-6343.2009.01453.x.
65. Tsui WK, Chua HD, Cheung LK. Bone anchor systems for orthodontic application: a systematic review. *Int J Oral Maxillofac Surg.* 2012 Nov;41(11):1427-38. doi: 10.1016/j.ijom.2012.05.011. Epub 2012 Jun 15.
66. Ohashi E, Pecho OE, Moron M, et al. Implant vs screw loading protocols in orthodontics. *Angle Orthod.* 2006 Jul;76(4):721-7. doi: 10.1043/0003-3219(2006)076[0721:IVSLPI]2.0.CO;2.
67. Ahmed V KS, Rooban T, Krishnaswamy NR, et al. Root damage and repair in patients with temporary skeletal anchorage devices. *Am J Orthod Dentofacial Orthop.* 2012 May;141(5):547-55. doi: 10.1016/j.ajodo.2011.11.014.
68. Kravitz ND, Kusnoto B, Tsay TP, et al. The use of temporary anchorage devices for molar intrusion. *J Am Dent Assoc.* 2007 Jan;138(1):56-64.
69. Noble J, Hechter FJ, Karaikos NE, et al. Future practice plans of orthodontic residents in the United States. *Am J Orthod Dentofacial Orthop.* 2009 Mar;135(3):357-60. doi: 10.1016/j.ajodo.2008.09.024.
70. Wahl N. Orthodontics in 3 millennia. Chapter 15: Skeletal anchorage. *Am J Orthod Dentofacial Orthop.* 2008 Nov;134(5):707-10. doi: 10.1016/j.ajodo.2008.04.015.
71. Scheffler NR, Proffit WR, Phillips C. Outcomes and stability in patients with anterior open bite and long anterior face height treated with temporary anchorage devices and a maxillary intrusion splint. *Am J Orthod Dentofacial Orthop.* 2014 Nov;146(5):594-602. doi: 10.1016/j.ajodo.2014.07.020. Epub 2014 Oct 28.
72. Kojima Y, Kawamura J, Fukui H. Finite element analysis of the effect of force directions on tooth movement in extraction space closure with miniscrew sliding mechanics. *Am J Orthod Dentofacial Orthop.* 2012 Oct;142(4):501-8. doi: 10.1016/j.ajodo.2012.05.014.
73. Choi YJ, Lee JS, Cha JY, et al. Total distalization of the maxillary arch in a patient with skeletal Class II malocclusion. *Am J Orthod Dentofacial Orthop.* 2011 Jun;139(6):823-33. doi: 10.1016/j.ajodo.2009.07.026.
74. Al Maaitah EF, Safi AA, Abdelhafez RS. Alveolar bone density changes around miniscrews: a prospective clinical study. *Am J Orthod Dentofacial Orthop.* 2012 Dec;142(6):758-67. doi: 10.1016/j.ajodo.2012.07.013.
75. Reynders R, Ronchi L, Bipat S. Mini-implants in orthodontics: a systematic review of the literature. *Am J Orthod Dentofacial Orthop.* 2009 May;135(5):564.e1-19; discussion 564-5. doi: 10.1016/j.ajodo.2008.09.026.
76. Chen YJ, Chang HH, Huang CY, et al. A retrospective analysis of the failure rate of three different orthodontic skeletal anchorage systems. *Clin Oral Implants Res.* 2007 Dec;18(6):768-75. Epub 2007 Sep 14.
77. Sugawara J. Temporary skeletal anchorage devices: the case for miniplates. *Am J Orthod Dentofacial Orthop.* 2014 May;145(5):559-65. doi: 10.1016/j.ajodo.2014.03.010.
78. Nanda R, Uribe FA. Temporary anchorage devices in orthodontics. St. Louis, MO. Mosby. 2009.

79. De Clerck H, Nguyen T, de Paula LK, et al. Three-dimensional assessment of mandibular and glenoid fossa changes after bone-anchored Class III intermaxillary traction. *Am J Orthod Dentofacial Orthop.* 2012 Jul;142(1):25-31. doi: 10.1016/j.ajodo.2012.01.017.
80. Nguyen T, Cevitanes L, Cornelis MA, et al. Three-dimensional assessment of maxillary changes associated with bone anchored maxillary protraction. *Am J Orthod Dentofacial Orthop.* 2011 Dec;140(6):790-8. doi: 10.1016/j.ajodo.2011.04.025.
81. Kircelli BH, Pektas ZO. Midfacial protraction with skeletally anchored face mask therapy: a novel approach and preliminary results. *Am J Orthod Dentofacial Orthop.* 2008 Mar;133(3):440-9. doi: 10.1016/j.ajodo.2007.06.011.
82. Sar C, Arman-Özçırpıcı A, Uçkan S, et al. Comparative evaluation of maxillary protraction with or without skeletal anchorage. *Am J Orthod Dentofacial Orthop.* 2011 May;139(5):636-49. doi: 10.1016/j.ajodo.2009.06.039.
83. Baek SH, Kim KW, Choi JY. New treatment modality for maxillary hypoplasia in cleft patients. Protraction facemask with miniplate anchorage. *Angle Orthod.* 2010 Jul;80(4):783-91. doi: 10.2319/073009-435.1.
84. Hajeer MY, Millett DT, Ayoub AF, et al. Applications of 3D imaging in orthodontics: part II. *J Orthod.* 2004 Jun;31(2):154-62. doi: 10.1179/146531204225020472.
85. Luu NS, Nikolcheva LG, Retrouvey JM, et al. Linear measurements using virtual study models. *Angle Orthod.* 2012 Nov;82(6):1098-106. doi: 10.2319/110311-681.1. Epub 2012 Apr 24.
86. Israel M, Kusnoto B, Evans CA, et al. A comparison of traditional and computer-aided bracket placement methods. *Angle Orthod.* 2011 Sep;81(5):828-35. doi: 10.2319/072110-425.1. Epub 2011 Apr 28.
87. Mah JK, Huang JC, Choo H. Practical applications of cone-beam computed tomography in orthodontics. *J Am Dent Assoc.* 2010 Oct;141 Suppl 3:7S-13S.
88. Kapila SD, Nervina JM. CBCT in orthodontics: assessment of treatment outcomes and indications for its use. *Dentomaxillofac Radiol.* 2015;44(1):20140282. doi: 10.1259/dmfr.20140282.
89. Angelieri F, Franchi L, Cevitanes LH, et al. Diagnostic performance of skeletal maturity for the assessment of midpalatal suture maturation. *Am J Orthod Dentofacial Orthop.* 2015 Dec;148(6):1010-6. doi: 10.1016/j.ajodo.2015.06.016.
90. Angelieri F, Cevitanes LH, Franchi L, et al. Midpalatal suture maturation: classification method for individual assessment before rapid maxillary expansion. *Am J Orthod Dentofacial Orthop.* 2013 Nov;144(5):759-69. doi: 10.1016/j.ajodo.2013.04.022.
91. Sun L, Zhang L, Shen G, et al. Accuracy of cone-beam computed tomography in detecting alveolar bone dehiscences and fenestrations. *Am J Orthod Dentofacial Orthop.* 2015 Mar;147(3):313-23. doi: 10.1016/j.ajodo.2014.10.032.
92. Kihara T, Tanimoto K, Michida M, et al. Construction of orthodontic setup models on a computer. *Am J Orthod Dentofacial Orthop.* 2012 Jun;141(6):806-13. doi: 10.1016/j.ajodo.2011.10.027.
93. Grünheid T, McCarthy SD, Larson BE. Clinical use of a direct chairside oral scanner: an assessment of accuracy, time, and patient acceptance. *Am J Orthod Dentofacial Orthop.* 2014 Nov;146(5):673-82. doi: 10.1016/j.ajodo.2014.07.023. Epub 2014 Oct 28.
94. Kravitz ND, Groth C, Jones PE, et al. Intraoral digital scanners. *J Clin Orthod.* 2014 Jun;48(6):337-47.
95. Groth C, Kravitz ND, Jones PE, et al. Three-dimensional printing technology. *J Clin Orthod.* 2014 Aug;48(8):475-85.

Additional Resources

- No Additional Resources Available

About the Authors

Melissa Alfonso, DMD, MS



Melissa Alfonso Sedeño is a practicing orthodontist in Miami, Florida. Dr. Alfonso completed her orthodontic training at the University of Florida, receiving an orthodontic certificate and a Master's in Dental Sciences degree. Her thesis focused on the use of vibration to accelerate orthodontic tooth movement. During her residency, she served as Chief Resident and received the 2016 Charley Schultz Resident Scholar Award from the American Association of Orthodontists. She also presented her research at the 2015 OrthoVoice meeting. Dr. Alfonso also attended the University of Florida for her Bachelor's of Arts in Political Science and Doctor of Dental Medicine degrees.

Email: malfonso@dental.ufl.edu

Calogero Dolce, DDS, PhD



Dr. Calogero Dolce is a Professor, Chair and graduate program Director in the Department of Orthodontics at the University of Florida. Dr. Dolce completed his DDS and PhD at State University New York-Buffalo and a certificate in orthodontics at the University of Florida. He is a Diplomat of the American Board of Orthodontics. His research interests are in the biology of tooth movement, the treatment of Class II malocclusion and the repair of cleft lip and palate. He has been involved in three clinical trials funded by NIH/NICDR. Dr. Dolce has published more than 50 articles related to orthodontics and serves as a reviewer for various journals including the Journal of Dental Research, the American Journal of Orthodontics and Dentofacial Orthopedics and Angle Orthodontics. He has lectured at national and international meetings. Dr. Dolce is involved in teaching orthodontic residents and is part of intramural faculty practice.

Email: cdolce@dental.ufl.edu