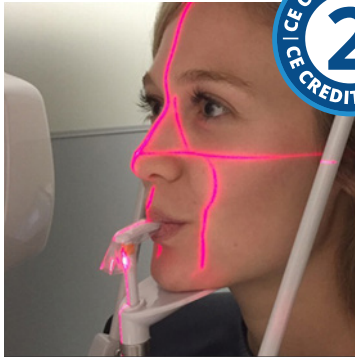

## Panoramic Radiographs: Technique & Anatomy Review



**Course Author(s):** Shelly Withers, RDH, MS, PhD; Marilyn Heyde, RDH, MPH  
**CE Credits:** 2 Hour(s)  
**Intended Audience:** Dentists, Dental Hygienists, Dental Assistants, Dental Students, Dental Hygiene Students, Dental Assistant Students  
**Date Course Online:** 04/02/2018  
**Last Revision Date:** 10/20/2024  
**Course Expiration Date:** 10/19/2027  
**Cost:** Free  
**Method:** Self-instructional  
**AGD Subject Code(s):** 10, 731

**Online Course:** [www.dentalcare.com/en-us/ce-courses/ce533](http://www.dentalcare.com/en-us/ce-courses/ce533)

### Disclaimers:

- P&G is providing these resource materials to dental professionals. We do not own this content nor are we responsible for any material herein.
- Participants must always be aware of the hazards of using limited knowledge in integrating new techniques or procedures into their practice. Only sound evidence-based dentistry should be used in patient therapy.

### Conflict of Interest Disclosure Statement

- Shelly Withers reports no conflicts of interest associated with this course. She has no relevant financial relationships to disclose.
- Marilyn Heyde reports no conflicts of interest associated with this course. She has no relevant financial relationships to disclose.

### Introduction

The purpose of the Panoramic Radiographs: Technique & Anatomy Review course is to provide students and clinicians with a review of panoramic imaging techniques in order to take diagnostic images. The course will review normal radiographic anatomy and structures, as well as various technique errors and how to correct them.

## Course Contents

- Overview
- Learning Objectives
- Glossary
- Introduction
- Review of Normal Anatomical Landmarks and Variations
- Technique
  - Equipment Preparation
  - Patient Preparation
  - Patient Positioning
- Causes and Appearance of Errors in Technique
- Use of Panoramic Imaging for Patient Education
- Issues Related to Standard of Care: ALARA & ALADA
- Conclusion
- Course Test
- References
- About the Authors

## Overview

The purpose of the course is to provide students and clinicians with a review of panoramic imaging techniques in order to take diagnostic images. Topics include equipment preparation, patient preparation, and patient positioning. Taking a diagnostic image the first time prevents additional patient exposure to radiation by following the principles of ALARA (As Low as Reasonably Achievable). The course will review normal and abnormal radiographic anatomy and structures, as well as various technique errors and how to correct them.

## Learning Objectives

**Upon completion of this course, the dental professional should be able to:**

- Review normal anatomy observed in panoramic images.
- Determine the cause and appearance of various technique errors.
- Discuss the importance of using radiographs for patient education.
- Understand the benefit of using panoramic radiographs to fulfill the principles of ALARA (As Low As Reasonably Achievable).

## Glossary

**Radiolucent** – Refers to structures that are less dense and permit the x-ray beam to pass through them. Radiolucent structures appear dark or black in the radiographic image.

**Radiopaque** – Refers to structures that are dense and resist the passage of x-rays. Radiopaque structures appear light or white in a radiographic image.

### Bony Landmarks<sup>1</sup>

**Anterior nasal spine** – a radiopaque V-shaped structure in the maxilla that intersects the floor of the nasal cavity and the nasal septum.

**External auditory meatus** – a round radiolucent passage way to the ear (bilateral).

**Genial tubercle** – a round/oval radiopaque structure inferior to the mandibular incisors.

**Hard palate** – a horizontal radiopaque bony structure that separates the nasal cavity from the oral cavity.

**Internal oblique ridge** – a radiopaque structure which is located on the internal surface of the mandible and proceeds downward to become the mylohyoid ridge (bilateral).

**Maxillary sinus** – a radiolucent area located above the apices of the maxillary premolars and molars. The floor of the maxillary sinus often appears as a thin, wavy radiopaque line (bilateral).

**Mandibular canal** – a radiolucent tube-like structure outlined by two radiopaque lines that starts at the mandibular foramen and proceeds to the mental foramen (bilateral).

**Mandibular condyle** – a rounded radiopaque structure, which extends from the ramus and articulates with the glenoid fossa (bilateral).

**Mental foramen** – a round/oval radiolucent structure inferior to the mandibular premolars (bilateral).

**Nasal septum** – a radiopaque vertical bony structure that divides the nasal cavity into two sections.

**Orbit** – a radiolucent area superior to the maxillary sinus (bilateral).

**Styloid process** – a long, pointed radiopaque structure that extends from the temporal bone anterior to the mastoid process (bilateral).

**Submandibular fossa** – a radiolucent area toward the middle of the mandible that lies inferior to the mylohyoid line (bilateral).

**Zygomatic process** – a “J or U” shaped radiopaque structure in the maxilla that lies superior to the maxillary first molars (bilateral).

#### Airspaces<sup>1</sup>

**Nasopharyngeal air space** – a radiolucent area that extends from the nasal cavity to the pharynx.

**Glossopharyngeal air space** – a radiolucent area that extends posteriorly from the tongue and oral cavity to the pharynx.

**Palatoglossal air space** – a radiolucent band that lies superior to the apices of the maxillary teeth and inferior to the hard palate.

#### Introduction

A panoramic image displays the patient’s maxillary and mandibular oral and facial structures across a flat surface.<sup>1</sup> According to Iannucci & Howerton, “panoramic imaging is an extraoral technique that is used to examine the maxilla and mandible on a single projection.” Panoramic imaging was first introduced in the 1930s, but became more popular as a diagnostic tool in the 1960s.<sup>2,3</sup> During the 1980s, panoramic imaging transitioned to a digital format, which had the advantage of less radiation as well as immediate viewing of the image for patient education.<sup>3</sup> Panoramic imaging enables the dentist to diagnose the entire dentition and facial structures that are not visible in a full-mouth series.<sup>4</sup> The technique is considered part of the standard of care and is popular due to the relative ease of use, wide scope of examination, and low radiation dose.<sup>5</sup> The guidelines presented by the American Dental Association (ADA) indicate that a panoramic image and posterior bitewings are considered an acceptable full mouth series in certain cases.<sup>6</sup>

Dental professionals must understand the difference between normal anatomical

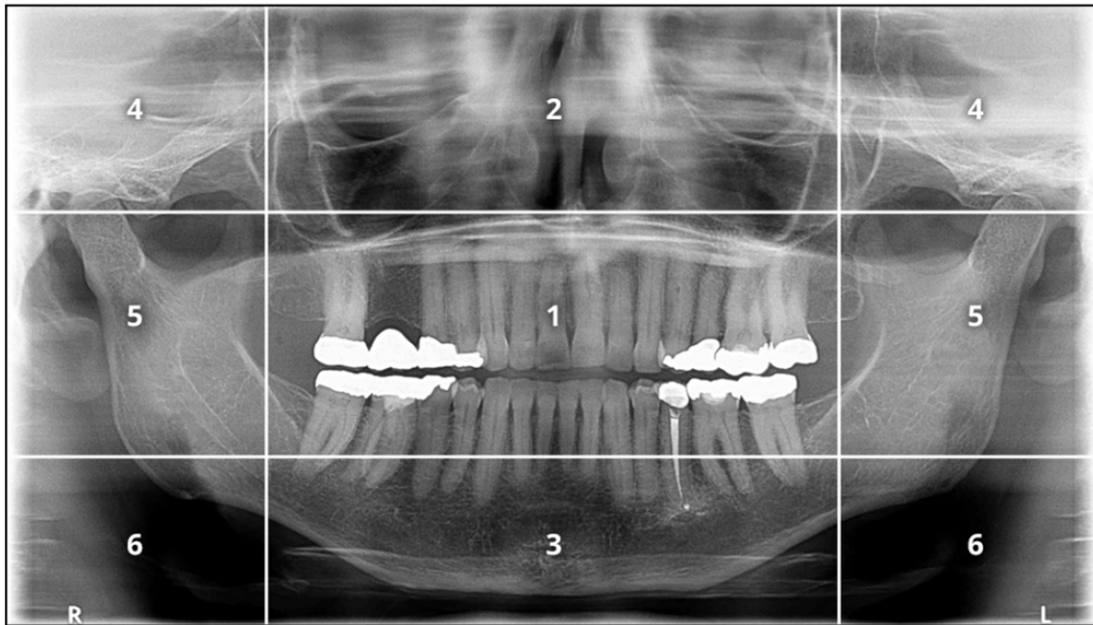
landmarks and abnormal findings, such as artifacts or pathology, which may be present on a panoramic image when viewing both the mandible and maxilla in the one projection. It is recommended to review the image systematically in order not to overlook anything that might be a deviation from normal.<sup>4</sup> The clinician may utilize the technique they are comfortable using; however, it must be consistent and ensure that all diagnostic information is read.<sup>2</sup> For instance, Perschbacher, recommends the following sequence: 1) review osseous structures and surrounding soft tissues, 2) review the alveolar process, and 3) review the teeth.<sup>4</sup>

It is important to evaluate the image bilaterally to look for symmetry, or asymmetry, which can indicate a pathological condition. For that reason, the methods suggested by Langland, Langlais, and Preece, which divides the image into 6 different zones (Figure 1), is a valuable tool for use during interpretation.<sup>3</sup>

#### Review of Normal Anatomical Landmarks and Variations

It is important to understand the landmarks normally seen on panoramic images in order to prevent misdiagnosis of a radiopaque or radiolucent area. For the purposes of this course, we will focus on the structures that are most commonly viewed in panoramic images. For additional information, a review of the anatomic structures can be found in the article by Farman<sup>2</sup> and the text by Iannucci & Howerton.<sup>1</sup>

Figure 2 includes many of the normal anatomical landmarks that will be visible on a diagnostic panoramic image. The maxillary sinuses are radiolucent and can be found bilaterally on either side of the nasal septum. The zygomatic process is a vertical, radiopaque line that forms the anterior portion of the zygomatic arch (cheekbone). In the mandibular region, the mandibular canal is bordered by two radiopaque lines and it houses the inferior alveolar nerve. The internal oblique ridge is a bony landmark that may be palpated during an inferior alveolar nerve block. At the midline of the mandible, there is a radiolucent lingual foramen that is bordered by genial tubercles, which are radiopaque. Finally, the submandibular fossa is a radiolucent depression that houses the sublingual gland.

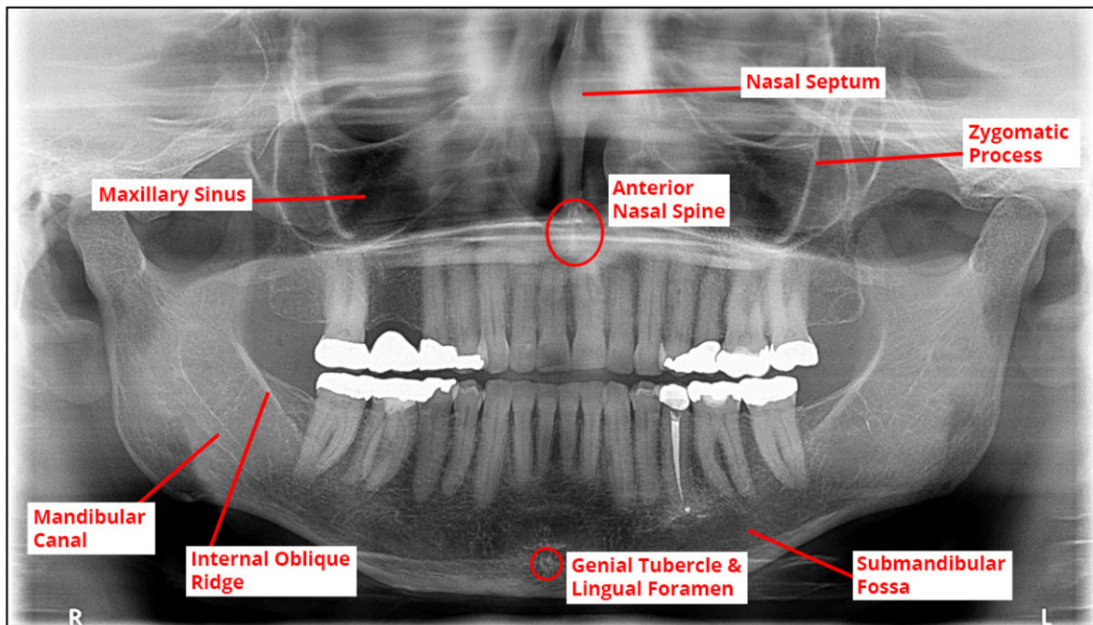


**Figure 1. Zones of Interpretation.**<sup>3</sup>

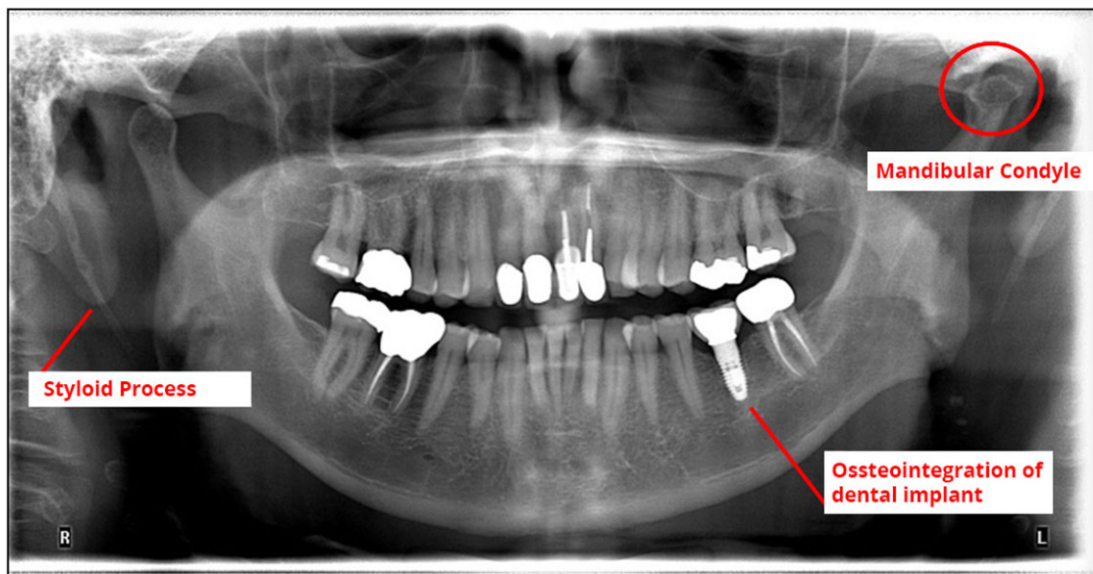
Image source: MH & Dr. Iwata.

**Table 1. Zones of Panoramic Image Interpretation.**<sup>3</sup>

Zone 1: Dentition	<ul style="list-style-type: none"> <li>✓ Teeth arranged with an upward smile-like curve</li> <li>✓ Anterior teeth should not be too large or small</li> <li>✓ Posterior teeth should be evenly sized without excessive overlap</li> <li>✓ Apices/crowns of teeth should be visible</li> </ul>
Zone 2: Nose & Sinus	<ul style="list-style-type: none"> <li>✓ Inferior turbinates and surrounding air spaces visible</li> <li>✓ Soft tissue of nose should not be visible</li> <li>✓ Shadow of hard palate will be seen in maxillary area</li> <li>✓ Tongue should be in contact with hard palate</li> </ul>
Zone 3: Mandibular Body	<ul style="list-style-type: none"> <li>✓ Inferior border of mandible should be continuous and smooth</li> <li>✓ Ghost image of hyoid should not be visible</li> <li>✓ Midline area should have proper proportions</li> </ul>
Zone 4: Condyles	<ul style="list-style-type: none"> <li>✓ Condyles should be centered within the area of the zone</li> <li>✓ Condyles should be of equal size and on same horizontal plane</li> </ul>
Zone 5: Ramus & Spine	<ul style="list-style-type: none"> <li>✓ Ramus of mandible should be similar width bilaterally</li> <li>✓ Spine, if seen, may be present as long as it doesn't superimpose over the ramus</li> <li>✓ If spine is present, the distance between the ramus and spine should be equivalent on both sides</li> </ul>
Zone 6: Hyoid Bone	<ul style="list-style-type: none"> <li>✓ Hyoid bone should appear as a bilateral, double image with equal proportions</li> <li>✓ Hyoid image may touch the mandible, but should not spread across it</li> </ul>



**Figure 2.** Normal Anatomical Landmarks.<sup>3</sup>  
 (Refer to the glossary for the definition of each structure shown).  
 Image source: Dr. Iwata.



**Figure 3.** Example of Pathology and Variations of Normal.  
 (Refer to the glossary for the definition of each structure shown).  
 Image source: AB & Dr. Iwata.

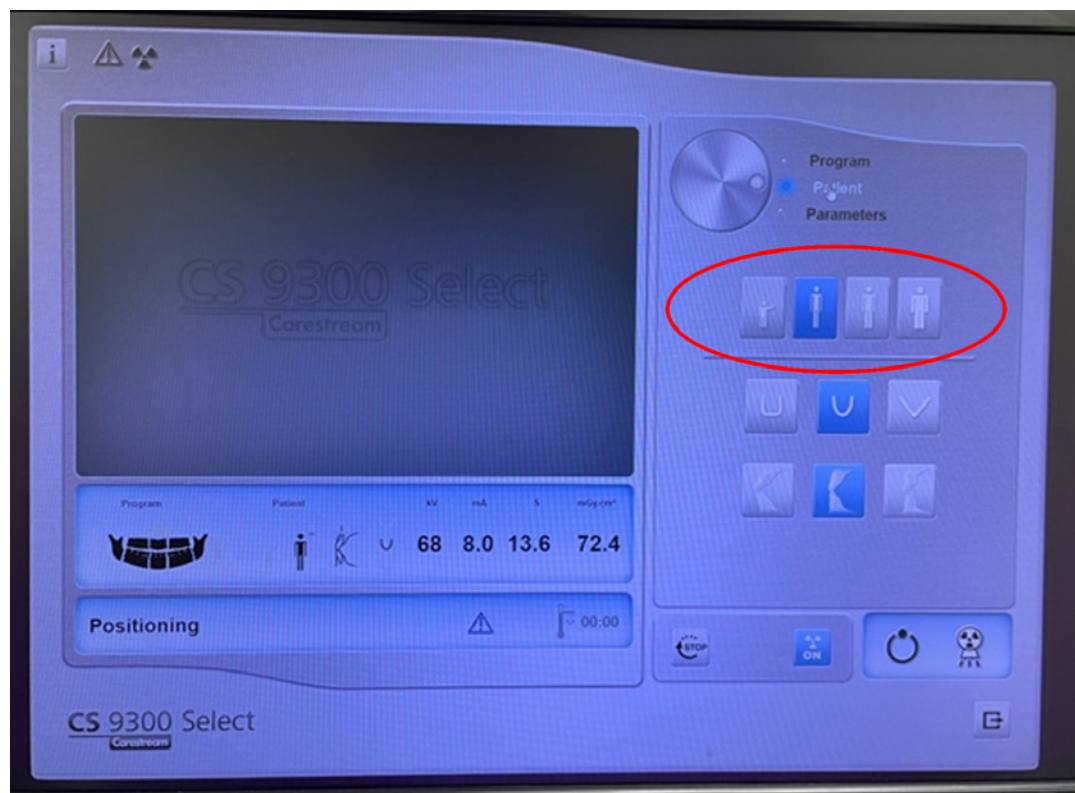In Figure 3, the patient's chief complaint was popping near the temporomandibular joint (TMJ). The panoramic image indicated a flattened condyle and significant wear of the glenoid fossa of the temporal bone due to constant force from bruxism and clenching. It was also noted that the patient had very pronounced styloid processes (bilaterally).

## Technique

### Equipment Preparation

As with any dental procedure, it is important to properly prepare the equipment beforehand. Equipment preparation includes items such as the receptor, bite block, exposure settings, and patient selection (Table 2). If the panoramic image is being taken with a direct digital system, which transfers the image directly to the computer, it is important that the proper patient is selected in the electronic health record prior to the exposure. Otherwise, the image will be stored in the wrong location.

Setting the proper exposure time prior to beginning the procedure will help improve efficiency and reduce the possibility of over-exposing the patient to unnecessary radiation. The results of one survey of general dentists found that clinicians did not always change the exposure time related to the patient's need. In fact 74% of respondents used the same exposure time for all patients.<sup>7</sup> In order to properly protect patients, the exposure setting must be tailored for each individual patient. Most machines have settings that can be adjusted according to the stature of the patient. For example, when imaging a pediatric patient, the child exposure setting should be selected. Exposure settings should be adjusted accordingly as height and mass increases. There are usually two or three settings available for adult patients and one for children (Figure 4), which makes it possible to tailor the amount of radiation being produced.



**Figure 4.** Sample screen for selecting exposure settings for a child, slender adult, average adult, and large adult (circled in red). It is currently set for a slender adult with a curved arch.

Image source: Dr. Specht


**Table 2. Equipment Preparation.<sup>1</sup>**

<b>Receptor</b>	Analog/PSP plate placed in cassette according to guidelines.
<b>Select patient</b>	Direct digital sensor - have the correct patient assigned in computer before setting up.
<b>Bite-block</b>	Cover with disposable plastic covering (Fig. 5) or use a sterilized bite block made of impervious material between patients.
<b>Exposure Settings</b>	Set according to the manufacturer's recommendations, which are pre-programmed according to the size of the patient. Most machines have a single setting for pediatric patients and two options for adult patients (according to their size (Fig. 4). Newer machines do not require that the clinician selects specific exposure times and doses for each patient.
<b>Height</b>	Adjust entire machine to the correct height for the patient and any other moveable parts as necessary (Fig. 6).



**Figure 5.** Bite block covered with disposable plastic covering.

Image source: Dr. Specht



**Figure 6.** Control panel for pano machine. Area for setting height of machine and activating lights for patient positioning is circled in red.

Image source: Dr. Specht

**Table 3. Patient Preparation Guidelines.**

<b>Jewelry</b>	All necklaces, piercings (earrings, tongue rings, etc.) and jewelry in the head and neck regions need to be removed (if possible) prior to exposure.
<b>Metal objects</b>	Items such as glasses, headbands, bobby pins, hair clips, hearing aids, etc. must be removed prior to exposure. Removable partial dentures and orthodontic appliances should be taken out prior to imaging.
<b>Lead Apron</b>	Apron must not have a thyroid collar and should be placed properly so it does not block the x-ray beam.

### Patient Preparation

Patient preparation is extremely important for ensuring that a high-quality image is produced and that errors are avoided (Table 3). For instance, incorrect patient preparation can lead to “ghost images” which can render the radiographic image undiagnostic. While ghost images often occur due to metallic objects, they can also occur due to anatomical structures located outside the image layer or focal trough. Ghost images always appear higher and distorted on the opposite side of the radiographic image (see Figure 7). Some errors are unavoidable due to the patient’s stature, facial asymmetry, or difficulty following instructions.<sup>8</sup>

An important item to include when preparing the patient is the use of a lead apron, which is recommended for all radiographic procedures, or when local legislation mandates.<sup>15</sup> Lead aprons help provide protection for radiosensitive tissues in the neck (thyroid gland), chest, reproductive areas, and blood forming tissue. In addition, lead aprons stop nearly 98% of scattered radiation from reaching reproductive organs. There are lead-free aprons that use an alloy material instead of lead. They are 50% lighter and safer for patients and clinicians because they are lead-free.<sup>9</sup>

While thyroid collars are not indicated for panoramic imaging, they are effective for use during intraoral imaging, because they have been shown to stop 92% of scatter radiation.<sup>9</sup> One study revealed that only 2% of the general dentists surveyed report using a lead apron with a thyroid shield prior to taking radiographs.<sup>7</sup>

In Figure 7, the patient’s earrings were not removed prior to imaging. Therefore, a ghost

image is present. In the example, the image of the actual left earring is on the right side and the ghost image of the left earring is on the left side of the image. Ghost images appear distorted, higher, and on the opposite side of the panoramic radiograph. The other error that can be observed, is that the chin is too low. This causes the exaggerated smile and the spine to be more pronounced on both sides of the image.

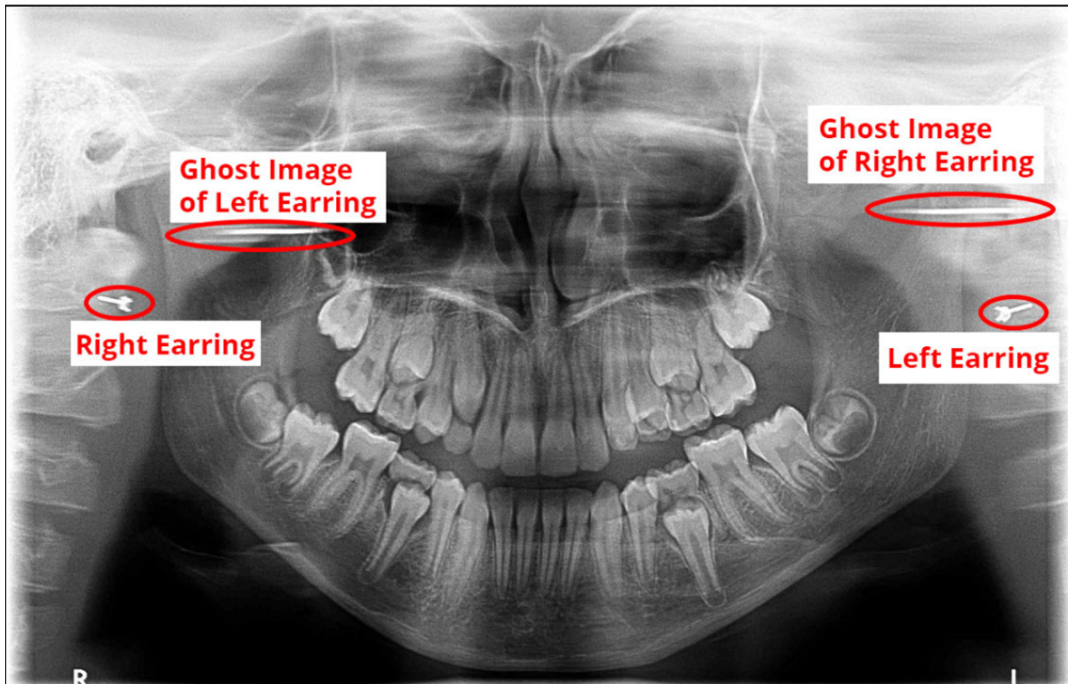
### Patient Positioning

In order to obtain diagnostically useful images, patients must be positioned carefully within the image layer or focal trough, which is a three-dimensional curved zone (Figure 5). Structures found within the image layer will be reasonably well-defined.<sup>5</sup> The patient must be positioned correctly so that the proper structures are aligned within the image layer.

If patient positioning is incorrect, errors are likely to occur. Patient positioning errors are the most common type of error when performing panoramic radiography.<sup>8</sup> For instance, in a study evaluating 460 panoramic radiographs, careless head positioning accounted for 38% of the errors.<sup>5</sup> Patient positioning errors accounted for 85% in a sample of 1,813 panoramic radiographs.<sup>5</sup>

The most common patient positioning error occurs when the tongue is not placed close enough to the palate.<sup>5,16</sup> This may be due to the patient misunderstanding the instructions and only placing the tip of their tongue on the palate. Incorrect positioning of the tongue creates radiolucency near the apices on the maxilla, which makes diagnosis of periodontitis and root resorption challenging.<sup>5</sup>

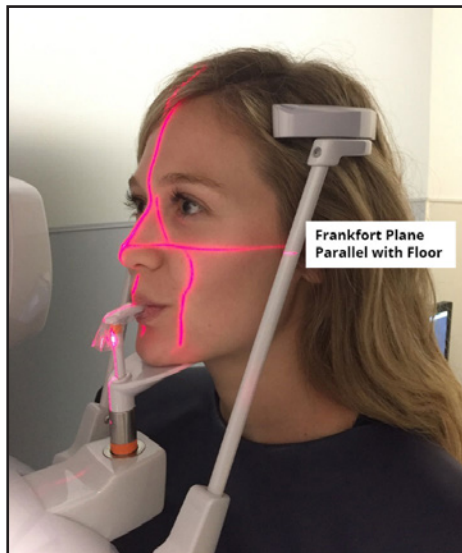




**Figure 7.** Appearance of Ghost Image.

The patient's earrings were not removed prior to imaging. Therefore, a ghost image is present. In the example, the image of the actual left earring is on the right side and the ghost image of the left earring is on the left side of the image. Ghost images appear distorted, higher, and on the opposite side of the panoramic radiograph. The other error that can be observed, is that the chin is too low. This causes the exaggerated smile and the spine to be more pronounced on both sides of the image.

Image source: BR L. Iwata, DDS.



**Figure 8.** Example of correct patient positioning with the tongue pressed against the palate, teeth in the groove of the bite-block, and the indicator light for the midsagittal plane centered and perpendicular to the floor. The Frankfort Plane, or ala-tragus line, is parallel with the floor.

It is helpful to note that each manufacturer provides specific operation instructions in the manual that accompanies the unit. It is worthwhile for each team member to become acquainted with the contents of the manual. While the instructions make panoramic imaging easy to perform well, it is equally as easy to perform badly when manufacturers' instructions are not followed.<sup>2</sup> Proper patient positioning (Table 4) will help reduce the possibility of errors in panoramic imaging.

**Causes and Appearance of Errors in Technique**

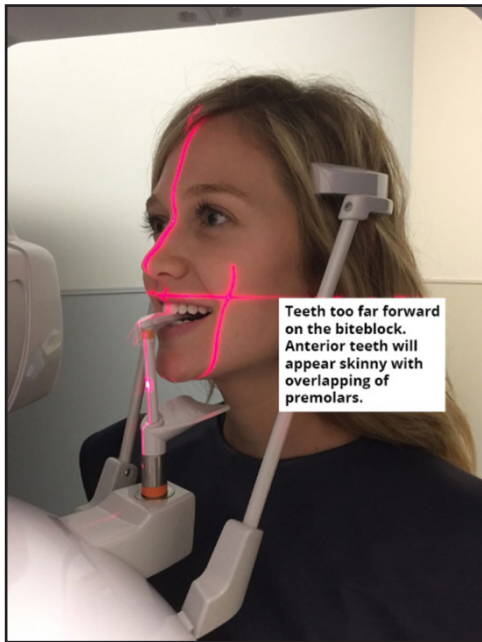
It is important for the clinician to be able to understand errors when they occur and how to correct them. Table 5 lists various errors that can occur with panoramic imaging. It also addresses the radiographic appearance of the errors and solutions for correcting the problem.

**Table 4. Patient Positioning Guidelines.**<sup>5,8,15</sup>

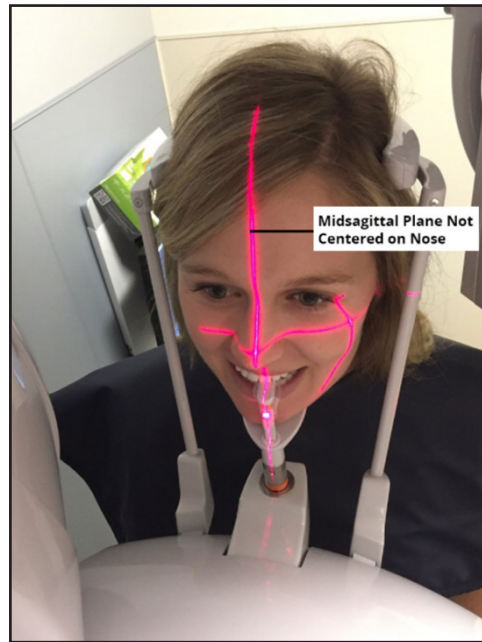
<b>Standing/Sitting</b>	<ul style="list-style-type: none"> <li>✓ If patient is able to stand, have them stand erect without the spine being slumped.               <ul style="list-style-type: none"> <li>• Taking a small step forward can help straighten the cervical spine.<sup>15</sup> Make sure patient is holding on to the handles for support and balance.</li> </ul> </li> <li>✓ If patient is seated, they should sit as upright as possible.</li> <li>✓ It helps to do a test run with the panoramic machine to make sure it will not hit the patient's shoulders.</li> </ul>
<b>Mouth position</b>	<ul style="list-style-type: none"> <li>✓ Patient needs to place maxillary/mandibular incisors correctly on bite block in order to achieve proper alignment of the teeth.</li> <li>✓ Most units have a notch in the bite block indicating the proper location for the patient to bite.</li> </ul>
<b>Midsagittal Plane</b>	<ul style="list-style-type: none"> <li>✓ The patient's head must be straight &amp; not tilted.</li> <li>✓ The midsagittal plane must be kept perpendicular to the floor.</li> <li>✓ It is ideal for the vertical light to be positioned between the maxillary central incisors. Due to asymmetry of facial soft tissues, the dental midline may not match the midline of the nose.<sup>15</sup></li> </ul>
<b>Frankfort Plane</b>	<ul style="list-style-type: none"> <li>✓ Keep the Frankfort plane parallel with the floor. The positioning light should extend from the ala of the nose to the tragus of the ear.</li> </ul>
<b>Tongue</b>	<ul style="list-style-type: none"> <li>✓ Instruct the patient to place their ENTIRE tongue on the hard palate and leave it there for the duration of the exposure.</li> </ul>
<b>Lips</b>	<ul style="list-style-type: none"> <li>✓ Instruct patient to keep their lips together for the duration of the exposure.</li> </ul>
<b>Eye</b>	<ul style="list-style-type: none"> <li>✓ Have patient close their eyes if they feel they might become dizzy due to the movement of the tube head.</li> </ul>

**Table 5. Patient Positioning Errors.<sup>1</sup>**

#	Error	Appearance on Image	Correction
1	Ghost images	Ghost image resembles real image Projected on opposite side of film and is higher	Have patient remove all radiodense objects before exposure
2	Lead apron artifact	Radiopaque, cone-shaped artifact in center of image	Use lead apron without thyroid collar
3	Patient lips not closed	Dark radiolucent shadow around anterior teeth	Remind patient to close lips around bite block
4	Patient chin too high	Condyles may not be visible Maxillary incisors appear blurred and magnified Reverse smile line (frown)	Keep Frankfort plane parallel with floor
5	Patient chin too low	Exaggerated smile line (Joker) Condyles higher on image Mandibular incisors appear blurred; roots appear short	Keep Frankfort plane parallel with floor
6	Patient too far forward (anterior to focal trough) (Figure 9)	Anterior teeth are narrowed Spine is visible on film	Make sure patient's teeth are in bite block notches
7	Patient too far back (posterior to focal trough)	Anterior teeth appear magnified Ramus isn't entirely visible	Make sure patient's teeth are in bite block notches
8	Patient head not centered (Figure 10)	Ramus and posterior teeth appear unequally magnified Side farthest from receptor appears magnified Side closest to receptor appears smaller Example: Patient turned to right will produce image with magnification on left side and overlapping of contacts	Keep midsagittal plane perpendicular to floor & ensure indicating light is located at center of patient's nose (between the maxillary central incisors)
9	Patient spine isn't straight	Cervical spine appears as radiopacity in center of image	Have patient stand as tall as possible. Seat patient if necessary



**Figure 9.** Incorrect positioning. The patient is positioned too far forward, because the canine indicator light is posterior to the canine.



**Figure 10.** Incorrect positioning. The patient's midsagittal plane is not centered along the midline of the face. The indicator light is over tooth #9, rather than between the maxillary central incisors.

As mentioned previously, the most common error is the failure to position the tongue directly against the hard palate.<sup>2,5,10</sup> In Figure 11, the maxillary roots of the anterior teeth are not visible, due to the fact that the tongue was not flat against the hard palate. The radiolucent area between the dorsum of the tongue and the hard palate is the palatoglossal air space, which is more pronounced.

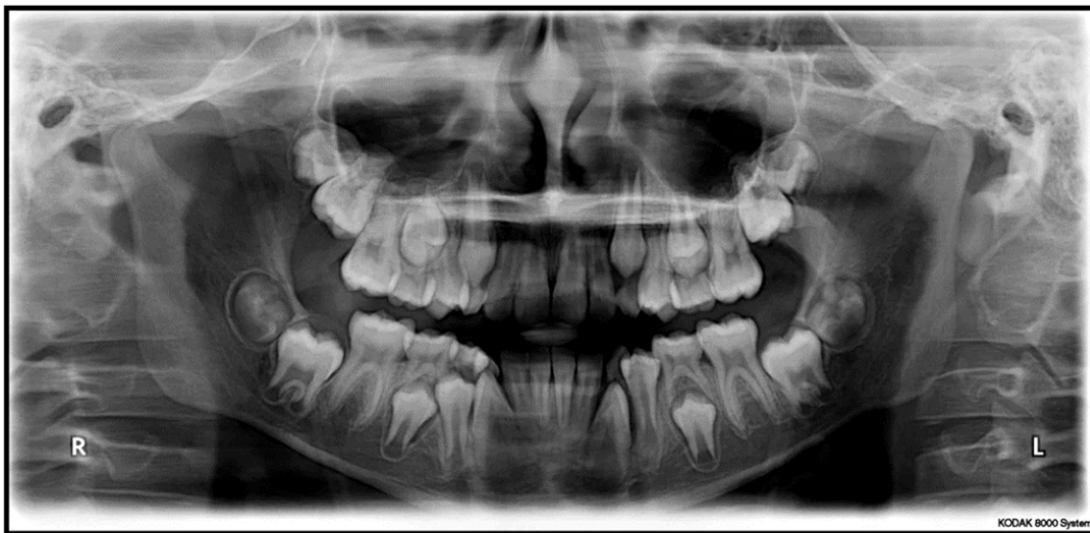Another error that is visible in Figure 11 is that the chin position is too low causing the spine to be more pronounced on the image. In addition, the mandibular incisors appear blurry with short roots.<sup>1,10</sup>

Most patients are able to tolerate the panoramic procedure with ease. However, certain patients will have challenges with the imaging process due to difficulty maintaining the proper position. For example, elderly patients may be unable to stand for the duration of the image, but some panoramic imaging units allow for the patient to sit.<sup>11</sup> If the patient is seated during the procedure, they

must be reminded to sit as upright as possible in order to prevent slumping, which can cause superimposition of the spine over the anterior teeth.<sup>5</sup>

### Use of Panoramic Imaging for Patient Education

With the abundance of information readily available on the internet, patients are becoming more informed about health care. The dental patient may ask why radiographic images are necessary instead of just agreeing to the treatment. Because of this, the dental professional must be able to accurately interpret the panoramic image and educate the patient. It is important to have the patient actively involved with their treatment. Incorporating this information into the patient's appointment will help improve their understanding of their oral condition and increase the perceived value of the appointment. Patients desire to be informed about their health and treatment options. Taking time to explain the images and educate the patient will help meet this expectation.



**Figure 11. Patient Positioning.**

Image source: Dr. Iwata,

According to Rondon, panoramic imaging is helpful for the following situations (Table 6):

**Table 6. Uses for Panoramic Images.**

- General surveys of oral health
- Best radiographic supplements for surgical procedures
- Evaluations for orthodontic treatment
- Pediatric growth and development
- Chronological dental eruption
- Evaluating cysts or neoplastic lesions
- Measurements for implantology
- Historical documentation
- Evaluation of TMJ

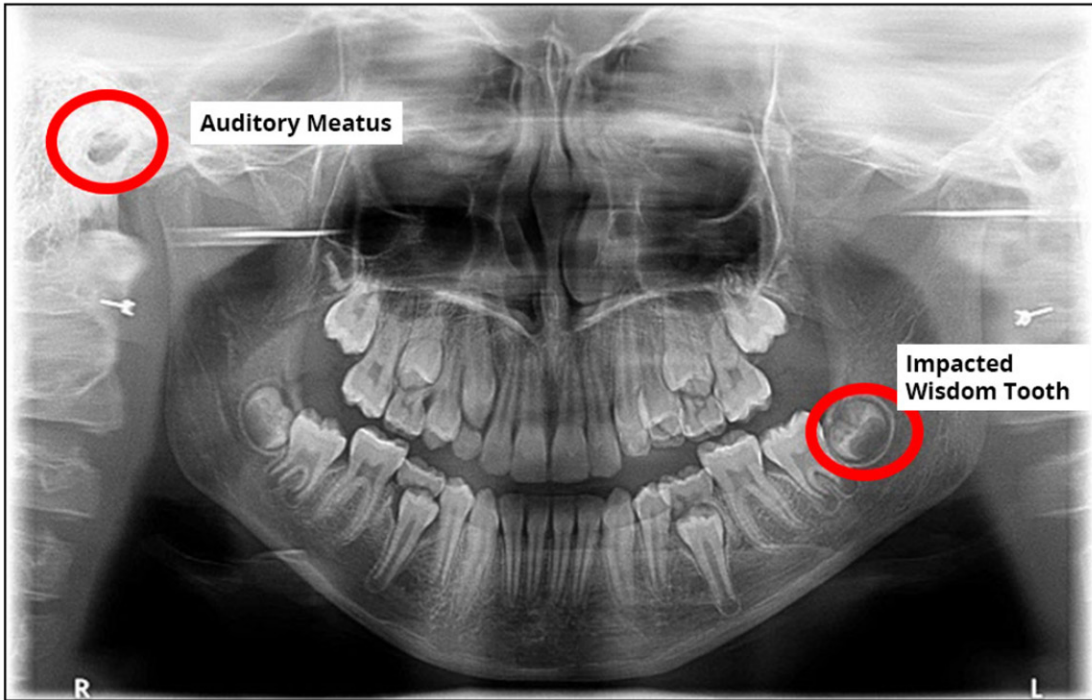
The following case of Patient A provides examples of using panoramic images to evaluate pediatric development and orthodontic treatment. Figure 12 is a pano of Patient A, who was 9 years old and had mixed dentition. The clinician explained the process of tooth development to the parent and the possibility of orthodontic treatment in the future, due to the rotation of teeth #22 & 27. Figure 13 is Patient A at 15 years old. The clinician explained that the wisdom teeth

may need to be extracted and was able to involve the parent and patient by explaining what was seen on the panoramic image. This pano provided a great visual to help them understand their current condition and how it compared to the imaging from 6 years earlier. In Figure 13, teeth #22 & 27 were still rotated, but not causing problems currently.

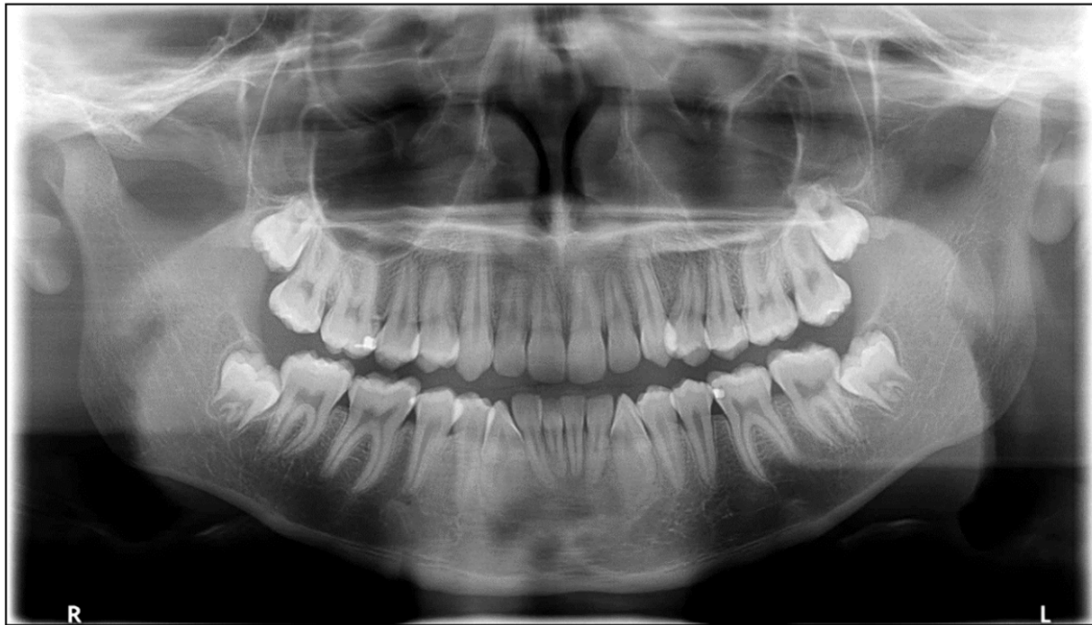In the next case, Patient B presented to the dental office with a complaint about their front tooth. After taking the panoramic image (Figure 14), it was noted that tooth #9 had resorption on the root. The dentist then requested a periapical radiograph to evaluate the condition more closely (Figure 15). Upon review of the periapical image, it was confirmed that internal resorption was occurring in tooth #9 and the dentist was able to treat the condition accordingly.

### **Issues Related to Standard of Care: ALARA & ALADA**

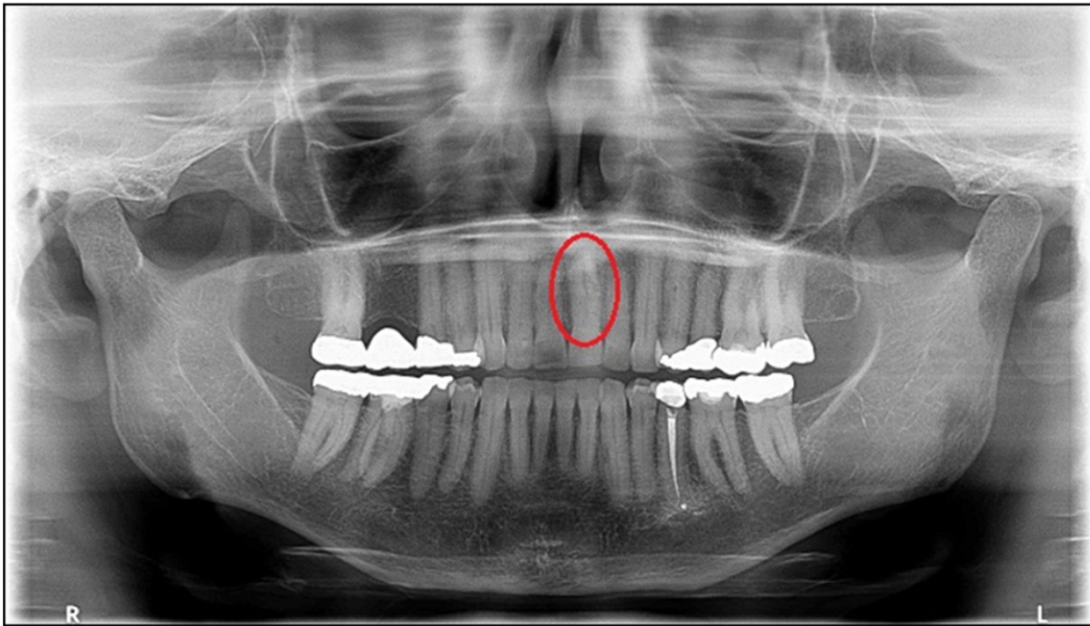
With the increased use of diagnostic radiation within healthcare, it is imperative that dental radiography is used with regard to the overall dose patients may be receiving. The concept of ALARA, (As Low As Reasonably Achievable), helps ensure that the radiation dose is kept as low as possible to achieve the desired outcome.<sup>7</sup> In fact, there is a call for imaging specialists to educate colleagues regarding the



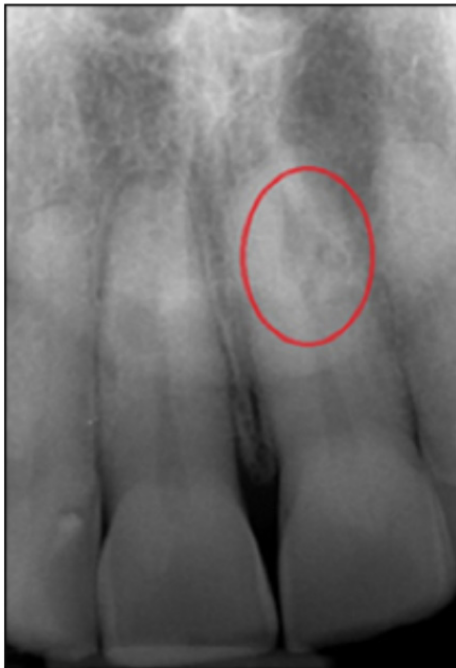**Figure 12.** Patient A: Part 1  
Panoramic image of Patient A (9 y/o) with rotated mandibular canines and mixed dentition.  
Image source: Dr. Iwata



**Figure 13.** Patient A: Part 2  
Panoramic image of Patient A (15 y/o).  
Image source: Dr. Iwata



**Figure 14.** Patient B: Part 1  
Panoramic image of Patient B taken after the patient reported discomfort in their front tooth.  
Image source: Dr. Iwata



**Figure 15.** Patient B: Part 2  
Periapical image of Patient B, which confirmed internal resorption was occurring on tooth #9.  
Image source: Dr. Iwata

**Table 7. Effective Radiation Doses for Dental Radiographic Examination.<sup>13</sup>**

Radiographic Exam	Average Effective Dose (Adults) in Millisieverts (mSv)
Digital panoramic radiography	0.01
Intraoral X-Ray	0.005
Full mouth series (18 images) with PSP or F-speed film and rectangular collimation	0.035
Bitewing (4 images) with PSP plates or F-speed film and rectangular collimator	0.005

**Table 8. Six-step plan to minimize radiation exposure to children.<sup>14</sup>**

1	Select x-rays for patient's individual needs, not as a routine
2	Use the fastest image receptor possible
3	For intraoral radiographs, collimate the x-ray beam to expose the area of interest only (rectangular collimation is best) <sup>8</sup>
4	Use thyroid collars (for intraoral images)
5	Reduce exposure time according to child's size
6	Use CBCT (Cone Beam Computed Tomography) only when necessary

difference between a “beautiful” image and a “diagnostically acceptable” image, which is the premise of the new concept ALADA, or “as low as diagnostically acceptable.”<sup>12</sup>

It is up to the dental radiographer to determine the type of examination and number of images to take according to the individual needs of each patient. [\*The American Dental Association \(ADA\) has created a guide for determining when to perform various dental radiographic examinations.\*](#)<sup>6</sup> Table 7 outlines the effective radiation doses for various dental radiographic examinations.<sup>13</sup> This provides perspective on the amount of radiation required for a full-mouth intraoral series compared to a panoramic image.

According to White et al., the public is more knowledgeable of the importance of radiation protection, especially at high doses, because of the correlation between radiation and other childhood cancers, like leukemia.<sup>14</sup> This is a concern because children are more susceptible to cancers from radiation exposure due to the high turnover rate of cells during replication.<sup>14</sup>

The Image Gently in Dentistry campaign has been designed to improve education and awareness of radiation safety in pediatric maxillofacial radiology. One of the educational tools used in the campaign is a “Six-Step Plan” to help minimize radiation to children (Table 8).<sup>14</sup>

### **Conclusion**

Dental radiographs, especially panoramic images, provide valuable information for both the clinician and the patient. The information contained within a panoramic image is helpful for screening, diagnosis, and patient education. As with any type of ionizing radiation, proper safety measures should be taken to ensure that both the patient and operator are protected. In addition, there is a need to be aware of the total dose of radiation patients are receiving through various medical and dental procedures. Through the concepts described in this course, dental radiographers can take steps to reduce patient radiation and to produce diagnostic panoramic images consistently.



## Course Test Preview

To receive Continuing Education credit for this course, you must complete the online test. Please go to: [www.dentalcare.com/en-us/ce-courses/ce533/start-test](http://www.dentalcare.com/en-us/ce-courses/ce533/start-test)

- 1. The maxillary sinus appears on the panoramic image as a radiopaque structure. The maxillary sinus is located above the maxillary premolars and molars.**
  - A. Both statements are TRUE.
  - B. Both statements are FALSE.
  - C. The first statement is TRUE, the second statement is FALSE.
  - D. The first statement is FALSE, the second statement is TRUE.
- 2. This anatomical landmark appears as a J or U-shaped radiopacity over the maxillary first molars.**
  - A. Genial Tubercle
  - B. Zygomatic Process
  - C. Anterior Nasal Spine
  - D. Hard Palate
- 3. All of the following are advantages of digital panoramic imaging, except one. Which one is the exception?**
  - A. A panoramic image is considered a complete radiographic series
  - B. The patient is subjected to less radiation
  - C. Immediate viewing of the image for patient education
  - D. Visualization of areas not normally seen in intraoral images
- 4. According to the ADA, which of the following meets the requirements for a "Complete Radiographic Series?"**
  - A. A Panoramic Image and Posterior Bitewings
  - B. 4 Bitewings and 3 Periapical Images
  - C. 2 Bitewings and 4 Periapical Images
  - D. A Panoramic image
- 5. When the clinician interprets a panoramic image, it is important that they can differentiate between normal and abnormal anatomical landmarks. A radiolucent structure will appear white on a panoramic image.**
  - A. Both statements are TRUE.
  - B. Both statements are FALSE.
  - C. The first statement is TRUE, the second statement is FALSE.
  - D. The first statement is FALSE, the second statement is TRUE.
- 6. It is important for the clinician to be systematic when viewing the panoramic image to prevent overlooking anything that might be a deviation from normal. The dentition will be visible in Zone 2 when utilizing this systematic approach.**
  - A. Both statements are TRUE.
  - B. Both statements are FALSE.
  - C. The first statement is TRUE, the second statement is FALSE.
  - D. The first statement is FALSE, the second statement is TRUE.
- 7. Which of the following statements regarding Zone 5 is correct?**
  - A. The distance between the ramus and spine should be greater on the left side.
  - B. Spine may be present and it is acceptable to be superimposed over the ramus.
  - C. The width of the ramus should be similar on both sides of the image.

8. **This round radiopaque landmark is observed inferior to the mandibular incisors.**
- A. Internal Oblique Ridge
  - B. Zygomatic Process
  - C. Genial Tubercle
  - D. Mandibular Canal
9. **To allow passage of the x-ray beam, the lead apron should not have a thyroid collar. In preparation to take the panoramic image, the clinician needs to have the patient remove jewelry, bobby pins, hearing aids, etc. from the head and neck.**
- A. Both statements are TRUE.
  - B. Both statements are FALSE.
  - C. The first statement is TRUE, the second statement is FALSE.
  - D. The first statement is FALSE, the second statement is TRUE.
10. **Lead aprons help provide protection for each of the following radiosensitive areas, except one. Which area is not protected by a lead apron?**
- A. Blood forming tissues
  - B. Neck and chest areas
  - C. Reproductive organs
  - D. Cerebral cortex
11. **A ghost image in a panoramic image appears \_\_\_\_\_.**
- A. on same side and lower on the image
  - B. on same side and higher on the image
  - C. on opposite side and lower on the image
  - D. on opposite side and higher on the image
12. **The anatomical landmarks of the \_\_\_\_\_ are the floor of the orbit and the external auditory meatus.**
- A. Midsagittal Plane
  - B. Frankfort Plane
  - C. Focal Trough
13. **What patient positioning error occurred if the anterior teeth are narrowed and the spine is visible on the film?**
- A. Patient position was anterior to the focal trough
  - B. Patient position was posterior to the focal trough
  - C. Patient's lips were not closed
  - D. Patient's head was not centered
14. **When positioning a patient, the \_\_\_\_\_ must be kept perpendicular to the floor.**
- A. Frankfort Plane
  - B. Midsagittal Plane
  - C. Focal Trough
  - D. Ala-tragus line
15. **What error can be observed on a panoramic image if the patient's tongue is not positioned directly against the hard palate during exposure?**
- A. Crowns of mandibular posterior teeth may not be visible
  - B. Crowns of maxillary posterior teeth may not be visible
  - C. Roots of maxillary anterior teeth may not be visible
  - D. Roots of mandibular anterior teeth may not be visible

- 16. A panoramic image can be an effective tool for patient education. Panoramic images are helpful to determine if the wisdom teeth are properly developing.**
- A. Both statements are TRUE.
  - B. Both statements are FALSE.
  - C. The first statement is TRUE, the second statement is FALSE.
  - D. The first statement is FALSE, the second statement is TRUE.
- 17. ALARA stands for \_\_\_\_\_.**
- A. Any Low Amount of Retakes are Acceptable
  - B. Association of Limited Applied Radiology
  - C. As Low As Reasonably Achievable
  - D. As Low as Diagnostically Acceptable
- 18. The Image Gently in Dentistry campaign developed the “Six-Step Plan” to help minimize exposure in which patient population?**
- A. Pediatric patients
  - B. Pregnant patients
  - C. Geriatric patients
  - D. Underserved patients

## References

1. Iannucci JM, Howerton LJ. Dental radiography: principles and techniques. 5th ed. St. Louis, MO. Elsevier/Saunders. 2017.
2. Farman AG. Getting the most out of panoramic radiographic interpretation. In Panoramic radiology seminars on maxillofacial imaging and interpretation. Springer, Berlin Heidelberg. 2007 (p. 1-5).
3. Langland OE, Langlais RP, Preece JW. Principles of dental imaging. 2nd ed. Baltimore, MD. Lippincott Williams & Wilkins. 2002.
4. Perschbacher S. Interpretation of panoramic radiographs. Aust Dent J. 2012 Mar;57 Suppl 1:40-5. doi: 10.1111/j.1834-7819.2011.01655.x.
5. Subbulakshmi AC, Mohan N, Thiruneervannan R, et. al. Positioning errors in digital panoramic radiographs: A study. Journal of Orofacial Sciences. 2016 8(1), 22-26. Accessed March 20, 2017.
6. American Dental Association. Council on Scientific Affairs. Dental Radiographic Examinations: Recommendations for Patient Selection and Limiting Radiation Exposure. Revised 2012. Accessed March 20, 2017.
7. Chaudhry M, Jayaprakash K, Shivalingesh KK, et al. Oral Radiology Safety Standards Adopted by the General Dentists Practicing in National Capital Region (NCR). J Clin Diagn Res. 2016 Jan;10(1):ZC42-5. doi: 10.7860/JCDR/2016/14591.7088. Epub 2016 Jan 1.
8. Rondon RH, Pereira YC, do Nascimento GC. Common positioning errors in panoramic radiography: A review. Imaging Sci Dent. 2014 Mar;44(1):1-6. doi: 10.5624/isd.2014.44.1.1. Epub 2014 Mar 19.
9. Howerton LJ. Advancements in radiology. Dimensions of Dental Hygiene, 2004 May;2(5):18, 20-21. Accessed March 20, 2017.
10. Dhillon M, Raju SM, Verma S, et al. Positioning errors and quality assessment in panoramic radiography. Imaging Sci Dent. 2012 Dec;42(4):207-12. doi: 10.5624/isd.2012.42.4.207. Epub 2012 Dec 23.
11. Levy H, Rotenberg LR. Tools and Equipment for Managing Special Care Patients Anywhere. Dent Clin North Am. 2016 Jul;60(3):567-91. doi: 10.1016/j.cden.2016.03.001.
12. Jaju PP, Jaju SP. Cone-beam computed tomography: Time to move from ALARA to ALADA. Imaging Sci Dent. 2015 Dec;45(4):263-5. doi: 10.5624/isd.2015.45.4.263. Epub 2015 Dec 17.
13. American Dental Association. Oral health topics: X-rays. Center for Scientific Information, ADA Science Institute. Updated: September 14, 2017.
14. White SC, Scarfe WC, Schulze RK, et al. The Image Gently in Dentistry campaign: promotion of responsible use of maxillofacial radiology in dentistry for children. Oral Surg Oral Med Oral Pathol Oral Radiol. 2014 Sep;118(3):257-61. doi: 10.1016/j.oooo.2014.06.001. Epub 2014 Jun 16.
15. Różyło-Kalinowska, I. Panoramic radiography in dentistry. Clin Dent Rev 5, 26 (2021).
16. Suparno, N.R., Faizah, A. and Nafisah, A.N., 2023. Assessment of panoramic radiograph errors: an evaluation of patient preparation and positioning quality at soelastri dental and oral hospital. The Open Dentistry Journal, 17(1).

## Additional References

- ADA Recommendations for Prescribing Dental Radiographs (2012)

## About the Authors



### **Shelly Withers, RDH, MS, PhD**

Shelly Withers has been a dental hygiene educator for over 20 years. She has worked in private practice, dental research, and served as DH Chair at LLU. She obtained degrees in Dental Hygiene (BS) and Health Professions Education (MS) from Loma Linda University. She earned a PhD in Psychology from Grand Canyon University. Her research interests include student/faculty well-being and educational psychology. She is a member of Sigma Phi Alpha National Dental Hygiene Honor Society, ADHA, and Psi Chi, the International Honor Society in

Psychology.

Email: [DrShellyWithers@gmail.com](mailto:DrShellyWithers@gmail.com)



### **Marilynn Heyde, RDH, MPH**

Marilynn Heyde is a graduated from Loma Linda University in 1974 with a BS in Dental Hygiene. In 2000, Marilyn completed a Master's in Public Health Education. Marilyn's career has included private practice, public health dental education, and dental hygiene education. At this time, Marilyn is an Associate Professor at Loma Linda University, teaching dental hygiene students preclinical courses and anesthesia. Marilyn has taught dental hygienists a variety of courses in the field of dental hygiene over the past 17 years.

Email: NA