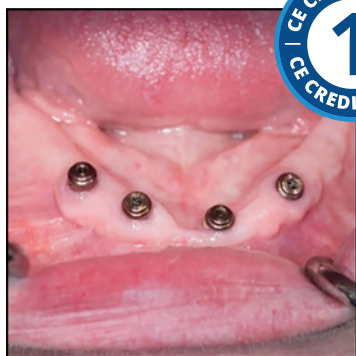

Full Arch Implant Prostheses: Part I - Diagnosis and Treatment Planning



Course Author(s): Swati Ahuja, BDS, MDS

CE Credits: 1 hour

Intended Audience: Dentists, Dental Students

Date Course Online: 02/25/2021

Last Revision Date: 02/24/2024

Course Expiration Date: 02/23/2027

Cost: Free

Method: Self-instructional

AGD Subject Code(s): 690

Online Course: www.dentalcare.com/en-us/ce-courses/ce612

Disclaimers:

- P&G is providing these resource materials to dental professionals. We do not own this content nor are we responsible for any material herein.
- Participants must always be aware of the hazards of using limited knowledge in integrating new techniques or procedures into their practice. Only sound evidence-based dentistry should be used in patient therapy.

Conflict of Interest Disclosure Statement

- Dr. Ahuja reports no conflicts of interest associated with this course, nor does she have any relevant financial relationships to disclose.

Introduction – Full Arch Implant Prostheses

The introduction of implant-supported prostheses has improved the quality of life of the edentulous population. The choice of the prostheses and the attachments should be based on various factors and not the preferences of the dentist or the patient. The success of an implant prosthesis relies on proper planning starting with the treatment prosthesis, progressing to CBCT assisted implant planning, and finally placement of implants with 3D surgical guides. Prosthetically driven implant planning ensures optimal placement of implants.

Please note: This is Part I of a two-part series. Full Arch Implant Prostheses: Part II - Fabrication Procedures will describe all the procedural steps for fabricating a predictable implant-supported removable dental prosthesis and an all-on-4/all-on-5 implant-supported fixed prosthesis. Each of the two courses can be taken independently and in any order.

Course Contents

- Overview
- Learning Objectives
- Introduction
- Mode of Retention of Removable Implant Prosthesis
 - Bar Attachments
 - Individual Stud Attachments
 - Selection of the Optimal Attachment System for Implant Overdentures
- Mode of Retention of Fixed Implant Prosthesis
- Diagnosis and Treatment Planning for Implant Prostheses
- Summary
- Course Test
- References / Additional Resources
- About the Author

Overview

Implants have helped improve the denture bearing foundation and quality of life of edentulous patients. Treatment options available for edentulous patients are complete dentures, implant-supported overdentures, and implant-supported fixed restorations. This course describes the factors governing the choice of implant prostheses and attachments/abutments for both removable and fixed implant restorations. It also details the entire treatment planning sequence starting with the treatment prosthesis, progressing to CBCT assisted implant planning, and finally placement of implants with 3D surgical guides.

Learning Objectives

Upon completion of this course, the dental professional should be able to:

- Understand the indications, contraindications, advantages and disadvantages of implant-supported fixed and removable prostheses.
- Choose optimal prostheses for the patient based on all relevant factors.
- Choose the most appropriate attachment system for the patient based on all the relevant factors including restorative space.
- Understand the entire workflow beginning with implant planning to implant placement based on both the anatomic and prosthetic determinants using CBCT, implant planning software, and 3D surgical guides.
- Learn to plan restoratively driven implants and understand the small but important

differences in implant placement for removable and fixed prostheses.

Introduction

Definition

Implant prosthesis is a prosthesis supported and retained in part or whole by dental implants.

Edentulism is considered a major health problem as it affects the overall well-being of an individual.¹⁻³ Traditionally, complete dentures were the only treatment option available for edentulous patients.⁴ The lack of prosthesis retention and stability coupled with poor masticatory efficiency led to dissatisfaction among denture patients, forcing them to seek alternative therapy.^{5,6} The advent of implants and implant prostheses have positively impacted the quality of life of many edentulous patients.⁶⁻¹⁰

An implant-supported and/or retained prosthesis can be fixed or removable. However, most dentists and patients believe that the most suitable restoration (that will eliminate all of the patient's existing problems) is a "fixed" implant prosthesis.¹¹⁻¹³ The choice of the definitive prosthesis should **not** be based on the preference of the dentist or the patient, rather, it should be determined by comprehensive diagnosis and treatment planning.¹³ The bone quantity and quality, the number, location and distribution of implants, the available restorative space, smile line, lip length, opposing arch, oral hygiene compliance, financial implications, and the time required for fabrication and maintenance of the prosthesis should be taken into consideration while choosing the type of implant prosthesis.^{11,12,14} Removable implant prosthesis can be indicated in most situations which may be conducive to the fabrication of fixed implant prosthesis.^{13,15,16}

Removable implant restorations (Implant overdentures) may be either implant-retained and mucosa-supported or implant-retained and implant-supported. When the prosthesis is retained by implants and supported by mucosal tissues, it is termed as an implant-retained and mucosa-supported prosthesis. When the prosthesis is retained and supported by implants, it is an implant-retained and

implant-supported prosthesis. Implant overdentures have several advantages compared to conventional complete dentures and removable partial dentures, including decreased bone resorption (in locations where implants are placed),¹⁷ reduced prosthesis movement, improved mastication, nutrition,^{18,19} appearance²⁰ (teeth placement can be dictated by esthetics), satisfaction²¹ and quality of life²² and maintenance of the occlusal vertical dimension (OVD). When compared to fixed implant prostheses, implant overdentures have the following advantages: (These can be also be interpreted as disadvantages of fixed implant prostheses.)

1. **Fewer implants needed:** Fabrication of implant-supported overdentures generally requires a lesser number of implants compared to fixed implant prostheses.
2. **Improvement of esthetics:** Patients with significant resorption of the labial aspect of the anterior maxilla require lip support to optimize the esthetics. The labial flange of the overdenture can be contoured to provide the desired lip support.^{20,23} Managing this situation with a fixed implant prosthesis would necessitate bone augmentation procedures or the development of non-cleansable contours in the fixed restoration.
3. **Improvement in speech:** The overdenture surfaces can be appropriately contoured and the prosthetic teeth can be optimally positioned to permit an improvement in speech. Also, the problem of air leakage between the prosthesis and the ridges is minimized with an overdenture.^{20,24,25}
4. **Easy to clean:** The oral cavity, attachments and the prosthesis are easy to clean because the prosthesis can be easily removed from the mouth.^{20,26}
5. **Cost-effective:** Removable implant restorations are less expensive to fabricate and repair than fixed implant restorations.

However, there are a few disadvantages associated with implant overdentures (which can also be interpreted as advantages of fixed implant prosthesis) they include the following:

1. All removable restorations must be kept out of the mouth for 6 to 8 hours in a 24-hour period which may be objectionable to some of the patients.²⁷

2. Removable implant prostheses generally require more restorative space than fixed implant restorations.²⁸

Note: Restorative space is the 3-dimensional oral space available (specific to the arch under consideration) to receive the proposed prosthodontics restoration.²⁹ Vertical restorative space may be assessed using measuring tools, such as a Boley gauge and existing complete dentures, wax rims (Figure 1A), or wax trial dentures. The tips of the measuring caliper should simultaneously contact the intaglio surface of the denture or record base and the deepest aspect of the overlying occlusal surface or the wax rim.²⁹ Vertical space may also be directly calculated using mounted casts with adjusted wax rims (Figure 1B) or wax trial dentures.²⁹ Also, computed tomography (CT) scans with computer-based planning can also be used to determine the available restorative space. The minimum vertical space requirement of various implant prostheses are shown in Table 1:²⁸⁻³⁰

Minimum Vertical Space Requirement of Various Implant Prostheses ²⁸⁻³⁰	
Fixed screw-retained (implant level) restoration (porcelain fused to metal/Zirconia) replacing a single/few teeth	4-5 millimeters
Fixed screw-retained (abutment level) prosthesis (porcelain fused to metal/Zirconia) replacing a single/few teeth	7.5mm
Fixed cement-retained prosthesis (porcelain fused to metal/Zirconia) replacing a single/few teeth	7-8mm
Fixed full arch implant prosthesis (porcelain fused to metal/Zirconia)	12mm
Fixed screw-retained complete denture (acrylic and metal)	15mm*
Overdenture supported by locator attachments	8.5mm
Overdenture supported by bar attachment system	13-14mm
*All the different types of fixed implant prostheses require lesser vertical restorative space compared to the removable implant prostheses except the fixed screw-retained complete denture.	

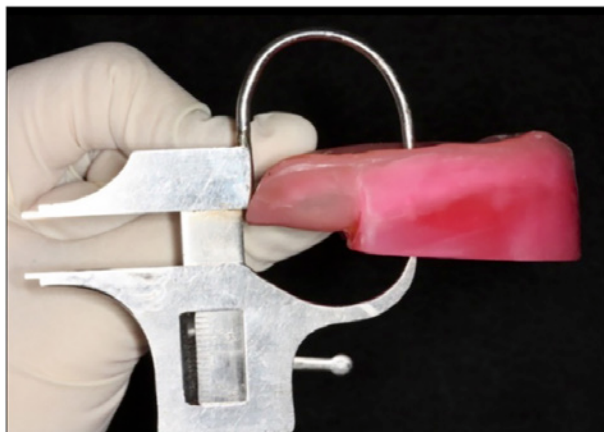


Figure 1A. Evaluation of restorative space using the wax rim and Boley gauge.

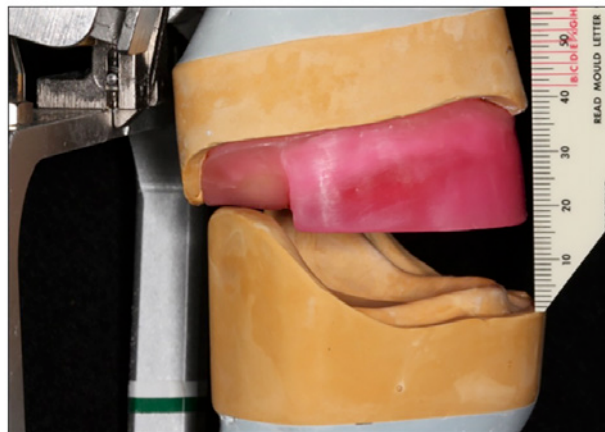


Figure 1B. Evaluation of restorative space using wax rims on mounted casts.

3. There is a need for constant replacement of the retentive elements of the stud attachments when used in situations where the implants are not placed parallel to each other.²⁷
4. Since fewer implants are placed, the osseous structures will continue to resorb in locations where there are no implants.²⁷

All these factors should be taken into consideration while choosing the type of implant prosthesis.

Mode of Retention of Removable Implant Prosthesis

Implant overdentures may be retained using bar and clip attachment systems and/or individual, free-standing abutment-based attachments. Freestanding attachments include balls, magnets, resilient stud attachments, such as the Locator system (Zest Dental Solutions), Locator R-Tx system (Zest Dental Solutions) and ERA (Sterngold), and non-resilient stud attachments such as Ankylos Syncone (Dentsply International).³¹

Bar Attachments

Bars are usually planned to accommodate non-parallel implant trajectories.³¹ Bars provide excellent stabilization, retention, and force distribution (due to splinting effect) (Figure 2A). There are various designs of bars such as Ackermann Bar (spherical shape), Dolder Bar (ovoid or “U” shape), and Hader Bar (keyhole shape).³¹ Bars may be casted, milled, or fabricated by CAD-CAM (computer-aided

designing/computer-aided manufacturing) technology.³¹ Fabrication of a prosthesis supported by a bar attachment requires substantial planning and is technique sensitive.^{28,31-35} Bars require more vertical restorative space (minimum 13-14mm) compared to individual stud attachments.³⁶ Patients with bar-supported prostheses may develop mucosal hyperplasia beneath the bar and mucositis around the implants when optimal oral hygiene is not maintained (Figure 2B).³¹ Individual stud attachments are preferred attachments (due to reduced tissue coverage) for patients with poor oral hygiene (Figure 3).³⁷

Individual Stud Attachments

With the advent of the locator attachment system, there has been a decrease in the use of magnets, ball attachments, and the ERA attachment system. Features such as resiliency, self-alignment³⁸⁻⁴⁰ (making it easy for the patient to align and seat the prosthesis), dual retention (internal and external),³⁸⁻⁴⁰ ease of replacement of the nylon retentive inserts^{41,42} and maintenance of oral hygiene,⁴³ lowest vertical profile⁴⁰ (3.17mm for external hexagon implant, 2.5mm for internal connection) (Figure 4), high success rate⁴⁴ and superior clinical performance (compared to ball and bar attachments)⁴⁰ have made the locator attachments very popular among the restorative dentists. The locator attachment system has become the attachment of choice when there is reduced vertical restorative space.²⁸ However, all stud attachments (Locator included) incur a

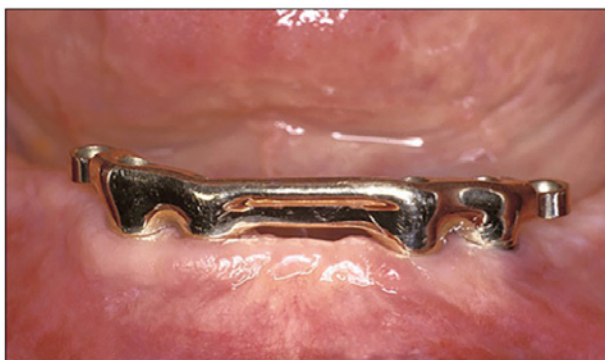

Figure 2A. Hader Bar fabricated with ERA extensions to support an overdenture.
Picture courtesy of Dr. Cagna

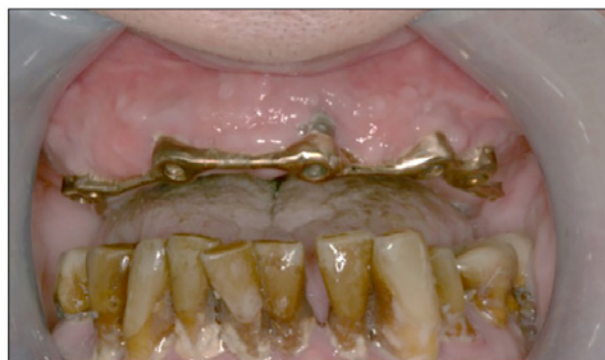

Figure 2B. Mucosal hyperplasia and mucositis in a bar-supported prosthesis due to poor oral hygiene.

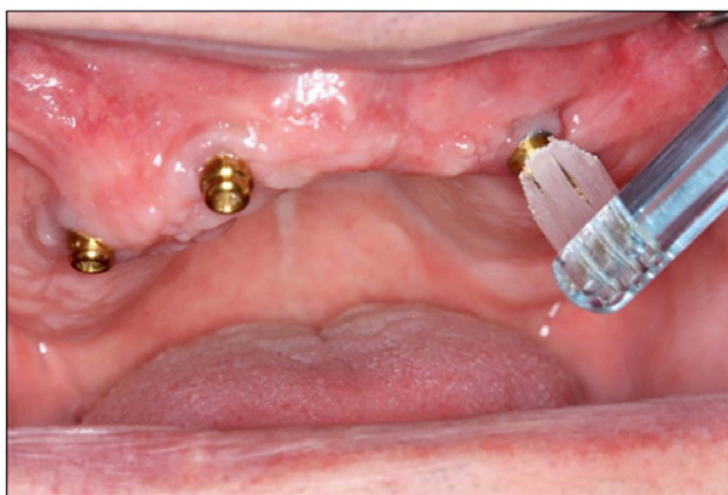


Figure 3. Easier accessibility for oral hygiene maintenance with individual stud attachments.




Figure 4. Comparison of vertical dimensions of the locator (left), mini ERA (center), and the ERA (right) attachment system.
Picture courtesy of Dr. Cagna

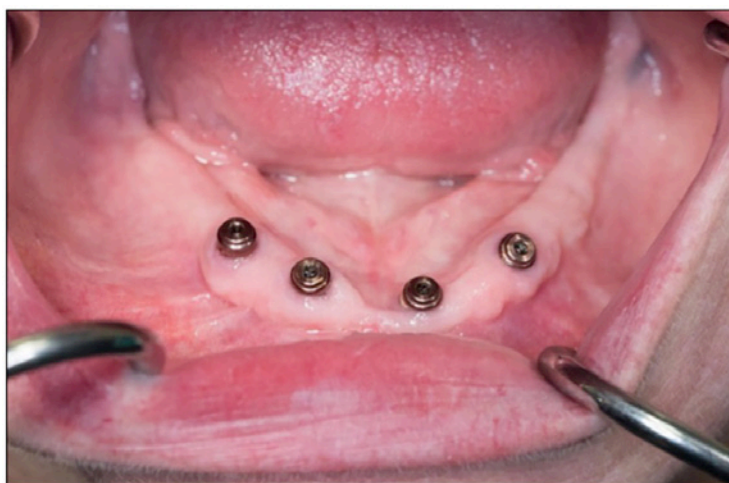


Figure 5. Locator R-Tx attachment system.

Picture courtesy of Dr. Massad

significant reduction in retention when used in association with converging/diverging implants.⁴⁵⁻⁴⁷ The extended range (Gray, red, orange, or green) locator inserts to correct up to 20° angulation per implant (40° between two implants) have been recommended for non-parallel implants. However, the extended range inserts only provide external retention and also wear faster than the standard range.^{48,49}

Recently introduced Locator R-Tx removable attachment system (attachment system for removable implant-supported prostheses) (Figure 5) eliminates the limitations associated with conventional locator attachment.⁴⁹ It permits a 50% increase in pivoting capability and up to 30° angle correction per implant as opposed to a maximum of 20° angle correction per implant with the conventional locator attachment system.⁴⁹ In addition to its angle correction capability, several new features have been incorporated to improve its clinical performance.⁴⁹ The success of a removable implant restoration primarily depends on the retentive capacity of its attachment to perform optimally over an extended period of time.

Selection of the Optimal Attachment System for Implant Overdentures

Attachment system selection depends on a variety of factors that must be identified early in the treatment sequence. These factors include:

1. Trajectory and position of implants:

Individual attachments (Locators, ERA, Ball, and Magnets) are often indicated when

implants are planned/placed parallel to each other.⁵⁰ When implants have non-parallel trajectories, a bar attachment, Syncone, or the R-Tx attachment system should be selected. Bar attachments are also preferred when implants cannot be placed in ideal locations due to interference with anatomic structures, such as the presence of mental foramen or ridge crest seen in patients with severely resorbed ridges.⁵¹⁻⁵³

2. **Desire for cross arch stabilization:** The inherent design of the bar attachment system provides cross arch stabilization.^{54,55}
3. **Decrease in Prosthesis size:** When patients require a minimum size of the definitive prosthesis, specifically designed milled bars can be utilized to accomplish the same.⁵⁶
4. **Frequent occurrence of sore spots:** Bar attachments are commonly indicated in patients who are xerostomic and/or prone to soft-tissue sore spots as the denture can be entirely bar supported, thereby minimizing impingement on denture bearing tissues.⁵⁷
5. **Poor oral hygiene:** Patients who are incapable of maintaining optimal oral hygiene or patients who will not dedicate appropriate time for maintenance of oral hygiene should be cautioned and, at times, denied placement of bar attachments until they commit to an appropriate oral hygiene regimen.⁴³
6. **Restorative space:** Minimum restorative space required for implant-supported overdentures with locator attachments is 8.5mm vertically.²⁹ Implant overdentures supported by bar attachments require a minimum of 12 to 14mm of vertical space.³⁶

7. **Ease of fabrication/repair:** Removable restorations supported by a bar are more challenging to fabricate and repair than removable restorations supported with individual stud attachments.^{31,33,35}
8. **Opposing arch:** It is necessary to identify the opposing arch in the treatment planning process. If a complete denture is planned for the maxillary arch; it would be advised to treatment plan the mandibular implant overdenture with individual stud attachments as opposed to a bar attachment system to avoid excessive forces on the maxillary ridge.³⁷
9. **Economics:** The cost of fabrication of the bar attachments in contrast to stud abutments will be much higher in most instances.^{11,53} However, treatment options should never solely be based on finances.

Mode of Retention of Fixed Implant Prosthesis

Fixed dental implant-supported prostheses may be either cement-retained or screw-retained. Screw-retained prostheses (Figure 6) are retrievable and require lesser vertical restorative space compared to cement-retained prostheses.^{58,59} Retrievability enables better hygiene maintenance of the prosthesis, the implants, and the surrounding mucosa⁶⁰ and easier management of the restorations in case of complications. Screw loosening, the requirement of sectioning and soldering procedures, increased costs, greater complexity of components and laboratory procedures, increased chairside time, and compromised esthetics, occlusion and porcelain strength

are the major disadvantages associated with screw-retained prostheses.⁵⁸⁻⁶¹ It is also difficult to place a screw-retained restoration in a patient's mouth with a limited oral opening as it may be challenging to insert the screwdriver in the oral cavity.⁶²

Cement-retained implant prostheses (Figure 7) offer superior stability,⁶³ occlusion, esthetics, stronger implant prosthetic connection, and improved force transmission compared to screw-retained implant prostheses.^{58,59} Extrusion of the excess cement into the peri-implant sulcus (which may be difficult to recognize and remove) is one of the major drawbacks of a cement-retained prosthesis.^{58,64} Several techniques have been reported that aid in preventing/decreasing the flow of cement into the subgingival sulcus.⁶⁴⁻⁶⁷

The Locator FIXED attachment system (attachment system for fixed implant-supported prostheses) (Figure 8) has been recently introduced by Zest Dental Solutions as a solution to the disadvantages of both screw and cement retention.⁶⁸ The Locator FIXED attachment system eliminates the use of screw access holes, cement, and several difficult intraoral procedures.^{23,68} It permits the fabrication and placement of a fixed full arch implant prosthesis using the conventional Locator attachments in conjunction with the proprietary fixed inserts. It also permits the transition from removable to fixed implant restorations using the same Locator attachments with proprietary fixed inserts. The Locator Fixed Denture Attachment

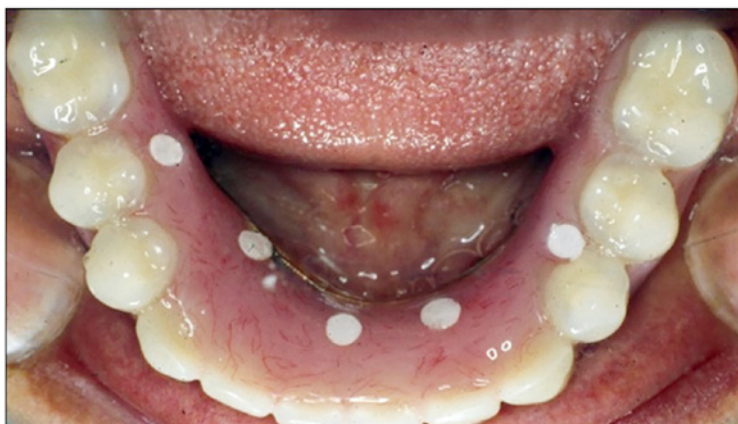

Figure 6. Screw-retained prosthesis.

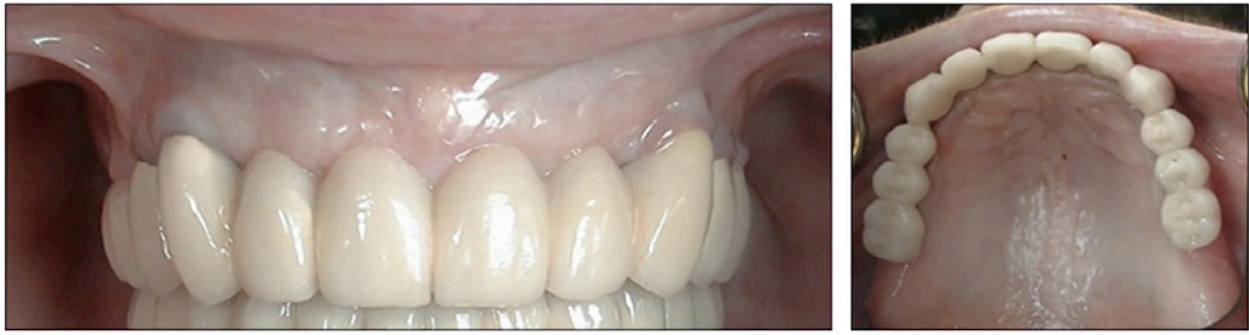

Figure 7. Cement-retained prosthesis.

Picture courtesy of Dr. Wicks

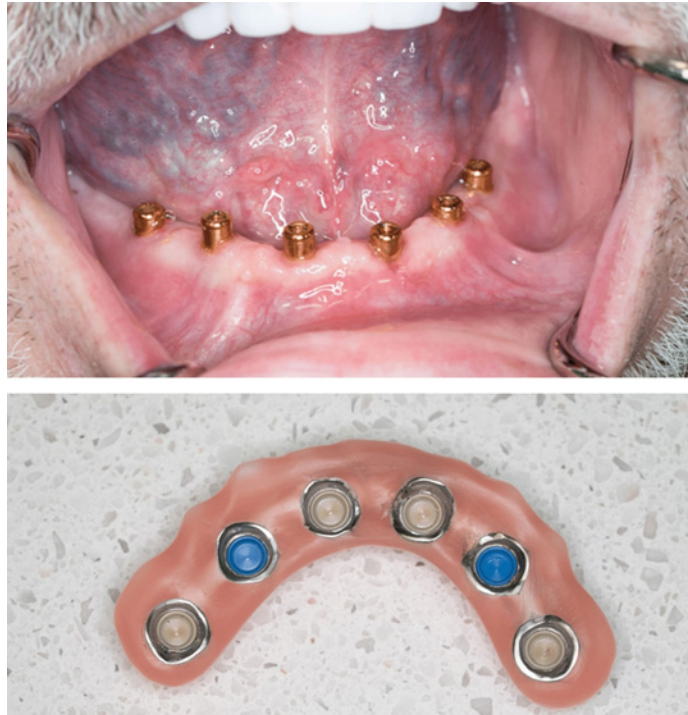

Figure 8. Locator FIXED attachment system used to retain a full-arch implant restoration.

Picture courtesy of Dr. Massad

Housings (DAHs) are picked up in the prosthesis via a chairside pick-up procedure similar to that used for the conventional locator attachment system.⁶⁸ The Locator FIXED inserts can accommodate implants with up to 20° of divergence, however, this system is not indicated for long cantilevers.

Diagnosis and Treatment Planning for Implant Prostheses

Treatment Prosthesis

Prior to planning implant restorations, it is critical to assess the medical and dental history

and ensure that there are no contraindications to the placement of dental implants. For any implant restoration to be successful, it is critical to plan and place implants accurately.^{69,70} Ideally a treatment prosthesis should be fabricated for every patient. This prosthesis helps the dentist gauge the restorative space (Figure 9), the lip support, phonetics, OVD, the relationship between the edentulous ridge and the intended position of the prosthetic teeth, the intended design of the definitive restoration, esthetics and expectations of the patient. The restorative dentist should decide the type and

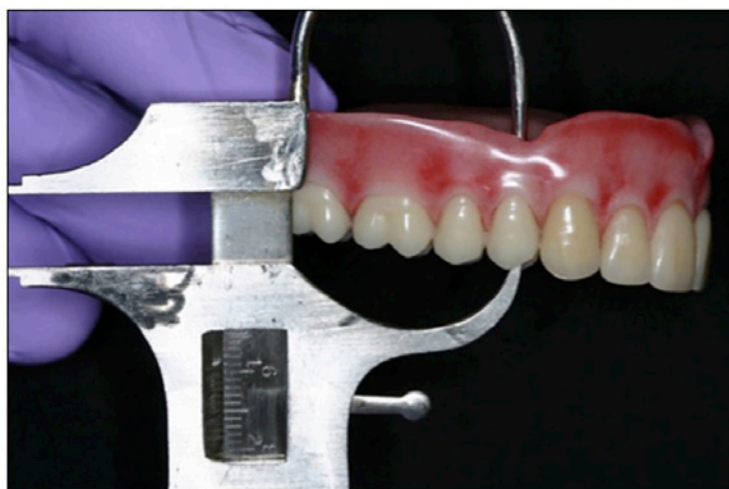

Figure 9. Boley gauge used to evaluate the vertical restorative space at the location of the right first premolar.

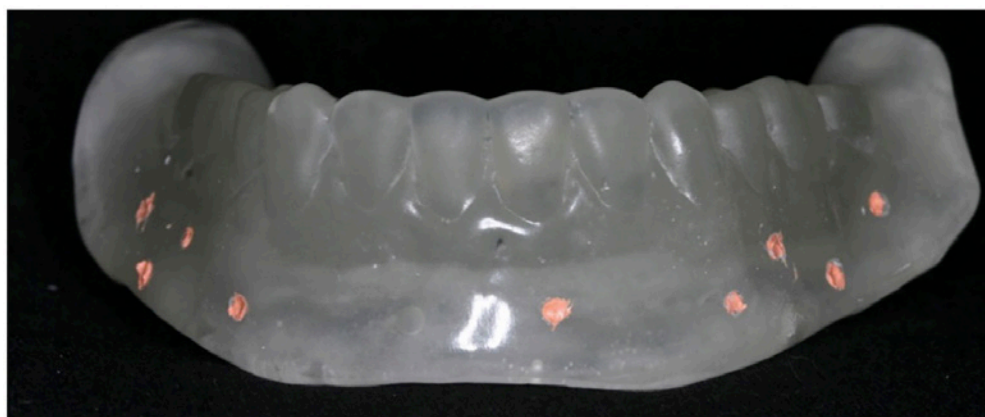

Figure 10. Fiduciary markers incorporated in the treatment prosthesis.

the design of the prosthesis before implant placement. If the patient is satisfied with the treatment prosthesis, it can be converted into a radiographic guide (by adding fiduciary markers or painting radiopaque ink) (Figure 10) and used to plan implant positions and angulations based on the intended position of the prosthetic teeth.⁷⁰

CBCT Assisted Implant Planning

It is beneficial to plan implant positions using the data generated from 3-dimensional (3-D) Cone beam computed tomography (CBCT) scans and guided implant planning software.⁷⁰⁻⁷² Usually two CBCT scans are made (Dual scan protocol). The first scan is made of the patient with the radiographic guide placed in the oral cavity, and the other scan is made of the radiographic guide itself. Using the implant planning software,

the raw data is converted into DICOM (Digital Imaging and Communications in Medicine) data and the data from the two scans is combined into one to treatment plan the implants in relation to the bone and prosthesis. This has helped change the osseous-driven approach to a combination of osseous- and prosthetic-driven approach for implant placement.⁷⁰⁻⁷³

The planning and placement of the implants should vary depending on the design of the prosthesis. For an implant-supported removable restoration, the long axis of the implants should emerge from the lingual aspect of the prosthetic teeth since it is the bulkiest part of the prosthesis. For a fixed implant restoration, the implants should emerge (the long axis of the implant) through the center of the prosthetic teeth. Implants

should be planned such that they are parallel to each other and perpendicular to the occlusal plane (Figure 11).

The anteroposterior (A-P) spread is the mesiodistal distance between the posterior edges of the distal implants and the midpoint of the most anterior implant in an arch.^{74,75} An A-P spread that minimizes the distal cantilevers and establishes stability may contribute to implant and prosthesis success.^{74,75} Hence, it is recommended to maximize the A-P spread of implants.^{74,75} When adequate A-P spread of the implants cannot be achieved (due to inadequate bone) implants can be tilted posteriorly to optimize the A-P spread. Multi-unit angle correction abutments can be used to correct the angulation of the tilted implants.

A minimum of 4 implants are required for a maxillary removable and a fixed implant prosthesis, respectively. A minimum of 1 (or 2) and 4 implants (with a good anteroposterior spread) are required for mandibular removable and fixed implant prosthesis, respectively. Incorporating additional implant/s than the bare minimum requirement is advantageous as it aids in providing extra support and also prevents the need for a subsequent surgical procedure if an implant is lost.

Another factor that must be evaluated during implant planning is the available vertical restorative space.^{28,29} Vertical restorative space can be calculated on the CBCT scan by measuring the distance between the platform of the planned implant and the occlusal surface of the prosthetic tooth (Figure 12).²⁹ Fabrication of a prosthesis in the presence of inadequate restorative space may lead to physiologically inappropriate contours, structurally weak prostheses, esthetic compromise, encroachment into freeway space, and/or suboptimal retention and stability of the treatment result.^{28,29} When the restorative space is inadequate, clinical procedures may be implemented to improve vertical space availability. These procedures include alveoloplasty, intentional increase in OVD, occlusal plane repositioning, and management of attachment selection.²⁸ These procedures should be implemented prior to implant placement when treatment options are being considered.²⁸

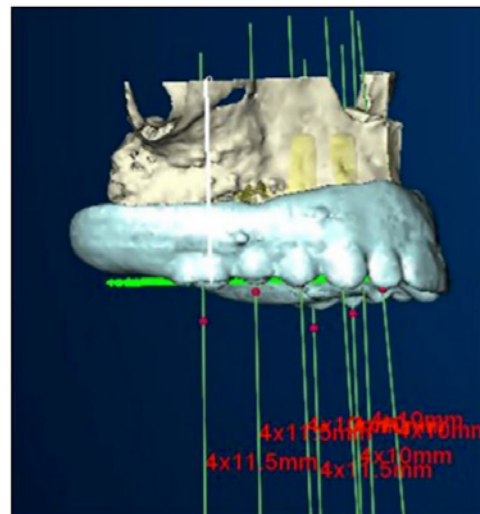


Figure 11. Implants planned parallel to each other.

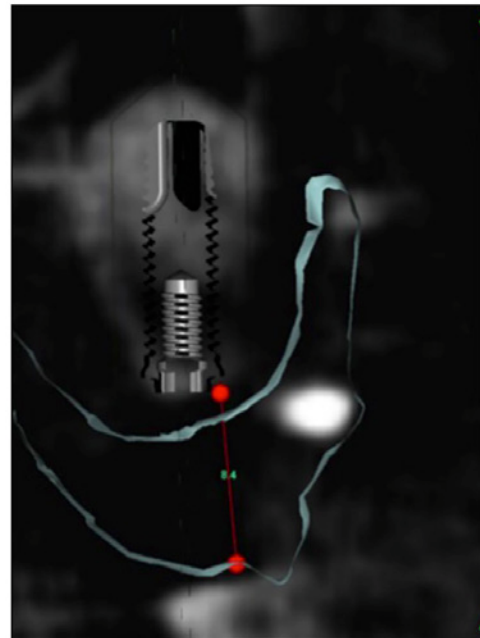

Figure 12. Vertical restorative space calculated on the CBCT cross-sectional image.

Surgical Guide and Guided Surgery

Anchor pins may be planned to help stabilize the surgical guide during the osteotomy procedures. Combining the CAD/CAM technique, digital implant planning can be applied to clinical practice using 3-D surgical guides.⁷¹⁻⁷³ Once the plan has been approved the CAD (computer-assisted design) files may be sent to the 3D surgical guide manufacturer for the fabrication of the 3D surgical guide (Figure 13).



Figure 13. 3D surgical guide.

The surgical guide should be tried in the mouth and adjusted to ensure that it completely seats in the mouth. The osteotomy, as well as implant placement, can be accomplished through the 3D guide following the manufacturers' recommended protocol (Figure 14). The surgical guide directs the osteotomies and placement of implants in the X, Y, and Z-axis. Following implant placement, a transitional fixed restoration, cover screws (requires second-stage surgery) or healing abutments may be attached to the implants. If cover screws/healing abutments are attached, the treatment denture may be adjusted as needed and then relined with a soft lining material and placed in the patient's mouth.

Note: The implant placement through the guide is exactly as planned in the software. It is so accurate that a cast may be retro

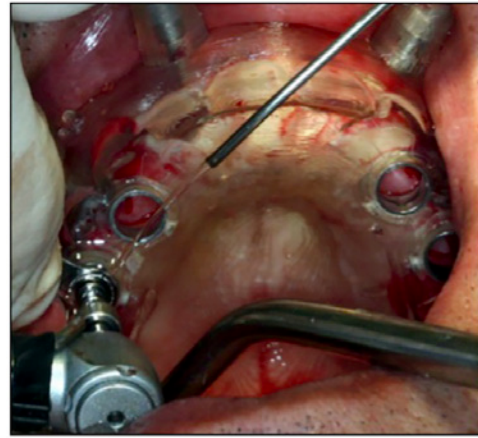


Figure 14. Implants placed through the 3D surgical guide.

engineered using the surgical guide and a transitional restoration can be fabricated on the cast prior to the placement of implants. If a transitional fixed restoration (pre-fabricated by the laboratory) is planned, the prosthesis is adjusted, the temporary abutment cylinders are picked up clinically, the prosthesis is finished and polished, screws are tightened and screw access holes are plugged with Teflon tape and sealed with composite resin.

Conclusion

Comprehensive diagnosis and thorough treatment planning are prerequisites to achieving successful implant rehabilitation. Information gathered during diagnosis can seamlessly influence surgical decision making, implant placement, choice of prosthesis and attachments, and the design of a definitive prosthesis.

Course Test Preview

To receive Continuing Education credit for this course, you must complete the online test. Please go to: www.dentalcare.com/en-us/ce-courses/ce612/test

- 1. Which of the following factors is NOT used in the early identification and selection of the attachment system for implant overdentures?**
 - A. Oral hygiene
 - B. Retrievability
 - C. Desire for cross arch stabilization
 - D. Trajectory and position of implants
- 2. Which of the following is NOT an advantage of cement-retained fixed implant prosthesis?**
 - A. Esthetics
 - B. Ease of repair
 - C. Stability
 - D. Occlusion
- 3. Which attachment system has the lowest vertical profile?**
 - A. Locator
 - B. Ball
 - C. Mini ERA
 - D. Magnets
- 4. The Locator FIXED and the R-Tx attachment system can be used for retaining and supporting implant overdentures. The technique of incorporating the locator FIXED denture attachment housing in a prosthesis is similar to that used for the conventional locator.**
 - A. Both the statements are true.
 - B. Both the statements are false.
 - C. The first statement is true. The second statement is false.
 - D. The first statement is false. The second statement is true.
- 5. Surgical guides can direct placement of implants in x, y and x axis.**
 - A. True
 - B. False
- 6. If a complete denture is planned for the maxillary arch which of the following prosthesis would be the optimal choice for the mandibular arch in a patient with Class III jaw relationship?**
 - A. Fixed cement retained all ceramic implant prosthesis
 - B. Fixed screw retained porcelain fused to metal implant prosthesis
 - C. Implant over denture supported with stud attachments
 - D. Implant overdenture supported by a bar
- 7. Which of the following CANNOT be used to correct the implant angulation?**
 - A. Multi-unit abutment
 - B. Locator FIXED
 - C. Locator R-Tx
 - D. Stock abutment

8. Which of the following is not used to retain a full arch implant supported fixed restorations?
- A. Cement
 - B. Locator
 - C. Locator R-TX
 - D. Screw
9. When the restorative space is inadequate clinical procedures may be implemented to improve vertical space availability. Which of the following procedures does NOT improve vertical dimension?
- A. Alveoloplasty
 - B. Intentional increase in occlusal vertical dimension
 - C. Intentional increase in rest vertical dimension
 - D. Occlusal plane repositioning
10. Design of the prosthesis should be determined after the placement and healing of implants. Removable implant prostheses generally require more restorative space than fixed implant restorations.
- A. Both the statements are true.
 - B. Both the statements are false.
 - C. The first statement is true. The second statement is false.
 - D. The first statement is false. The second statement is true.
11. Bars are usually planned to accommodate parallel implant trajectories. Bars provide excellent stabilization, retention and force distribution.
- A. Both the statements are true.
 - B. Both the statements are false.
 - C. The first statement is true. The second statement is false.
 - D. The first statement is false. The second statement is true.

References

1. Global Burden of Disease Study 2013 Collaborators. Global, regional, and national incidence, prevalence, and years lived with disability for 301 acute and chronic diseases and injuries in 188 countries, 1990-2013: a systematic analysis for the Global Burden of Disease Study 2013. *Lancet*. 2015 Aug 22;386(9995):743-800. doi: 10.1016/S0140-6736(15)60692-4. Epub 2015 Jun 7.
2. Nordenram G, Davidson T, Gynther G, et al. Qualitative studies of patients' perceptions of loss of teeth, the edentulous state and prosthetic rehabilitation: a systematic review with meta-synthesis. *Acta Odontol Scand*. 2013 May-Jul;71(3-4):937-51. doi: 10.3109/00016357.2012.734421. Epub 2012 Oct 29.
3. Peltzer K, Hewlett S, Yawson AE, et al. Prevalence of loss of all teeth (edentulism) and associated factors in older adults in China, Ghana, India, Mexico, Russia and South Africa. *Int J Environ Res Public Health*. 2014 Oct 30;11(11):11308-24. doi: 10.3390/ijerph111111308.
4. Lee DJ, Saponaro PC. Management of Edentulous Patients. *Dent Clin North Am*. 2019 Apr;63(2):249-261. doi: 10.1016/j.cden.2018.11.006. Epub 2019 Jan 30.
5. Prithviraj DR, Madan V, Harshamayi P, Kumar CG, Vashisht R. A comparison of masticatory efficiency in conventional dentures, implant retained or supported overdentures and implant supported fixed prostheses: A literature review. *J Dent Implant* 2014;4:153-7. doi: 10.4103/0974-6781.140882. Accessed February 22, 2021.
6. Sharka R, Abed H, Hector M. Oral health-related quality of life and satisfaction of edentulous patients using conventional complete dentures and implant-retained overdentures: An umbrella systematic review. *Gerodontology*. 2019 Sep;36(3):195-204. doi: 10.1111/ger.12399. Epub 2019 Mar 15.
7. Sargozaie N, Moeintaghavi A, Shojaie H. Comparing the Quality of Life of Patients Requesting Dental Implants Before and After Implant. *Open Dent J*. 2017 Aug 31;11:485-491. doi: 10.2174/1874210601711010485.
8. Zhang L, Lyu C, Shang Z, Niu A, Liang X. Quality of Life of Implant-Supported Overdenture and Conventional Complete Denture in Restoring the Edentulous Mandible: A Systematic Review. *Implant Dent*. 2017 Dec;26(6):945-950. doi: 10.1097/ID.0000000000000668.
9. Miranda SB, Possebon APDR, Schuster AJ, Marcello-Machado RM, de Rezende Pinto L, Faot F. Relationship Between Masticatory Function Impairment and Oral Health-Related Quality of Life of Edentulous Patients: An Interventional Study. *J Prosthodont*. 2019 Jul;28(6):634-642. doi: 10.1111/jopr.13070. Epub 2019 May 22.
10. Boven GC, Raghoobar GM, Vissink A, Meijer HJ. Improving masticatory performance, bite force, nutritional state and patient's satisfaction with implant overdentures: a systematic review of the literature. *J Oral Rehabil*. 2015 Mar;42(3):220-33. doi: 10.1111/joor.12241. Epub 2014 Oct 13.
11. Sadowsky SJ. The implant-supported prosthesis for the edentulous arch: design considerations. *J Prosthet Dent*. 1997 Jul;78(1):28-33. doi: 10.1016/s0022-3913(97)70084-2.
12. DeBoer J. Edentulous implants: overdenture versus fixed. *J Prosthet Dent*. 1993 Apr;69(4):386-90. doi: 10.1016/0022-3913(93)90186-r.
13. Zitzmann NU, Marinello CP. Treatment plan for restoring the edentulous maxilla with implant-supported restorations: removable overdenture versus fixed partial denture design. *J Prosthet Dent*. 1999 Aug;82(2):188-96. doi: 10.1016/s0022-3913(99)70155-1.
14. Stanford CM. Academy of Osseointegration's Summit on Clinical Practice Guidelines for the Edentulous Maxilla: Overview, Process, and Outcomes-Changing the Face of Implant Dentistry. *Int J Oral Maxillofac Implants*. 2016;31 Suppl:s6-s15. doi: 10.11607/jomi.16suppl.ovw.
15. Zitzmann NU, Marinello CP. Implant-supported removable overdentures in the edentulous maxilla: clinical and technical aspects. *Int J Prosthodont*. 1999 Sep-Oct;12(5):385-90.
16. Zitzmann NU, Marinello CP. Treatment outcomes of fixed or removable implant-supported prostheses in the edentulous maxilla. Part I: patients' assessments. *J Prosthet Dent*. 2000 Apr;83(4):424-33. doi: 10.1016/s0022-3913(00)70037-0.
17. Wright PS, Glantz PO, Randow K, Watson RM. The effects of fixed and removable implant-stabilised prostheses on posterior mandibular residual ridge resorption. *Clin Oral Implants Res*. 2002 Apr;13(2):169-74. doi: 10.1034/j.1600-0501.2002.130207.x.

18. Benzing U, Weber H, Simonis A, Engel E. Changes in chewing patterns after implantation in the edentulous mandible. *Int J Oral Maxillofac Implants*. 1994 Mar-Apr;9(2):207-13.
19. Morais JA, Heydecke G, Pawliuk J, Lund JP, Feine JS. The effects of mandibular two-implant overdentures on nutrition in elderly edentulous individuals. *J Dent Res*. 2003 Jan;82(1):53-8. doi: 10.1177/154405910308200112.
20. Heydecke G, Boudrias P, Awad MA, De Albuquerque RF, Lund JP, Feine JS. Within-subject comparisons of maxillary fixed and removable implant prostheses: Patient satisfaction and choice of prosthesis. *Clin Oral Implants Res*. 2003 Feb;14(1):125-30. doi: 10.1034/j.1600-0501.2003.140117.x.
21. Thomason JM, Lund JP, Chehade A, Feine JS. Patient satisfaction with mandibular implant overdentures and conventional dentures 6 months after delivery. *Int J Prosthodont*. 2003 Sep-Oct;16(5):467-73.
22. Awad MA, Lund JP, Shapiro SH, Locker D, Klemetti E, Chehade A, Savard A, Feine JS. Oral health status and treatment satisfaction with mandibular implant overdentures and conventional dentures: a randomized clinical trial in a senior population. *Int J Prosthodont*. 2003 Jul-Aug;16(4):390-6.
23. Brennan M, Houston F, O'Sullivan M, O'Connell B. Patient satisfaction and oral health-related quality of life outcomes of implant overdentures and fixed complete dentures. *Int J Oral Maxillofac Implants*. 2010 Jul-Aug;25(4):791-800.
24. Heydecke G, McFarland DH, Feine JS, Lund JP. Speech with maxillary implant prostheses: ratings of articulation. *J Dent Res*. 2004 Mar;83(3):236-40. doi: 10.1177/154405910408300310.
25. Lundqvist S, Lohmander-Agerskov A, Haraldson T. Speech before and after treatment with bridges on osseointegrated implants in the edentulous upper jaw. *Clin Oral Implants Res*. 1992 Jun;3(2):57-62. doi: 10.1034/j.1600-0501.1992.030202.x.
26. Feine JS, de Grandmont P, Boudrias P, Brien N, LaMarche C, Taché R, Lund JP. Within-subject comparisons of implant-supported mandibular prostheses: choice of prosthesis. *J Dent Res*. 1994 May;73(5):1105-11. doi: 10.1177/00220345940730051301.
27. Misch CE. *Dental implant prosthetics*, 2nd ed. St. Louis, MO: Elsevier Mosby; 2015.
28. Ahuja S, Cagna DR. Classification and management of restorative space in edentulous implant overdenture patients. *J Prosthet Dent*. 2011 May;105(5):332-7. doi: 10.1016/S0022-3913(11)60064-4.
29. Ahuja S, Cagna DR. Defining available restorative space for implant overdentures. *J Prosthet Dent*. 2010 Aug;104(2):133-6. doi: 10.1016/S0022-3913(10)60107-2.
30. Carpentieri J, Greenstein G, Cavallaro J. Hierarchy of restorative space required for different types of dental implant prostheses. *J Am Dent Assoc*. 2019 Aug;150(8):695-706. doi: 10.1016/j.adaj.2019.04.015.
31. Martínez-Lage-Azorín JF, Segura-Andrés G, Faus-López J, Agustín-Panadero R. Rehabilitation with implant-supported overdentures in total edentulous patients: A review. *J Clin Exp Dent*. 2013 Dec 1;5(5):e267-72. doi: 10.4317/jced.50817.
32. Gotfredsen K, Holm B. Implant-supported mandibular overdentures retained with ball or bar attachments: a randomized prospective 5-year study. *Int J Prosthodont*. 2000 Mar-Apr;13(2):125-30.
33. Behr M, Lang R, Leibrock A, Rosentritt M, Handel G. Complication rate with prosthodontic reconstructions on ITI and IMZ dental implants. *Internationales Team für Implantologie*. *Clin Oral Implants Res*. 1998 Feb;9(1):51-8. doi: 10.1034/j.1600-0501.1998.090107.x.
34. Mericske-Stern RD, Taylor TD, Belser U. Management of the edentulous patient. *Clin Oral Implants Res*. 2000;11 Suppl 1:108-25. doi: 10.1034/j.1600-0501.2000.011s1108.x.
35. Payne AG, Solomons YF. The prosthodontic maintenance requirements of mandibular mucosa- and implant-supported overdentures: a review of the literature. *Int J Prosthodont*. 2000 May-Jun;13(3):238-43.
36. Sadowsky SJ. Treatment considerations for maxillary implant overdentures: a systematic review. *J Prosthet Dent*. 2007 Jun;97(6):340-8. doi: 10.1016/S0022-3913(07)60022-5.

37. Massad JJ, Ahuja S, Cagna D. Implant overdentures: selections for attachment systems. *Dent Today*. 2013 Feb;32(2):128, 130-2.
38. Evtimovska E, Masri R, Driscoll CF, Romberg E. The change in retentive values of locator attachments and hader clips over time. *J Prosthodont*. 2009 Aug;18(6):479-83. doi: 10.1111/j.1532-849X.2009.00474.x. Epub 2009 Jun 3.
39. Büttel AE, Bühler NM, Marinello CP. Locator oder Kugelanker? Eine Hilfe für die klinische Entscheidungsfindung [Locator or ball attachment: a guide for clinical decision making]. *Schweiz Monatsschr Zahnmed*. 2009;119(9):901-18. French, German.
40. Cakarar S, Can T, Yaltirik M, Keskin C. Complications associated with the ball, bar and Locator attachments for implant-supported overdentures. *Med Oral Patol Oral Cir Bucal*. 2011 Nov 1;16(7):e953-9. doi: 10.4317/medoral.17312.
41. Chikunov I, Doan P, Vahidi F. Implant-retained partial overdenture with resilient attachments. *J Prosthodont*. 2008 Feb;17(2):141-148. doi: 10.1111/j.1532-849X.2007.00261.x. Epub 2007 Nov 15.
42. Kleis WK, Kämmerer PW, Hartmann S, et al. A comparison of three different attachment systems for mandibular two-implant overdentures: one-year report. *Clin Implant Dent Relat Res*. 2010 Sep;12(3):209-18. doi: 10.1111/j.1708-8208.2009.00154.x. Epub 2009 Mar 31.
43. Ahuja S, Wicks R, Selecman A. Fabrication of new restorations with a consideration of oral hygiene. *J Indian Prosthodont Soc*. 2016 Jul-Sep;16(3):307-10. doi: 10.4103/0972-4052.158084.
44. Seo YH, Bae EB, Kim JW, et al. Clinical evaluation of mandibular implant overdentures via Locator implant attachment and Locator bar attachment. *J Adv Prosthodont*. 2016 Aug;8(4):313-20. doi: 10.4047/jap.2016.8.4.313. Epub 2016 Aug 18.
45. Elsyad MA, Abid KS, Elkhalek EA. Effect of Buccal Implant Inclination on Stresses Around Two-Implant-Retained Overdentures with Resilient Stud Attachments. *Int J Oral Maxillofac Implants*. 2017 May/June;32(3):e135-e142. doi: 10.11607/jomi.5427. Epub 2017 Apr 12.
46. Aroso C, Silva AS, Ustrell R, et al. Effect of abutment angulation in the retention and durability of three overdenture attachment systems: An in vitro study. *J Adv Prosthodont*. 2016 Feb;8(1):21-9. doi: 10.4047/jap.2016.8.1.21. Epub 2016 Feb 23.
47. Uludag B, Polat S, Sahin V, Çomut AA. Effects of implant angulations and attachment configurations on the retentive forces of locator attachment-retained overdentures. *Int J Oral Maxillofac Implants*. 2014 Sep-Oct;29(5):1053-7. doi: 10.11607/jomi.3401.
48. Evtimovska E, Masri R, Driscoll CF, Romberg E. The change in retentive values of locator attachments and hader clips over time. *J Prosthodont*. 2009 Aug;18(6):479-83. doi: 10.1111/j.1532-849X.2009.00474.x. Epub 2009 Jun 3.
49. Zest Dental Solutions. Accessed February 22, 2021.
50. Chung KH, Chung CY, Cagna DR, Cronin RJ Jr. Retention characteristics of attachment systems for implant overdentures. *J Prosthodont*. 2004 Dec;13(4):221-6. doi: 10.1111/j.1532-849X.2004.04042.x.
51. Asvanund C, Morgano SM. Restoration of unfavorably positioned implants for a partially edentulous patient by using an overdenture retained with a milled bar and attachments: a clinical report. *J Prosthet Dent*. 2004 Jan;91(1):6-10. doi: 10.1016/j.prosdent.2003.09.009.
52. Taylor TD, Agar JR. Twenty years of progress in implant prosthodontics. *J Prosthet Dent*. 2002 Jul;88(1):89-95.
53. Khadivi V. Correcting a nonparallel implant abutment for a mandibular overdenture retained by two implants: a clinical report. *J Prosthet Dent*. 2004 Sep;92(3):216-9. doi: 10.1016/j.prosdent.2004.06.019.
54. Kurtzman GM. The locator attachment: free-standing versus bar-overdentures. *Dental Labor International Plus*. 2009;1:20-23.
55. English CE. Critical A-P spread. *Implant Soc*. 1990 Mar-Apr;1(1):2-3.
56. Moeller MS, Duff RE, Razzoog ME. Rehabilitation of malpositioned implants with a CAD/CAM milled implant overdenture: a clinical report. *J Prosthet Dent*. 2011 Mar;105(3):143-6. doi: 10.1016/S0022-3913(11)00025-4.
57. DeBoer J. Edentulous implants: overdenture versus fixed. *J Prosthet Dent*. 1993 Apr;69(4):386-90. doi: 10.1016/0022-3913(93)90186-r.

58. Misch CE. Principles of Fixed Implant Prosthodontics: Cement-Retained Restorations. Dental implant prosthetics, 2nd ed. St. Louis, MO: Elsevier Mosby; 2015:650-99.
59. Lewis MB, Klineberg I. Prosthodontic considerations designed to optimize outcomes for single-tooth implants. A review of the literature. Aust Dent J. 2011 Jun;56(2):181-92. doi: 10.1111/j.1834-7819.2011.01322.x.
60. Chee W, Jivraj S. Screw versus cemented implant supported restorations. Br Dent J. 2006 Oct 21;201(8):501-507. doi: 10.1038/sj.bdj.4814157.
61. Massad J, Wicks R, Ahuja S, Cagna DR. A Prosthesis Retention System for Full-Arch, Fixed, Implant-Supported Prosthesis. J Prosthodont. 2019 Apr;28(4):e912-e916. doi: 10.1111/jopr.12972. Epub 2018 Oct 8.
62. Guichet DL, Caputo AA, Choi H, Sorensen JA. Passivity of fit and marginal opening in screw- or cement-retained implant fixed partial denture designs. Int J Oral Maxillofac Implants. 2000 Mar-Apr;15(2):239-46.
63. Torrado E, Ercoli C, Al Mardini M, Graser GN, Tallents RH, Cordaro L. A comparison of the porcelain fracture resistance of screw-retained and cement-retained implant-supported metal-ceramic crowns. J Prosthet Dent. 2004 Jun;91(6):532-7. doi: 10.1016/j.prosdent.2004.03.014.
64. Yuzbasioglu E. A modified technique for extraoral cementation of implant retained restorations for preventing excess cement around the margins. J Adv Prosthodont. 2014 Apr;6(2):146-9. doi: 10.4047/jap.2014.6.2.146. Epub 2014 Apr 22.
65. Schwedhelm ER, Lepe X, Aw TC. A crown venting technique for the cementation of implant-supported crowns. J Prosthet Dent. 2003 Jan;89(1):89-90. doi: 10.1067/mpr.2003.66.
66. Lee JH, Park IS, Sohn DS. A digital approach to fabricating an abutment replica to control cement volume in a cement-retained implant prosthesis. J Prosthet Dent. 2016 Jul;116(1):25-8. doi: 10.1016/j.prosdent.2016.01.008. Epub 2016 Mar 2.
67. Begum Z, Sonika R, Pratik C. Effect of different cementation techniques on retained excess cement and uniaxial retention of the implant-supported prosthesis: an in vitro study. Int J Oral Maxillofac Implants. 2014 Nov-Dec;29(6):1333-7. doi: 10.11607/jomi.3724. Epub 2014 Aug 20.
68. Zest Dental Solutions. LOCATOR F-Tx® Fixed Attachment System: Fixed Full-Arch Restorations. Accessed December 1, 2023.
69. Engelman MJ, Sorensen JA, Moy P. Optimum placement of osseointegrated implants. J Prosthet Dent. 1988 Apr;59(4):467-73. doi: 10.1016/0022-3913(88)90044-3.
70. Gowd MS, Shankar T, Ranjan R, Singh A. Prosthetic Consideration in Implant-supported Prosthesis: A Review of Literature. J Int Soc Prev Community Dent. 2017 Jun;7(Suppl 1):S1-S7. doi: 10.4103/jispcd.JISPCD_149_17. Epub 2017 Jun 20.
71. Pal US, Chand P, Dhiman NK, Singh RK, Kumar V. Role of surgical stents in determining the position of implants. Natl J Maxillofac Surg. 2010 Jan;1(1):20-3. doi: 10.4103/0975-5950.69153.
72. Hultin M, Svensson KG, Trulsson M. Clinical advantages of computer-guided implant placement: a systematic review. Clin Oral Implants Res. 2012 Oct;23 Suppl 6:124-35. doi: 10.1111/j.1600-0501.2012.02545.x.
73. Ganz SD. Presurgical planning with CT-derived fabrication of surgical guides. J Oral Maxillofac Surg. 2005 Sep;63(9 Suppl 2):59-71. doi: 10.1016/j.joms.2005.05.156.
74. Shackleton JL, Carr L, Slabbert JC, Becker PJ. Survival of fixed implant-supported prostheses related to cantilever lengths. J Prosthet Dent. 1994 Jan;71(1):23-6. doi: 10.1016/0022-3913(94)90250-x.
75. El-Amier N, Elsaih E, Gibreel M, El-Motaiaim H. Effect of Implant Location on Palateless Complete Overdenture Retention: an In Vitro Study. J Oral Maxillofac Res. 2018 Sep 30;9(3):e3. doi: 10.5037/jomr.2018.9303.

Additional Resources

- No Additional Resources Available.

About the Author

Swati Ahuja, BDS, MDS



Dr. Ahuja graduated with a BDS from Nair Hospital Dental College in 2002 and an MDS certificate in Prosthodontics from the University of Tennessee Health Science Center, Memphis, TN. She then joined the same University as an Assistant Professor in the Department of Prosthodontics where she worked for 3 and half years. She served as the editor for the Department of Prosthodontics at University of Tennessee Health Science Center, Memphis, TN for the next 6 years. She has lectured nationally and internationally on various prosthodontic topics at various dental conferences. She has more than 60 publications in peer reviewed national and international journals. Dr. Ahuja is also the co-author of the textbook titled, "Applications of the Neutral Zone in Prosthodontics." Currently, she has a private practice in Mumbai.

Email: swatiahuja@gmail.com