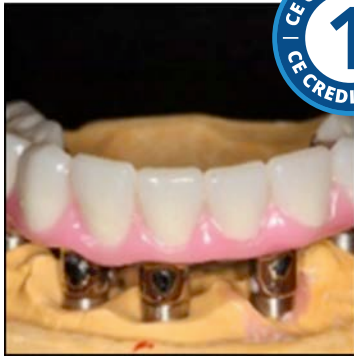

Full Arch Implant Prostheses: Part II - Fabrication Procedures



Course Author(s): Swati Ahuja, BDS, MDS

CE Credits: 1 hour

Intended Audience: Dentists, Dental Students

Date Course Online: 03/18/2021

Last Revision Date: N/A

Course Expiration Date: 03/17/2024

Cost: Free

Method: Self-instructional

AGD Subject Code(s): 690

Online Course: www.dentalcare.com/en-us/professional-education/ce-courses/ce618

Disclaimers:

- P&G is providing these resource materials to dental professionals. We do not own this content nor are we responsible for any material herein.
- Participants must always be aware of the hazards of using limited knowledge in integrating new techniques or procedures into their practice. Only sound evidence-based dentistry should be used in patient therapy.

Conflict of Interest Disclosure Statement

- Dr. Ahuja reports no conflicts of interest associated with this course, nor does she have any relevant financial relationships to disclose.

Introduction – Full Arch Implant Prostheses

Fabrication of a full arch implant-supported/assisted prosthesis is technique sensitive and a complex procedure. To achieve optimal fit, esthetics, and functional outcomes, all procedural steps should be performed accurately and thoroughly. An error introduced in any one of the procedural steps will intensify during the insertion of the final prosthesis necessitating a remake. Following all the steps accurately will ensure a predictable outcome.

Please note: This is Part II of a two-part series. [Full Arch Implant Prostheses: Part I - Diagnosis and Treatment Planning](#) describe the advantages, disadvantages, indications, and contraindications for implant-supported removable and fixed dental prostheses. Each of the two courses can be taken independently and in any order.

Course Contents

- Overview
- Learning Objectives
- Introduction
- Type and Design of Definitive Prosthesis
- Fabrication of Definitive Prosthesis
 - First Clinical Appointment
 - Second Clinical Appointment
 - Third Clinical Appointment
 - Fourth Clinical Appointment
 - Fifth Clinical Appointment
 - Sixth Clinical Appointment
- Summary
- Course Test
- References / Additional Resources
- About the Author

Overview

This course details all the steps for fabrication of Implant overdentures and “all-on-5” prostheses. The same procedural steps can be applied to the fabrication of various other types of implant prostheses. It describes the rationale for all the steps and the problems encountered if short cuts are taken and the steps are not performed thoroughly.

Learning Objectives

Upon completion of this course, the dental professional should be able to:

- Learn step-by-step procedures for fabricating implant-supported removable and implant-supported fixed prostheses (All-on-4).
- Understand the reasons for fabricating an impression index and a verification index.
- Understand the materials to be utilized for the fabrication of the impression index and the verification index.
- Understand that each step is crucial to the success of the definitive prosthesis.

Introduction

Definition

An implant prosthesis is a prosthesis supported and retained in part or whole by dental implants.

The successful osseointegration of implants has had an enormous impact on the treatment of edentulous patients. Rehabilitation with implant prostheses has significantly improved prosthesis retention and stability and the masticatory ability, esthetics, expectations, and the overall quality of life of edentulous patients.¹⁻³ In the early phase of implant dentistry, implants were used to retain full arch fixed, totally implant-supported prostheses.⁵⁻⁸ With the success of the fixed implant-supported prostheses, new prosthetic designs and types were developed. Initially, the bar-retained implant overdenture was introduced as an alternative to the fixed implant-supported prosthesis.⁹⁻¹² The bar supported implant overdenture helped improve the prosthesis retention, patient's masticatory ability and required a lesser number of implants compared to the fixed counterpart. It also aided in decreasing the financial burden of implant rehabilitation.¹² Easy placement and removal of the implant overdenture made oral hygiene maintenance easier to achieve. The implant overdenture also helped improve esthetics by providing optimal lip and facial support.^{13,14} With the continuous improvement in the success rates of implant, stud attachments were developed to retain and support the implant restorations, further reducing the treatment cost.¹⁵⁻¹⁷

Recently, newer technologies and materials (such as monolithic zirconia, milled monolithic acrylic, as well as new ceramics, polymers, and hybrids) have been developed and used for fabricating implant prostheses.¹⁸⁻²⁰ The use of digital dental technologies has improved the overall prosthetic outcome. CAD/CAM technology has helped fabricate simple and complex fixed and removable prostheses and frameworks.²¹ CAD/CAM frameworks are very accurate compared to the cast frameworks developed by the lost wax technique.²¹ CAD/CAM frameworks have a passive fit thereby decreasing the prosthesis movement and bacterial leakage.²² This course will describe in detail the fabrication steps for both removable and fixed implant prostheses along with a brief discussion on CAD-CAM frameworks.

Type and Design of Definitive Prostheses

The type of the prostheses to be fabricated (and the attachments to be used) should be decided prior to the placement of implants. The number and position of implants should be planned based on the design of the intended prosthesis. All the factors discussed in part I section of this course should be taken into consideration while deciding the type of prosthesis.

If an open palate overdenture design is planned for the maxillary arch, a minimum of 4 implants should be planned with a wide anteroposterior (AP) spread (implants configured in canine and first molar bilaterally). The implants should be planned such that they are parallel to each other and emerge through the palatal aspect of the prosthetic teeth. However, if adequate bone is available, planning 6 implants would be advantageous, the reason is even if one or two implants are lost, there would still be a sufficient number of implants left to permit the continuation of the same treatment.

Similarly, if a fixed implant prosthesis is planned for the mandibular arch a minimum of 4 implants should be planned with a wide AP spread (implants configured in canine and first molar bilaterally). However, if sufficient bone is available, 6 implants would be preferable. When an optimal AP spread of implants cannot be achieved due to lack of posterior bone height, the posterior implants may be intentionally angled to improve the AP spread (all-on-4 prostheses). The protocol for the "all-on-4" prosthesis includes the use of four implants in the anterior part of edentulous jaws to support a fixed prosthesis. The two most anterior implants are placed axially, whereas

the two posterior implants are placed distally and angled to minimize the cantilever length and to allow the fabrication of prostheses with 10-12 prosthetic teeth. The length of the cantilever should be kept as small as possible when treatment planning an "all-on-4/all-on-5" implant prosthesis. The angulation of the implants can be corrected using multi-unit angle corrections abutments. However, the use of these abutments increases the vertical restorative space requirement by 2-3mm.

Implant Overdentures

An implant overdenture supported by individual attachments may be fabricated by one of the two methods. A conventional complete denture may be fabricated and the retentive elements of the attachments can be picked up chair-side during placement of the denture or the retentive elements can be incorporated in the prosthesis during denture processing. The latter technique is also used for the fabrication of bar-supported overdentures.

Fabrication of Definitive Prostheses

The technique for fabrication of a maxillary implant overdenture with an open palate design (retentive elements incorporated during denture processing) and a mandibular "all-on-5" fixed (Figure 1) implant-supported complete denture (acrylic with titanium framework) is described below:

Second Stage Surgery

Following implant placement and a 3-4-month healing period (as determined by the surgeon), second stage surgery is performed (if needed) and cover screws are replaced with healing abutments (Figure 2). The transitional prostheses are adjusted and relined with a

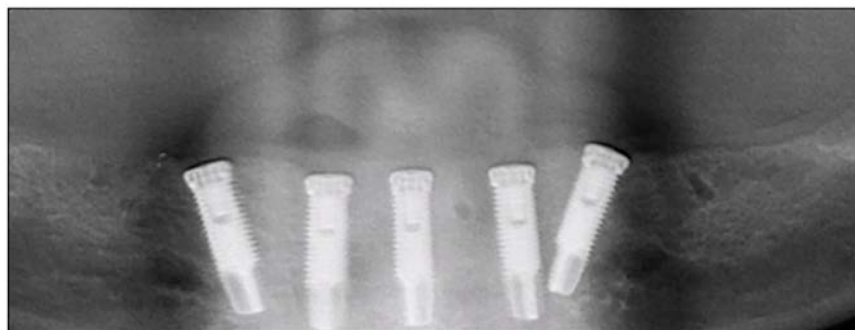


Figure 1. Mandibular posterior implants intentionally tilted by 30° to improve the AP spread.

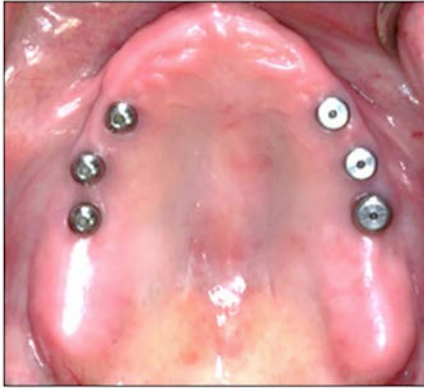

Figure 2A. Healing abutments attached to the maxillary implant.

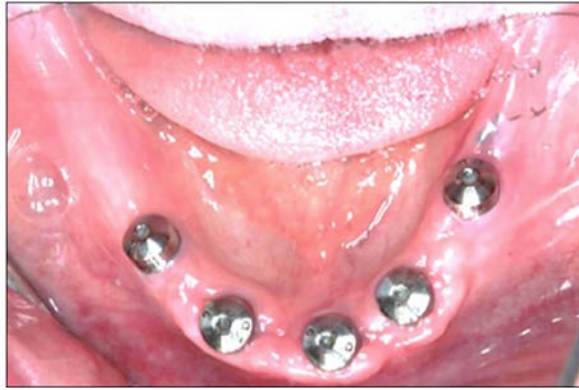

Figure 2B. Healing abutments attached to the mandibular implants.

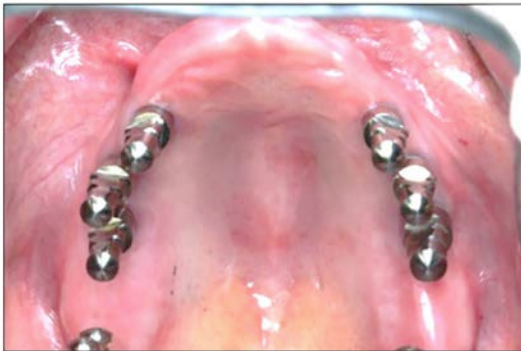

Figure 3A. Closed tray impression copings attached to the maxillary implants.

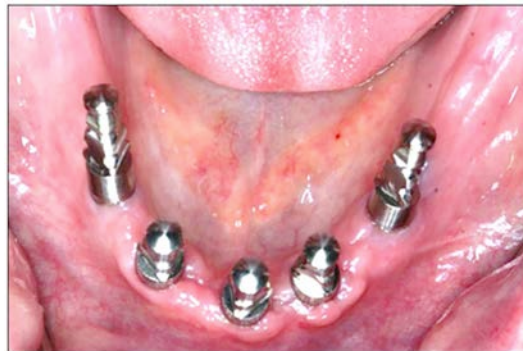

Figure 3B. Closed tray impression copings attached to the mandibular implants.

soft relin material. The procedures for the fabrication of the definitive prostheses are initiated after 2-3 weeks.

First Clinical Appointment

Primary Impressions

The healing abutments are removed and kept aside in labeled containers denoting their exact positions. Closed tray impression copings (preordered prior to the appointment for all the implants) are attached to the implants (Figure 3). Ease in the placement of the impression copings can be achieved by starting with the posterior-most implant and then proceeding anteriorly. Upon removal of the healing abutments, the impression coping should be immediately attached to the implants to prevent tissue rebound. Primary impressions may be made using alginate in stock trays (dentate trays, to accommodate the height of the impression copings) (Figure 4).

Following the removal of the impression, the impression copings are removed from the mouth one by one, starting with the anterior-most first and then proceeding posteriorly. The healing abutments are replaced as soon as the impression copings are removed. The impression copings are attached to the implant replica/analog (preordered for all the implants) and placed in the impression coping indentations in the impression. The impression copings are placed in the same location as they were in the mouth. Once all the impression copings with the analogs are placed in the impression, the impressions are carefully poured using type III dental stone to generate an implant level cast.

Second Clinical Appointment

Preparation for Master Impressions

- a. *Multi-unit Abutments attached to the mandibular implant analogs*

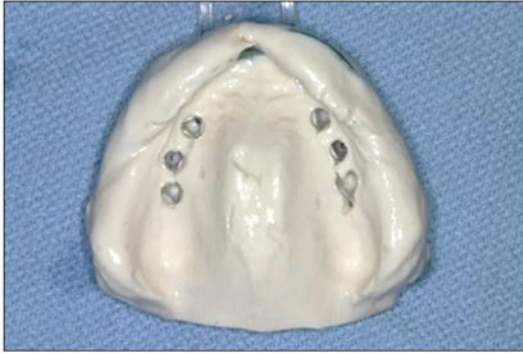

Figure 4A. Maxillary primary impression.

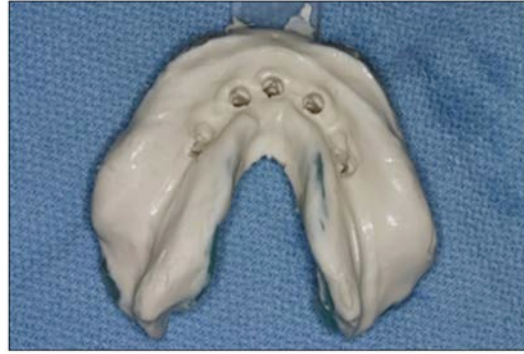

Figure 4B. Mandibular primary impression.

Multi-unit angle correction abutments are utilized to correct the divergence of the angulated posterior mandibular implants. 30° Multi-unit angle correction abutments are attached to the posterior implant analogs on the cast and are aligned such that they are parallel to the remaining implants and themselves. Straight multi-unit abutments are attached to the anterior mandibular implant analogs on the cast. Note: The multi-unit abutments on the anterior implants are used to keep all the implant platforms at the same level (not to correct angulation of implants) and maintain consistency while ordering implant components.

- b. *Splinting Impression Copings*
 Accurate transfer of the spatial relationships of the implants from the oral cavity to the master cast is a very critical first step for fabricating a well-fitting and passive implant framework and prosthesis.²³ A poorly fitted implant framework/prosthesis will exert uneven occlusal loads and stresses on the implants leading to marginal bone loss, failure of implants, loosening of screws, and fatigue fractures of implant components.^{24,25}

The open tray impression copings (pre-ordered) are attached to the maxillary implant analogs and mandibular multi-unit abutments on the primary casts. The open-tray master impression can be made by attaching the open-tray impression copings to the implants/abutments in the mouth and picking them directly in the master impression. Alternatively, they (copings) can be splinted to provide more rigid fixation of the copings within the impression.

Splinting of the open tray impression copings while making a master impression aids in making an accurate impression by minimizing the movement/rotation of the copings during impression making, removal, and pouring of the impression. Splinting of the copings aids in generating an impression index. Various materials may be used for splinting the impression copings including auto polymerizing resin [DuraLay (Reliance) or Pattern Resin LS (GC AMERICA INC)], dual-cured resins, plaster, and prefabricated resin bars.

- c. *Fabricating an impression index and custom trays*

The maxillary open tray copings may be splinted with prefabricated resin bars and auto polymerizing acrylic resin (having minimum polymerization shrinkage) on the primary cast. The mandibular copings may be splinted with floss and auto polymerizing acrylic resin (having minimum polymerization shrinkage) on the primary cast. The impression index generated is sectioned between adjacent implants and opposing implants (Figure 5). A layer of spacer wax is adapted over the splinted copings and the cast, and custom trays are fabricated (Figure 6). The screw axis holes are created on the custom trays to enable the pick-up of the copings in the impression.

Master Impression

During the clinical appointment, healing abutments are removed. The 30° multi-unit angle correction abutments (retrieved from the casts) are attached to the two posterior mandibular implants in the predetermined position and the straight multi-unit abutments

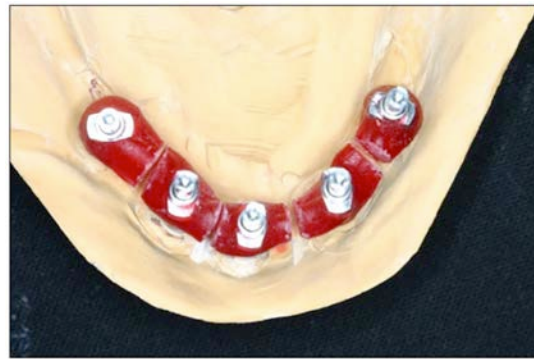

Figure 5. Impression index sectioned between opposing and adjacent implants.

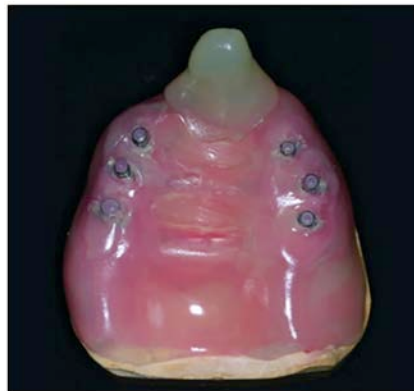

Figure 6A. Maxillary custom tray.

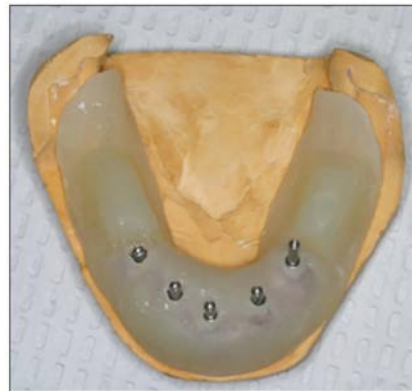

Figure 6B. Mandibular custom tray.

are attached to the anterior mandibular implants. All the abutments are torqued as per the manufacturer's recommendations (Figure 7).

The impression index sections (attached to the impression copings) are attached to the implants/abutments in the mouth in their predetermined positions. The split sections of the index are reconnected to each other with auto polymerizing resin (having minimum polymerization shrinkage). Upon polymerization of the resin material, the passivity of the index may be tested by performing the one screw test (Sheffield test).

Sheffield test/ one screw test: The index is said to be passive if all the impression copings are completely seated on the implant/abutment platform when only one of the impression copings is attached to the implant/abutment (the distal-most implant) with a screw. If the junction of the impression coping and the implant platform is subgingival, the seating

of the impression copings may be verified with a radiograph (periapical or a panoramic radiograph.)

Border molding procedures are performed for both the maxillary and mandibular arches. Most restorative dentists do not perform border molding procedures while fabricating a fixed prosthesis; however, if the treatment plan is altered to a removable prosthesis at the time of try-in, one may have to repeat all the steps starting from master impression if the border molding procedures were not performed. The maxillary and mandibular master impressions may be made using vinyl polysiloxane (VPS) or polyether impression material (Figure 8). Following the complete polymerization of the impression material, the impression copings are detached from the maxillary implants and mandibular abutments by loosening the screws through the screw access perforations in the tray. The impressions are removed from the oral cavity and examined for detail. The impression indices with the copings are picked

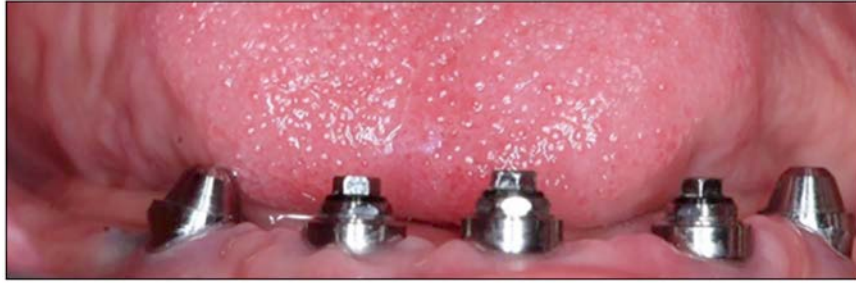

Figure 7. Multi-unit abutments attached to the mandibular implants.

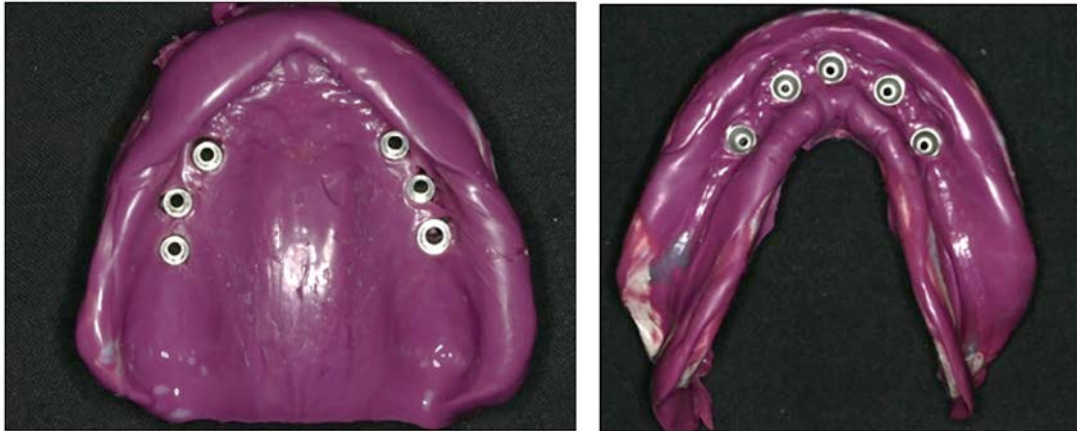


Figure 8. Master Impressions.

up in the impressions. The healing abutments and healing caps are attached to the maxillary implants and mandibular multi-unit abutments respectively. Appropriately sized maxillary implant analogs and mandibular multi-unit abutment analogs are attached to the maxillary and mandibular impression copings respectively (on the impression). Tissue forming material is injected around the copings and the impressions are beaded, boxed, and poured with Type IV die stone to generate implant and abutment level maxillary and mandibular casts respectively.

Note: Digital impressions have become very popular in the last twenty years, however, the literature reports that intraoral scans for complete arch prosthesis are not very accurate and should be restricted to short spans.

Third Clinical Appointment

Verification Index Fabrication

Inaccuracies can be introduced during the making of the impression, attachment of

the analogs to the impression copings, and pouring of the cast. These inaccuracies cause misfit and lead to non-passive castings.²⁶ Passively fitting implant prosthesis can only be generated on a cast with verified implant positions.²⁷⁻²⁹ It is recommended to use a verification index for verifying the implant positions on the cast.³⁰⁻³² A verification of the master cast prior to the framework fabrication minimizes the possibility of having to remake the framework. Verification of the master cast is a critical step in prosthesis fabrication and it aids in decreasing stress, dissatisfaction, and treatment costs.

Fabricating an all-resin verification index may give the clinician a false-positive result owing to the flexibility of the resin material. A rigid material and non-engaging copings (false-positive results may be achieved with engaging copings) should be used for the fabrication of the verification index. Verification indices may be fabricated using a thick metal wire (as thick as a coat hanger wire) and minimal auto

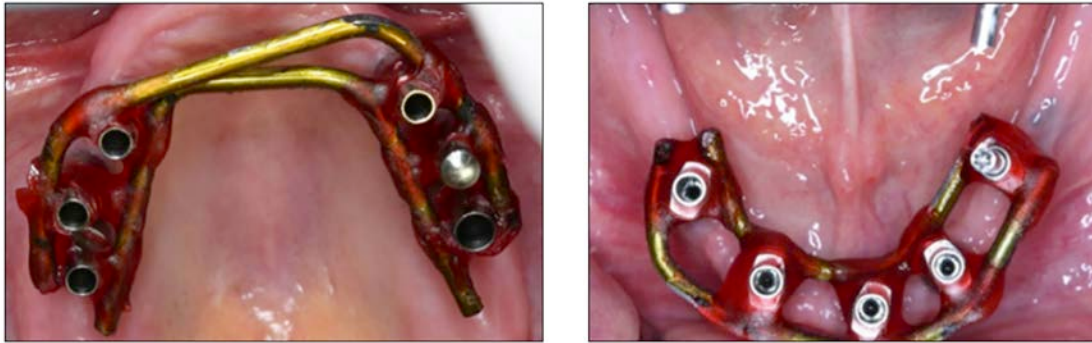


Figure 9. Verification index tested with one screw test.

polymerizing resin material (DuraLay, Reliance) (with minimum polymerization shrinkage) to join the wire segments.²⁶ The verification index is first tested on the cast with one screw test (Sheffield test).

Verification Procedure

The maxillary healing abutments and the mandibular healing caps are removed and placed in labeled containers. The verification index is tested in the mouth with the one screw test (Figure 9). A single screw is tightened, and the seating of all the other copings is noted. This process is repeated for all the implants. A panoramic/periapical radiograph is taken to verify complete seating of the verification index with one screw test when the junction of the coping and the implant platform is subgingival. When the verification index does not seat on the other implants with one screw tightened, it indicates that the cast is inaccurate. When the cast is inaccurate, the impression needs to be remade and the cast would need to be reverified.

Fabrication of Trial Denture Base and Wax Occlusal Rims and Registering the Jaw Relation Records

Trial denture base (Triad, Dentsply Prosthetics) and wax occlusal rim are fabricated for the mandibular abutment level cast. The healing abutments attached to the maxillary implants in the mouth are removed and are attached to the implant analogs on the maxillary cast and the trial denture base is fabricated over the healing abutments. This helps in achieving improved stability of the maxillary trial denture base while registering the interocclusal records.

The healing abutments (retrieved from the laboratory) are reattached to the maxillary implants in the mouth. Using standard complete denture clinical methods for assessing esthetics, phonetics, and biomechanical dictates of appropriate denture tooth position, the maxillary wax occlusion rim is appropriately adjusted clinically. The adjusted wax occlusal rim served as a guide for setting the prosthetic teeth accurately. Maxillary anterior teeth are set chairside and evaluated for esthetics and phonetics at the same appointment.³³⁻³⁸ This procedure is time-consuming, however, it precludes the need for redoing the wax try-in procedures associated with the improper setting of anterior maxillary teeth. Preview shell teeth (Nobilium) may be waxed to the maxillary occlusal rim and utilized for evaluating esthetics and phonetics.

The mandibular wax occlusal rim is adjusted to establish the optimal occlusal vertical dimension (OVD). The centric relation record is registered at the established OVD with a VPS bite registration paste (Regisil, Dentsply Caulk) (Figure 10). Next, a face bow record and a protrusive record (to set the articulator's condylar elements, to achieve balanced occlusion) are registered. The casts, trial denture bases, and the interocclusal records are sent to the laboratory for mounting of the casts in the articulator and setting the prosthetic teeth.

Fourth Clinical Appointment

Wax Try-in

The wax trial dentures are evaluated intraorally for esthetics (Figure 11), phonetics, and OVD.

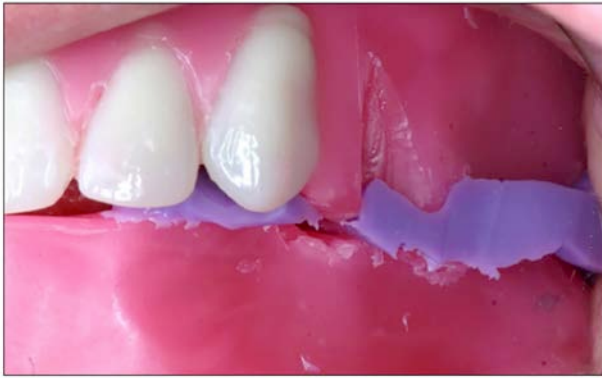

Figure 10. Registering the interocclusal records.

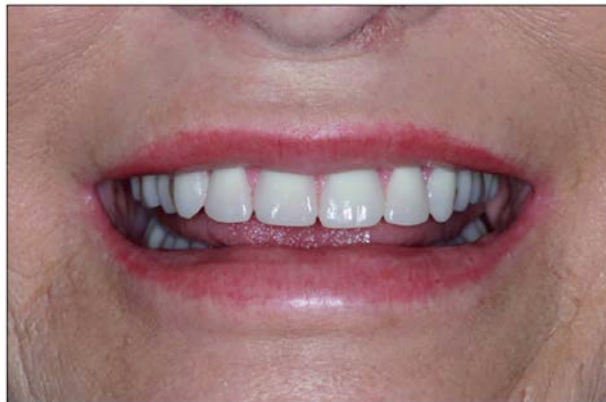

Figure 11. Evaluating patient esthetics during the wax try-in procedure.

The occlusal contacts are checked to ensure a bilateral balanced occlusion.

The patient's partner (or significant other person in their life) must be present during this appointment. They should be asked to opine about the esthetics and phonetics with the wax trial dentures and changes should be made as necessary. Approval from both of them, prior to proceeding with the next step is crucial, since, the same tooth set up will be used as a guide to fabricate the frameworks and will also be replicated in the definitive prostheses.

External Impressions

Next external impressions may be made to develop appropriate contours of the polished surface of the maxillary wax trial denture.³⁹ Baseplate wax apical to the prosthetic teeth on the wax trial denture is carefully removed, VPS tray adhesive (Caulk tray adhesive, Dentsply Caulk) is painted on the area where the wax is removed (Figure 12A) and low viscosity VPS

impression material (Aquasil Ultra LV fast set, Dentsply Caulk) is applied to the same area (Figure 12B). The wax trial denture with the impression material is inserted in the patient's mouth. The patient is instructed to make orofacial movements such as pucker their lips, smile, cough, suck, open and close the mouth and move the jaw from side to side to make the maxillary external impression. The wax trial denture is removed from the mouth following the complete polymerization of the impression material and evaluated. Excess impression material is trimmed with scissors (Figure 12C).

Verification of the Restorative Space, Selection of Attachments, and Framework Fabrication for The Maxillary Prosthesis

Ideally, restorative and esthetic spaces should be evaluated in the diagnostic phase before the placement of implants.⁴⁰⁻⁴³ Nevertheless it must be verified and re-verified before selecting the attachments and processing the denture. An occlusal or facial matrix of the wax trial denture may be used for re-assessing the restorative space. All the factors discussed in Part I of this course should be taken into consideration while making the attachment selection.

When inadequate vertical restorative space is present, locator abutments are the attachments of choice. They are selected for each implant based on the height of the mucosal cuff. Incorporation of the metal framework in the design of the overdenture aids in increasing its strength (especially important when restorative space is inadequate), decreasing its flexure (when the open palate design is planned) and fracture susceptibility.^{44,45} The locator abutment assembly (abutment and their retentive element) is attached to the implant analogs on the maxillary casts. The maxillary master cast and the wax trial denture are sent to the laboratory for fabrication of the metal framework. The restorative dentist should provide the design of the framework to the laboratory (Figure 13A). The framework is examined and adjusted to ensure complete seating on the cast (Figure 13B).

Designing and Fabrication of the Milled Framework for the Mandibular Prosthesis

The mandibular master cast and wax trial denture are sent to the laboratory for the

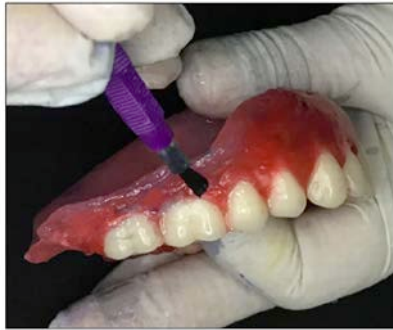

Figure 12A. VPS tray adhesive painted on the area where the wax is removed.

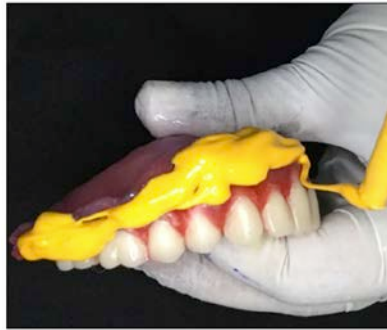

Figure 12B. Low viscosity VPS impression material applied to the same area.

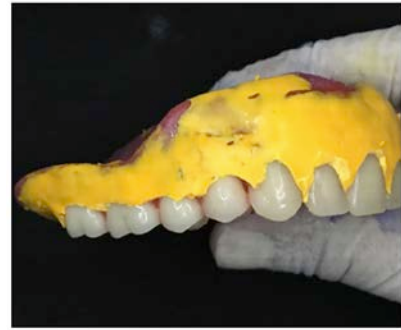

Figure 12C. Trimmed external impression.

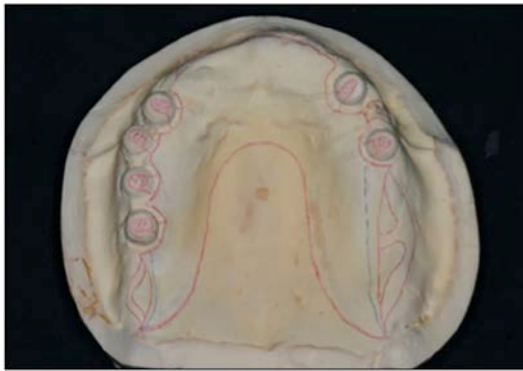

Figure 13A. Framework design.

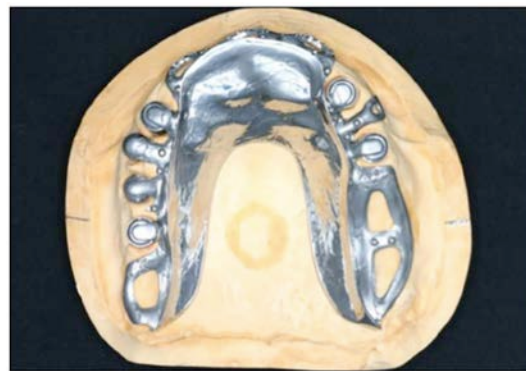

Figure 13B. Maxillary framework.

fabrication of the CAD/CAM milled titanium framework (more accurate compared to a cast framework) for the “all-on-5” prosthesis. Precision of fit (passivity), durability, simplicity, and ability to use biocompatible and/or esthetic materials such as titanium and zirconia are some of the advantages of CAD/CAM framework (however, they are more expensive compared to casted frameworks.)²¹ It is important to be involved in the designing process of the framework. The technician should be asked to send screenshots of the design for approval. While reviewing the software images, there should be adequate distance between the framework and the tissue to perform oral hygiene. The framework should extend posteriorly up to the distal-most prosthetic teeth and it should be within the confines of the prosthetic teeth in all 3 dimensions (Figure 14). A short dental arch is planned for this patient based on the position of the implants. Increasing the number of posterior teeth will increase the cantilever length and the stresses on the implants.

Fifth Clinical Appointment

Mandibular Framework Try-in

The healing caps are removed and the mandibular milled framework (Figure 15) is evaluated intraorally. The milled framework should passively seat on all the implants. One screw test is performed to verify the passivity of the framework. The distal-most screw is tightened completely first and a radiograph of the contralateral side is taken to ascertain that the framework is completely seated on the abutments on that side. A misfit indicates that the cast is inaccurate. In this instance, a new impression must be made and all the steps must be repeated from the impression making step. Hence, the cast verification step is critical to the success of the definitive prosthesis.

The maxillary framework, maxillary cast with locator attachment assembly, wax trial dentures, and mandibular cast with milled titanium framework are sent to the laboratory for processing the maxillary implant-supported

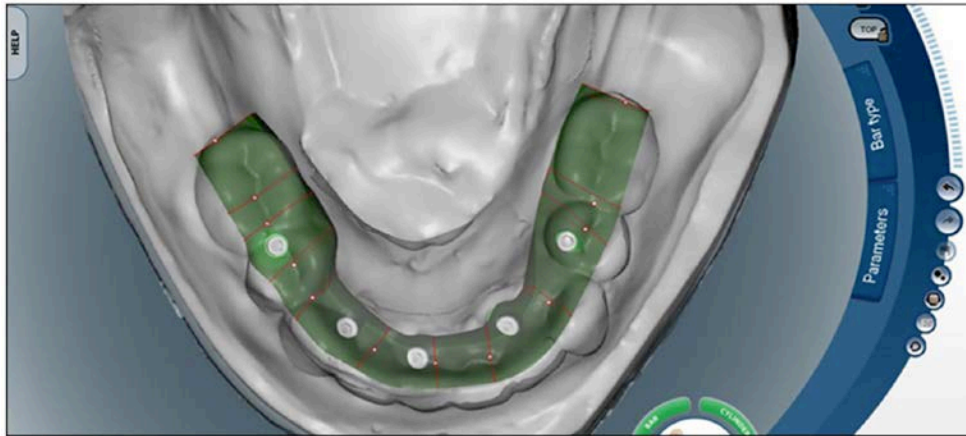


Figure 14. The framework extends posteriorly to the posterior-most teeth.

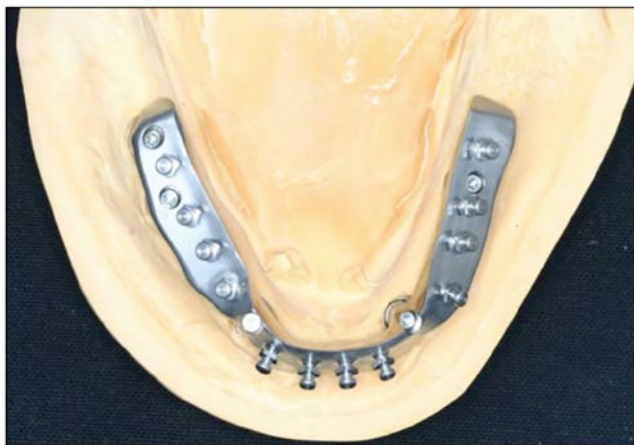

Figure 15. Milled mandibular framework.

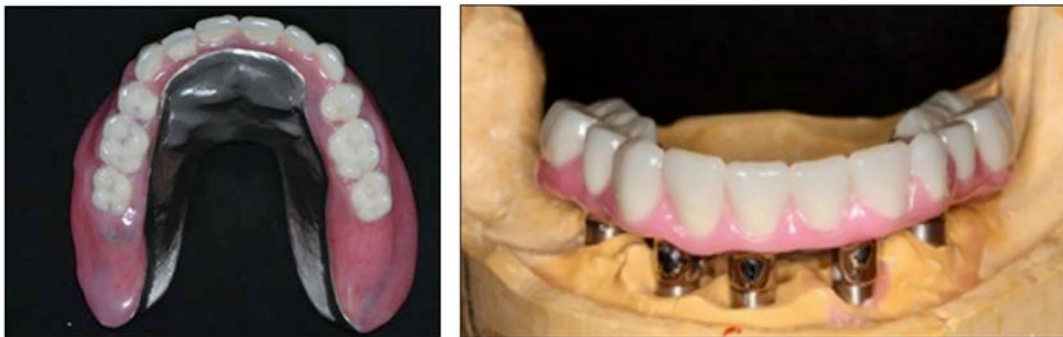

Figure 16. Definitive Prostheses.

overdenture and fabricating the fixed screw-retained mandibular complete denture (Figure 16). If another wax try-in procedure with the frameworks is required, the laboratory should be instructed accordingly. The laboratory should be provided with detailed instructions for prostheses fabrication.

Sixth Clinical Appointment

Placement of the Maxillary Implant Supported Overdenture

Healing abutments are removed and the locator abutments (retrieved from the laboratory) are attached to the implants,

verified radiographically, and torqued as per the manufacturer's recommendations. The maxillary implant-supported overdenture is adjusted as needed, finished, polished, and placed in the patient's mouth. The black processing elements are changed to pink, grey, or blue retentive elements depending on the amount of retention desired.

Placement of the Mandibular "All-on-5" Prosthesis

The healing caps are removed and the mandibular restoration is tried, adjusted, finished, and polished. The occlusion (bilateral balanced) is verified. The screws of the mandibular restoration are tightened and torqued as per the manufacturer's recommended torque values. The screw axis holes are packed with Teflon tape and composite resin.

The patient is educated and instructed regarding the hygiene procedures and

scheduled for routine maintenance recalls. The patient should be provided with all the cleaning aids to help maintain their oral hygiene.^{46,47}

Summary

There are several techniques for fabricating implant-supported restorations. However, having implant level (or multi-unit abutment level) verified casts enable the fabrication of all types of removable and fixed prostheses. Following the wax try-in procedure, the laboratory can be informed regarding the type of the prosthesis and the desired type can be fabricated.

Also, most of the procedures are similar for fixed and removable prostheses except the last few steps. The procedures described in this course will guide the fabrication of various types of removable (supported by studs or bar attachments) and fixed restorations (metal acrylic, metal ceramic, all-ceramic, and/or zirconia).

Course Test Preview

To receive Continuing Education credit for this course, you must complete the online test. Please go to: www.dentalcare.com/en-us/professional-education/ce-courses/ce618/test

- 1. The verification index should be tested in the mouth with one screw test. The verification index is said to be passive when any one of the impression coping is completely seated on the implant/abutment platform.**
 - A. Both statements are true.
 - B. Both statements are false.
 - C. The first statement is true. The second statement is false.
 - D. The first statement is false. The second statement is true.
- 2. Which implant prosthetic components are required to make an implant level cast?**
 - A. Impression copings and implant analogs
 - B. Multi-unit abutments and analogs
 - C. Impression copings, multi-unit abutment, and implant analogs
 - D. Impression copings, implant analogs, multi-unit abutment, and analogs
- 3. What is the best method for determining the height of the locator attachments?**
 - A. Determining the width of the implant platform
 - B. Measuring the height of the mucosal cuff
 - C. Measuring the height of the impression copings
 - D. Measuring the mouth opening
- 4. Multi-unit angle correction abutment decreases the amount of vertical restorative space required for a prosthesis. It also helps correct the angulation of implants.**
 - A. Both the statements are true.
 - B. Both the statements are false.
 - C. The first statement is true. The second statement is false.
 - D. The first statement is false. The second statement is true.
- 5. What is the objective of fabrication of the impression index?**
 - A. Cast verification
 - B. Splinting of the impression copings
 - C. Ease of impression making
 - D. Both A and B
- 6. The impression copings used to fabricate a verification index should be:**
 - A. Engaging
 - B. Non-engaging
 - C. Hexed
 - D. Both A and B
- 7. What is the purpose of making external impressions?**
 - A. To acquire intricate details of the intaglio surface.
 - B. To improve the retention of the prosthesis.
 - C. To develop proper contours of the polished surface.
 - D. To develop both the intaglio and the polished surface.

- 8. All of the following are advantages of milled framework EXCEPT one. Which one is this exception?**
- A. Ability to use biocompatible and/or esthetic materials
 - B. Cost
 - C. Durability
 - D. Passivity
- 9. All of the following are true for the CAD-CAM framework EXCEPT one. Which one is this exception?**
- A. It should passively seat on all the implants.
 - B. There should be adequate distance between the framework and the tissue.
 - C. It should extend posteriorly up to the distal-most prosthetic teeth.
 - D. It should be within the confines of the prosthetic teeth in all 3 dimensions.
 - E. It should actively seat on all the implants.
- 10. What does the misfit of the milled bar in the oral cavity indicate?**
- A. The cast is inaccurate.
 - B. The framework does not fit the cast.
 - C. Poor design of the framework.
 - D. Inaccurate jaw relationship records.

References

1. Vogel R, Smith-Palmer J, Valentine W. Evaluating the health economic implications and cost-effectiveness of dental implants: a literature review. *Int J Oral Maxillofac Implants*. 2013 Mar-Apr;28(2):343-56. doi: 10.11607/jomi.2921.
2. Beikler T, Flemmig TF. EAO consensus conference: economic evaluation of implant-supported prostheses. *Clin Oral Implants Res*. 2015 Sep;26 Suppl 11:57-63. doi: 10.1111/clr.12630. Epub 2015 Jun 15.
3. Sadowsky SJ. The implant-supported prosthesis for the edentulous arch: design considerations. *J Prosthet Dent*. 1997 Jul;78(1):28-33. doi: 10.1016/s0022-3913(97)70084-2.
4. Misch CE. *Dental implant prosthetics*, 2nd ed. St. Louis, MO: Elsevier Mosby; 2015.
5. Adell R, Eriksson B, Lekholm U, Brånemark PI, Jemt T. Long-term follow-up study of osseointegrated implants in the treatment of totally edentulous jaws. *Int J Oral Maxillofac Implants*. 1990 Winter;5(4):347-59.
6. Adell R, Lekholm U, Rockler B, Brånemark PI. A 15-year study of osseointegrated implants in the treatment of the edentulous jaw. *Int J Oral Surg*. 1981 Dec;10(6):387-416. doi: 10.1016/s0300-9785(81)80077-4.
7. Jemt T. Fixed implant-supported prostheses in the edentulous maxilla. A five-year follow-up report. *Clin Oral Implants Res*. 1994 Sep;5(3):142-7. doi: 10.1034/j.1600-0501.1994.050304.x.
8. Schwartz-Arad D, Chaushu G. Full-arch restoration of the jaw with fixed ceramometal prosthesis. *Int J Oral Maxillofac Implants*. 1998 Nov-Dec;13(6):819-25.
9. Jennings KJ, Lilly P. Bar-retained overdentures for implants--technical aspects. *J Prosthet Dent*. 1992 Aug;68(2):380-4. doi: 10.1016/0022-3913(92)90351-a.
10. Engquist B, Bergendal T, Kallus T, Linden U. A retrospective multicenter evaluation of osseointegrated implants supporting overdentures. *Int J Oral Maxillofac Implants*. 1988 Summer;3(2):129-34.
11. Glantz PO, Nilner K. Biomechanical aspects on overdenture treatment. *J Dent*. 1997 Jan;25 Suppl 1:S21-4. doi: 10.1016/s0300-5712(97)87696-8.
12. Hooghe M, Naert I. Implant supported overdentures--the Leuven experience. *J Dent*. 1997 Jan;25 Suppl 1:S25-32. doi: 10.1016/s0300-5712(97)87697-x.
13. Naert I, De Clercq M, Theuniers G, Schepers E. Overdentures supported by osseointegrated fixtures for the edentulous mandible: a 2.5-year report. *Int J Oral Maxillofac Implants*. 1988 Fall;3(3):191-6.
14. Spiekermann H, Jansen VK, Richter EJ. A 10-year follow-up study of IMZ and TPS implants in the edentulous mandible using bar-retained overdentures. *Int J Oral Maxillofac Implants*. 1995 Mar-Apr;10(2):231-43.
15. Attard N, Wei X, Laporte A, Zarb GA, Ungar WJ. A cost minimization analysis of implant treatment in mandibular edentulous patients. *Int J Prosthodont*. 2003 May-Jun;16(3):271-6.
16. Massad JJ, Ahuja S, Cagna D. Implant overdentures: selections for attachment systems. *Dent Today*. 2013 Feb;32(2):128, 130-2.
17. Lian M, Zhao K, Wang F, Huang W, Zhang X, Wu Y. Stud vs Bar Attachments for Maxillary Four-Implant-Supported Overdentures: 3- to 9-year Results from a Retrospective Study. *Int J Oral Maxillofac Implants*. 2019 July/August;34(4):936-946. doi: 10.11607/jomi.7224. Epub 2019 Apr 1.
18. Ouzer A. The Evolution and Fabrication of Implant-supported Full-arch Hybrid Prostheses. From Conventional Casted Metal to an All-Ceramic Zirconia. *N Y State Dent J*. 2015 Nov;81(6):44-9.
19. Pozzi A, Gargari M, Barlattani A. CAD/CAM technologies in the surgical and prosthetic treatment of the edentulous patient with biomymetic individualized approach. *Oral Implantol (Rome)*. 2008 Apr;1(1):2-14. Epub 2008 Jun 16.
20. Patzelt SB, Spies BC, Kohal RJ. CAD/CAM-fabricated implant-supported restorations: a systematic review. *Clin Oral Implants Res*. 2015 Sep;26 Suppl 11:77-85. doi: 10.1111/clr.12633. Epub 2015 Jun 7.
21. Farawati FA. Digital Fabrication of Dental Implant Prostheses. *Decisions in Dentistry*. 2018 Sep 11;4(9):22-25. Accessed March 11, 2021.

22. Karl M, Taylor TD. Parameters determining micromotion at the implant-abutment interface. *Int J Oral Maxillofac Implants*. 2014 Nov-Dec;29(6):1338-47. doi: 10.11607/jomi.3762.
23. Elshenawy EA, Alam-Eldein AM, Abd Elfatah FA. Cast accuracy obtained from different impression techniques at different implant angulations (in vitro study). *Int J Implant Dent*. 2018 Mar 20;4(1):9. doi: 10.1186/s40729-018-0118-6.
24. Abduo J. Fit of CAD/CAM implant frameworks: a comprehensive review. *J Oral Implantol*. 2014 Dec;40(6):758-66. doi: 10.1563/AAID-JOI-D-12-00117.
25. Michalakis KX, Hirayama H, Garefis PD. Cement-retained versus screw-retained implant restorations: a critical review. *Int J Oral Maxillofac Implants*. 2003 Sep-Oct;18(5):719-28.
26. Rutkunas V, Ignatovic J. A technique to splint and verify the accuracy of implant impression copings with light-polymerizing acrylic resin. *J Prosthet Dent*. 2014 Mar;111(3):254-6. doi: 10.1016/j.prosdent.2013.08.015. Epub 2014 Jan 17.
27. Wee AG, Aquilino SA, Schneider RL. Strategies to achieve fit in implant prosthodontics: a review of the literature. *Int J Prosthodont*. 1999 Mar-Apr;12(2):167-78.
28. Kan JY, Rungcharassaeng K, Bohsali K, Goodacre CJ, Lang BR. Clinical methods for evaluating implant framework fit. *J Prosthet Dent*. 1999 Jan;81(1):7-13. doi: 10.1016/s0022-3913(99)70229-5.
29. Romero GG, Engelmeier R, Powers JM, Canterbury AA. Accuracy of three corrective techniques for implant bar fabrication. *J Prosthet Dent*. 2000 Dec;84(6):602-7. doi: 10.1067/mpr.2000.111494.
30. Knudson RC, Williams EO, Kemple KP. Implant transfer coping verification jig. *J Prosthet Dent*. 1989 May;61(5):601-2. doi: 10.1016/0022-3913(89)90284-9.
31. Papazian S, Morgano SM. Four uses of a disposable implant mount. *J Prosthet Dent*. 1998 Feb;79(2):222-5. doi: 10.1016/s0022-3913(98)70220-3.
32. Papazian S, Morgano SM. Use of aluminum strips to fabricate verification jig for an implant-supported fixed partial denture. *J Prosthet Dent*. 1998 Mar;79(3):350-2. doi: 10.1016/s0022-3913(98)70250-1.
33. Frush JP, Fisher RD. How dentogenic restorations interpret the sex factor. *J Prosthet Dent* 1956 Mar 01;6(2):160-72. doi: 10.1016/0022-3913(56)90110-X. Accessed March 11, 2021.
34. Frush JP, Fisher RD. How dentogenics interprets the personality factor. *J Prosthet Dent*. 1956 Jul 01;6(4):441-49. doi: 10.1016/0022-3913(56)90089-0. Accessed March 11, 2021.
35. Frush JP, Fisher RD. The age factor in dentogenics. *J Prosthet Dent*. 1957 Jan 01;7(1):5-8. doi: 10.1016/0022-3913(57)90004-5. Accessed March 11, 2021.
36. Frush JP. *Dynesthetics Illustrated*. The Swissdent Foundation. 1958.
37. Frush JP, Fisher RD. The dynesthetic interpretation of the dentogenic concept. *J Prosthet Dent*. 1958 Jul 01;8(4):558-81. doi: 10.1016/0022-3913(58)90043-X. Accessed March 11, 2021.
38. Frush JP, Fisher RD. Dentogenics: Its practical application. *J Prosthet Dent*. 1959 Nov 01;9(6):914-21. doi: 10.1016/0022-3913(59)90149-0. Accessed March 11, 2021.
39. Cagna DR, Massad JJ, Schiesser FJ. The neutral zone revisited: from historical concepts to modern application. *J Prosthet Dent*. 2009 Jun;101(6):405-12. doi: 10.1016/S0022-3913(09)60087-1.
40. Massad JJ. Commentary. Creating natural-looking removable prostheses: combining art and science to imitate nature. *J Esthet Restor Dent*. 2012 Jun;24(3):169-70. doi: 10.1111/j.1708-8240.2011.00494.x. Epub 2011 Nov 15.
41. Massad JJ, Ahuja S, Verma M. Treating a failing dentition: stable implant-supported removable restorations. *Dent Today*. 2014 Jan;33(1):134, 136-9.
42. Ahuja S, Cagna DR. Defining available restorative space for implant overdentures. *J Prosthet Dent*. 2010 Aug;104(2):133-6. doi: 10.1016/S0022-3913(10)60107-2.
43. Ahuja S, Cagna DR. Classification and management of restorative space in edentulous implant overdenture patients. *J Prosthet Dent*. 2011 May;105(5):332-7. doi: 10.1016/S0022-3913(11)60064-4.
44. Rodrigues AH. Metal reinforcement for implant-supported mandibular overdentures. *J Prosthet Dent*. 2000 May;83(5):511-3. doi: 10.1016/s0022-3913(00)70006-0.
45. Jameson WS. Fabrication and use of a metal reinforcing frame in a fracture-prone mandibular complete denture. *J Prosthet Dent*. 2000 Apr;83(4):476-9. doi: 10.1016/s0022-3913(00)70045-x.

46. Cagna DR, Massad JJ, Daher T. Use of a powered toothbrush for hygiene of edentulous implant-supported prostheses. *Compend Contin Educ Dent*. 2011 May;32(4):84-8.
47. Massad J, Verma M, Ahuja SA. Improving implant survival by implementing the use of an electric toothbrush. *Dent Today*. 2019 Oct 01;38:68-7. Accessed March 11, 2021.

Additional Resources

- No Additional Resources Available.

About the Author

Swati Ahuja, BDS, MDS



Dr. Ahuja graduated with a BDS from Nair Hospital Dental College in 2002 and an MDS certificate in Prosthodontics from the University of Tennessee Health Science Center, Memphis, TN. She then joined the same University as an Assistant Professor in the Department of Prosthodontics where she worked for 3 and half years. She served as the editor for the Department of Prosthodontics at University of Tennessee Health Science Center, Memphis, TN for the next 6 years. She has lectured nationally and internationally on various prosthodontic topics at various dental conferences. She has more than 55 publications in peer reviewed national and international journals. Dr. Ahuja is also the co-author of the textbook titled, "Applications of the Neutral Zone in Prosthodontics." Currently, she has a private practice in Mumbai.

Email: swatiahuja@gmail.com