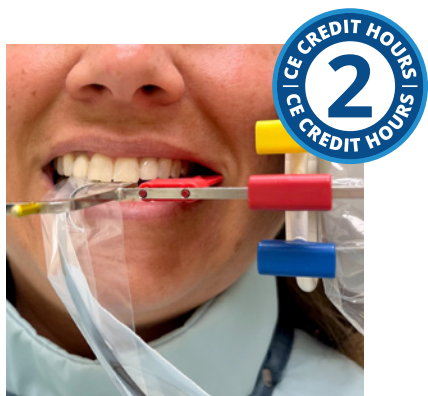

## Intraoral Imaging Techniques: Beyond the Textbook



**Course Author(s):** Debra A. Dixon, DMD, MSc

**CE Credits:** 2 hours

**Intended Audience:** Dentists, Dental Hygienists, Dental Assistants, Dental Students, Dental Hygiene Students, Dental Assistant Students

**Date Course Online:** October 6, 2022

**Last Revision Date:** October 3, 2025

**Course Expiration Date:** October 2, 2028

**Cost:** Free

**Method:** Self-instructional

**AGD Subject Code(s):** 731

**Online Course:** [www.dentalcare.com/en-us/ce-courses/ce660](http://www.dentalcare.com/en-us/ce-courses/ce660)

**Disclaimer:** Participants must always be aware of the hazards of using limited knowledge in integrating new techniques or procedures into their practice. Only sound evidence-based dentistry should be used in patient therapy.

### Conflict of Interest Disclosure Statement

- Dr. Dixon reports no conflicts of interest associated with this course. She has no relevant financial relationships to disclose.

### Short Description

This course will briefly review the basics of intraoral imaging, but most importantly will go beyond those basics by highlighting common difficulties with sensors and providing solutions to help the dental professional produce high-quality diagnostic images.

## Course Contents

- Overview
- Learning Objectives
- Introduction
- Variables of Intraoral Imaging
- The Path of Radiation
- The Digital Sensor
- The Intraoral Examination
- The Basics of Intraoral Imaging: Horizontal and Vertical Angulation
  - o Horizontal Angulation: What is it? How do I find it?
  - o Horizontal Angulation: I am using a rod and ring aiming system. How do I know if I can follow the aiming ring?
  - o Horizontal Angulation: How do I know that the distal canine crown will appear on the premolar periapical image?
  - o Vertical Angulation: How do I know if I can follow the aiming ring?
  - o Vertical Angulation: Why are the mandibular anterior teeth always foreshortened on periapical images?
  - o Vertical Angulation: Why are the incisal edges/cusp tips not captured on the anterior & posterior periapical images?
- Common Problems & Solutions
  - o Problem #1: Small mouth/limited opening
  - o Problem #2: Difficulty Positioning Sensor for Mandibular Molar Periapical
  - o Problem #3: Fail to Capture Distal of Canine on Premolar Bitewing Image
  - o Problem #4: Bitewing Images Not Ideal
  - o Problem #5: Comparison of periapical images versus bitewing images
  - o Problem #6: Not Imaging the Entire Tooth
  - o Problem #7: Images for Implant Procedures
  - o Problem #8: Difficulty Capturing 2nd and 3rd Molars on Periapical Images
  - o Problem #9: Capturing the Mesial and Distal of a Canine
  - o Problem #10: Capturing the Apex during an Endodontic Procedure
- Summary
- Course Test
- References
- About the Author

## Overview

The purpose of this course is to provide practical 'hands-on' information to students and clinicians for successful intraoral imaging with digital

sensors. In addition, this course will briefly review the basics of intraoral imaging, but most importantly will go beyond those basics by highlighting common difficulties with sensors and providing solutions to help the dental professional produce high-quality diagnostic images. Numerous photographs and radiographic images are embedded in the text to enhance the mastery of the material.

There are numerous textbooks that thoroughly teach intraoral technique. It is anticipated that the learner will have a working knowledge as they begin this course, which will include basic imaging in discussions of modifications of techniques. The clinician will learn to assess the instrument system setup **before** pressing the exposure button with a critical evaluation of the horizontal and vertical angulations as dictated by the rod-and-ring alignment system used. There are multiple textbook resources available for intraoral technique instruction.<sup>1,2</sup> There are also many short videos available on electronic media, but 'buyer beware', as all videos are not accurate or complete.

## Learning Objectives

**Upon completion of this course, the dental professional should be able to:**

- Learn a method to determine the active area on a digital sensor.
- Understand what variables are involved when imaging, and their effects.
- Understand and assess proper vertical and horizontal angulation of the x-ray beam, by critiquing the aiming rod and ring's position prior to exposure.
- Understand when modifications of the sensor's position in the mouth and PID position are necessary to create diagnostic images and learn to apply these modifications.
- Understand the effects of altering sensor position and x-ray beam position.
- Understand intraoral techniques for implant procedures.

## Introduction

Intraoral radiography is integral to nearly every dental procedure. The dentist is at a disadvantage without diagnostic images when treatment planning and providing treatment. It

is critical that the dental professional acquiring the images be knowledgeable of proper technique and radiographic anatomy, available in **Intraoral Radiographic Anatomy CE 601**. The prescription of images is the responsibility of the dentist, whereas the acquisition of images is primarily the responsibility of the dental auxiliary. An overview of digital imaging and the latest advances in digital technology is available in **Digital Imaging in Dentistry: Intraoral, Extraoral, and 3D Technology CE 512**.

Each radiographic examination is unique, because every patient is unique: the size of the jaws, the number and position of teeth present, the presence or absence of palatal and/or mandibular tori, the morphology of the anterior lingual mandible (bone is upright or flares out creating a shelf), and, of course, the patient's level of cooperation and ability to hold the sensor in proper position. When teeth are 'out of alignment' (mal-positioned) and overlapped, the interproximal contacts cannot be 'opened'. It can be very difficult to image the apex of a very long rooted tooth, and some patients find the procedure uncomfortable.

There are two techniques associated with intraoral periapical imaging: the Paralleling Technique and the Bisected Angle Technique. The Bisected Angle Technique was introduced in 1904 and is based on the geometry of equilateral triangles. The operator must identify the long axis of the teeth and the long axis of the receptor (sensor or film) and place the x-ray beam at a right angle to an imaginary line that bisects those two planes. Charts with suggested vertical angulations are available in most dental imaging textbooks (Table 1 is representative). These vertical angulations are important to remember when exposing intraoral image receptors, even when using aiming instruments.

The Paralleling Technique was introduced in 1920 and is based on paralleling the receptor (sensor or film) to the long axis of the teeth and placing the x-ray beam at right angles to those paralleled lines. Paralleling is also known as the Right-Angle Technique and the Long-Cone Technique.

## Variables of Intraoral Imaging

There are four variables involved in acquiring radiographic images: horizontal angulation, vertical angulation, sensor placement, and head position. When aiming instruments are used, the horizontal and vertical angulations are shown by the position of the aiming ring, but as we will learn, the aiming ring is not always in the ideal position. When using simple sensor holders, such as sticky tabs, without an aiming device, the operator must understand how to manage the four variables.

**Horizontal angulation** is responsible for 'opening' interproximal contacts and embrasures, both of which are critical for caries diagnosis and periodontal bone assessment. The horizontal angulation of the PID (position indicating device, see figure 1) is ultimately determined by the position of the teeth. Changing the horizontal angulation can capture the distal of a forward canine or a posterior molar and can separate multiple endodontic files and master cones.

**Vertical angulation** is responsible for capturing the entire tooth and root and surrounding bone. Creating an image that is equal or nearly equal to the actual length of the tooth is critical for periapical diagnosis and endodontic procedures. Elongation and foreshortening are distortions that result from insufficient and excessive vertical angulation, respectively. When acquiring bitewings, vertical angulation is responsible for capturing maxillary and mandibular alveolar crest levels. When the patient has periodontal bone loss, a vertical bitewing holder increases the chances of capturing alveolar crest bone levels on the image, as the length of the sensor is positioned 'up and down', as opposed to the normal horizontal position.

**Sensor placement:** The operator may have little ability to change the sensor's position in the mouth because intraoral anatomy and the amount of room available in the oral cavity dictate where the sensor will rest. When the arch is larger and there is extra room in the mouth, the operator has some flexibility when placing the sensor. When the mouth is small, the sensor can only position where there is room; the sensor and aiming ring's placement

**Table 1. Suggested Vertical Angulations for Periapical Images.  
Occlusal Plane Parallel To The Floor**

	Incisors	Canines	Premolars	Molars
Maxillary	+40 degrees	+45 degrees	+30 degrees	+20 degrees
Mandibular	-15 degrees	-20 degrees	-10 degrees	-5 degrees
Bitewings	+5 degrees			

for the teeth of interest may be compromised. Blindly following an out-of-position aiming ring will create poor images.

**Head position** should be managed by the operator, even when using aiming instruments. The operator's perspective is better when the patient's skeletal midline is straight, perpendicular to the floor, and the occlusal plane is parallel with the floor. Placing the PID requires determination of the horizontal and vertical angulations needed for the particular area and the purpose of the intended image. It is much easier to assess the position of the teeth in the jaws and to place the sensor parallel with the teeth when the occlusal plane is at 0 degrees (parallel with the floor), as in Figure 4.

### The Path of Radiation

**The Path of Radiation** must include the area of interest (teeth and surrounding bone) and active sensor (Figure 1). As an example, if you expect to capture the distal half of a canine crown on a bitewing image, the canine must

be covered with radiation and there must be active sensor in the path of radiation as shown by the PID's position. The operator is responsible for putting all the pieces together to create diagnostic images. Here's an analogy to make it easier to understand...the baseball glove has to be in the exact position to catch the baseball or the ball will land on the ground!

There are consequences when the path of radiation does not contain the teeth and the full sensor: if the sensor and the required teeth are not in the radiation's path, they will not appear on the image (Figure 2A) and if the path of radiation does not cover the entire sensor, a cone-cut (an area of non-exposure) will result (Figure 2B)

### The Digital Sensor

Before we get started with the patient, let's look at the digital sensor. Figure 3 shows a penny placed on the active side of a sensor, and the resultant image after the PID was positioned directly over the sensor and an exposure was made. The image shows a dead zone, i.e., we

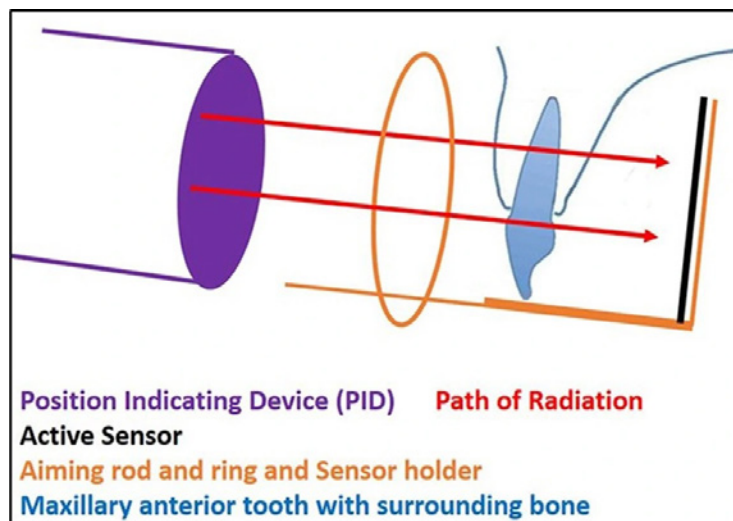
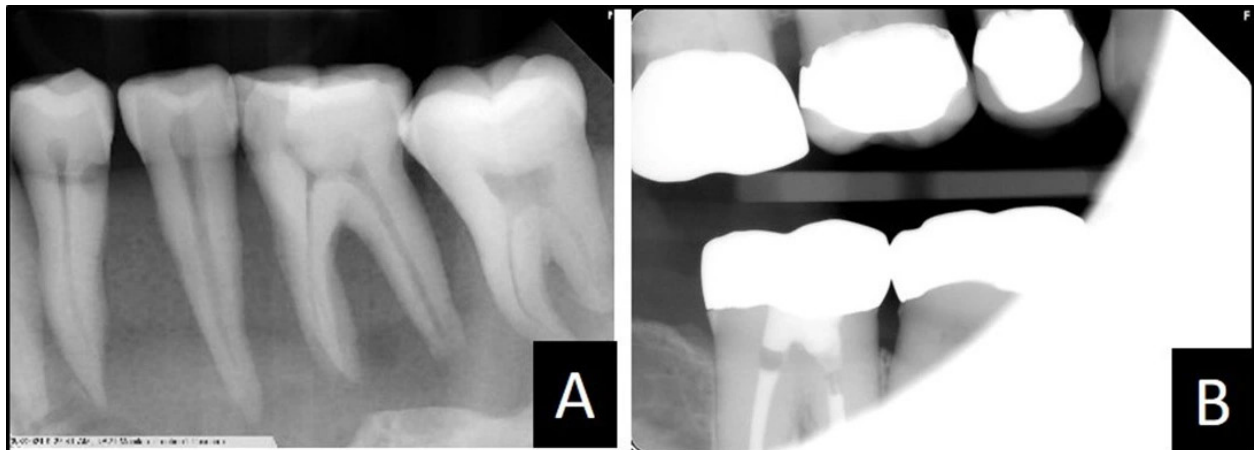



Figure 1 - The Path Of Radiation.



**Figure 2**  
(A) Active sensor was not behind the canine. (B) Sensor not fully covered by radiation resulted in a cone-cut.



**Figure 3 - Digital Sensor**  
(A) Penny placed on active side of sensor. (B) Resultant image shows deadzone with this particular sensor.

can only see a portion of the penny's image. Where the penny superimposed the black strip, no image exists. The active zone on this particular sensor is within the thin black line; the outer edge of the entire sensor is a dead zone. You can do this simple exercise with your own sensors. By first determining the needed horizontal angulation, you will be successful with your placement of the sensor's active zone.

### The Intraoral Examination

Patient shielding during dentomaxillofacial radiography. Recommendations from an American Academy of Oral and Maxillofacial Radiology (AAOMR) ad hoc committee were published in JADA 2023. The ad hoc committee considered the risks from thyroid cancer negligible and recommended that thyroid shielding not be used during intraoral, panoramic, cephalometric, and cone-beam computed tomographic (cbct) imaging.<sup>3</sup> An expert panel established by the ADA Council on Scientific Affairs published recommendations in February 2024, that aligned with those from the AAOMR. "Patient thyroid shielding during diagnostic intraoral, panoramic, cephalometric, and CBCT imaging no longer should be used in routine practice for pediatric or adult patients. As necessary, federal, state, and local regulations and guidance should be revised to remove any actual or implied requirement for routine protective shielding for intraoral, panoramic, cephalometric, and CBCT imaging."<sup>4</sup> These recommendations apply to all patients, regardless of age or health status (like pregnancy). The April 2024 JADA article serves as the source for Radiation Safety Recommendations, and a thorough review is highly recommended by this author. As always, be sure to comply with your state mandated requirements. If a patient asks for the apron, there's no harm in using it, as long as the radiation path is not impeded. To summarize, the ADA supports the recommendation that protective aprons of any kind (thyroid or chest) are no longer recommended for any dental imaging (intraoral, panoramic, cephalometric, or cbct).

Seat the patient upright in the dental chair, making sure they are comfortable. Always support the patient's head against the headrest;

this is easier for the patient and the operator. The operator should assess the mouth by performing a brief intraoral examination. Feel the anterior lingual mandible and assess its morphology; is the bone upright or is it sloped? If the bone is sloped, the operator will need to position the sensor posteriorly to avoid the bone and the sensitive soft tissues covering the bone. Feel for palatal and mandibular tori. If large mandibular tori are present, place the sensor posterior to avoid the thin, sensitive tissues covering the tori. If the tori are small, try to position the sensor between them and as far forward as possible to successfully image the premolars. Note the position of the teeth, especially the canines. If the canines are extremely forward in the jaw, there may not be a way to image the distal canine crown. If there is extreme malposition and crowding, there may not be a path to open the compromised contacts. Marginal ridges that parallel and create a clean separation between crowns allow the radiation path to parallel and 'open' the contact. When a tooth is out of alignment, i.e., one is buccal and one is lingual, the marginal ridges often overlap, thereby eliminating the separation of crowns and the possibility of open contacts. Knowing what is achievable before beginning the radiographic examination will lessen the operators stress.

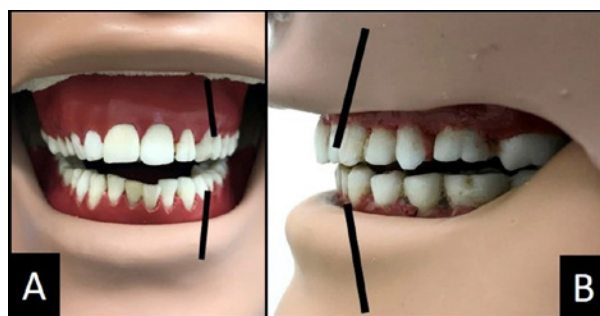
Start with the easiest images first to gain rapport with the patient. The patient is more likely to tolerate an uncomfortable position of a sensor when they know you care about their comfort and are being as efficient as possible. Ask the patient to smile as you position the sensor, **do not allow the lips to close around the holder at any point during the setup process.** Seeing the teeth and the interproximal contacts as you position the sensor and ultimately the PID is critical. When the sensor is uncomfortable, the patient wants to open and relieve the pressure. Keep the patient smiling, and reposition the sensor away from the sensitive tissues. Make sure the patient is biting down fully. **The sensor holder's bitepiece must be in contact with the teeth at all times during setup and exposure.** If the patient does not bite down all the way and hold the sensor in place, the apices may not appear on periapical images,



and bitewings may not capture bone levels. Rod and ring aiming instruments move together, but the ends move in opposite directions from each other. The tooth is the pivot point, and the sensor holder and the aiming ring move about that point. An easy analogy is the teeter-totter...when one person is in the air, the other is on the ground. Whether the PID is up or down, following the ring will cover the sensor with radiation. The complexities become apparent when we actually get in the mouth and find that the maxillary palate is shallow, or that large mandibular tori are present that compromise the sensor's position.

Bitewings are the preferred image type when diagnosing caries and periodontal bone loss. The addition of vertical angulation to the periapical technique, whether paralleling or bisecting, tends to superimpose anatomical structures over the teeth. The margins of restorations and crowns superimpose with the crestal bone on the image and the ability to diagnose caries at those margins on periapical views is impossible. Paralleled periapical views tend to superimpose fewer structures than bisected periapical views. Vertical angulation is necessary to image apices and surrounding bone. Excessive vertical angulation should be avoided, except in the case of exceptionally long roots where the apex needs to be recorded.

Whether using the Paralleling Technique with rod and ring aiming instruments, or the Bisected Angle Technique with appropriate sensor holders, the operator will assess horizontal and vertical angulations throughout the procedure. Knowing how the teeth are positioned in the jaw is critical. In Figure 4, the black lines represent the long axis of the posterior and anterior teeth of this particular teaching mannequin. Assess the position of the teeth in your patient's mouth during the initial examination. The patient should always be positioned upright, with the skeletal midline perpendicular to the floor (head should not be tipped to one side or rotated), and the occlusal plane parallel with the floor of the room. This increases the odds of acquiring images where the radiographic tooth length is as close as possible to the actual tooth length.



**Figure 4**  
(A) Long axis of posterior teeth as viewed from the front.  
(B) Long axis of anterior teeth as viewed from the side, cone-cut.

### The Basics of Intraoral Imaging: Horizontal and Vertical Angulation

As discussed earlier, horizontal and vertical angulations are responsible for the way the teeth appear on the image. The process is a 'balancing act' between covering the area of interest with radiation and having the active sensor in the radiation's path. In this way, we create an image that shows the entire tooth, surrounding bone, and open interproximal contacts. Knowing the anatomy and the position of the teeth in the jaw is critical to producing a technically ideal image. Whether using a rod and ring alignment system or a simple sensor holder, the PID must be placed correctly over the desired area. The following pages (7 through 12) will teach the operator to critically evaluate the aiming ring's position and the position of the sensor in the mouth and to know whether the PID should perfectly align with the aiming ring or not.

### Horizontal Angulation: What is it? How do I find it?

**First, find the teeth you are imaging.** Place your finger along the marginal ridges of the contacts of interest, this is the horizontal angulation needed to 'open' those contacts (Figure 5). Stand in that path as you bring the sensor into the mouth. The operator identifies the correct horizontal angulation / radiation path **before** positioning the active area of the sensor correctly to 'catch' the teeth desired on the image. Remember, tooth position dictates sensor placement and PID placement!

**FIRST: Find the horizontal angulation.**

**SECOND: Place the sensor.**

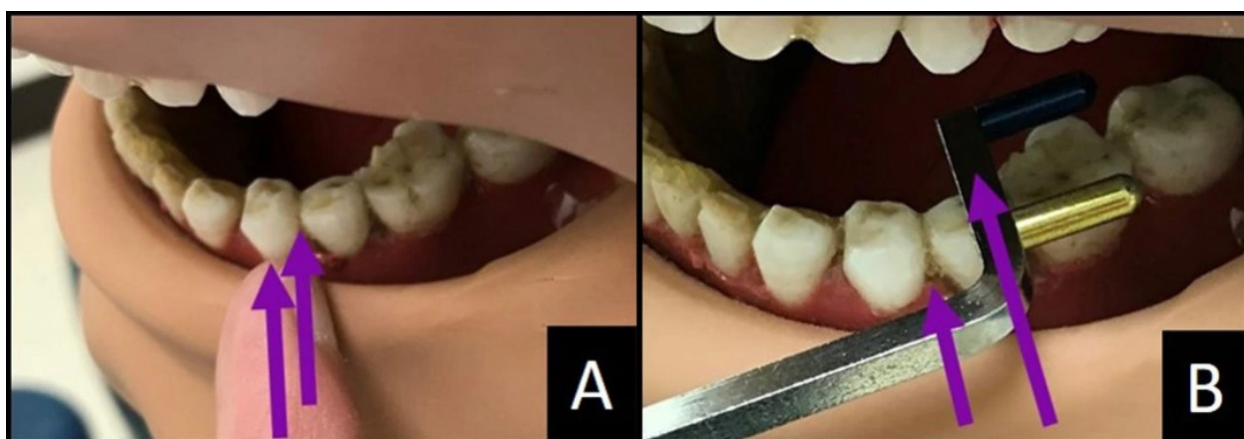
Your mind's eye has to see the path of radiation you are creating (sensor and teeth within the path) to 'catch' the image (just like the baseball). It's only by knowing the horizontal angulation that the operator can place the sensor in the mouth with confidence, knowing that the active sensor will be behind the required teeth and in the radiation path.

For bitewings, follow the marginal ridges of the maxillary teeth. The mandibular contacts usually open too. If the maxillary contacts open but the mandibular do not, the operator may need to expose another image while focusing on the lower contacts only. Depending on the position of the teeth in the jaw, all contacts may open in one image, or as seen in Figure 6C, the mesial and distal contacts of both first

premolars are open, but the molar contacts are not. This indicates that the marginal ridges are not all parallel. In this case, premolar and molar contacts must be opened on separate images.

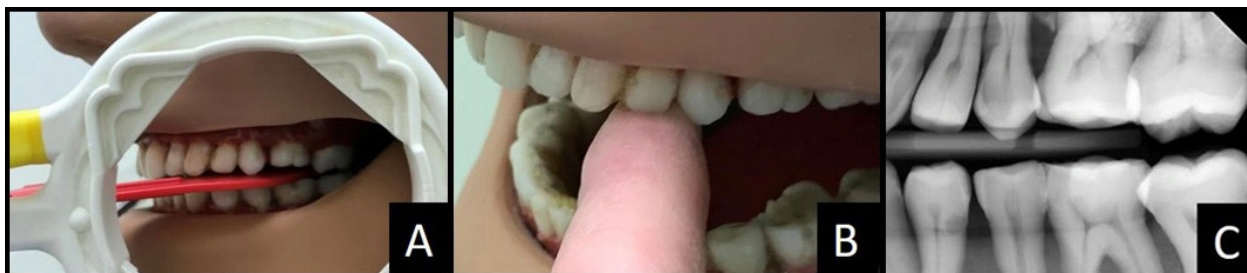
**Horizontal Angulation: I am using a rod and ring aiming system. How do I know if I can follow the aiming ring?**

The operator has identified the position of the marginal ridges and the horizontal angulation. With the sensor holder positioned in the mouth, the operator critiques the position of the sensor, and the aiming rod's position. Is the aiming rod parallel to the marginal ridges? Is there active sensor in this path? **If YES**, the aiming ring can be followed in the horizontal plane. Look at the contacts between teeth whenever setting the horizontal angulation of the PID (Figure 7).



**Figure 5 - Horizontal Angulation**

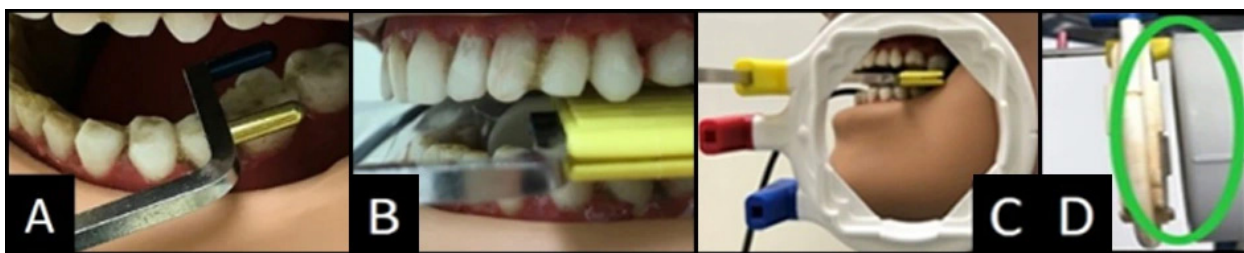(A) Finger is parallel with the marginal ridge between 20-21 and 21-22. (B) Aiming rod is parallel with the same marginal ridges. The aiming ring can be followed.



**Figure 6 - Premolar Bitewing Horizontal**

(A) Looking through the aiming ring at #12, which reflects the parallel finger in (B). (C) Active sensor in the correct horizontal path captured the distal canine crowns, and opened the contacts around the first premolars.





**Figure 7 - Premolar Periapical Horizontal Angulation: Can I follow the aiming ring?**


(A) Confirm aiming rod is parallel with the marginal ridge. (B) Confirm active sensor behind the canine in the radiation's path. (C) Looking through the aiming ring. (D) Confirm the PID's position equal gap with the aiming ring.

If **NO**, try to re-position the sensor holder to find parallel alignment. If parallel alignment is not possible, the aiming ring should not be followed in the horizontal plane. The PID should be positioned independent of the ring and placed parallel with the marginal ridges of the teeth (Figure 8). Make sure active sensor is in the path created.

### Horizontal Angulation: How do I know that the distal canine crown will appear on the premolar periapical image?

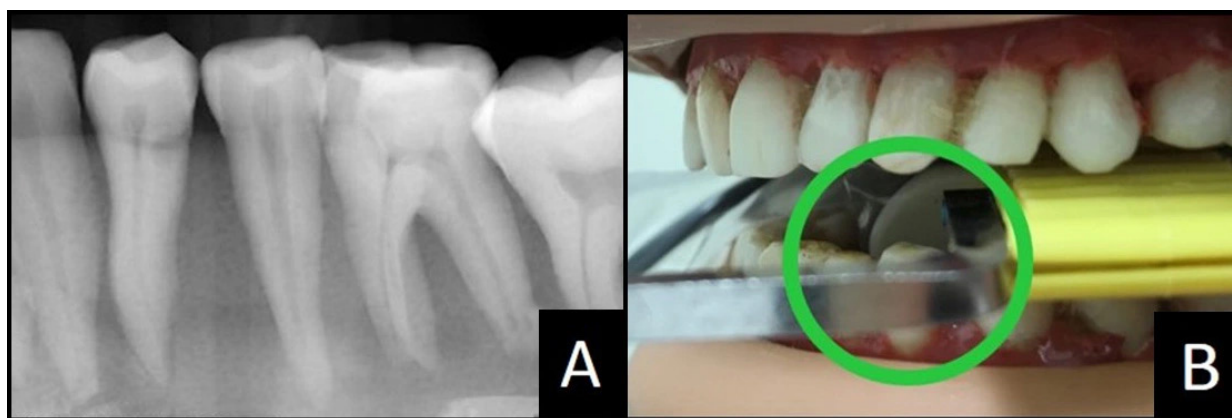
You must identify the correct horizontal angulation, and when standing in that path, make sure the active part of the sensor is physically within the radiation's path. In Figure 9B, the photograph was created when standing in the correct horizontal angulation to capture the distal canine crown and to open the contacts around the first premolar. We can see active sensor positioned behind the canine #22 (within the green circle). The distal half of canine #22 and the premolars appear in the periapical

image. In Figure 10, canine #22 does not appear in the image. Looking through the aiming ring, we see the sensor's dead zone behind the canine. This can be difficult to correct. Keep reading and find solutions in Problem #3.



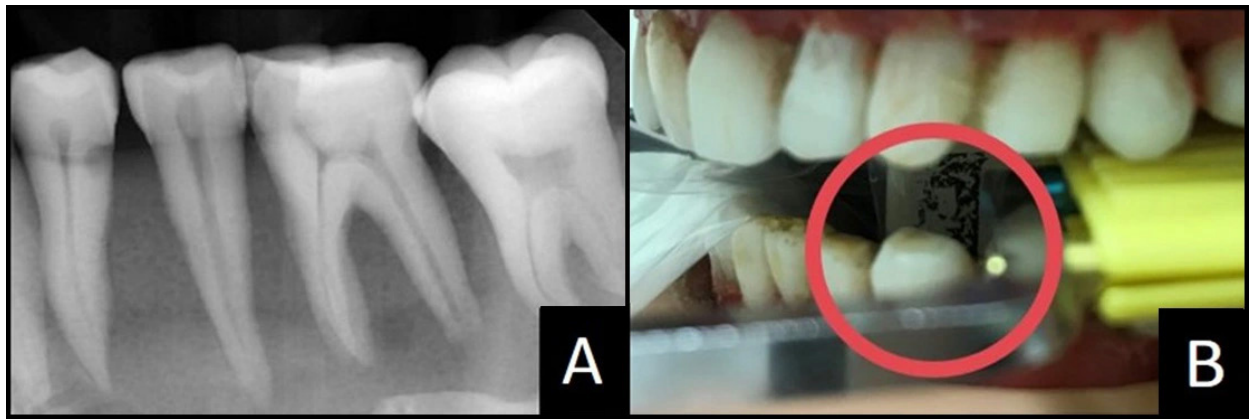
**Figure 8 - Horizontal Angulation**

The PID is following the marginal ridges of the teeth, and is not aligned with the aiming ring.



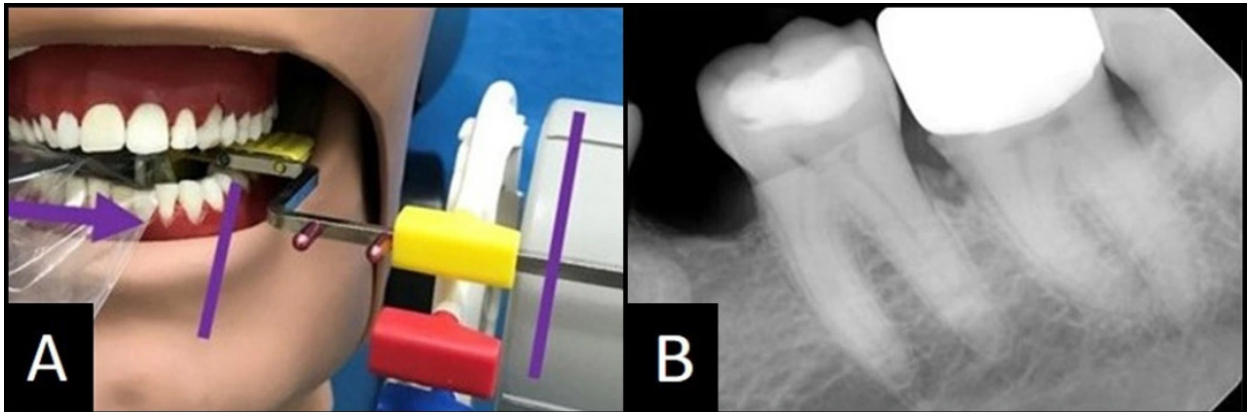
**Figure 9 - Premolar Periapical**

(A) Image with required distal crown #22. (B) Verification of active sensor behind #22 within green circle.



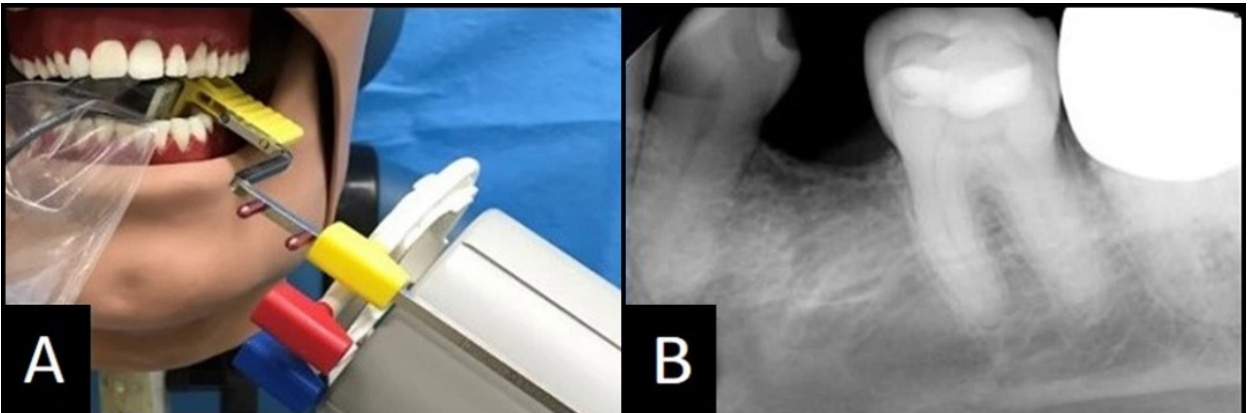
**Figure 10 - Premolar Periapical**

(A) Image without required distal crown #22. (B) Deadzone behind #22 within red circle... tooth will not appear on the image.



**Figure 11 - Mandibular Molar Periapical: Ideal**

(A) Sensor position, long axis of teeth, aiming ring, and PID are parallel. Aiming ring should be followed. (B) Ideal length of molar roots



**Figure 12 - Mandibular Molar Periapical: Foreshortened**

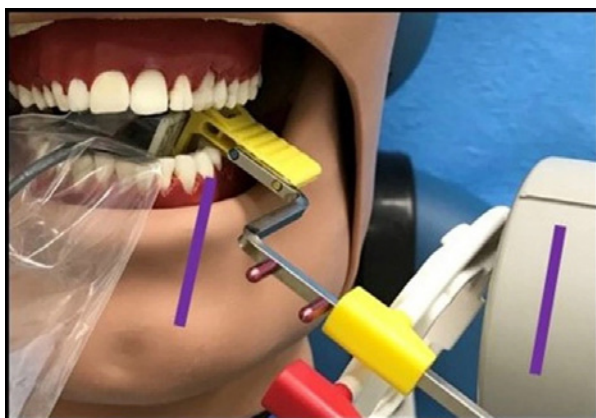(A) Sensor aiming ring, and PID are not paralleling the teeth. The vertical angulation is excessive, as evidenced by the foreshortened roots in (B)

### Vertical Angulation: How do I know if I can follow the aiming ring?

Maxillary teeth require some amount of positive vertical angulation, while mandibular teeth require some amount of negative vertical angulation. Remember, the path of radiation must include the entire tooth and active sensor...or something will be 'cut off' the image. With the patient sitting straight in the chair and the midsagittal plane vertical, level the occlusal plane and identify the position of the roots in the jaw (the long axis of the teeth) as you look directly at the patient (Figure 4). Your goal should always be to position the sensor parallel to the long axis of the teeth. Let's look at maxillary and mandibular teeth in detail.

**Mandibular Posterior Periapical:** Correct positioning is verified when the sensor is parallel with the long axis of the teeth, and when this is achieved, the aiming ring can be followed (Figure 11 shows purple parallel lines of the teeth and the PID). In Figure 12, the sensor is not paralleling the mandibular teeth, the sensor holder is out of position, and the PID's vertical angulation is excessive, as evidenced by the foreshortened molar in the image.

It is better to follow the teeth when positioning the PID, even if the aiming ring and sensor are not paralleling the teeth (Figure 13).



**Figure 13 - Mandibular periapical:** For a non-foreshortened image, the PID should parallel the long axis of the roots (purple lines), even though the sensor and aiming ring are not.

### Vertical Angulation: Why are the mandibular anterior teeth always foreshortened on periapical images?

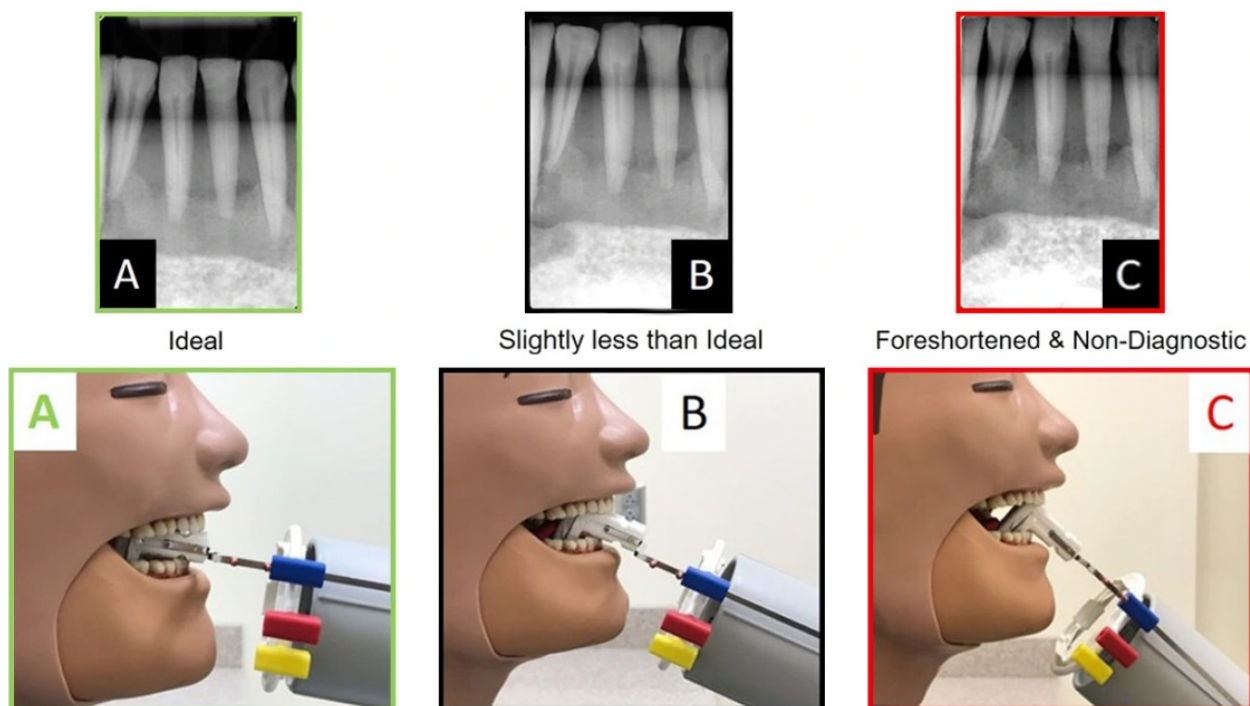
**Mandibular Anterior Periapical:** For an ideal image, place the sensor parallel with the long axis of the teeth, best identified by looking at the patient from the side (Figure 14A). The sensor holder's bitepiece can position against the teeth with varying amounts of vertical angulation. This often happens when the positioning is painful and the patient's tongue pushes the sensor out of the mouth over the teeth. The aiming ring is then pointing towards the floor, and if followed by the PID, will create a severely foreshortened image, with the incisal edges often projected off the edge of the image, because there was no active sensor behind them (Figure 14C).

First, level the occlusal plane. Re-examine the anatomy, looking for mandibular tori or a shelf of bone. Move the sensor posteriorly to find more room in the mouth and avoid those sensitive tissues. If the sensor can parallel the long axis of the teeth, the aiming ring can be followed to create an ideal image (Figure 14A). Check this position by looking at the teeth and aiming ring from the side, as in Figure 14. If ideal positioning is not possible, place the PID over the teeth with the suggested vertical angulation for the area. The PID should not follow the ring (as in Figure 13).

### Vertical Angulation: Why are the incisal edges/cusp tips not captured on the anterior & posterior periapical images?

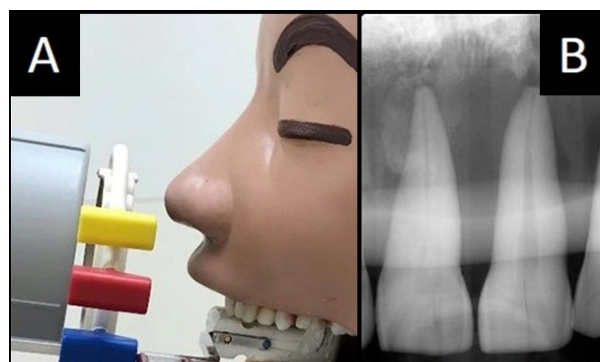**Maxillary Anterior Periapical:** For an ideal image, place the sensor parallel with the long axis of the teeth, best identified by looking at the patient from the side (Figure 15). Realize that the sensor holder can take many positions against the incisal edges, moving the sensor away from parallelism. In the case of a shallow palate or maxillary torus, the sensor's position is often altered, the aiming ring will have increased vertical angulation, and should not be followed. Figure 16 shows the effects of small changes of the position of the bitepiece and the loss of parallelism of sensor and teeth.



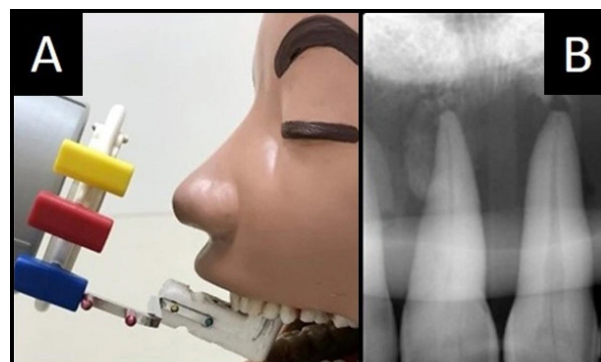


**Figure 14 - Mandibular anterior periapical setups and resultant images.**

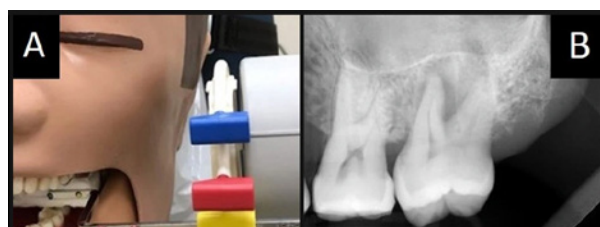The effects of different positions of the sensor holder can be drastic. **(A)** is ideal, **(B)** is slightly less than ideal, but still diagnostic, **(C)** is Non-Diagnostic as the crowns are off the image, the length of the teeth are foreshortened, making bone level assessment difficult.



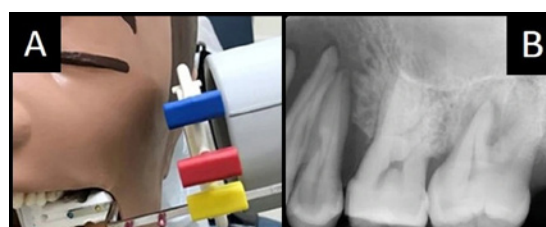
**Figure 15 - Maxillary anterior periapical**  
Ideal image **(B)** results when the sensor parallels the long axis of the teeth **(A)**.



**Figure 16 - Maxillary anterior periapical**  
Sensor is not paralleling the long axis, the vertical angulation is excessive, and the incisal edges are cut off of the image.



**Figure 17 - Maxillary posterior periapical.**  
**(B)** Ideal image results when the sensor parallels the long axis of the teeth **(A)**.



**Figure 18 - Maxillary posterior periapical.**  
**(A)** Sensor is not paralleling the long axis, the vertical angulation is excessive, and the crowns are cut off of the image **(B)**.

**Maxillary Posterior Periapical:** For an ideal image, the sensor should be placed parallel with the long axis of the teeth, which is best identified by looking at the patient from the front (Figure 17). In much the same way, a shallow palate or maxillary torus will push the sensor away and increase the vertical angulation. The crown of a tooth is often 'cut off' the image (Figure 18).


### Common Problems & Solutions

Strong tongue? Limited opening? Limited space within the mouth for a large rigid sensor? Patient gagging? Difficulty in placing the sensor parallel with the mandibular teeth? Patient's tongue pushing the sensor out of the mouth? Unable to image the most distal molar in the mouth? Every dental professional has experienced these challenges. Always be aware of the sensor's position in the mouth. Think past the aiming ring! In a difficult situation, it may be impossible to get an ideal image. Get creative...use a different sensor holder, have the patient hold a hemostat with a simple sticky tab, modify the technique.

#### Problem #1: Small mouth/limited opening:

**Example:** Small mouth, limited opening, cannot get the large sensor and its holder in the mouth.

**Solution:** Use smaller sensor holders such as sticky tabs (Figure 19). Their use eliminates several millimeters of plastic that position at the sides of many sensor holders. Having the patient hold the sensor in place with their own finger should be avoided.



**Figure 19 - Sticky Tabs**

A Sticky Tab system eliminates the bulkiness of other systems, making it easier for the patient. The white (anterior), blue (bitewing), and yellow (posterior) tabs accommodate the aiming rod and ring. The green tab can be held with a hemostat. The red tab can be used as is.

#### Problem #2: Difficulty Positioning Sensor for Mandibular Molar Periapical

**Example:** Difficulty positioning the sensor for a mandibular molar periapical...tongue is pushing the sensor over the teeth. The mouth is small and the sensor is too long front to back.

**Discussion and Solution:** First, level the occlusal plane. Using a vertical bitewing holder, offset the sensor to align with the particular tooth/teeth. The holder keeps the sensor inside the mouth...it cannot move out of position. Do not use an aiming ring...follow the correct vertical angulation for that particular tooth/teeth. You will not image as many teeth as a traditional periapical, but the image of the selected molar can be ideal (Figure 20). This is a great technique for an adolescent, where anterior-posterior space is limited. It is easier to position the sensor vertical...you won't capture as many teeth in 1 image, but you will create a great diagnostic image for emergency toothaches and endodontic procedures, where 1 tooth is the focus of the image.

#### Problem #3: Fail to Capture Distal of Canine on Premolar Bitewing Image

**Example:** Not capturing the distal canine crown on the premolar bitewing image.

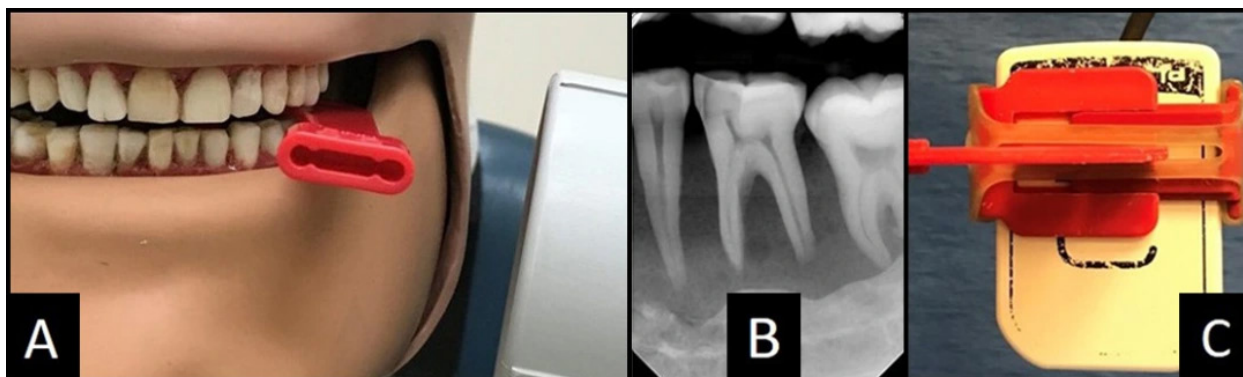
**Discussion:** There are many reasons for this problem and several solutions. Examples include malpositioned canine crowns that are too far forward, uncomfortable positioning that causes the patient to move the mandible forward and away from the sensor, and dead zones on the sensors.

In Figure 21, the sensor is positioned for a premolar bitewing, where the criteria includes imaging the distal crown of canines #11 and #22. As seen inside the red circle, there is dead zone behind premolar #'s 12 and 21. The full first premolars and the distal canine crowns will not appear on the image.

#### Solutions:

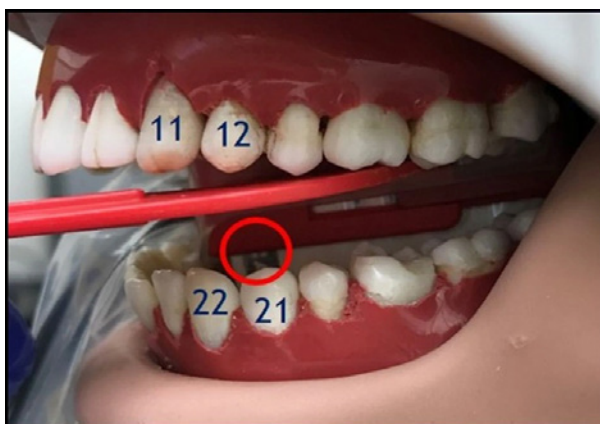
**1.** Purposefully position the PID to pass radiation over the canine, whether the sensor is fully behind the canine or not. By moving the PID forward, you are changing the





**Figure 20 - Mandibular molar periapical.**

Use of a vertical bitewing holder (C) as an alternate sensor holder when the mouth is small. Use the suggested -5 degrees negative vertical angulation (A) to create an ideal molar periapical (B).



**Figure 21 - Premolar Bitewing**

The deadzone of the sensor is behind tooth #21 within the red circle. The premolars and the distal canine crowns will not be captured in the image.



**Figure 22**

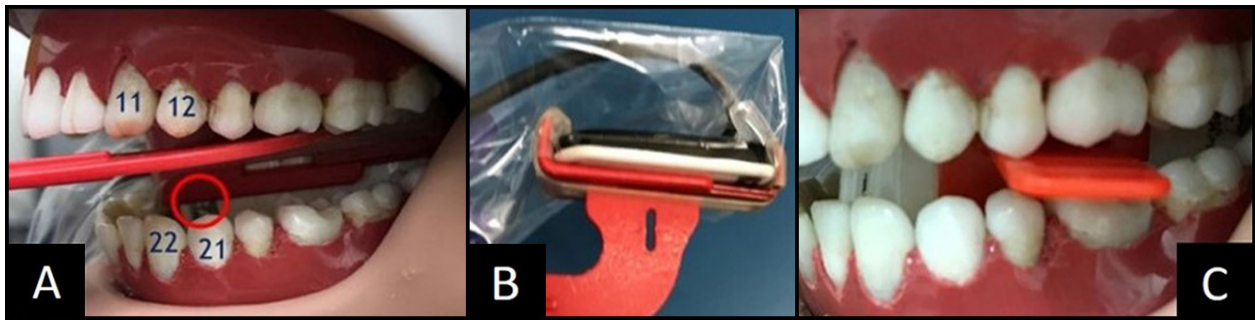The PID may be intentionally placed away from the aiming ring when it is determined that the ring is not creating the needed radiation path to open the contacts.

radiation's path allowing a portion of the canine crown to be imaged. In Figure 22, the PID is not following the aiming ring in the horizontal plane as evidenced by the unequal gap between the PID and the ring.

**2.** Corded sensors often have a larger dead zone at the corded end. Figure 23 shows two solutions with the featured sensor, which has rounded corners and a fuller active area on the far end (away from the cord) of the sensor. The corded end of the sensor is posterior, and the cord has been **gently turned forward** to come out of the mouth (ensure that the active side of the sensor is toward the PID). Figure 23 B shows the reversed sensor in the bitewing holder. Figure 23 C shows the use of a simple bite-tab on a reversed sensor, which eliminates

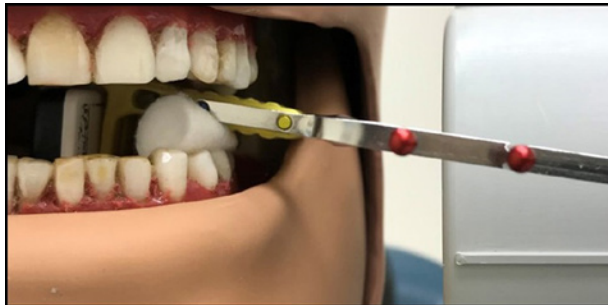
the bulkiness of the bitewing holder, positioning ample active sensor behind the canine crowns. Use this technique with caution, and only as a last resort, as bending the cord may damage the sensor.

**3.** When positioning the sensor for a premolar bitewing, the anterior mandibular bone is in contact with the sensor, and if painful, the patient moves the mandible forward and away from the sensor. When the above methods are unsuccessful in capturing the distal of the mandibular canine crown, use a periapical holder instead of a bitewing holder (Figure 24). The mandible cannot move away from the periapical holder as it can with a bitewing holder. Use zero degrees vertical angulation across the mandibular premolar-canine to create the 'bitewing' look of the crowns and interproximal contacts.



**Figure 23 - Premolar Bitewing.**

(A) Sensor deadzone is behind the premolars... the required canine and premolar will not be captured in the image. Solutions to position active sensor behind the canine crown include reversing the sensor in a traditional holder (B), or by using a simple tab with a reversed sensor (C).



**Figure 24**

The PID may be intentionally placed away from the aiming ring when it is determined that the ring is not creating the needed radiation path to open the contacts.

#### **Problem #4: Bitewing Images Not Ideal**

**Example:** Bitewing image is not balanced, there is more mandible than maxilla.

**Discussion:** Bitewings are not just for opening contacts. Bitewings are critical for capturing true bone levels. The vertical angulation used for periapical images often distorts the bone levels and the dentist is at a disadvantage when diagnosing periodontal bone loss. Because of the position of the teeth in the jaws (Figure 4), +5 degrees is needed to create an ideal bitewing image.

**Solution:** Remember the statement from earlier in this presentation: "The Path of Radiation must include the area of interest (teeth and surrounding bone) and active sensor." When the patient bites on the bitewing holder, the aiming ring is often tilted downwards towards the floor, as in Figure 25A. In this negative path, active sensor may not be

in position behind the maxillary crestal bone. The crowns of the maxillary teeth will appear on the image, but not the bone levels. When this happens, position the PID at +5 degrees across the maxillary bone and center across the arches of teeth (Figure 25B).

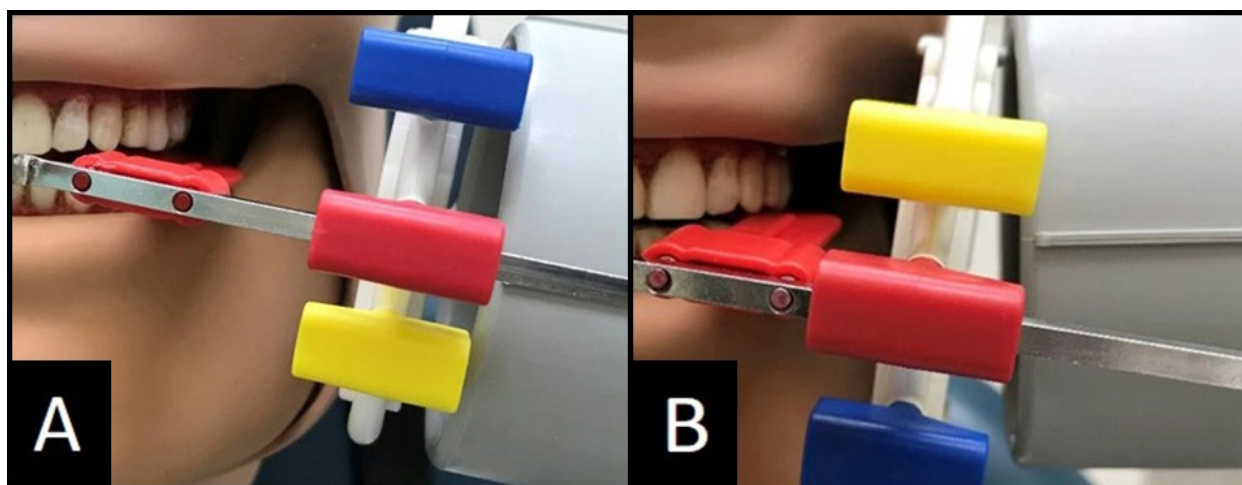
**Example:** No Maxillary restoration margins or bone levels on the bitewing.

**Discussion:** When critiquing bitewing images, identify restoration margins and bone levels on both the maxillary and mandibular arches. When restorations are large and extend further apically along the root, the full restoration and its position against the natural tooth may not be captured with a traditional bitewing position. In Figure 26, the crown margin of #13 is barely visible, #14 can be seen, and the distal of #15 was not imaged. The crown margins of #'s 18, 19, and 20 are apparent and diagnostic. Insufficient positive vertical angulation is the reason the maxillary margins are missing.

**Solution:** The positive vertical angulation in Figure 27B has remedied the problem. When the maxillary bone loss is extensive, the PID may need +5 to +10 degrees, and should be positioned higher across the actual position of the crestal bone that is desired (Figure 27C).

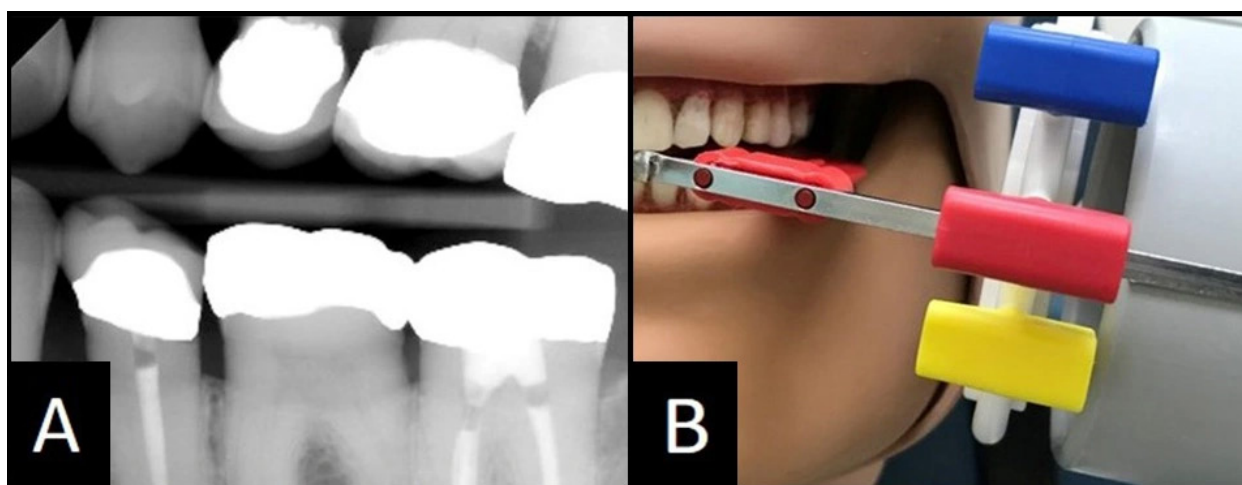
#### **Problem #5: Comparison of periapical images versus bitewing images:**

**Question:** Will a periapical of maxillary teeth show caries at the crown margin as well as a bitewing?



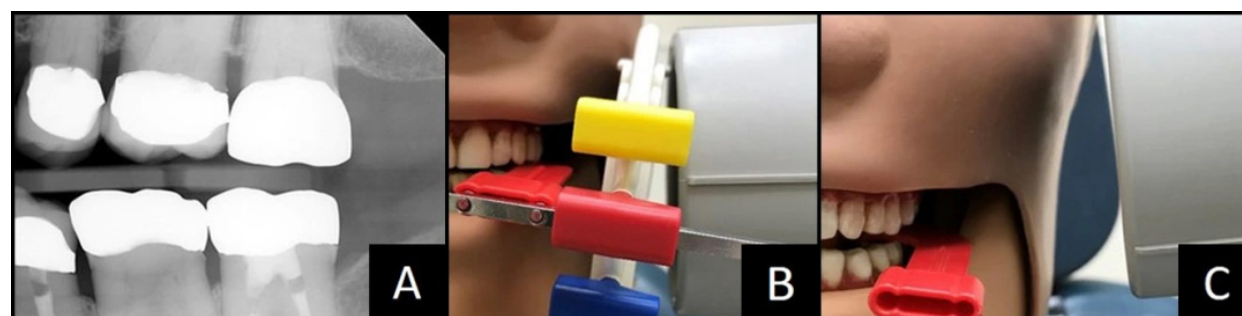
**Figure 25 - Bitewing not balanced.**

(A) Negative vertical angulation across a bitewing will often cut off the Maxillary crowns and bone levels. (B) The PID has been placed to the suggested +5 degrees, and is not following the aiming ring.



**Figure 26 - Bitewing image did not capture Maxillary margins or bone.**

(A) The crown margins and bone levels of tooth #'s 13, 14, 15, do not appear in the image, because the patient's bite caused the sensor holder to pitch downward with negative vertical angulation, and the aiming ring was followed (B).



**Figure 27 - Ideal bitewing image.**

(A) The image is balanced with crown margins and bone levels on both arches. (B) The PID was set at +5 degrees across the occlusal plane, and did not follow the aiming ring. (C) In patients with moderate to severe periodontal disease, the PID can be positioned over the area of Maxilla that is desired.



**Answer and Discussion: NO.** The maxillary periapical image is created using +10 to +30 degrees of vertical angulation as compared to a bitewing that is usually created with +5 degrees. The greater vertical angulation changes the way the crown looks on the image. The buccal and lingual margins superimpose part of the root, making diagnosis of the margin impossible. Figure 28 compares a periapical and bitewing of the same crowns. Caries can only be diagnosed from this bitewing image, as the crown margins are covering the root immediately adjacent to the margin on the periapical image.

**Solution:** Well-taken bitewing images are far superior to periapical images for imaging crown margins and bone levels. The goal is to keep the crown separate from the neighboring tooth and bone. First, level the occlusal plane. Stand in front of the patient, look at the buccal and lingual margins of the crown and place them on

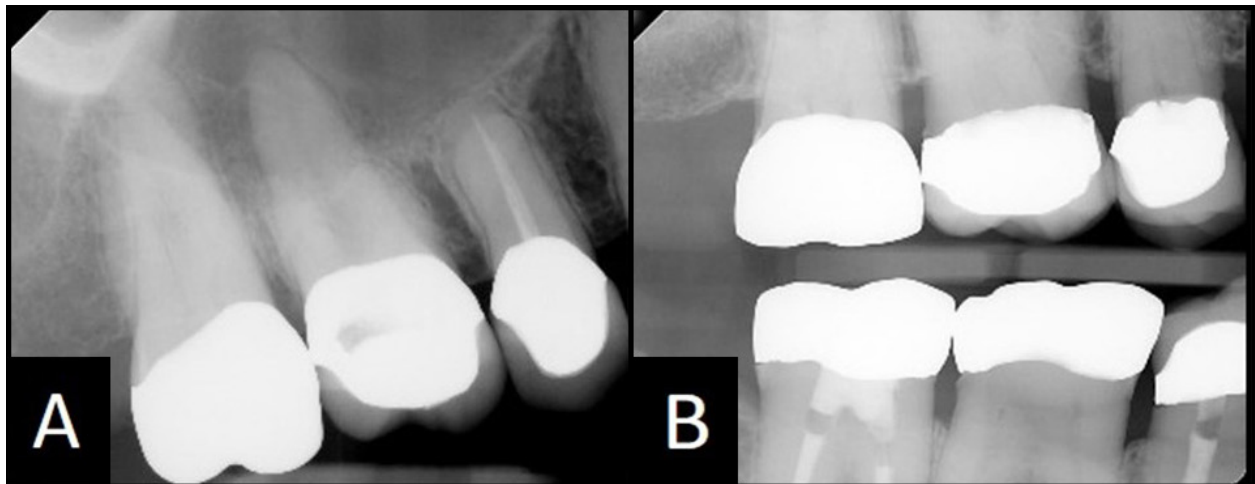
a single line, then follow that line with the PID's vertical angulation, as in Figure 29a.

Use this technique when verifying crown margins prior to cementation (Figure 29B). Do not use the aiming ring, your goal is to parallel the margins of the crown. Better to do that by positioning the PID directly across the crown margins.

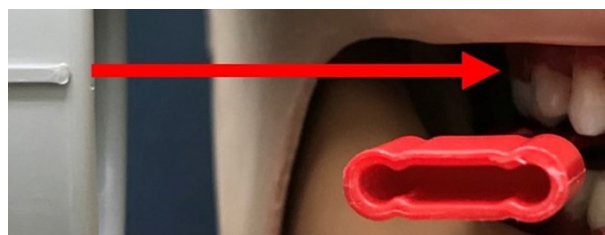
**Question:** Is a periapical of maxillary molars the best image to portray the periodontal bone status and show the furcation areas?

**Answer:** Usually not, because of limitations in the oral cavity, such as a shallow palate, preventing the sensor from paralleling the teeth.

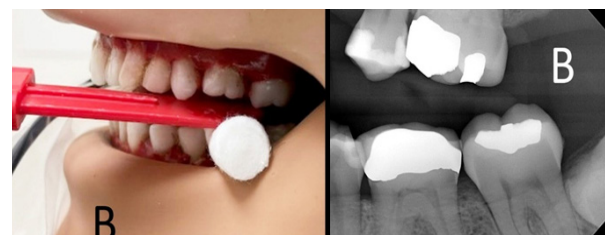
**Discussion:** As mentioned in the introduction, excessive vertical angulation can foreshorten



**Figure 28 - Comparison of periapical and bitewing images of the same crowns in the same patient.** (A) The periapical image is not diagnostic for bone levels and crown margins. (B) The crown margins and bone are visible for examination on this ideal Bitewing image.



**Figure 29a - Imaging crown margins.** Create a single plane across the buccal and lingual margins with the Path of Radiation to create an ideal image.



**Figure 29b** Cotton placed on the crown #19 prior to cementation to check seating of the crown.

the structures on an image. When there is adequate room in the palate for the sensor to parallel the teeth, the image will be ideal. When the sensor does not parallel the teeth because of a narrow or small palate, the sensor must flatten towards the occlusal plane, thereby increasing the vertical angulation, positioning the aiming ring towards the ceiling.

**Solution:** The vertical bitewing technique can be used in the maxillary arch when a non-foreshortened image of a molar is needed (Figure 30). This is particularly helpful when assessing periodontal bone loss and furcation involvement. In a patient with a flat, shallow palate, the sensor cannot align fully with the maxillary roots. The operator used +10 degrees

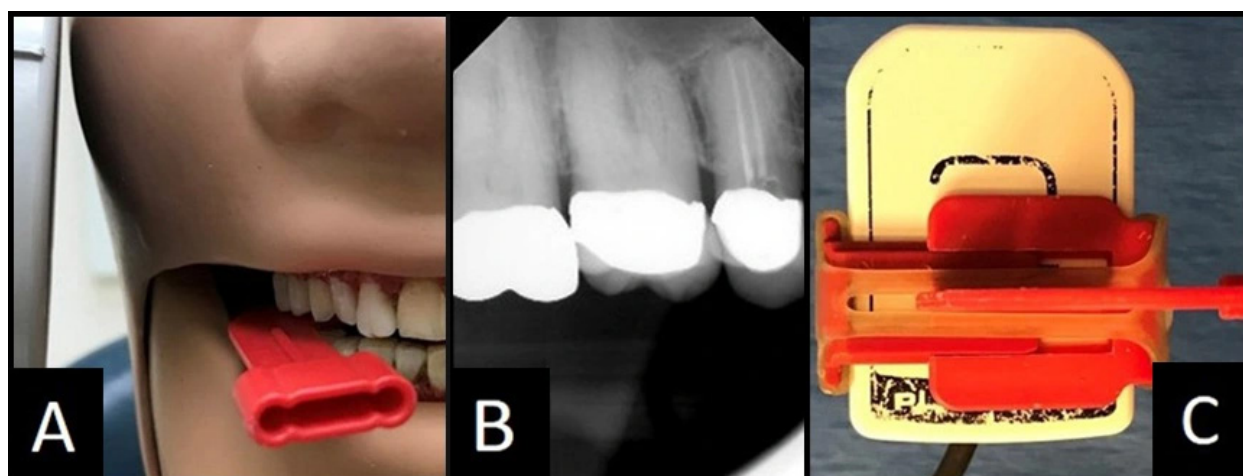
and the molar's apex is nearly off the image (Figure 30B). The furcation, crown margins, and the bone levels are visible in this diagnostic image. Although this image is not ideal, it may give valuable diagnostic information.

#### **Problem #6: Not Imaging the Entire Tooth**

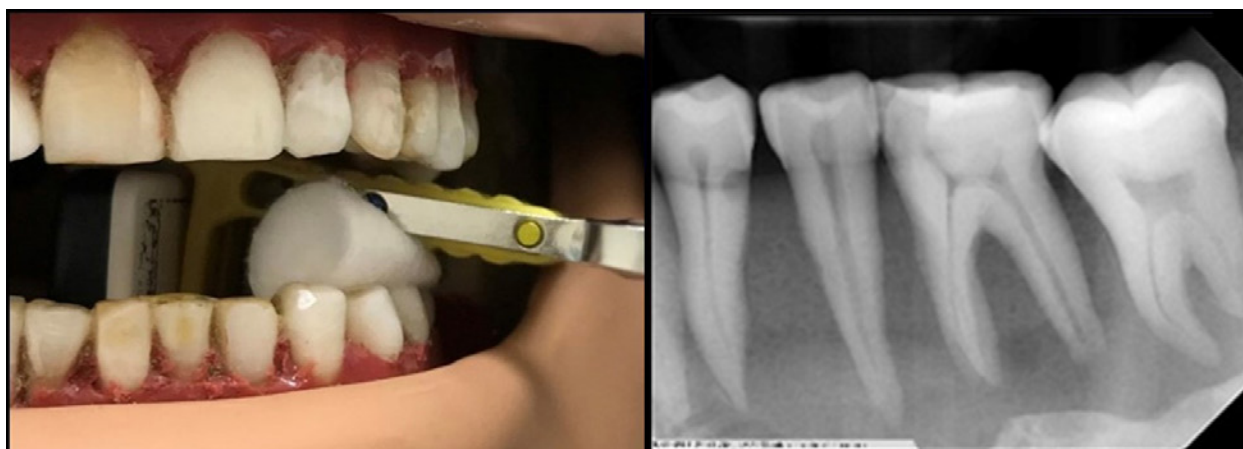
**Example:** Cutting the crowns and incisal edges off periapical images, not imaging the entire tooth.

#### **Discussion and Solutions:**

**1.** Excessive vertical angulation can cut crowns and incisal edges (section on **The Basics of Intraoral Imaging: Horizontal and Vertical Angulation**) off the image. Correct this problem by decreasing the vertical angulation either by



**Figure 30 - Maxillary periodontal assessment of bone levels and furcations using the vertical bitewing holder. (A)** Lift the PID over the desired area at +5 to +10 degrees. **(B)** The bone levels and furcation are imaged true, though the entire apex is not visible. **(C)** Offset the sensor towards the Maxilla.



**Figure 31 - Creating space with a cotton roll to prevent cutting crowns off the image. Lifting the sensor above the crowns will increase the chance that the Path of Radiation will include active sensor.**



re-positioning the sensor in the mouth, or by simply moving the PID to a more appropriate position for the teeth being imaged.

**2. Crowns and incisal edges may be cut off** because of the lack of active sensor in the path. This often happens because the sensor holder has a thin bitepiece that places the dead zone directly across from the crowns. **Solution:** Use a spacer at the crown of the tooth. By placing a piece of cotton against the crown of the tooth, the sensor is raised above the crown, allowing the radiation path to include active sensor (Figure 31). Be sure to flatten the cotton, all that is needed is a narrow gap above the crowns on the image.

#### **Problem #7: Images for Implant Procedures**

**Discussion:** Imaging during implant surgery and restorative procedures is critical to success. Verification of the seating of components (healing caps, impression copings, and abutments) is mandatory prior to the fabrication of crowns, bridges, and dentures, whether in-house or at a contracted lab.

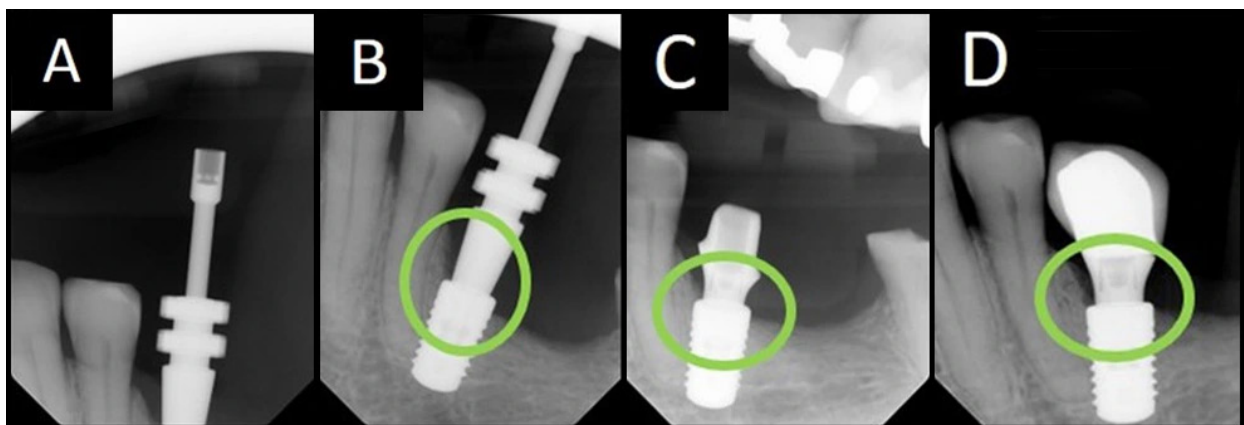
**Solution:** Identifying the platform, the flat top of the implant, is the first step. Most important: the vertical angulation of the PID must parallel the position of the component to the implant platform. A bitewing holder is most successful, as it tends to be more stable in the mouth, do not use an aiming ring, simply follow the top of

the implant. A vertical bitewing holder should be used when the bone levels have resorbed away from the occlusal plane. Periapical holders can be used without the aiming ring. Simple sticky tabs can be used with a hemostat. The operator's goal is to parallel the PID with the position of the implant. Typically, maxillary implants require some degree of positive vertical angulation, while mandibular implants require some degree of negative vertical angulation. A series of images for #20 (impression coping, abutment, cemented crown on abutment) using a bitewing holder and a periapical holder is shown in Figure 32. An impression coping not fully seated is shown in Figure 33, along with the corrected position and periapical view of the final implant crown fully seated. An open, not fully seated, abutment and crown is shown in Figure 34.

#### **Problem #8: Difficulty Capturing 2nd and 3rd Molars on Periapical Images**

**Discussion:** It is often difficult to position the sensor in the molar area. The bite can move the sensor holder forward towards the premolars or the patient may be uncomfortable with the holder in that position, triggering the gag reflex. Lift the chin to drop the tongue back and away to alleviate this feeling.

**Solution:** The sensor does not have to be placed so far posterior that the patient is uncomfortable. Remember the path of radiation



**Figure 32 - Implant #20.**

(A) and (B) Impression coping. Implant platform not captured in (A). Sensor re-positioned lower in the mouth to capture the interface in (B). (C) Abutment fully seated. Image is diagnostic, excessive vertical angulation was used. (D) Crown cemented, platform captured with ideal vertical angulation.

statement one more time: The path of radiation must include the area of interest (teeth and surrounding bone) and active sensor. Change the path to cross the area from behind. Position the tubehead towards the ear and set the horizontal angulation of the radiation path forward across the most distal molar. The sensor can be placed as far posterior in the mouth as is comfortable. The interproximal contacts will be overlapped, but the root apices of the molars will be visible (Figure 35).

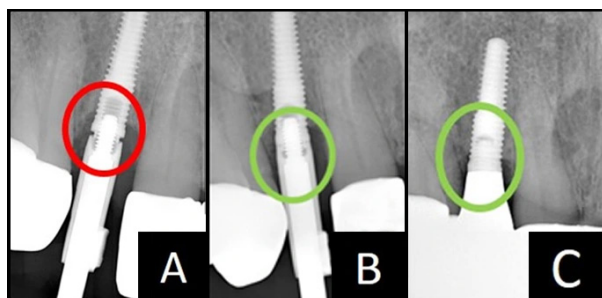
#### **Problem #9: Capturing the Mesial and Distal of a Canine**

**Discussion and Solution:** The canine sits at the corner of the arch. The mesial canine contact is captured from the front on an anterior periapical image, and the distal contact is captured from a posterior perspective, on a premolar bitewing or periapical image. In Figure 36, a periapical image of canine #6 was acquired for a pre-cementation check of the PFM crown.

The entire crown margin cannot be seen due to the overlap of the premolar #5 on the periapical image. A bitewing image was acquired that shows the open contact on the distal margin. When imaging a canine that is within the arch of teeth, it is best to capture images from an anterior and a posterior perspective.

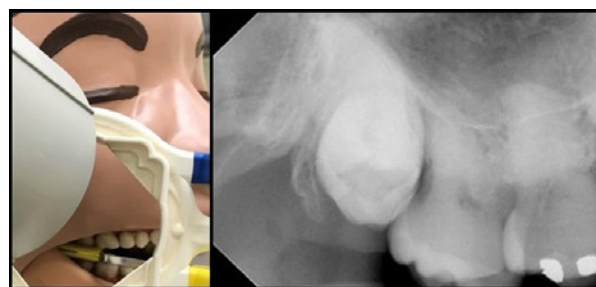#### **Problem #10: Capturing the Apex during an Endodontic Procedure**

**Discussion and Solution:** Completing images when the tooth is under rubber dam and has files or gutta percha points in place is challenging. Using rod and ring aiming instruments specific for endodontics places the apices of the tooth within the aiming ring. Proper placement of the sensor holder is critical. The operator can also use a simple sticky tab and hemostat to secure the sensor. The variables (horizontal and vertical angulation, head position, and sensor position) must be controlled and correct. The patient's



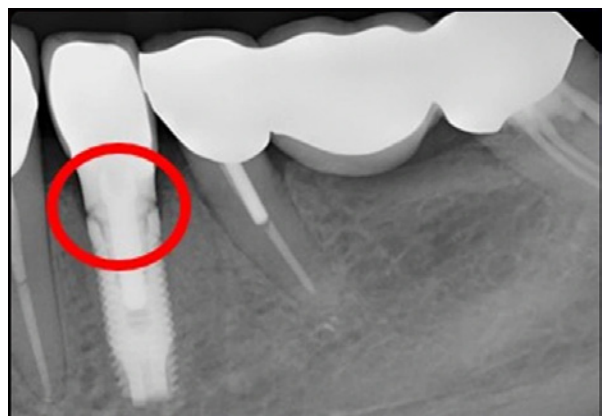
**Figure 33 - Implant #7.**

(A) Impression coping not fully seated.  
(B) Impression coping repositioned and fully seated.  
(C) Final image of abutment and crown fully seated.



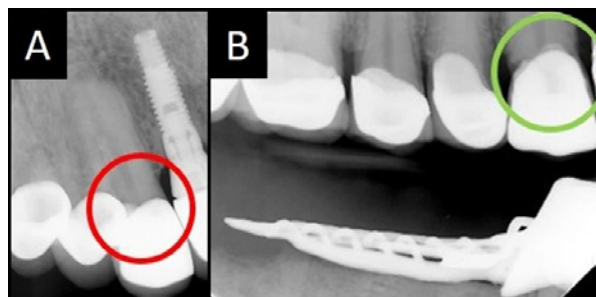
**Figure 35 - Distal Molar Periapical.**

Redirecting the PID posterior to the aiming ring to ensure coverage of radiation over the Maxillary third molar and distal tuberosity.



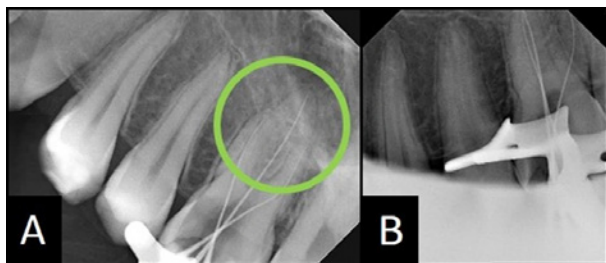
**Figure 34 - Implant #21.**

Abutment/crown not fully seated verified by radiolucent gap (red circle).



**Figure 36 - Canine Periapical.**

(A) Pre-cementation periapical of #6 does not show the distal margin. (B) The bitewing shows the open distal margin (as well as the mesial in this case).



**Figure 37 - Endodontic procedure #14 working length files.**

**(A)** Occlusal plane was positioned parallel to the floor of the room. The 3 canals are imaged without distortion (green circle). **(B)** Occlusal plane was up towards the ceiling. The working length files were not captured.

head position is often forgotten, and when left positioned towards the ceiling, a maxillary tooth may be cut off, and a mandibular tooth will be foreshortened. Images of working length files in a maxillary first molar, where the patient's head position was the problem (looking up towards the ceiling shown in Figure 37B). The occlusal plane was repositioned towards the floor, and

the apices were captured (Figure 37 A). When the occlusal plane cannot be level with the floor, the vertical angulation must be adjusted to ensure coverage of the apices with radiation. The PID will move with the occlusal plane, typically the patient is looking towards the ceiling, and the vertical angulation will be increased past the suggested values.

### Summary

Successful imaging is not easy. Intraoral imaging requires knowledge of anatomy of the maxilla and mandible, and of the position of the teeth in the jaws. Despite our best efforts, we may need to expose a panoramic to get what we need. You have learned to modify an intraoral technique based on the position of the teeth in the jaws, and the position of the patient's head. Remember that the teeth and the sensor must be contained in the path of radiation no matter what instruments are used or where the head is positioned.

## Course Test Preview

To receive Continuing Education credit for this course, you must complete the online test. Please go to: [www.dentalcare.com/en-us/ce-courses/ce660/test](http://www.dentalcare.com/en-us/ce-courses/ce660/test)

1. **The Paralleling Technique is also known as the \_\_\_\_\_.**
  - A. Short-Cone Technique
  - B. Straight-Angle Technique
  - C. Long-Cone Technique
  - D. The Bisected Angle Technique
2. **Of the four variables of intraoral imaging, which one is missing from this list: horizontal angulation, vertical angulation, sensor placement, and \_\_\_\_\_.**
  - A. Number of teeth in the mouth
  - B. Head position
  - C. Type of instrument used
  - D. Age of the patient
3. **The Path of Radiation must contain all of the following EXCEPT one. Which is the exception?**
  - A. The teeth of interest
  - B. Full apex and surrounding bone on a periapical image
  - C. Aiming rod
  - D. Active sensor
4. **The PID is part of the x-ray machine. We position the PID with the needed horizontal and vertical angulations. PID stands for \_\_\_\_\_.**
  - A. Photo Imaging Device
  - B. Parallel Imaging Device
  - C. Position Indicating Device
  - D. Photon Indicating Device
5. **Which of the four variables involved with intraoral imaging is ultimately responsible for opening interproximal contacts?**
  - A. Sensor position
  - B. Head position
  - C. Horizontal angulation
  - D. Vertical angulation
6. **The American Dental Association no longer recommends the use of a protective apron..**
  - A. True
  - B. False
7. **The operator should perform a brief intraoral examination before beginning the process of acquiring images and assess all of the following EXCEPT one. Which is the exception?**
  - A. Number of teeth in the mouth
  - B. The anterior mandible looking for tori
  - C. The position of the canines
  - D. The color of the teeth
  - E. The parallelism of the marginal ridges for opening contacts

8. **The operator should always ask the patient to \_\_\_\_\_ during the process of placing the sensor in the mouth and placing the PID for exposure.**
- A. Cough
  - B. Close their lips
  - C. Smile
  - D. Hold their breath
9. **\_\_\_\_\_ dictates sensor placement and PID placement.**
- A. The aiming ring
  - B. Tooth position
  - C. Age of the patient
  - D. The absence of opposing teeth
10. **Which of the following is the correct sequence prior to exposing the sensor?**
- A. Place the sensor in the mouth and follow the aiming ring without looking at the marginal ridges of the teeth. Expose the sensor.
  - B. Find the horizontal angulation needed to open interproximal contacts first, then place the sensor. Position the PID parallel with the marginal ridges. Expose the sensor, and evaluate the image.
  - C. Find the largest teeth in the mouth and place the sensor holder on them, then follow the aiming ring. Expose the sensor.
  - D. Place the sensor in the mouth, position the PID against the aiming ring and expose the sensor. Evaluate the image and take corrective actions.
11. **Which of the following images is BEST for diagnosing caries and periodontal bone loss?**
- A. Periapicals
  - B. Occlusals
  - C. Bitewings
  - D. Panoramic
12. **Select the one answer below that is not needed to complete this statement: Before exposing the sensor, the operator should\_\_\_\_\_.**
- A. Position the patient's occlusal plane parallel to the floor of the room
  - B. Find the horizontal angulation needed to open the interproximal contacts and make sure active sensor is in the path
  - C. Confirm that the aiming ring should be followed for horizontal and vertical angulations
  - D. Make sure the patient's eyes are closed
  - E. Make sure the patient is smiling to show the teeth
13. **Increasing the vertical angulation (too much positive vertical for a maxillary tooth, or too much negative for a mandibular tooth) will \_\_\_\_\_**
- A. Elongate the tooth on the image
  - B. Foreshorten the tooth on the image
  - C. Result in a perfect image
  - D. Always require the patient to look at the ceiling of the room
14. **All of the following have the potential of cutting the incisal edges off the image EXCEPT one. Which is the exception?**
- A. Sensor holder sliding out of the mouth, increasing the vertical angulation
  - B. Using an excessive amount of vertical angulation
  - C. Confirming the parallelism of the aiming ring to the long axis of the teeth with active sensor in the radiation path created
  - D. By not placing cotton at the incisal edges of the anterior teeth



- 15. Which of the following sensor holders should be avoided?**
- A. Autoclavable sensor holders for Paralleling
  - B. Disposable sticky tab system
  - C. The patient's finger
  - D. Autoclavable periapical holder
- 16. Of the following autoclavable sensor holders for paralleling, which did you learn can be used to create an ideal molar periapical in a small mouth?**
- A. Horizontal bitewing holder
  - B. Posterior periapical holder
  - C. Anterior periapical holder
  - D. Vertical bitewing holder
- 17. The premolar bitewing image is the proper image for viewing the distal canine crown for caries. All of the following techniques can increase the chance of capturing the canine EXCEPT one. Which is the exception?**
- A. Making sure active sensor is forward in the jaws and positioned behind the canine
  - B. Using a periapical holder for a mandibular premolar (the mandible can't move away from the sensor like it can with a bitewing holder)
  - C. Positioning the PID more forward and passing radiation across the canine
  - D. Simply following the aiming ring even though the sensor's dead zone is positioned behind the canine
- 18. Ideal bitewing images are created with +5 degrees vertical angulation and an occlusal plane parallel with the floor. Bitewing images should fulfill all of the following criteria EXCEPT one. Which is the exception?**
- A. Create a balanced image...same amount of maxilla as mandible
  - B. Open the appropriate interproximal contacts
  - C. Show maxillary alveolar crestal bone levels
  - D. Show maxillary apices
- 19. When the bitewing aiming ring is pointed towards the floor of the room, all of the following should be expected EXCEPT one. Which is the exception?**
- A. A non-balanced image showing more mandible than maxilla
  - B. A high probability that the maxillary bone will not be seen
  - C. A high probability that maxillary crown (restorations) margins will not be seen
  - D. A balanced image with maxillary bone levels
- 20. Implant images can be exposed with any sensor holder as long as the sensor is contained in the correct radiation path, and the proper vertical angulation is used. Images can be acquired using the following sensor holders to ensure seating of the component EXCEPT one. Which is the exception?**
- A. Horizontal bitewing holder
  - B. Vertical bitewing holder
  - C. Holder for occlusal technique
  - D. Simple sticky tab with hemostat
  - E. Periapical holder

## References

1. Mallya, S. M., Lam, E. W. N., White, S. C., & Pharoah, M. J. (2019). White and Pharoah's oral radiology: Principles and interpretation, 8th ed. St. Louis, MO. Elsevier. 2019
2. Whaites, E. (2014). Essentials of Dental Radiography and Radiology. London: Elsevier Health Sciences UK, 4th ed. 2007
3. Erika Benavides, Avni Bhula, Anita Gohel, Alan G Lurie, Sanjay M Mallya, Aruna Ramesh, Donald A Tyndall. Patient shielding during dentomaxillofacial radiography: Recommendations from the American Academy of Oral and Maxillofacial Radiology. J Am Dent Assoc. 2023 Sep;154(9):826-835.e2
4. Erika Benavides, Joseph Krecioch, Roger Connolly, Trushul Allareddy, Allison Buchanan, David Spelic, Kelly O'Brien, Martha Keels, Ana Karina Mascarenhas, Mai-Ly Duong, Mickie J. Aerne-Bowe, Kathleen Ziegler, Ruth Lipman. Optimizing radiation safety in dentistry. Clinical recommendations and regulatory considerations. J Am Dent Assoc. 2024;155(4):280-293.

## Additional Resources

- No Additional Resources Available

## About the Authors

### Debra A. Dixon, DMD, MSc



Debra Dixon is a Professor, Head of Radiology, and Section Head of Diagnostic Sciences at Southern Illinois University School of Dental Medicine in Alton, Illinois. Graduating from SIU School of Dental Medicine in 1993, she then completed an AEGD program and was in the inaugural 1995-1996 Implant Fellowship class at the school. She completed an MSc in Dental Radiology at the University of London. She has been a Radiology educator for pre-doctoral students for 25 years, has participated in several NIH projects with colleagues and has authored/co-authored several manuscripts. She is a member of the American Academy of Oral and Maxillofacial Radiology and continues to serve on the ADA Commission for Continuing Education Provider Recognition. Dr. Dixon presents Radiology CE for dental auxiliaries in collaboration with the Illinois State Dental Society.

Email: [ddixon@siue.edu](mailto:ddixon@siue.edu)