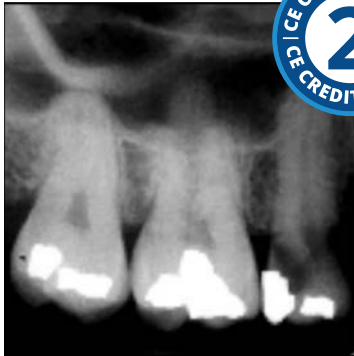

# Intraoral Radiographic Anatomy



**Course Author(s):** Gail F. Williamson, RDH, MS

**CE Credits:** 2 hours

**Intended Audience:** Dentists, Dental Hygienists, Dental Assistants, Dental Students, Dental Hygiene Students, Dental Assistant Students

**Date Course Online:** 03/23/2020

**Last Revision Date:** N/A

**Course Expiration Date:** 03/22/2023

**Cost:** Free

**Method:** Self-instructional

**AGD Subject Code(s):** 731

**Online Course:** [www.dentalcare.com/en-us/professional-education/ce-courses/ce601](http://www.dentalcare.com/en-us/professional-education/ce-courses/ce601)

**Disclaimer:** Participants must always be aware of the hazards of using limited knowledge in integrating new techniques or procedures into their practice. Only sound evidence-based dentistry should be used in patient therapy.

## Conflict of Interest Disclosure Statement

- The author reports no conflicts of interest associated with this course.

## Introduction – Intraoral Radiographic Anatomy

Intraoral Radiographic Anatomy will focus on the anatomical structures that are recorded on intraoral radiographic images. The clinician must be familiar with the anatomical structures to ensure accurate orientation and/or arrangement prior to interpretation. Recognition of anatomical structures serves as a baseline to differentiate normal structures from abnormalities.

## Course Contents

- Overview
- Learning Objectives
- Intraoral Survey Organization
  - Digital Systems
  - Radiographic Film
- Intraoral Radiographic Anatomy
  - Radiolucent vs. Radiopaque
  - General Anatomy of the Maxilla and Mandible
  - Maxillary Anatomical Landmarks
    - Maxillary Anterior Landmarks
    - Maxillary Posterior Landmarks
    - Summary of Maxillary Landmarks
  - Mandibular Anatomical Landmarks
    - Mandibular Anterior Landmarks
    - Mandibular Posterior Landmarks
    - Summary of Mandibular Landmarks
  - Review of Landmarks on Surveys
    - Bitewing Surveys
    - Full Mouth Surveys
- Summary
- Course Test
- References
- About the Author

## Overview

Intraoral radiography is part and parcel of the daily practice of dentistry. Radiographs provide important information to supplement the clinical examination, enabling the dentist to render a diagnosis and develop a treatment plan. Guidance regarding the prescription of radiographs can be found in course, [\*Radiographic Selection Criteria \(CE584\)\*](#).

This course will focus on the anatomical structures that are recorded on intraoral radiographic images. The clinician must be familiar with the anatomical structures to ensure accurate orientation and/or arrangement prior to interpretation. Recognition of anatomical structures serves as a baseline to differentiate normal structures from abnormalities.

It should be understood that not every structure presented will be seen on every radiographic survey. However, enough structures will be recorded to provide the necessary guidance for arrangement and interpretation.

## Learning Objectives

**Upon completion of this course, the dental professional should be able to:**

- Describe the standard for image orientation, arrangement and viewing of intraoral radiographic images.
- Discuss the typical anatomic structures that are recorded on intraoral radiographic images.
- Identify and describe normal anatomic structures of the maxilla.
- Identify and describe normal anatomic structures of the mandible.
- Identify anatomical structures that are commonly recorded on bitewings.
- Determine if intraoral radiographic images are properly oriented and arranged.
- Given a radiographic image or survey, identify anatomical structures that are depicted.

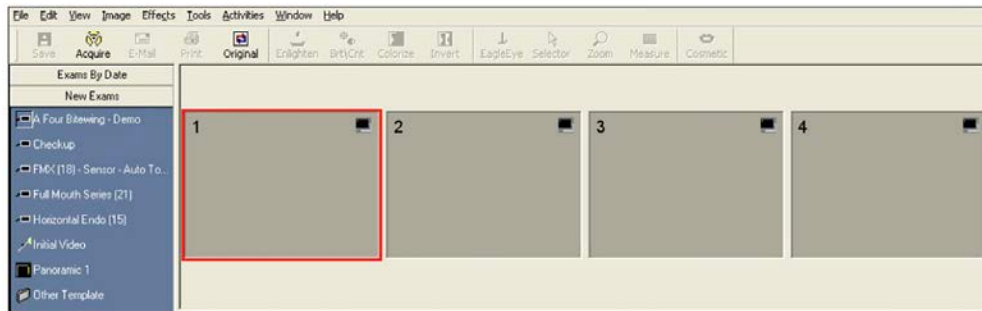
## Intraoral Survey Organization

The American Dental Association's (ADA) standard for viewing and interpreting intraoral radiographic images is labial mounting or arrangement. This orientation presents the survey as if the clinician is facing the patient's oral cavity with the views arranged and organized anatomically according to the patient's right and left sides. This standard applies regardless of the type of receptor (rigid sensor, phosphor plate, film) used to capture the radiographic image(s).

## Digital Systems

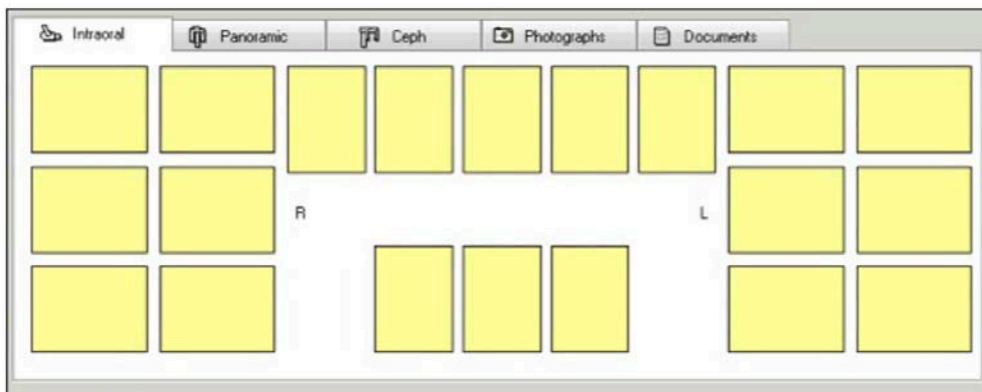
In direct digital (rigid sensor) intraoral radiographic software systems, the clinician selects the appropriate template for the prescribed radiographic examination. Most direct digital software programs allow the clinician to select the sequence of image acquisition according to their preference. This automatically places the images in the proper anatomical position within the template as the images are acquired. There are tools to rearrange images if they are not taken in the correct sequence, placed in the wrong position or incorrectly oriented.

With photostimulable phosphor plate technology, the clinician selects the type of template that matches the survey to be acquired as with direct digital imaging software. Some



#### Bitewing Template Example.

Eaglesoft Advanced Imaging, Patterson® Dental Supply Company, Inc.



#### Full Mouth Template Example.

ScanX®, Air Techniques, Inc.

systems permit the images to automatically populate the survey template if the plates are scanned in a particular order after exposure. In others, the clinician will need to orient and organize the individual images and place them into the correct anatomical and tooth position within the template. Typically, individual phosphor plates are identified with a letter or number to help the clinician properly orient the plate to differentiate right from left. The images can be dragged and dropped into the survey template. Identification of the anatomical landmarks is critical to ensure accurate arrangement.

#### Radiographic Film

With conventional radiographic film, the processed images are oriented with the dot convexity facing the clinician, organized according to anatomical structures, and, then, placed into a film mount. Radiographic film mounts should be made of a material that blocks the light around the window that holds the film. Pocket mounts are preferred as they



#### Various Film Mount Template Examples.

EZ View Pocket Mounts, Dentsply Sirona

provide protection of the film survey and serve as an infection control barrier.

There are anatomic structures that correlate to nearly every periapical and bitewing view to help the clinician verify accurate image location, especially when teeth are missing. These structures will be discussed in the forgoing text.

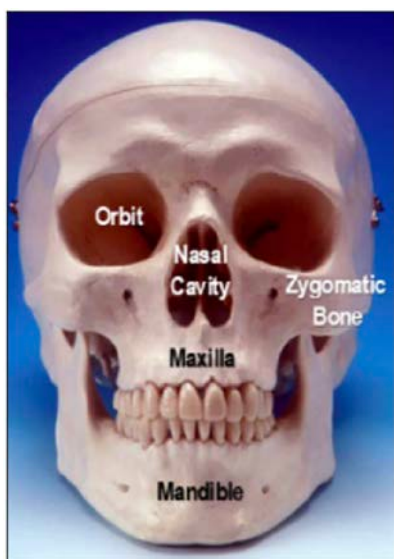
## Intraoral Radiographic Anatomy

### Radiolucent vs. Radiopaque

Structures that are cavities, depressions or openings in bone such as a sinus, fossa, canal or foramen will allow x-rays to penetrate through them and expose the receptor. These areas will appear **radiolucent** or black on radiographic images. Structures that are bony in origin absorb or stop the penetration of the x-rays and, therefore, do not reach the receptor. These areas appear **radiopaque** or white on radiographic images. Some structures partially absorb radiation and are represented in varying degrees of radiopacity.

### General Anatomy of the Maxilla and Mandible

The photograph below denotes the gross structures that are recorded on intraoral radiographic images. These basic structures include the nasal cavity, the zygomatic bone, the maxilla and the mandible. Labeled for general reference is the right orbit of the eye.

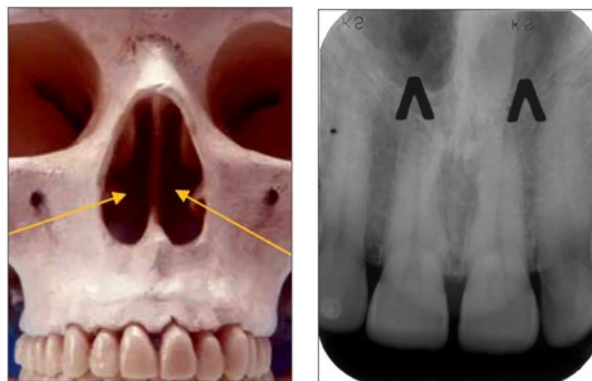


### Maxillary Anatomical Landmarks

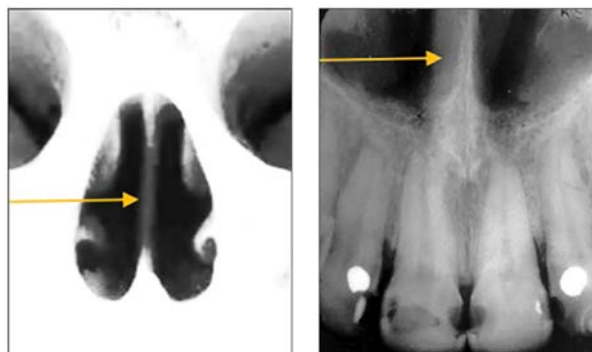
The maxilla is the upper dental arch that contains the maxillary alveolar process, the maxillary teeth and the maxillary sinuses. It sits on either side of the nasal cavity and below the orbits. There are characteristic landmarks both in the anterior and posterior segments of the maxilla that can be observed on maxillary periapicals.

### Maxillary Anterior Landmarks

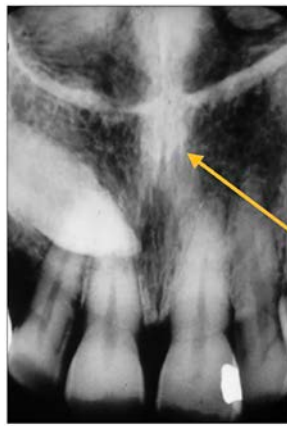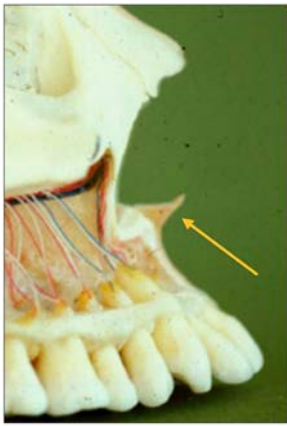
**Nasal fossae** – The nasal fossae (plural; singular - fossa) are the nasal openings located above the maxillary anterior teeth. The fossae are divided in the midline into right and left chambers. Radiographically, the nasal fossae appear as vertically oblong radiolucent structures bounded by bone. These structures can be seen on maxillary central incisor periapical views and partially on lateral incisor and canine periapicals.



**Nasal septum** – The nasal septum is a bony vertical band-like midline structure that divides the nasal cavity into right and left chambers. The nasal septum is a radiopaque landmark visible on maxillary central incisor periapicals.

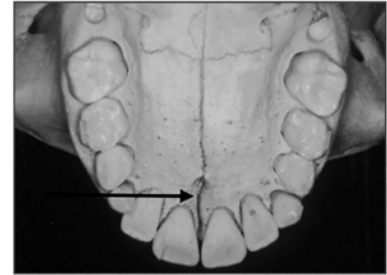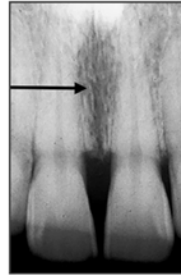
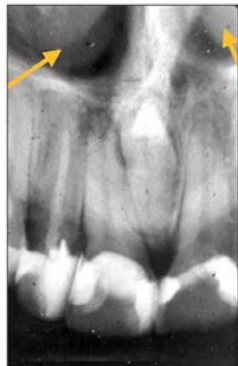
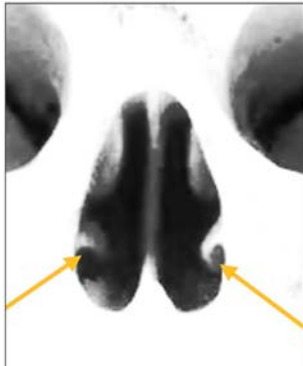


**Anterior nasal spine** – The anterior nasal spine (ANS) is a bony projection located at the base of the nasal septum in the maxillary midline. Radiographically, the ANS appears as a V-shaped or triangular point radiopacity. This structure is recorded on maxillary central incisor periapicals.

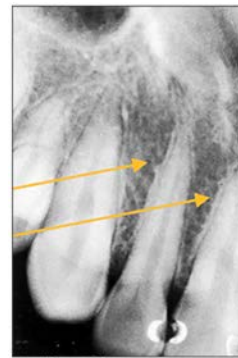


**Incisive foramen** – The incisive or nasopalatine foramen is located in the midline on the lingual aspect of the hard palate above the central incisor teeth crowns. The foramen is the termination of the nasopalatine canal. Radiographically, it appears between the roots of the central incisor teeth as a round to oval radiolucency less than one centimeter in diameter. It has a range of sizes and shapes, so variation is not unusual. This structure is recorded on maxillary central incisor periapicals.

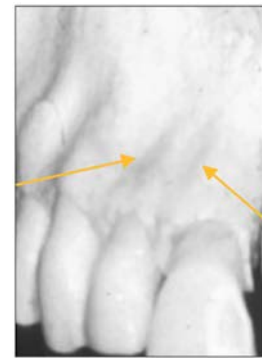**Inferior nasal concha** – The inferior nasal concha or turbinate bone projects into the inferior aspect of the nasal fossa from the lateral walls of the nasal cavity. These bilateral radiopaque structures (conchae) are sometimes visible on central and lateral incisor periapicals.



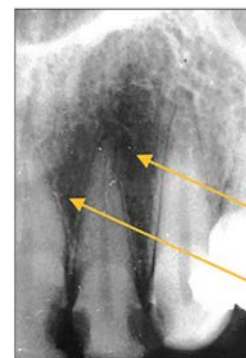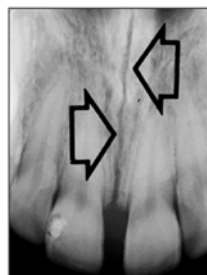
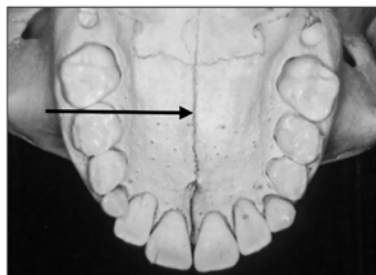
**Lateral fossa** – The lateral fossa is a slight dip or depression in the bone on the labial aspect of the maxilla near and around the lateral incisor tooth root. This diffuse radiolucency appears bilaterally and is recorded on lateral incisor and canine periapicals. It is sometimes referred to as the canine fossa.



Maxillary Right



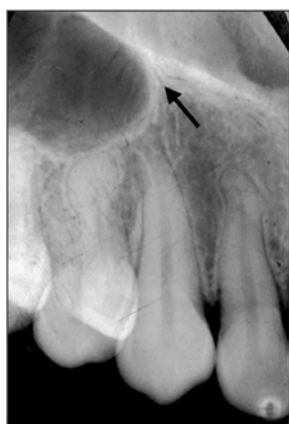**Mid-palatine suture** – The mid-palatine suture is the interface of the two halves of the premaxilla where they come together in the midline. The mid-palatine suture is also referred to as the median palatal suture. It courses from the alveolar crest through the midline to the posterior aspect of the hard palate. This structure appears radiographically as a thin vertical linear radiolucency in the midline on maxillary central incisor periapicals.



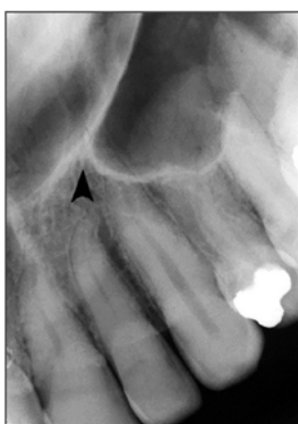Maxillary Left



**Inverted Y** – The inverted Y is a radiographic landmark that depicts where the nasal fossa crosses the maxillary sinus. The boundary between them is shaped like an upside-down letter Y, hence its name. The periapicals below demonstrate the inverted Y, a classic radiographic landmark of the right and left anterior maxilla. The fossa is positioned toward the midline while the sinus extends toward the posterior aspect of the maxilla. Typically, the inverted Y sits apical to the maxillary lateral incisor and canine teeth. No comparable structures are found in the mandibular lateral incisor and canine areas which differentiates maxillary from mandibular anterior periapicals.

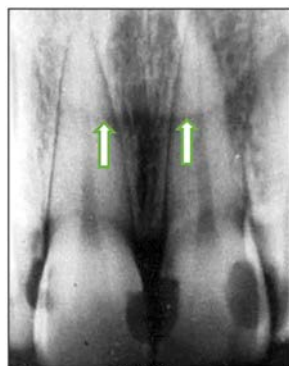


Maxillary right lateral-canine periapical

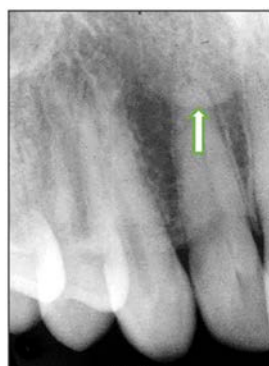

Maxillary left lateral-canine periapical

**Nasal soft tissue** – The soft tissue of the nose, including the tip and ala (corner of the nose), often can be seen superimposed over the roots of the teeth on anterior periapicals. The nasal soft tissue appears radiopaque.



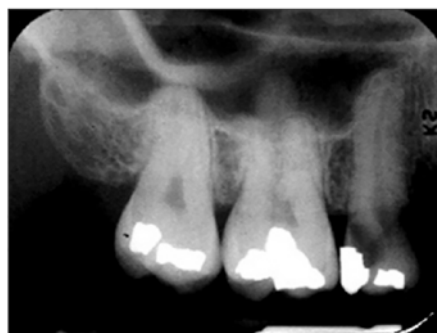Tip of Nose



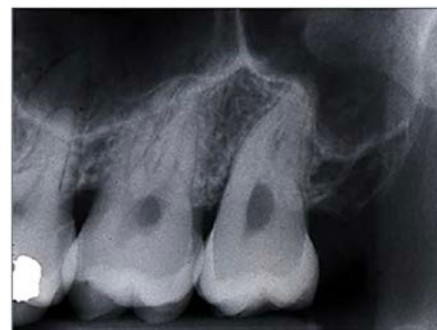Ala of Nose

### **Maxillary Posterior Landmarks**

**Maxillary sinus** – The maxillary sinus is one of the paired paranasal sinuses. This prominent radiolucent air-filled cavity is located above the posterior teeth on the right and left sides of the maxilla. The sinus cavities are horizontally oblong bilateral structures with fine radiopaque borders. The maxillary sinus may contain septa which appear as radiopaque lines within the body of the sinus cavity. The size of the maxillary sinus can be quite variable and sometimes encroaches into the alveolar process, especially when posterior teeth are missing. Typically, the sinus appears uniform right to left. The maxillary sinus is sometimes referred to as the maxillary antrum and can be observed on both maxillary premolar and molar periapicals and partially on lateral-canine periapicals.

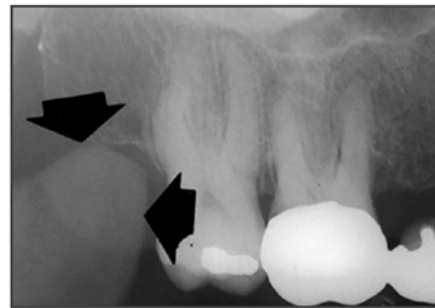
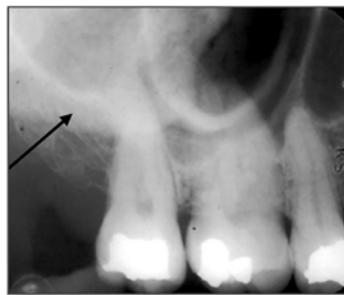
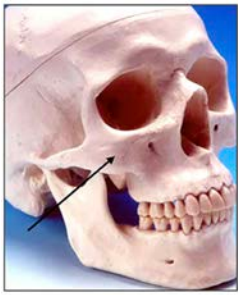


Maxillary right molar periapical

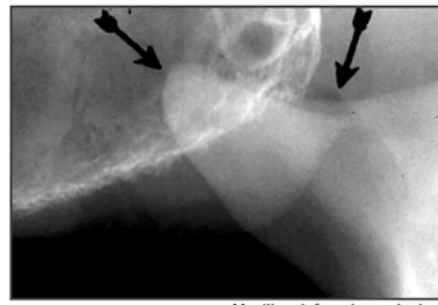


Maxillary left molar periapical

**Zygomatic bone** – The zygomatic bone or cheek bone attaches to the right and left sides of the posterior maxilla. The zygomatic bone, quadrangular in shape, broadens as it extends posteriorly. This bilateral radiopaque structure is also known as the malar bone. The zygomatic bone can be seen on maxillary premolar and molar periapicals.

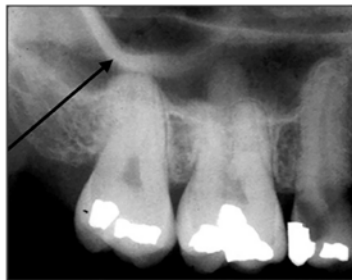
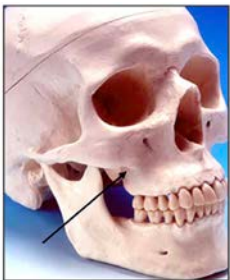

Maxillary right molar periapical



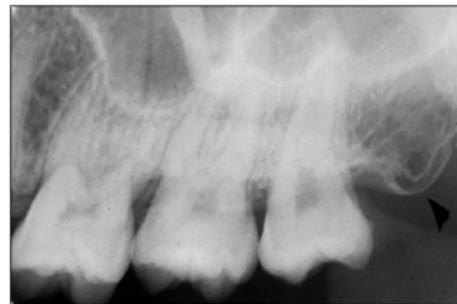Maxillary left molar periapical

**Zygomatic process** - The zygomatic process is the radiopaque U-shaped structure representing where the zygomatic bone attaches to the maxilla. The zygomatic process of the maxilla is the most anterior aspect of the zygomatic bone. The process is positioned toward the midline while the bone extends posteriorly away from the midline. This structure is sometimes referred to as the malar process and can be seen on maxillary premolar and molar periapicals.



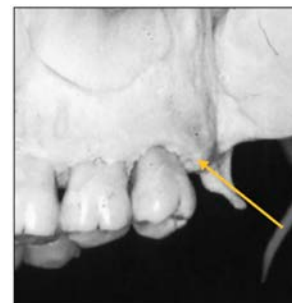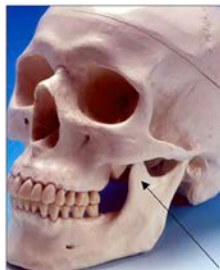Maxillary right molar periapical

**Maxillary tuberosity** – The maxillary tuberosity is the rounded end of the alveolar process of the maxilla. This radiopaque structure appears bilaterally on maxillary molar periapicals and often on maxillary premolar periapicals and molar bitewings. The tuberosity curves upward at the end of the maxillary alveolar process. The tuberosity gives a smile appearance to the maxilla and the dentition particularly on bitewings.

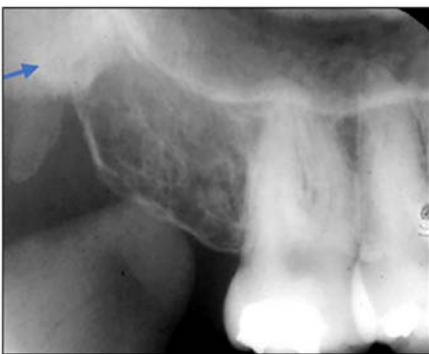
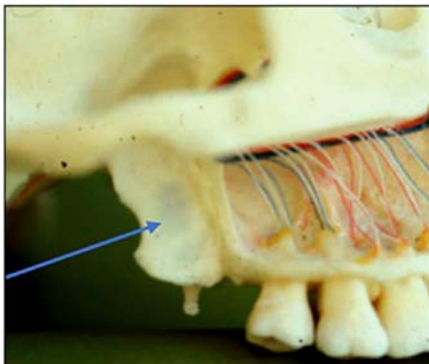


Maxillary left molar periapical

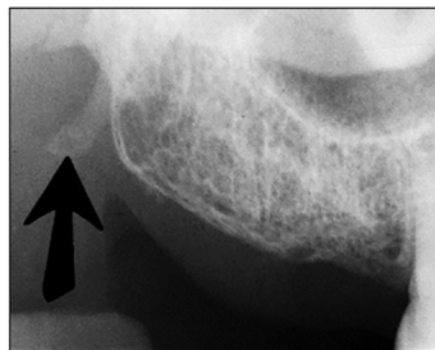
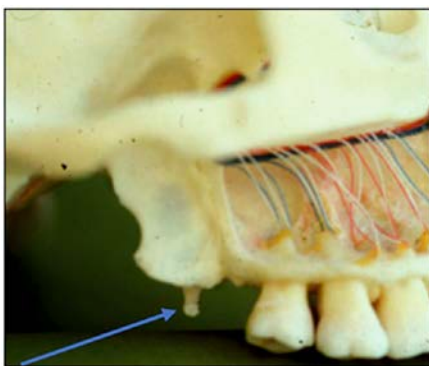
**Coronoid process** – The coronoid process of the mandible is the triangular bony portion of the anterosuperior aspect of the ramus. This mandibular structure can be recorded on maxillary molar periapicals as the ramus moves forward when the patient's mouth is open. It appears as a bilateral triangular or thumb-like radiopacity on posterior maxillary images. The triangular portion projects forward toward the midline. The coronoid process is the only mandibular structure recorded on maxillary molar periapicals.



**Pterygoid plates** – The lateral and medial pterygoid plates are located behind the maxillary tuberosity. They project a single image configured like a thin wing of bone extending posteriorly from the tuberosity. This bilateral radiopacity is occasionally recorded on maxillary molar periapicals when the receptor is positioned adequately posterior.



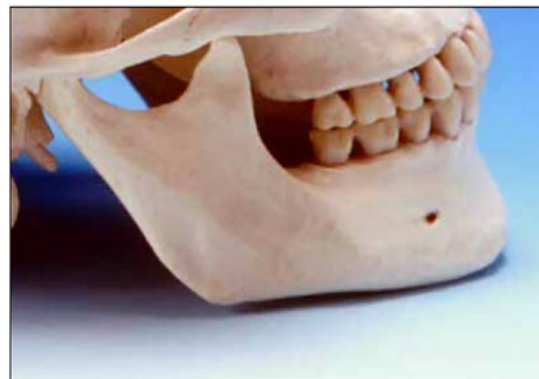**Hamular process** – The hamular process or pterygoid hamulus is a tiny finger or hook-like projection of bone that extends inferiorly from the medial pterygoid plate. This bilateral radiopacity occasionally appears on maxillary molar periapicals and molar bitewings when the receptor is positioned sufficiently posterior to record it.



### **Summary of Maxillary Landmarks** (See Table 1)

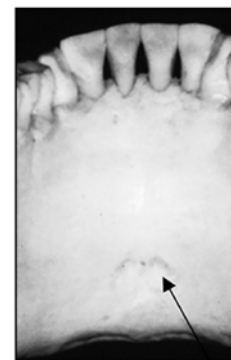
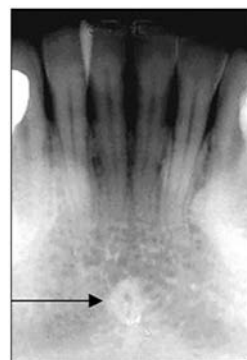
### **Mandibular Anatomical Landmarks**

The mandible is the lower dental arch that contains the mandibular alveolar process, the mandibular teeth and consists of the body (horizontal aspect) and ramus (posterior vertical aspect) intersecting at the angle.



### **Mandibular Anterior Landmarks**

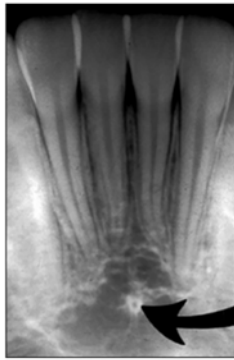
**Genial tubercle** – The genial tubercle is a spiny protuberance or prominence (sometimes two) of bone located in the midline on the lingual aspect of the mandible below the roots of the incisor teeth. This structure serves as the locus of attachment for the genioglossus





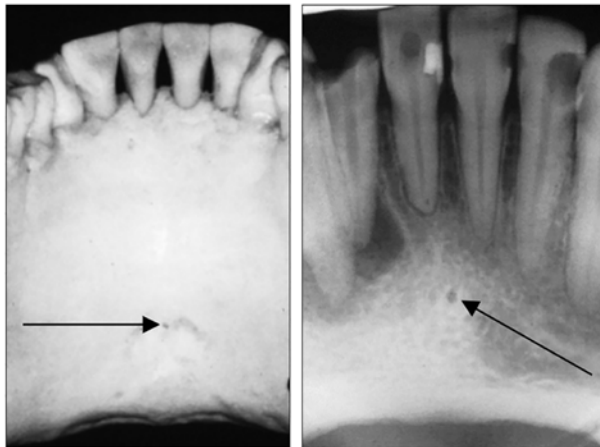
**Table 1. Summary of Maxillary Radiographic Landmarks.**

Landmark	Brief Description	Radiolucent / Radiopaque	Periapical	Bilateral / Unilateral	Alternate Name
<b>Anterior Nasal Spine</b>	Triangular Point	Radiopaque	Central Incisor	Unilateral	
<b>Coronoid Process</b>	Triangular	Radiopaque	Molar	Bilateral	
<b>Hamular Process</b>	Finger-like	Radiopaque	Molar	Bilateral	Pterygoid Hamulus
<b>Incisive Foramen</b>	Round/Oval	Radiolucent	Central Incisor	Unilateral	Nasopalatine Foramen
<b>Inferior Nasal Concha</b>	Round/Oval	Radiopaque	Central Incisor	Bilateral	Inferior Nasal Turbinate
<b>Inverted Y</b>	Upside-down Y	Radiopaque	Lateral Incisor Canine	Bilateral	
<b>Lateral Fossa</b>	Diffuse	Radiolucent	Lateral Incisor	Bilateral	Canine Fossa
<b>Maxillary Sinus</b>	Horizontally Oblong	Radiolucent	Premolar / Molar	Bilateral	Maxillary Antrum
<b>Maxillary Tuberosity</b>	Rounded	Radiopaque	Molar	Bilateral	
<b>Mid-palatine Suture</b>	Vertical line	Radiolucent	Central Incisor	Unilateral	Median Palatal Suture
<b>Nasal Fossa</b>	Vertically Oblong	Radiolucent	Central Incisor Lateral Incisor Canine	Bilateral	Nasal Cavity
<b>Nasal Septum</b>	Vertical Band	Radiopaque	Central Incisor	Unilateral	
<b>Pterygoid Plates</b>	Wing of Bone	Radiopaque	Molar	Bilateral	
<b>Zygomatic Bone</b>	Quadrangular-shaped	Radiopaque	Premolar / Molar	Bilateral	Malar Bone
<b>Zygomatic Process</b>	U-shaped	Radiopaque	Premolar / Molar	Bilateral	Malar Process

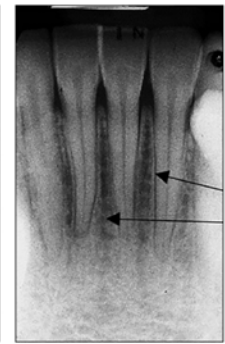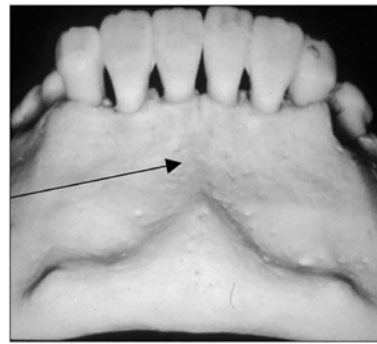


and geniohyoid muscles. Although variable in appearance, the tubercle often produces a ring-like or doughnut-shaped radiopacity on mandibular incisor periapicals. The genial tubercle is also referred to as the mental spine.

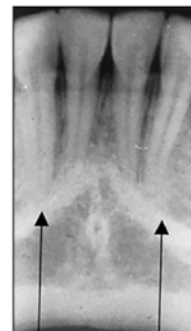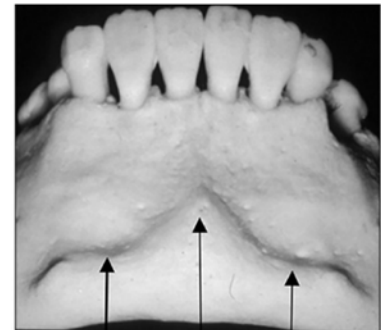
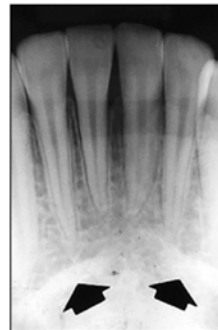**Lingual foramen** – The lingual foramen is a small pin-point opening in bone on the lingual aspect of the anterior mandible for the lingual nerve and arteries. The lingual foramen appears in the midline below the apices of the central incisor teeth. This dot-like radiolucency is frequently surrounded by the genial tubercle. The lingual foramen is recorded on mandibular incisor periapicals.



**Mental fossa** – The mental fossa is a depression in the bone on the labial aspect of the mandible. It has a diffuse radiolucent appearance above the mental ridge. The mental fossa varies in its prominence depending on the thickness and density of the anterior mandible.



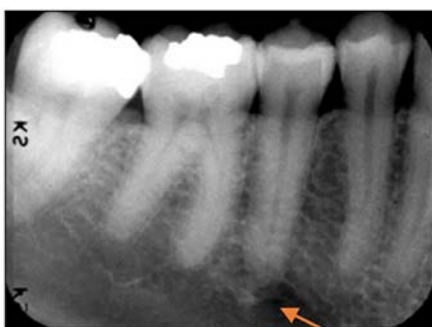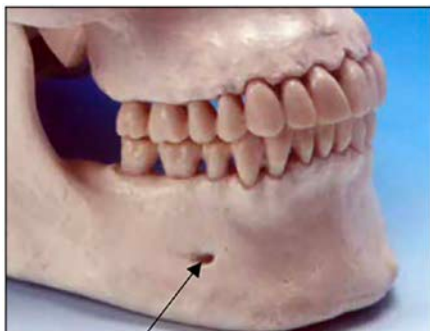
**Mental ridge** – The mental ridge is a prominence of bone on the labial surface of the anterior mandible. This structure presents as an inverted V-shaped radiopaque ridge that extends from the premolar to canine area on each side meeting in the midline. The mental ridge varies in its presentation with some individuals displaying very distinct ridge anatomy while others, little or no evidence of its presence. This mandibular landmark can be recorded on incisor and partially on the lateral aspect of canine periapicals.



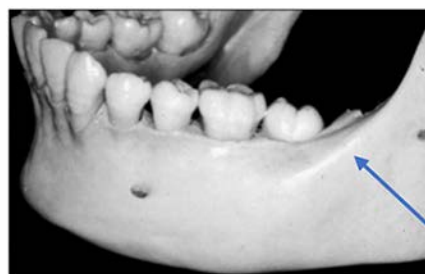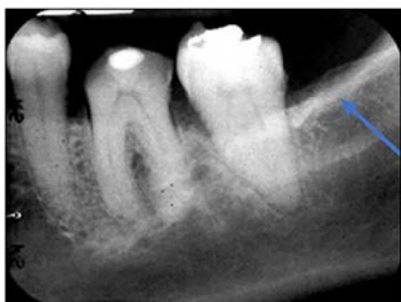### **Mandibular Posterior Landmarks**

**Mental foramen** – The mental foramen, the primary landmark of this area, is a circular radiolucent structure located below the roots of the mandibular premolar teeth.

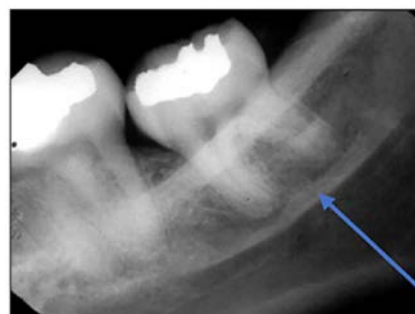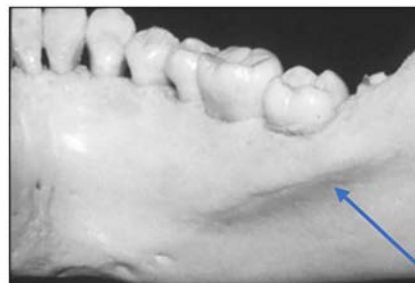This structure is the opening for passage of the mental nerve and vessels and can be observed on mandibular premolar and the lateral aspect of canine periapicals. This bilateral radiolucency can be misinterpreted as a periapical lesion. However, it is easily differentiated upon closer examination of the tooth and its supporting structures.



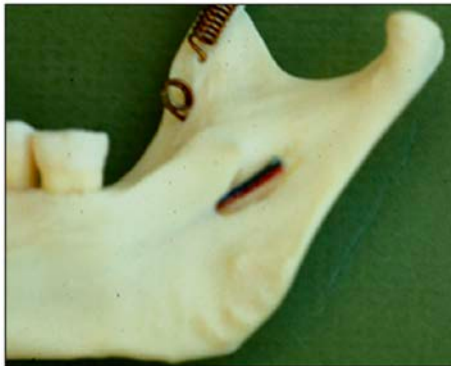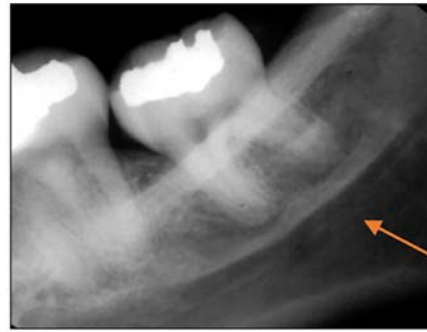
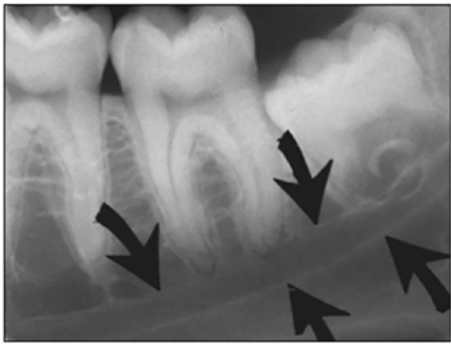
**External oblique ridge** – The external oblique ridge or line is the bony anterior border of the ramus located on the outer aspect of the mandible. This ridge has a downward diagonal course and is seen on most mandibular molar periapicals and molar bitewings. It is more prominent and appears more frequently than the internal oblique ridge which will be discussed next. This bilateral radiopaque landmark gives the mandible and the dentition a smile appearance.



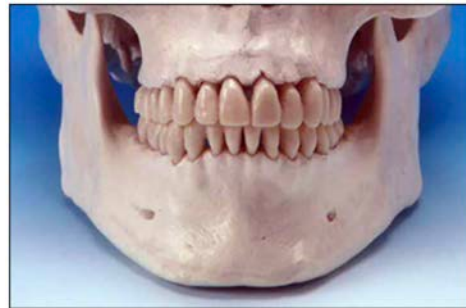
**Internal oblique ridge** - The internal oblique ridge is the bony ridge found bilaterally on the lingual aspect of the posterior mandible. This radiopaque ridge is variable in its appearance ranging from highly defined to barely visible. When recorded on molar periapicals, it runs parallel to but below the external oblique ridge. The internal oblique ridge is sometimes referred to as the mylohyoid line.



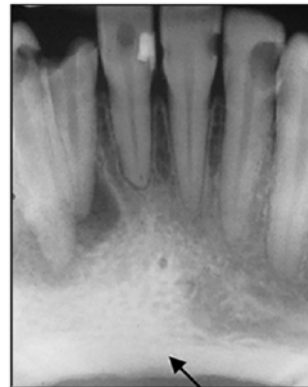
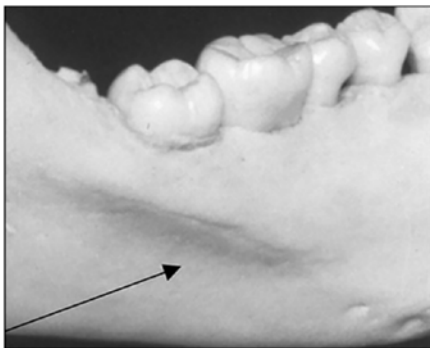
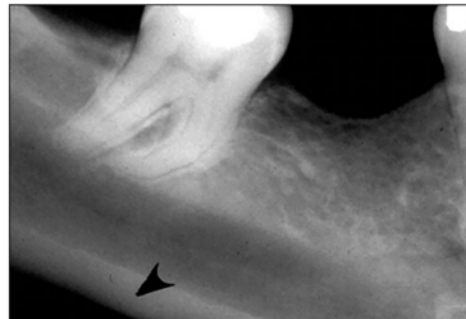
**Mandibular canal** – The mandibular canal is the pathway in bone where the inferior alveolar nerve and blood vessels course through the mandible. The canal extends from the mandibular foramen (This foramen is not recorded on mandibular periapicals.) within the ramus anteriorly to the mental foramen. This tubular bilateral radiolucency often demonstrates fine radiopaque boundaries. The mandibular canal is recorded on mandibular premolar and molar periapicals. It is also referred to as the inferior alveolar nerve canal.



**Lower border** – The lower border of the mandible appears as a radiopaque band of dense cortical bone demarcating the inferior aspect of the mandible. This structure can be observed on any mandibular periapical view, especially when the x-ray beam angulation is excessive.



**Submandibular fossa** – The submandibular fossa is a depression in bone on the lingual aspect of the posterior mandible. The fossa is located bilaterally below the internal oblique ridge or mylohyoid line. This concavity is where the submandibular salivary gland rests. The submandibular fossa presents as a diffuse bilateral radiolucency typically with few trabeculae. It can appear unusually radiolucent, enticing the novice clinician into thinking a bony lesion is present. The submandibular fossa is recorded on premolar and molar periapicals. This structure is also referred to as the submandibular gland fossa or mandibular fossa.





## Summary of Mandibular Landmarks

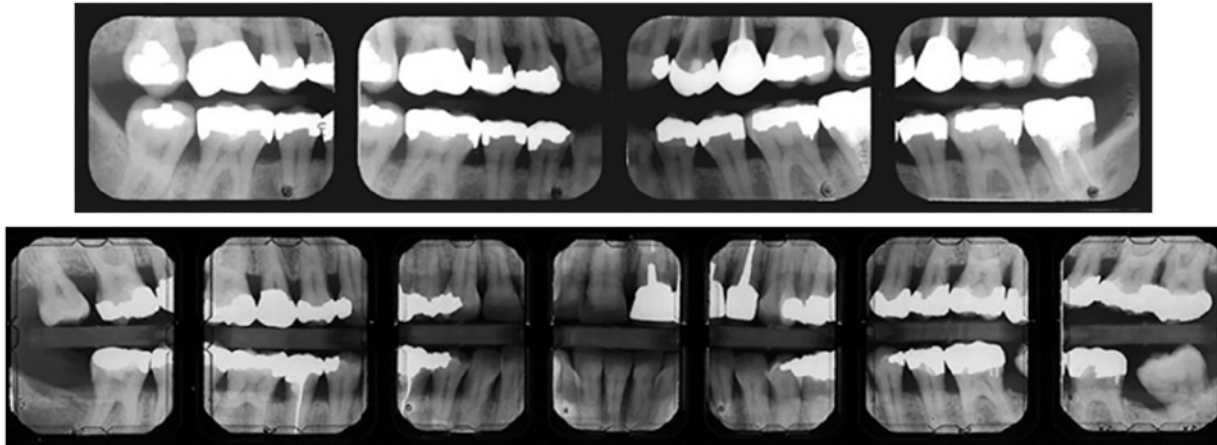
**Table 2. Summary of Mandibular Radiographic Landmarks.**

Landmark	Brief Description	Radiolucent / Radiopaque	Periapical	Bilateral / Unilateral	Alternate Name
<b>External Oblique Ridge</b>	Diagonal Line	Radiopaque	Molar	Bilateral	Exteranal Oblique Line
<b>Genial Tubercle</b>	Doughnut-shaped	Radiopaque	Central Incisor	Unilateral	Mental Spine
<b>Inferior Border of Mandible</b>	Horizontal Band	Radiopaque	Any Mandibular	Bilateral	Lower Border
<b>Internal Oblique Ridge</b>	Diagonal Line	Radiopaque	Molar	Bilateral	Mylohyoid Line
<b>Lingual Foramen</b>	Pinpoint dot	Radiolucent	Central Incisor	Bilateral	
<b>Mandibular Canal</b>	Tubular	Radiolucent	Premolar Molar	Bilateral	Inferior Alveolar Nerve Canal
<b>Mental Foramen</b>	Circular	Radiolucent	Premolar Canine	Bilateral	
<b>Mental Fossa</b>	Diffuse	Radiolucent	Central Incisor	Unilateral	
<b>Mental Ridge</b>	Inverted V	Radiopaque	Central Incisor Lateral Incisor Canine	Bilateral	
<b>Submandibular Fossa</b>	Diffuse	Radiolucent	Premolar Molar	Bilateral	Submandibular Gland Fossa Mandibular Fossa

## Review of Landmarks on Surveys

### ***Bitewing Surveys***

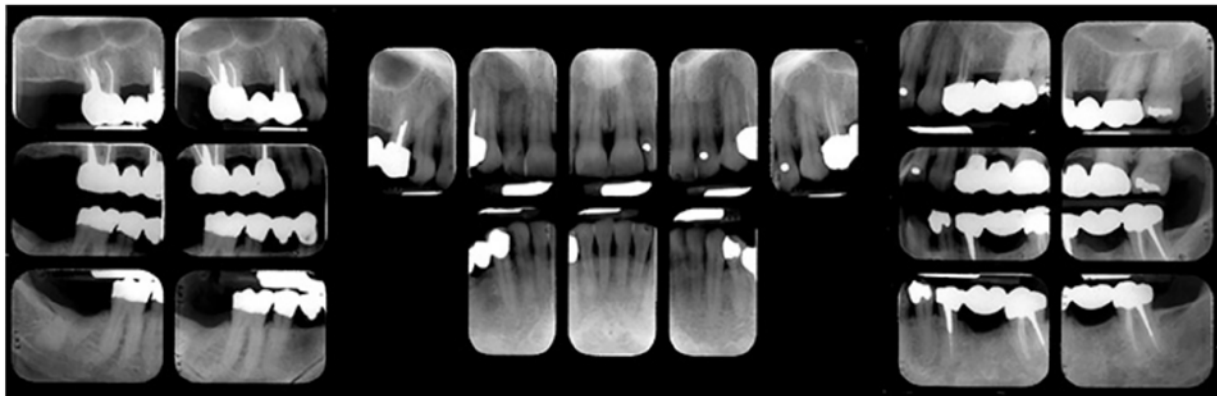
There are several landmarks recorded on molar bitewing radiographs whether vertical or horizontal in orientation. The most common structures observed are the external oblique ridge and maxillary tuberosity.



### ***Full Mouth Surveys***

The full mouth surveys below exhibit many of the anatomical structures presented in this course. Examine each survey to identify which structures are present.

#### **Full Mouth Survey #1**



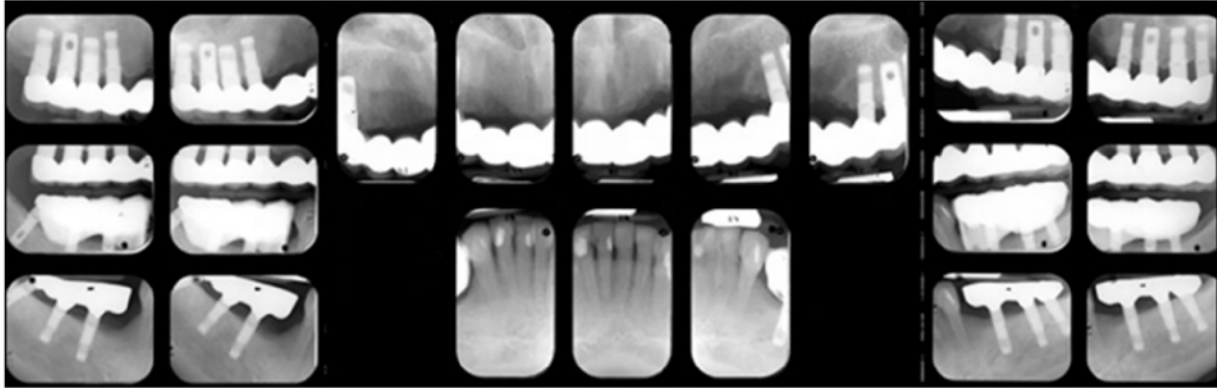
#### **Visible Structures**

**Maxilla:** zygomatic bone, zygomatic process, maxillary sinus, maxillary tuberosity, inverted Y, lateral fossa, incisive foramen, nasal soft tissue, mid-palatine suture

**Bitewings:** maxillary tuberosity, external oblique ridge

**Mandible:** external oblique ridge, mandibular canal, mental foramen, mental ridge, genial tubercle, lingual foramen

### Full Mouth Survey #2



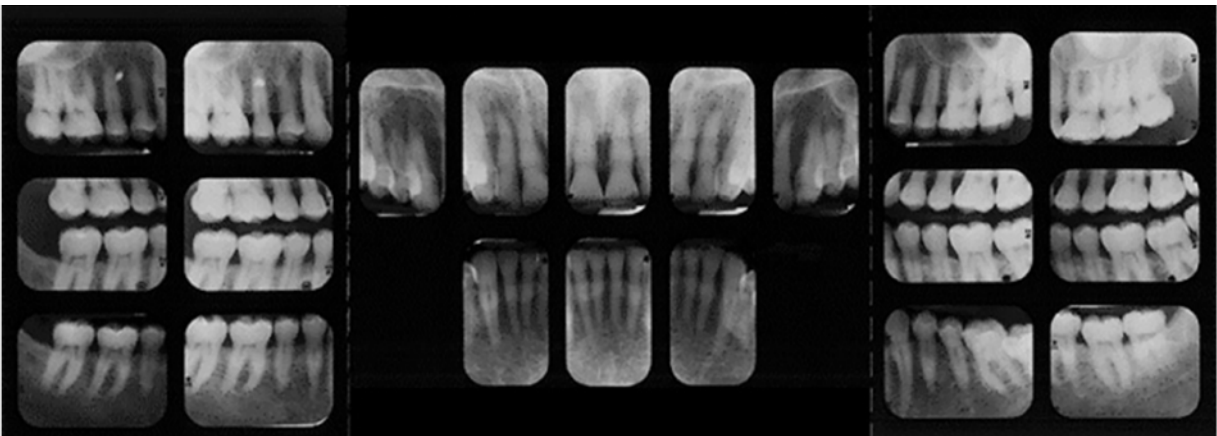
#### Visible Structures

**Maxilla:** zygomatic bone, zygomatic process, maxillary sinus, maxillary tuberosity, inverted Y, nasal concha, nasal fossa, nasal septum, nasal soft tissue, anterior nasal spine, incisive foramen

**Bitewings:** external oblique ridge

**Mandible:** external oblique ridge, mandibular canal, inferior border of the mandible, mental foramen, mental ridge, genial tubercle, lingual foramen

### Full Mouth Survey #3



#### Visible Structures

**Maxilla:** zygomatic bone, zygomatic process, maxillary sinus, maxillary tuberosity, pterygoid plates, coronoid process, inverted Y, nasal fossa, nasal soft tissue, lateral fossa, anterior nasal spine, incisive foramen

**Bitewings:** external oblique ridge

**Mandible:** external oblique ridge, internal oblique ridge (faint), mandibular canal, submandibular fossa, mental foramen, mental fossa, genial tubercle, lingual foramen

## Summary

Radiographic interpretation is predicated on the recognition of normal anatomical landmarks. It is important for the clinician to verify accurate image orientation and

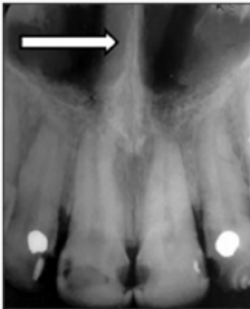
survey arrangement before interpretation is undertaken. Knowledge of anatomical structures is foundational to differentiation between normal structures and abnormalities.



## Course Test Preview

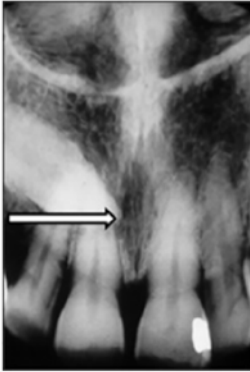
To receive Continuing Education credit for this course, you must complete the online test. Please go to: [www.dentalcare.com/en-us/professional-education/ce-courses/ce601/test](http://www.dentalcare.com/en-us/professional-education/ce-courses/ce601/test)

1. **What is the ADA's standard for viewing and interpreting intraoral radiographic images?**
  - A. Labial mounting
  - B. Lingual mounting
  - C. Patient orientation
  - D. External orientation
2. **Structures that appear radiopaque on radiographic images \_\_\_\_\_.**
  - A. allow passage of x-rays
  - B. absorb x-ray beam energy
  - C. represent openings in bone
  - D. appear as dark or black areas
3. **What is the structure identified by the arrow on this periapical image?**

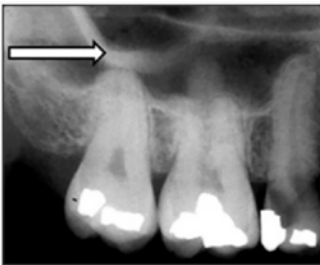

- A. Nasal fossa
  - B. Nasal spine
  - C. Nasal septum
  - D. Nasal concha
4. **Which anatomical structure fits the description, thin vertical linear radiolucency?**
  - A. Lateral fossa
  - B. Nasal soft tissue
  - C. Incisive foramen
  - D. Mid-palatine suture

5. What is a common alternate name for the structure identified by the arrow on this periapical?



- A. Lingual foramen
  - B. Anterior foramen
  - C. Nasopalatine foramen
  - D. Median palatal foramen
6. What structure represents a depression in bone on the labial aspect of the maxilla?
- A. Nasal spine
  - B. Lateral fossa
  - C. Incisive canal
  - D. Inferior concha
7. Which structure is the classic radiographic landmark of the maxillary canine-lateral region?
- A. Tuberosity
  - B. Inverted Y
  - C. Nasal septum
  - D. Zygomatic bone
8. What is the prominent radiolucent structure of the posterior maxilla?
- A. Maxillary tuberosity
  - B. Pterygoid hamulus
  - C. Zygomatic bone
  - D. Maxillary sinus
9. What is the structure identified by the arrow on this posterior periapical?



- A. Maxillary tuberosity
- B. Zygomatic process
- C. Coronoid process
- D. Border of sinus

**10. What mandibular structure is recorded on maxillary molar periapicals?**

- A. Internal oblique ridge
- B. Submandibular fossa
- C. Mandibular condyle
- D. Coronoid process

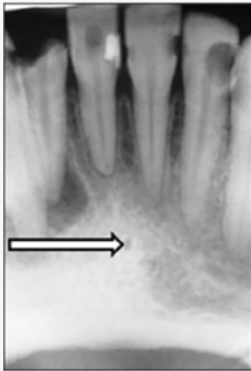
**11. The hamular process is part of which structure?**

- A. Medial pterygoid plate
- B. Lateral pterygoid plate
- C. Maxillary tuberosity
- D. Zygomatic bone

**12. What term is an alternate name for the genial tubercle?**

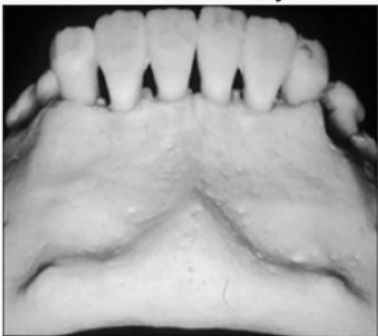
- A. Lingual prominence
- B. Incisive tubercle
- C. Mandibular spur
- D. Mental spine

**13. What structure is identified by the arrow on this periapical image?**



- A. Lingual foramen
- B. Genial tubercle
- C. Inferior border
- D. Mental fossa

**14. What structure is clearly demonstrated on the lower third of this photograph?**

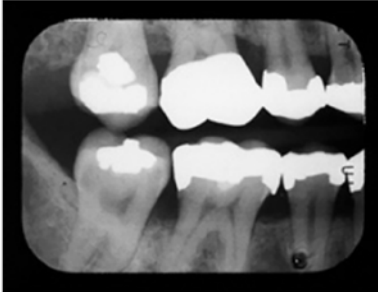


- A. Mylohyoid line
- B. Lateral fossa
- C. Mental ridge
- D. Inverted Y

**15. What structure is the primary landmark for the mandibular premolar area?**

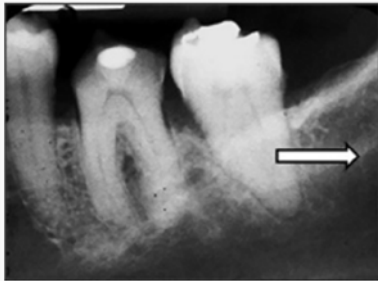
- A. Internal oblique ridge
- B. Submandibular fossa
- C. Mandibular border
- D. Mental foramen

**16. Which anatomical landmark is recorded on this molar bitewing view?**



- A. External oblique ridge
- B. Mandibular canal
- C. Zygomatic bone
- D. Mylohyoid line

**17. What is the structure identified by the arrow on this periapical image?**



- A. External oblique ridge
- B. Internal oblique ridge
- C. Mandibular ridge
- D. Mental ridge

**18. Each of the following foramina are recorded on intraoral periapicals except one. Which is the exception?**

- A. Mental
- B. Lingual
- C. Incisive
- D. Mandibular

**19. Which structure would match the description, tubular radiolucency with fine radiopaque borders?**

- A. Coronoid process of the mandible
- B. Inferior border of the mandible
- C. Inferior alveolar nerve canal
- D. Submandibular fossa



**20. What structure is housed within the submandibular fossa?**

- A. Submandibular salivary gland
- B. Sublingual salivary gland
- C. Inferior alveolar nerve
- D. Mylohyoid muscle

## References

1. Iannucci JM, Howerton LJ. Dental Radiography Principles and Techniques, 4th ed. St. Louis, MO. Elsevier Saunders. 2012.
2. Koenig LJ, Tamimi DF, Petroski CG, et al. Diagnostic Imaging: Oral and Maxillofacial, 2nd Ed. Salt Lake City, UT. Elsevier. 2017.
3. Miles DA, Van Dis ML, Williamson GF, et al. Radiographic Imaging for the Dental Team, 4th Ed. St. Louis, MO. Elsevier Saunders. 2009.
4. Parks ET, Williamson GF. Digital radiography: an overview. J Contemp Dent Pract. 2002;3(4):23–39. Published 2002 Nov 15.
5. White SC, Pharoah MJ. Oral radiology: Principles and interpretation, 7th ed. St. Louis, MO. Elsevier Mosby. 2014.

## Additional Resources

- No Additional Resources Available.

## About the Author

### Gail F. Williamson, RDH, MS



Gail F. Williamson is Professor Emerita of Dental Diagnostic Sciences in the Department of Oral Pathology, Medicine and Radiology at Indiana University School of Dentistry in Indianapolis, Indiana. A veteran teacher, Prof. Williamson has received numerous awards for teaching excellence during her academic career including the 2013 Outstanding Teacher of the Year Award from the Indiana University School of Dentistry and the 2018 Gordon J. Christensen Lecturer Recognition Award from the Chicago Dental Society. She is a co-author of several Radiology textbooks and author/co-author of multiple book chapters, journal articles and continuing education monographs. She has held leadership positions in several professional organizations including service as Councilor for Academy Affairs, Associate Executive Director and Executive Director of the American Academy of Oral and Maxillofacial Radiology. She presents continuing education courses on topics in oral and maxillofacial radiology nationally.

Email: [gwilliam@iu.edu](mailto:gwilliam@iu.edu)