

# Local Anesthesia in Pediatric Dentistry



**Course Author(s):** Jayakumar Jayaraman, BDS, MDS, FDSRCS, MS, PhD;

**CE Credits:** 2 hours

**Intended Audience:** Dentists, Dental Hygienists, Dental Assistants, Dental Students, Dental Hygiene Students, Dental Assisting Students

**Date Course Online:** 09/01/2008

**Last Revision Date:** 02/10/2025

**Course Expiration Date:** 02/09/2028

**Cost:** Free

**Method:** Self-instructional

**AGD Subject Code(s):** 340, 430

**Online Course:** [www.dentalcare.com/en-us/ce-courses/ce325](http://www.dentalcare.com/en-us/ce-courses/ce325)

## Disclaimers:

- P&G is providing these resource materials to dental professionals. We do not own this content nor are we responsible for any material herein.
- Participants must always be aware of the hazards of using limited knowledge in integrating new techniques or procedures into their practice. Only sound evidence-based dentistry should be used in patient therapy.

## Conflict of Interest Disclosure Statement

- Dr. Jayakumar Jayaraman reports no conflicts of interest associated with this course. He has no relevant financial relationships to disclose.

## Acknowledgement

We would like to acknowledge Dr. Steven Schwartz for his contributions to previous iterations of this course. Dr. Schwartz passed away on October 25, 2018. His impact on dental professionals through CE courses such as this one is appreciated and will be missed.

## Introduction - Local Anesthesia

This free continuing education course will teach the clinician how to administer an effective, and safe local anesthesia injection to a child or an adult.

## Course Contents

- Overview
- Learning Objectives
- Introduction
- Definition and Properties of Local Anesthetics
  - Topical Anesthetics
  - Injectable Local Anesthetics
- Injectable Local Anesthetic Agents
- Pre-administration Protocol
  - Local Anesthesia and Pregnancy
  - Local Anesthesia with Sedation, General Anesthesia, and/or Nitrous Oxide/oxygen Analgesia/anoxiolysis
- Armamentarium
  - Cartridge
  - Needles
  - Syringe (Cartridge Holder)
  - Topical Anesthetic
- Preparation of Patient
- Administration Protocol
  - Positioning the Patient in the Dental Chair
  - Drying the Tissue
  - Applying Topical Anesthetic
  - Administration of the Anesthetic
    - Stabilization
    - Communication
    - Basic Injection Technique
- Specific Injection Techniques
  - Inferior Alveolar Nerve Block
  - Lingual Nerve Block
  - Supraperiosteal Injections (Local Infiltration)
  - Technique to Supplement Block Anesthesia
  - Local Infiltration of the Maxillary Primary and Permanent Incisors and Canines
  - Anesthetization of the Maxillary Primary Molars and Premolars
  - Posterior Superior Alveolar Nerve Block
  - Anesthetization of the Palatal Tissues
  - Nasopalatine Nerve Block
  - Greater Palatine Nerve Block
  - Local Infiltration of the Palate
- Supplemental Injection Techniques
- Complications of Local Anesthesia
- Conclusion
- Course Test
- References
- About the Author

## Overview

One of the most important and challenging aspects of child behavior management is the control of pain. This course will teach the clinician how to administer an effective, and safe local anesthesia injection to a child or an adult.

## Learning Objectives

**Upon completion of this course, the dental professional should be able to:**

- Define local anesthesia and the properties of local anesthetic agents.
- Calculate appropriate child weight dosages of topical and injectable local anesthetic agents.
- List contraindications for local anesthesia.
- Discuss drug-to-drug interactions.
- Explain medical considerations in administering local anesthetic agents.
- List armamentarium for local anesthesia administration.
- Describe preparation of the pediatric patient prior to injection.
- Describe techniques for block, infiltration, palatal, and intraligamentary anesthesia.
- Manage local anesthesia complications.

## Introduction

One of the most important and challenging aspects of child behavior management is the control of pain. Children who undergo early painful experiences during dental procedures are likely to carry negative feelings toward dentistry into adulthood. Therefore, it is important that clinicians make every effort to minimize pain and discomfort during dental treatment.

Dentists commonly use local anesthetics and/or analgesics to control pain because of the likelihood of the pediatric dental patient experiencing discomfort during restorative and surgical procedures. The simplest and most effective method of reducing pain during dental procedures is via an injection of local anesthetic. Unfortunately, the anticipation of receiving a “needle shot” tends to increase anxiety in the pediatric and adult patient and similarly in the dentist who has the task of minimizing discomfort during the injection process. Most adults are willing to subject themselves to the minor discomfort of the injection because they

can envision the comfort they will experience during restorative and surgical procedures. Unfortunately, younger children do not have the ability to do this and thus may exhibit negative behavior before, during and after the injection process. Many dentists, wishing to circumvent such negative behavior, forego administering local anesthesia for restorative treatment especially in primary teeth. However, there are times when an anticipated “minor” procedure becomes a major procedure, and the patient is placed in a painful situation because of the lack of dental anesthesia. Local anesthesia can prevent discomfort associated procedures like placing a rubber dam clamp, tooth preparation, pulp therapy and extraction.

There are very few contraindications for the use of local anesthesia in children during dental procedures. However, when administering a local anesthetic to a child, the clinician should be aware of the possibilities of anesthetic overdose, self-induced traumatic injuries related to prolonged duration of soft tissue anesthesia and technique variations related to the smaller anatomical structures in pediatric patients.

The goal of this course is to familiarize the dentist and dental auxiliaries with effective and safe techniques for the administration of local anesthesia in the pediatric dental patient. For the most comprehensive source of information on local anesthesia, please refer to the references provided for this course.

### **Definition and Properties of Local Anesthetics**

Local anesthesia is the temporary loss of sensation or pain in one part of the body produced by a topically applied or injected agent without depressing the level of consciousness.<sup>1</sup>

Dental anesthetics fall into two groups: esters (procaine, benzocaine) and amides (lidocaine, mepivacaine, prilocaine and articaine). Esters are no longer used as injectable anesthetics; however, benzocaine is used as a topical anesthetic. Amides are the most commonly used injectable anesthetics with lidocaine also used as a topical anesthetic.

### **Topical Anesthetics**

Topical anesthetics are effective to a depth of 2-3mm and are effective in reducing the discomfort of the initial penetration of the needle into the mucosa. Although flavored topical anesthetics are currently available, it may be still disagreeable to patient and the length of application time may increase apprehension in some pediatric patient. Topical anesthetics are available in gel, liquid, ointment, patch and pressurized spray forms. When applying topical anesthetics to the soft tissue, use the smallest effective amount to avoid anesthetizing soft palate and pharyngeal tissues.

The most common topical anesthetics used in dentistry are those with benzocaine or lidocaine.

### **Benzocaine**

Ethyl aminobenzoate (benzocaine) is an ester local anesthetic. It is available in up to 20% concentrations. It is poorly absorbed into cardiovascular system. It remains at the site of application longer, providing a prolonged duration of action. Localized allergic reactions may occur following prolonged or repeated use, and it is reported to inhibit the antibacterial action of sulfonamides.

It is not known to produce systemic toxicity in adults but can produce local allergic reactions. The Food and Drug Administration (FDA) has raised concern regarding the use of benzocaine and compounded topical anesthetics containing mixture of amides and esters.<sup>2</sup> This compound may cause methemoglobinemia, a rare but serious and potentially fatal condition. Children younger than 2 years appear to be at particular risk. In the most severe cases, methemoglobinemia can result in death. Patients who develop methemoglobinemia may experience signs and symptoms such as pale, gray or blue colored skin, lips and nail beds; headache; lightheadedness; shortness of breath; fatigue; and rapid heart rate.

Most of the cases reported were in children younger than 2 years who were treated with topical benzocaine gels for the relief of teeth pain, hence it is preferable to avoid in this age group. The signs and symptoms can occur after a single application or multiple applications and can begin within minutes and hours of application.

## Lidocaine

Lidocaine is available as a solution or ointment up to 5% and as a spray up to 10% concentration. It has a low incidence of allergic reactions but is absorbed systemically and can combine with an injected amide local anesthetic to increase the risk of overdose. A metered spray is suggested if an aerosol preparation is selected.

Systemic absorption of a lidocaine topical anesthetic must be considered when calculating the total amount of anesthetic administered.

## Injectable Local Anesthetics

Local anesthetics create a chemical roadblock between the source of pain and the brain by interfering with the ability of a nerve to transmit electrical signals or action potentials. The local anesthetic blocks the operation of a specialized gate called the sodium channel. When the sodium channel of a nerve is blocked, the nerve signals cannot be transmitted. The only location at which the local anesthetic molecules have access to the nerve membrane is at the nodes of Ranvier, where there is an abundance of sodium channels. The interruption of a nerve signal in a myelinated nerve such as a dental nerve occurs when nerve depolarization or nerve signal is blocked at three consecutive nodes of Ranvier.

Local anesthetics are vasodilators and are eventually absorbed into the circulation. They have systemic effects that are directly related to their blood plasma level. Overdose with local anesthetics can result in Central Nervous System CNS depression, convulsions, elevated heart rate, and blood pressure.

Vasoconstrictors (epinephrine, levonordefrin, norepinephrine) are added to local anesthetics to counteract the vasodilatory action, slowing the removal of the anesthetic from the area of the nerve and thus prolonging its action. Different anesthetics have different rates of onset of symptoms and duration of action. The more acidic a local anesthetic solution is the slower the onset of action. The more closely the equilibrium pH for a given anesthetic approximates physiologic pH, the more rapid

the onset of anesthetic action. The better the local anesthetic molecule binds to the protein in the nerve's sodium channel, the longer the duration of anesthesia. It is important to note if a local anesthetic is injected into an area of infection, its onset will be delayed or even prevented. The inflammatory process in an area of infection lowers the pH of the extracellular tissue from its normal value of 7.4 to 6 or lower. The low pH inhibits anesthetic action because little of the free base form of the anesthetic is allowed to cross into the nerve sheath to prevent conduction of nerve impulses.<sup>3</sup>

## Injectable Local Anesthetic Agents

Amide local anesthetics available for dental usage include lidocaine, mepivacaine, articaine, prilocaine and bupivacaine. They differ from each other in their duration of action (Table 1) and the maximum dosage that may be safely administered to patients (Table 2).

Table 1 demonstrates the variation in duration of action of injectable local anesthetics in minutes. There is variation in duration between anesthetics, pulp and soft tissue, and maxillary infiltration and mandibular blocks.<sup>4,5</sup>

The duration of injectable anesthesia for bupivacaine (180-600 minutes) is greater than lidocaine (90-200 minutes) and articaine (60-230 minutes). The prolonged time of duration of action increases the likelihood of self-inflicted, post-operative soft tissue injury and therefore the use of bupivacaine is not recommended in pediatric patients and those patients with special needs.<sup>4,5</sup>

Another difference among injectable anesthetic agents is the maximum recommended doses. This is extremely relevant in pediatric dentistry where there is a wide variation in weight between patients and thus not all patients should receive equal amounts of local anesthetic for the same procedure. Refer to Table 1 that summarizes the maximum recommended doses of local anesthetic agents as per the American Academy of Pediatric Dentistry (AAPD) Guidelines.

**Table 1. Duration of Injectable Local Anesthetics (in minutes).<sup>1</sup>**

Anesthetic	Duration in minutes <sup>A</sup>	Maximum dose <sup>B</sup>		mg anesthetic/ 1.7 mL cartridge	mg vasoconstrictor/ 1.7 mL cartridge
		mg/kg	mg/lb		
<i>Lidocaine</i> <sup>C</sup>	90-200	4.4	2		
2%+1:50,000 epinephrine				34	0.034 mg
2%+1:100,000 epinephrine				34	0.017 mg
<i>Articaine</i> <sup>D</sup>	60-230	7	3.2		
4%+1:100,000 epinephrine				68	0.017 mg
4%+1:200,000 epinephrine				68	0.0085 mg
<i>Mepivacaine</i>	120-240	4.4	2		
3% plain				51	—
2%+1:20,000 levonordefrin				34	0.085 mg
<i>Bupivacaine</i> <sup>E</sup>	180-600	1.3	0.6		
0.5%+1:200,000 epinephrine				8.5	0.0085 mg

**Table 2. Dosage of local anesthesia per cartridge<sup>4</sup>**

Local anesthetic	Maximum dose with Epinephrine <sup>a</sup> (mg/kg)		Maximum dose without Epinephrine (mg/kg)		Duration of action <sup>b</sup> (min)
	Medical	Dental	Medical	Dental	
<i>Esters</i>					
Procaine	10.0	6	7	6	60-90
Chloroprocaine	20.0	12	15	12	30-60
Tetracaine	1.5	1	1	1	180-600
<i>Amides</i>					
Lidocaine	7.0	4.4	4	4.4	90-200
Mepivacaine	7.0	4.4	5	4.4	120-240
Bupivacaine	3.0	1.3	2.5	1.3	180-600
Levobupivacaine <sup>c</sup>	3.0	2	2	2	180-600
Ropivacaine	3.0	2	2	2	180-600
Articaine <sup>d</sup>	—	7	—	7	60-230

Using the maximum recommended dosages (Table 2), one can calculate the maximum recommended dosage and amount of local anesthetic agent for patients of specific weight and type of anesthetic. For example:

To calculate the maximum amount of lidocaine 2% with 1:100,000 epinephrine and the number of cartridges that can be safely administered to a 30-pound patient, the clinician would perform the following calculations.

$$\begin{aligned} \text{Maximum Dosage (mg/lbs) X weight (lbs)} &= \\ \text{Maximum Total Dosage (mg)} & \\ 2.0 \times 30 &= 60 \text{ mgs} \end{aligned}$$

$$\begin{aligned} \text{Maximum Total Dosage (mg) } \div \text{ mg/cartridge} &= \\ \text{Maximum \# cartridges} & \\ 60 \div 36 &= 1.67 \text{ cartridges} \end{aligned}$$

Thus, for a 30-pound child one can safely administer 1.67 cartridges of lidocaine 2% with 1:100,000 epinephrine.

To calculate the maximum amount of mepivacaine 3% plain and the number of cartridges that can be administered to a 30-pound patient the clinician would perform the following calculations.

$$\begin{aligned} \text{Maximum Dosage (mg/lbs) X weight (lbs)} &= \\ \text{Maximum Total Dosage (mg)} & \\ 2.0 \times 30 &= 60 \text{ mgs} \end{aligned}$$

$$\begin{aligned} \text{Maximum Total Dosage (mg) } \div \text{ mg/cartridge} &= \\ \text{Maximum \# cartridges} & \\ 60 \div 54 &= 1.1 \text{ cartridge} \end{aligned}$$

Note the difference between the number of cartridges of lidocaine 2% and mepivacaine 3% that can be administered to a 30-pound child is due to the difference in the number of mg of anesthetic solution in a 1.8cc cartridge of anesthesia; lidocaine contains 36 mg and mepivacaine contains 54 mg. Thus the difference is due to varying concentration of the local anesthetic in the cartridge (1.8cc).

The maximum amount of local anesthetic agent needs to be reduced if the patient is receiving a supplementary dose of enteral or parenteral sedative agent for behavior management. The action of the sedative has an additive depressive effect on the central nervous and cardiovascular systems can initiate overdose consequences. (see [Complications of Local Anesthesia](#)).

### Pre-administration Protocol

Before administering any drug to a patient, the clinician must evaluate the health of the patient to determine whether the patient can tolerate the drug and minimize possible complications resulting from the drug interacting with the patient's organ systems or with medication the patient is taking. Local anesthetic actions include depressant effects on the central nervous system and cardiovascular system. Because local anesthetics undergo biotransformation in the liver (amides) and blood (esters), and are excreted by the kidneys, the status of these organ systems should be evaluated. A patient's psychological acceptance of a local anesthetic needs to be assessed as many patients view the "needle shot" as the most traumatic aspect of the dental procedure.

While a comprehensive medical history is recommended for all dental patients, the following questions are most pertinent for those patients who are to receive local anesthesia.

- Has the patient ever received a local/topical anesthetic for medical or dental care?
  - If so, were there any adverse reactions?
- Is the patient having any pain at this time?
  - How severe?
  - How long?
  - Any swelling?
- Is the patient nervous about receiving dental treatment?
  - Why are they nervous?
  - Has the patient had any bad dental experiences?
- Has the patient been in a hospital during the past two years?
- Has the patient taken any medicine or drugs during the past two years?



- Has the patient been under the care of a physician during the past two years?
- Is the patient allergic to any foods or drugs?
- Does the patient have any bleeding problems that require special treatment?
- Has the patient ever had any of the following conditions or treatment?
  - Heart failure
  - Heart attack or heart disease
  - Angina pectoris
  - Hypertension
  - Heart murmur, rheumatic fever
  - Congenital heart problems
  - Artificial heart valve
  - Heart pacemaker
  - Implanted cardioverter/defibrillator
  - Heart operation
- Has the patient ever had any of the following conditions or treatment?
  - Anemia (methemoglobinemia)
  - Stroke
  - Kidney trouble
  - Hay fever, sinus trouble, allergies or hives
  - Thyroid disease
  - Pain in jaw joints
  - HIV/AIDS
  - Hepatitis A, B, C
  - Epilepsy or seizures
  - Fainting, dizzy spells, nervousness
  - Psychiatric treatment
- Does the patient bruise easily?
- Is the patient pregnant?
- Does the patient have any disease, condition or problem not mentioned?

As the confines of this course limit a full discussion of the effects of local anesthetics on the body and with other drugs the following tables summarize the more common interactions.

### Local Anesthesia and Pregnancy

Special considerations are needed when using local anesthesia during pregnancy and the postpartum period, especially during lactation. The use of local anesthesia during pregnancy is considered safe, however, the benefits and risks for the mother and fetus must always be considered.

The FDA has a drug classification system based on the risks to pregnant women and their fetuses. Of the five categories (A, B, C, D, and

X) lidocaine is considered in Category B, the safest of the local anesthetics. Mepivacaine and bupivacaine are Category C and may be used with caution.

During the first trimester and during lactation local anesthesia without vasoconstrictor should be considered to avoid possible idiosyncratic reaction to the fetus and neonate. This potential reaction is not to the vasoconstrictor but to the preservative used to stabilize the vasoconstrictor. Prilocaine should not be used due to the risk of the fetus developing methemoglobinemia. In the second and third trimesters, proper positioning and heart rate monitoring are important to avoid postural hypotension.<sup>3</sup>

### Local Anesthesia with Sedation, General Anesthesia, and/or Nitrous Oxide/oxygen Analgesia/anxiolysis

As local anesthetics and sedative agents both depress the CNS it is recommended that the dose of local anesthesia be adjusted downward when sedating children with opioids. Narcotics may decrease the amount of protein binding of local anesthetics and elevated arterial carbon dioxide which increase CNS sensitivity to convulsions.

For patients undergoing general anesthesia, the anesthesia care provider must be made aware of concomitant use of a local anesthetic containing epinephrine as epinephrine can produce dysrhythmias when used with halogenated hydrocarbons (e.g., halothane). The dosage of local anesthetic does not need to be altered if nitrous oxide/oxygen analgesia/anxiolysis is administered alone.<sup>1</sup>

### Armamentarium

The armamentarium necessary to administer local anesthesia are the cartridge needle and syringe (Figure 1). Although clinicians may feel extremely comfortable with these items, a discussion of their characteristics is warranted.

### Cartridge

- The cartridge contains the anesthetic solution.
- In the U.S. it contains 1.8ml (cc) of anesthetic solution. This amount may vary in other countries.
  - Its components consist of a cylindrical glass

**Table 3. Contraindications for Local Anesthetics.<sup>3</sup>**

Conditions	Anesthetics	Contraindication	Alternates
Local anesthetic allergy, documented	All local anesthetics in the same class, (e.g., esters)	Absolute	Local anesthetics in a different chemical class (e.g., amides)
Bisulfite allergy	Local anesthetics containing a vasoconstrictor	Absolute	Local anesthesia without a vasoconstrictor
Atypical plasma cholinesterase	Esters	Relative	Amides
Methemoglobinemia, idiopathic or congenital	Articaine, prilocaine, topical benzocaine in children younger than 2 years	Relative	Other amides or esters
Significant liver dysfunction (ASA III-IV)	Amides	Relative	Amides or esters but judiciously
Significant renal dysfunction (ASA III-IV)	Amides or ester	Relative	Amides or esters but judiciously
Significant cardiovascular dysfunction (ASA III-IV)	High concentrations of vasoconstrictors (as in racemic epinephrine cords)	Relative	Local anesthetics with concentrations of 1:200,000 or 1:100,000 or mepivacaine 3% or prilocaine 4% (nerve blocks)
Clinical hyperthyroidism (ASA III-IV)	High concentrations of vasoconstrictors (as in racemic epinephrine cords)	Relative	Local anesthetics with concentrations of 1:200,000 or 1:100,000 or mepivacaine 3% or prilocaine 4% (nerve blocks)

**Definitions:**

**Absolute contraindication** – Implies that under no circumstance should this drug be administered to this patient because the possibility of potentially toxic or lethal interactions is increased.

**Relative contraindication** – Implies that the drug in question may be administered to the patient after carefully weighing the risk of using the drug to its potential benefit, and if an acceptable alternative drug is not available.



**Table 4. Drug-to-Drug Interactions.<sup>3</sup>**

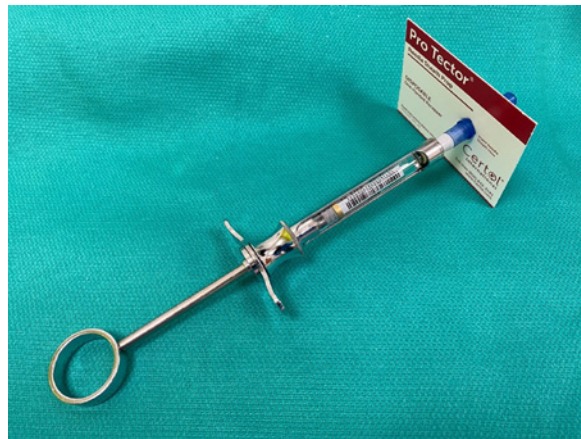Drugs	Example	Significance Rating	Interaction
Summation interactions of local anesthetics	Lidocaine plus articaine	Major	Toxicity of local anesthetics are additive. Total dose of all administered local anesthetics should not exceed the maximum recommended dose of the drugs.
Local anesthetics with opioid sedation	Local anesthetic with Demerol	Major	May increase the risk of local anesthetic overdose. Minimize the dosage of the local anesthetic.
Vasoconstrictor with cocaine	Epinephrine with cocaine Vasopressors should not be administered to patients who have used cocaine within the last 24 hours	Major	Increases likelihood of cardiac dysrhythmias, tachycardia and hypertension. May lead to MI and cardiac arrest.
Vasoconstrictors with general anesthetics	Epinephrine with halothane	Major	Increases the likelihood of cardiac dysrhythmias. Discuss with cardiologist before administration.
Vasoconstrictors with nonselective beta adrenoreceptor antagonists (beta-blocker)	Epinephrine with propranolol	Major	TCAs enhance the cardiovascular actions of administered vasopressors.  5-10X with levonordefrin and norepinephrine.  2X with epinephrine
Local anesthetic induced methoglobinemia (a condition in which the oxygen carrying capacity of the blood is reduced)	Excessive doses of prilocaine	Moderate	Large doses of benzocaine can also induce methemoglobinemia
Vasoconstrictor with antipsychotic drugs	Epinephrine with chlorpromazine	Moderate	May result in hypotension
Vasoconstrictor with thyroid hormone	Epinephrine with thyroxine	Moderate	Increase in effects of vasoconstrictor with excessive thyroid hormones
Sulfonamides and esters	Procaine and tetracaine and sulfonamides	Minor	Ester anesthetics inhibit the bacteriostatic action of sulfonamides. Use amide local anesthetics.
Amide local anesthetics with metabolic inhibitors (GI disorders)	Cimetidine (Tagamet) and lidocaine. No problem with rantidine (Zantac) and famotidine (Pepcid)	Minor	Inhibits anesthetic biotransformation. Increases half-life of anesthetic.  Use minimal dose of amide local anesthetic.
<p><b>Significance Rating</b>  <b>Major</b> – Potentially life threatening or capable of causing permanent damage.  <b>Moderate</b> – Could cause deterioration of patient's clinical status; additional treatment or hospitalization might be necessary.  <b>Minor</b> – Mild effects that are bothersome or unnoticed; should not significantly affect therapeutic outcome.</p>			

tube, rubber stopper, aluminum cap and diaphragm.

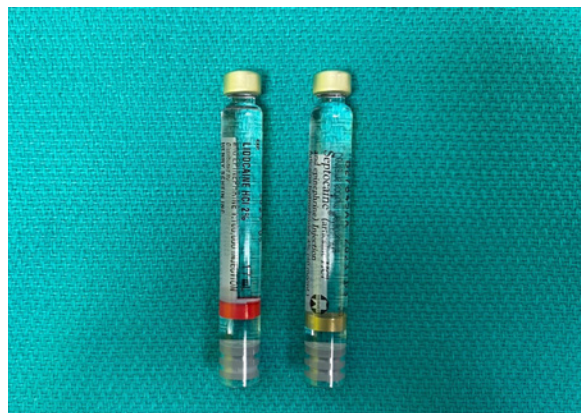- The glass cylinder is surrounded by thin plastic label that describes the contents and protects the patient if the cartridge cracks.
- The stopper is located at the end of the cartridge that receives the syringe harpoon. It is no longer color coded to the type of anesthetic used so the practitioner should double-check the contents of the cartridge before administering the anesthetic solution to the patient. The stopper is slightly indented from the lip of the glass cylinder and the cartridge should not be used if it is flush.
- The aluminum cap is located at the opposite end from the plunger. It holds the diaphragm in place and is silver colored on all cartridges.
- The diaphragm is a semi-permeable membrane made of latex rubber through which the needle perforates. (For patients with latex allergies, anesthetic cartridges with non-latex stoppers are available.)
- The contents of the cartridge are local anesthetic, vasopressor drug, preservatives for the vasopressor, sodium chloride and distilled water (Figure 2).
  - The local anesthetic interrupts the nerve impulses preventing them from reaching the brain.
  - The vasopressor drug is used to reduce dispersion of the local anesthetic into the circulation and increases its duration of action. It lowers the pH of the cartridge solution which may lead to discomfort during injection.
  - The vasopressor drug contains sodium bisulfite as an antioxidant. Patients may be allergic to bisulfite. Local anesthetics without vasopressor do not contain bisulfites and may be used as an alternative for these patients.
  - Sodium chloride is added to the anesthetic solution to make it isotonic with the body tissues.
  - Distilled water is added to provide the proper volume of solution in the cartridge.

Clinicians should be aware of possible problems with the cartridges:

**Bubble in the cartridge** – A small bubble may



**Figure 1.** Local anesthetic syringe and cartridge with a needle sheath prop



**Figure 2.** Local anesthetic cartridges (2% Lidocaine and 4% Septocaine)

just be nitrogen gas used in the manufacturing process and is of no concern. A large bubble that extrudes the plunger beyond the rim of the cartridge is indicative of freezing and should not be used.

**Burning on injection** – This may be just a normal response to the pH of the drug especially those containing vasopressor. However, it can also be indicative of disinfecting solution leaking into the cartridge or overheating of the anesthetic solution from a defective cartridge warmer.

**Leakage of solution** – Leakage of solution during injection can result from improper alignment of the diaphragm and needle.

**Broken cartridge** – A crack in the glass cartridge may be a result of damage during shipping. It can also result from excessive force

during engagement of the harpoon, a bent harpoon, or a bent needle leading to excessive pressure on the cartridge during injection.

## Needles

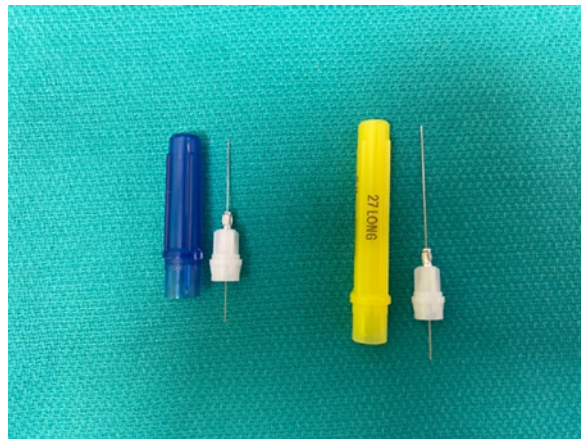
**Bevel** – The point or tip of the needle. The greater the angle of the bevel with the long axis of the needle, the greater the degree of deflection as the needle passes through the soft tissues. For most injections the bevel of the needle is oriented toward bone.

**Shank or shaft** – Is identified by the length of the shank and the diameter of the needle lumen (gauge). The higher the gauge the smaller the internal diameter. The most common gauges are 25, 27, and 30 gauge. It has been recommended to use the smallest gauge (largest diameter) needle available which allows for easier aspiration, less deflection of the needle as it perforates the soft tissue, and less chance of breakage at the hub.<sup>3</sup> The needle comes in three lengths, long short and ultra-short. The decision as to the length is dependent on the type of injection (block or infiltration) size of patient and thickness of tissue. The needle should not be inserted to the hub as retrieval during breakage is difficult so a long or short needle should be used for block anesthesia. The advantage of the ultra-short needle is less deflection of the needle. It may be used for infiltrations (Figure 3).

**Hub** – The hub is the plastic or metal piece through which the needle attaches to the syringe. The interior surface of a plastic hub is not pre-threaded. Therefore, attachment requires that the needle be pushed onto the syringe while being screwed on. Metal hub needles are usually pre-threaded. The syringe end of the needle perforates the rubber diaphragm of the cartridge when attached to the syringe.

Recommendations for needle utilization are:

- Sterile needles should be used.
- If multiple injections are to be administered, needles should be changed after three or four insertions in a patient.
- Needles must never be used on more than one patient.
- Needles should not be inserted into tissue



**Figure 3.** Needle sizes for delivering local anesthetics

to their hub to allow for easy retrieval if the needle breaks.

- To change a needle's direction while it is still in tissues, withdraw the needle almost completely then change direction.
- Never force a needle against resistance (bone) as it can increase the chance of breakage.
- Do not bend needles except for intrapulpal injections.
- Needles should remain capped until used and then recapped immediately after injection.
- Needles should be discarded and destroyed after use.

## Syringe (Cartridge Holder)

The American Dental Association (ADA) has established criteria for acceptance of local anesthetic syringes.

- They must be durable to withstand repeated sterilization without damage.
- Disposable syringes should be packaged in a sterile container.
- They should be capable of accepting a wide variety of cartridges and needles of different manufacturers.
- They should be inexpensive, self-contained, lightweight, and simple to use with one hand.
- They should provide for effective aspiration and be constructed so that blood may be easily observed in the cartridge.

Syringe durability can be enhanced by following a routine of proper care and handling.



- After each use, thoroughly wash and rinse the syringe of any local anesthetic solution, saliva and other foreign matter.
- Autoclave the syringe as other surgical instruments.
- After every five autoclavings, dismantle the syringe and lightly lubricate all threaded joints and where the piston contacts the thumb ring and guide bearing.
- Clean the harpoon with a brush after each use.
- After extended use the harpoon will decrease in sharpness and fail to remain embedded within the cartridge stopper. Replace the piston and harpoon as necessary.

Even with proper maintenance problems may still arise.

- **Bent harpoon** – An off-center puncture of the rubber plunger may cause breakage of the anesthetic cartridge or leakage of the anesthetic solution.
- **Dull harpoon** – A dull harpoon may cause disengagement from the rubber plunger during aspiration.<sup>3</sup>

### Topical Anesthetic

Topical anesthetic reduces the slight discomfort associated with insertion of the needle. It is affective to a depth of 2-3mm. Although its application is beneficial for reducing patient discomfort during the initial phase of local anesthetic administration, it may be a disadvantage in children if the taste is disagreeable to the patient. Also, excessive length of application time may increase apprehension of the approaching procedure.

It is available in gel, liquid, ointment, patch and pressurized spray forms. The most common topical anesthetics used in dentistry are those containing benzocaine or lidocaine.

Benzocaine (ethyl aminobenzoate) is an ester local anesthetic. It is available in up to 20% concentrations. It is not known to produce systemic toxicity but can produce local allergic reactions especially after prolonged or repeated use. It exhibits poor solubility in water and poor absorption into the cardiovascular system, thus

it remains at the site of application longer, providing a prolonged duration of action. Systemic toxic (overdose) reactions are virtually unknown. Benzocaine is reported to inhibit the antibacterial action of sulfonamides.

Lidocaine is available as a solution or ointment up to 5% concentration and as a spray up to 10% concentration. It has a low incidence of allergic reactions but is absorbed systemically and application of excessive amounts of topical lidocaine may absorb rapidly into the cardiovascular system leading to higher local anesthetic blood levels with an increased risk, especially in the pediatric patient, of overdose reaction. Thus, a minimal amount of topical gel should be applied to the tissue and a metered spray is suggested if an aerosol preparation is selected.

### Preparation of Patient

Preparation of the patient prior to injection consists of two components, mental and physical.

Mental preparation begins with explaining to the child, in terminology they can understand, the anesthesia administration process. The following narrative, and similar terms can be adapted in the dental practice (adapted from Dr. Steven Schwartz):

*“Today I’m going to put your tooth asleep, wash some germs out of your teeth and place a white star. When your tooth falls asleep your lip and tongue will feel fat and funny for a little while. First, you’re going to sit in my special chair and then I’m going to place some (goofy, cherry, bubble gum) tooth jelly next to your tooth. Then I’ll wash it away with the sleepy water. I’m going to show you everything I do so you can see how easy this is.”*

### Administration Protocol

#### Position the Patient in the Dental Chair

The patient is positioned with the head and heart parallel to the floor and the feet slightly elevated. Positioning the patient in this manner reduces the incidence of syncope that can occur because of increased anxiety (Figure 4).

*"Hop up into my chair and I'll move it back so I can see your tooth really well and you'll be comfortable. You can hold your hands if you feel tensed."*

### **Dry the Tissue**

Use a 2 X 2 gauze to dry the tissue and remove any gross debris around the site of needle penetration. Retract the lip to obtain adequate visibility during the injection. Wipe and dry the lip to make retraction easier (Figure 5).

*"I'm wiping your tooth and gums with my little soft cleaner to make sure everything is clean."*

### **Apply Topical Anesthetic**

Topical anesthetic reduces the slight discomfort associated with insertion of the needle. It is effective to a depth of 2-3mm. It is applied only at the site of preparation. The clinician should avoid excessive amounts that can anesthetize the soft palate and pharynx. The topical anesthetic should remain in contact with the soft tissue 1-2 minutes (Figure 6).

*"Now I'm rubbing (goofy, cherry, bubble gum) tooth jelly next to your tooth. If it begins to feel too warm or goofy, let me know and I'll wash it away with my sleepy water."*

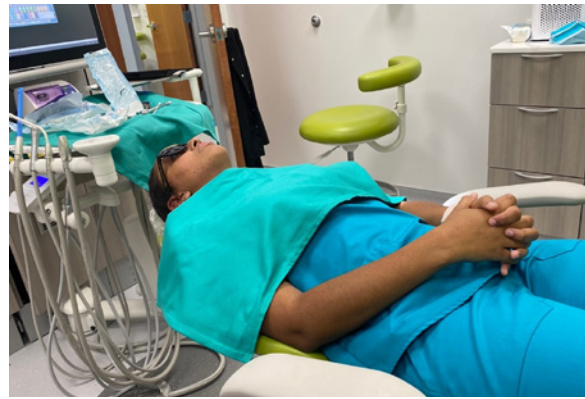
The following steps can be performed during application of the topical anesthetic.

### **Determine the Temperature of the Anesthetic Solution**

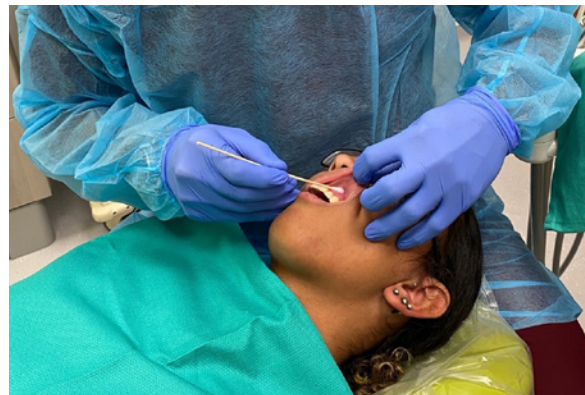The temperature of the anesthetic solution should be between room and body temperature. Commercial cartridge warmers are available that provide a constant source of heat to the cartridge using a small bulb as the heat source. However, it can overheat the anesthetic solution causing discomfort to the patient during injection. Another technique is to run warm water for a few seconds over the cartridge in a manner similar to warming a baby bottle. If the cartridge feels warm to the administrator's gloved hand, it is probably too warm.

### **Assemble the Syringe**

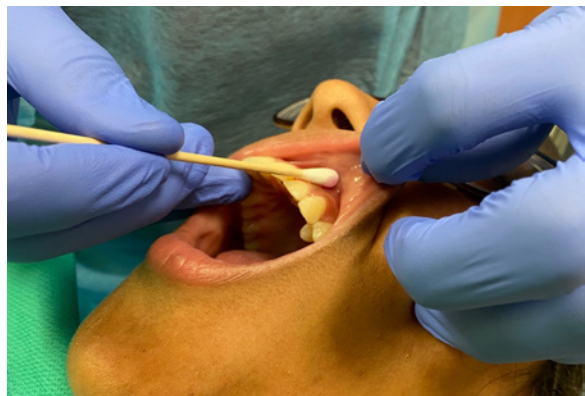It is preferable to assemble the syringe out of sight of the child patient as this may provoke



**Figure 4.** Positioning of patient in the dental chair



**Figure 5.** Drying the soft tissue



**Figure 6.** Application of topical anesthetic

unnecessary fear in the patient. It is also desirable to distract the patient when receiving the anesthetic syringe.

### **Administration of the Anesthetic**

There are two important goals one must accomplish during anesthetic administration;

control and limit movement of the patient's head and body and communicate with the patient to draw their attention away from the minor discomfort that may be felt during the injection process.

Most clinicians prefer to keep the uncapped needle out of the patient's line of sight. Do not ask the child to close his/her eyes as that is usually a sign to the child that something bad or painful is about to occur. Instead, the assistant passes the uncapped syringe behind the patient's head (Figure 7).

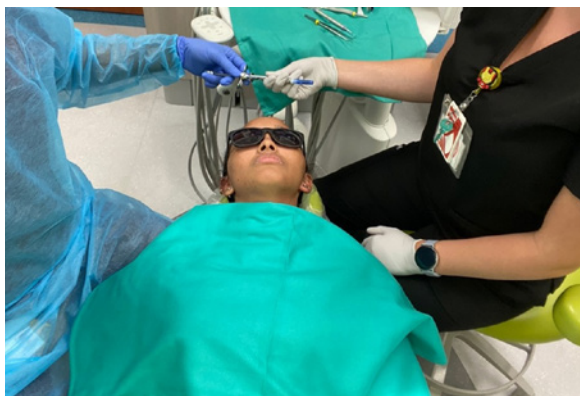### **Stabilization**

Before placement of the syringe in the mouth, the patient's head, hands and body should be stabilized. There are two basic positions for stabilizing the patient's head.

A behind the patient position is assumed for injecting the contralateral quadrants to the clinician's favored hand and the anterior regions, i.e., right-handed clinicians injecting the left side, left-handed clinicians injecting the right side.

The clinician stabilizes the patient's head by supporting the head against the clinician's body with the less favored hand and arm. The clinician stabilizes the jaw by resting the fingers against the mandible for support and retraction of lips and cheek.

For injections on the same side as the clinician's favored hand, i.e., right side for right-handed clinicians, left side for left-handed



**Figure 7.** Handling of local anesthetic syringe out of sight of the patient

clinicians, the clinician assumes a more forward position, 8 o'clock for right-handed clinicians, 4 o'clock for left-handed clinicians.

The clinician stabilizes the patient's head and retracts the soft tissues with the fingers of the weaker hand resting on the bones of the maxilla and mandible.

To prevent unexpected movements of the child's hands during the injection, the assistant restrains the hands by asking the child to place them on their belly button and placing her hands over them.

### **Communication**

The clinician initiates communication with the patient by speaking in a reassuring manner during anesthesia administration. The subject matter can range from describing the process in child friendly terminology, to praise, to storytelling, to singing, or, if the clinician is totally unimaginative, counting. Avoid words like shot, pain, hurt and injection and substitute words like cold, warm, weird, fat and funny.

*"Is that jelly beginning to feel warm and weird? If it is, then I have to wash it away with my fat and funny water. When I spray the water next to your tooth it may feel real cold. So, what I'll do is count and by the time I reach five the water will warm up."*

### **Basic Injection Technique**

The anesthetic injection begins by stretching the tissue taut at the administration site. Insert the needle 1-2mm into the mucosa with the bevel oriented toward bone. Inject several drops of anesthetic before advancing the needle. Slowly advance the needle toward the target while injecting up to ¼ cartridge of anesthetic to anesthetize the soft tissue ahead of the advancing needle and then aspirate.

The depth of insertion will vary with the type of injection; however, one should never insert a needle in its entirety to the hub. Although a rare occurrence, retrieving a broken needle fully embedded in soft tissue is extremely difficult.

After confirming a negative aspiration, the injection process should take between 1-2



minutes. The clinician should be mindful of not injecting a greater amount of anesthetic than recommended for the patient's weight.

Continue to speak to the patient throughout the injection process. Close observation of the patient's eye and hand movements along with crying will alert the clinician to patient discomfort.

*"Now I'm going to spray the sleepy water on your tooth. Open your mouth real wide like a crocodile and put your hands on your belly button so they don't get wet. I'm spraying the water and it probably feels cold so I'm counting to five to warm it up. Let's count 1, 2, 3, 4, 5. I think the cold went away so we can spray the rest of the water to make your tooth fat and funny. You're doing so good sitting so still with your mouth wide open and your hands on your belly button. I need to give you a special reward. How about a sticker? Nah, you're doing so good you should get two stickers and we have a whole selection of stickers. Do you like Spiderman stickers? Me too. How about puppy stickers? No. Okay. How about Princess stickers? Okay, we're finished. You were great! You can pick out two stickers while we wait for your tooth to fall asleep and your lip to feel fat and funny."*

It is preferable to reward the patient immediately after successfully completing a segment of the treatment rather than wait until after the entire treatment session is completed. It has been found to reinforce positive behavior throughout the procedure.

After depositing the desired amount of anesthetic, the syringe is withdrawn, and the needle safely recapped. It is preferable to use a needle holder to avoid injuries by directly recapping the needle.

Do not leave the patient unattended while waiting for anesthesia symptoms to develop. Continually observe the patient for blanching of the skin, signs of allergic reactions or vasopressor reactions.

Record the name of the topical anesthetic, amount of anesthetic injected, vasoconstrictor dose, type of needle used and the patient's reaction.

Upon completion of treatment and dismissal of the patient, the clinician says to the patient with the accompanying adult present:

*"You were a terrific helper. You can pick out 3 more stickers and I'm giving you an extra special sticker that says 'Careful, tooth, tongue, lips, asleep.' Although we're finished with today's treatment, your tooth will be asleep, and your lip and tongue will feel fat and funny for another hour. I also want you to bite on this tooth pillow (cotton roll). Don't eat or drink until your lip and tongue no longer feels fat and funny."*

### **Specific Injection Techniques**

The most common injection techniques used in pediatric dentistry are presented here:

#### **Inferior Alveolar Nerve Block**

The inferior alveolar nerve block (IANB) is indicated when deep operative or surgical procedures are undertaken for mandibular primary and permanent teeth. While a supraperiosteal injection (infiltration) may provide adequate anesthesia for the primary incisors and molars it is not as effective for providing complete anesthesia for the mandibular permanent molars.

A major consideration for IANB in the pediatric patient is that the mandibular foramen is situated at a lower level (below the occlusal plane) than in an adult. Thus, the injection is made slightly lower and more posteriorly than in an adult (Figure 8).

The areas anesthetized are the:

- Mandibular teeth to the midline
- Body of the mandible, inferior portion of the ramus
- Buccal mucoperiosteum, mucous membrane anterior to the mandibular first molar
- Anterior two thirds of the tongue and the floor of the oral cavity (lingual nerve)
- Lingual soft tissues and periosteum (lingual nerve)

The indications for the IANB are:

- Procedures on multiple mandibular teeth in a quadrant
- When buccal soft tissue anesthesia anterior to the first molar is necessary

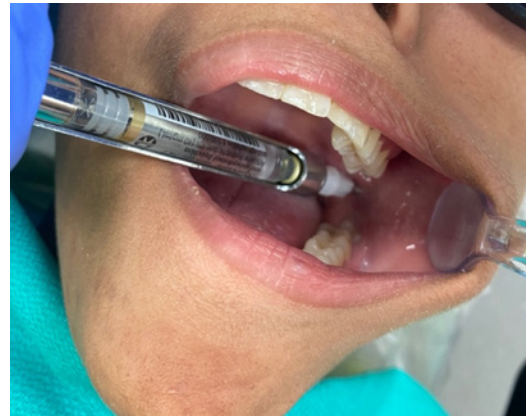- When lingual soft tissue anesthesia is necessary

Contraindications are:

- Infection in the area of injection
- Patients who are likely to bite the lip or tongue (young children and the mentally handicapped)

**Technique:**

- Depending on the age and size of the patient a 25 or 27 gauge long or short needle may be used.
- Lay the thumb on the occlusal surface of the molars, with the tip of the thumb resting on the internal oblique ridge and the ball of the thumb resting on the retromolar fossa. Support the mandible during the injection by resting the ball of the middle finger on the posterior border of the mandible.
- The barrel of the syringe should be directed between the two primary molars on the opposite side of the arch.
- Inject a small amount of solution as the tissue is penetrated. Wait 5 seconds.
- Advance the needle 4mm while injecting minute amounts (up to a ¼ cartridge).
- Stop and aspirate.
- If aspiration is negative, advance the needle 4mm while injecting minute amounts (up to a ¼ cartridge).
- Stop and aspirate.
- If aspiration is negative, advance the needle while injecting minute amounts until bony resistance is met). Withdraw the needle 2mm.
- Stop and aspirate.
- The average depth of insertion is about 15mm (varies with the size of the mandible and the age of the patient). Deposit about 1 ml of solution around the inferior alveolar nerve.
- If bone is not contacted, the needle tip is located too posteriorly. Withdraw it until approximately ¼ length of needle is left in the tissue, reposition the syringe distally so it is over the area of the permanent molar and repeat as above.
- If bone is contacted too early (less than half the length of a long needle) the needle tip is located too anteriorly. Withdraw it until



**Figure 8.** Inferior alveolar nerve block

approximately ¼ length of needle is left in the tissue, reposition the syringe mesially over the area of the cuspid and repeat as above.

- The needle is withdrawn and recapped.
- Wait 3-5 minutes before commencing dental treatment.

The signs and symptoms of an inferior alveolar block are:

- Tingling and numbness of the lower lip (however it is not an indication of depth of anesthesia).
- Tingling and numbness of the tongue (see Lingual Nerve Block).
- No pain is felt during dental treatment.

**Lingual Nerve Block**

Successful anesthesia of the inferior alveolar nerve will result in anesthesia of the lingual nerve with the injection of a small quantity of the solution as the needle is withdrawn. The clinician must not assume effective anesthesia is attained if the patient only exhibits tongue symptoms. The patient must also exhibit lip and mucosa symptoms.

**Long Buccal Nerve Block**

The long buccal nerve provides innervation to the buccal soft tissues and periosteum adjacent to the mandibular molars. For the removal of mandibular permanent molars or for placement of a rubber dam clamp it is necessary to anesthetize the long buccal nerve. It is contraindicated in areas of acute infection.

**Technique:**

- With the index finger, pull the buccal soft tissue in the area of the injection taut to improve visibility.
- Direct the needle toward the injection site with the bevel facing bone and the syringe aligned parallel with the occlusal plane and buccal to the teeth.
- Penetrate the mucous membrane at the injection site distal and buccal to the last molar.
- Advance the needle slowly until mucoperiosteum is contacted.
- The depth of penetration is 1-4mm.
- Aspirate.
- Inject approximately 1/8 of a cartridge over 10 seconds.
- The needle is withdrawn and recapped.
- Wait 3-5 minutes before commencing treatment.

**Supraperiosteal Injections (Local Infiltration)**

Supraperiosteal injection (commonly known as local infiltration) is indicated whenever dental procedures are confined to a localized area in either the maxilla or mandible. The terminal endings of the nerves innervating the region are anesthetized. The indications are pulpal anesthesia of all the maxillary teeth (permanent and primary), mandibular anterior teeth (primary and permanent) and mandibular primary molars when treatment is limited to one or two teeth. It also provides soft tissue anesthesia as a supplement to regional blocks. The contraindications are infection or acute inflammation in the injection area and in areas where dense bone covers the apices of the teeth, i.e., the permanent first molars in children. It is not recommended for large areas due to the need of multiple needle insertions and the necessity to administer larger total volumes of local anesthetic that may lead to toxicity.

**Local Infiltration for Mandibular Molars**

A number of studies have reported on the effectiveness of injecting local anesthetic solution in the mucobuccal fold between the roots of the primary mandibular molars. Q23. When comparing the effectiveness of mandibular infiltration to mandibular block anesthesia, it was generally agreed that the

two techniques were equally effective for restorative procedures, but the mandibular block was more effective for pulpotomies and extractions than mandibular infiltration. The mandibular infiltration should be considered in situations where one wants to perform bilateral restorative procedures without anesthetizing the tongue. Bilateral anesthesia of the tongue is uncomfortable for both children and adults (Figure 9).

**Technique:**

- Retract the cheek so the tissue of the mucobuccal fold is taut.
- Apply topical anesthetic.
- Orient the needle bevel toward the bone.
- Penetrate the mucous membrane mesial to the primary molar to be anesthetized directing the needle to a position between the roots of the tooth. Slowly inject a small amount of anesthetic while advancing the needle to the desired position and injecting about a 1/2 cartridge of anesthetic.
- If lingual tissue anesthesia is necessary (rubber dam clamp placement), then one can inject anesthetic solution directly into the lingual tissue at the free gingival margin or one can insert the needle interproximally from the buccal and deposit anesthesia as the needle is advanced lingually.
- The needle is withdrawn and recapped.
- Wait 3-5 minutes before commencing treatment.

**Local Infiltration for Mandibular Incisors**

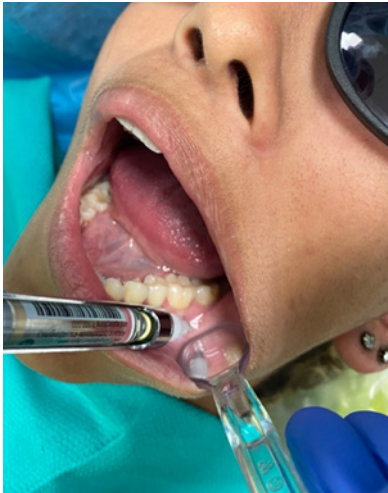The indications for mandibular incisor infiltration are:

- To supplement an inferior alveolar block when total quadrant anesthesia is desired.
- Excavation of superficial caries of the mandibular incisors or extraction of partially exfoliating primary incisor (Figure 10).

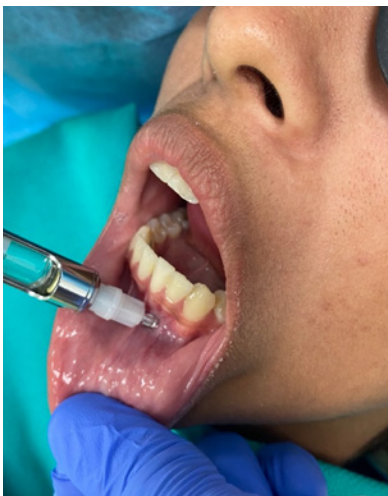If quadrant treatment is planned involving posterior and anterior teeth, mandibular infiltration is necessary to anesthetize the terminal ends of the inferior alveolar nerves that cross over the midline from the contralateral quadrant.

**Technique to Supplement Block Anesthesia**

- Retract the cheek so the tissue of the mucobuccal fold is taut.



**Figure 9.** Infiltration of mandibular molars



**Figure 10.** Infiltration for Mandibular Incisors

### Technique for Anterior Restorations and Extractions

- Retract the cheek so the tissue of the mucobuccal fold is taut.
- Apply topical anesthetic.
- Orient the needle bevel toward the bone.
- Penetrate the mucosa labial to the tooth to be treated close to the bone at the mucogingival margin. Advance the needle 2mm approximating the apex of the root. Inject a ¼-½ cartridge of anesthetic.
- If it is necessary to anesthetize an adjacent tooth, partially withdraw the needle and turn the needle in the direction of the indicated tooth and advance the needle until it approximates the apex.
- If lingual tissue anesthesia is necessary (extraction), then one can inject anesthetic solution directly into the lingual tissue at the free gingival margin or one can insert the needle interproximally from the buccal and deposit anesthesia as the needle is advanced lingually.
- The needle is withdrawn and recapped.
- Wait 3-5 minutes before commencing treatment.

### Local Infiltration of the Maxillary Primary and Permanent Incisors and Canines

#### Technique:

- Retract the cheek so the tissue of the mucobuccal fold is taut.
  - Apply topical anesthetic.
  - Orient the needle bevel toward the bone.
  - Penetrate the mucosa labial to the tooth to be treated close to the bone at the mucogingival margin with the syringe parallel to the long axis of the tooth. Advance the needle 2mm approximating the apex of the root (Figure 11).
  - Aspirate.
  - Inject a ¼-½ cartridge of anesthetic.
  - If it is necessary to anesthetize an adjacent tooth, partially withdraw the needle and turn the needle in the direction of the indicated tooth in advance the needle until it approximates the apex.
  - Aspirate.
  - Inject ¼-½ cartridge of anesthetic.
  - If palatal tissue anesthesia is necessary (extraction or incomplete anesthesia of the
- Apply topical anesthetic.
  - Orient the needle bevel toward the bone.
  - Penetrate the mucosa on the same side as the block close to the midline at the mucogingival margin and advance the needle 2mm approximating the location of the apex of the root. The needle is inserted in a diagonal direction and the solution is deposited on the opposite side of the midline. A ½ cartridge of solution should suffice.
  - The needle is withdrawn and recapped.
  - Wait 3-5 minutes before commencing treatment.



tooth due to accessory innervation from the palatal nerves), then one can inject anesthetic solution directly into the lingual tissue at the free gingival margin or one can insert the needle interproximally from the buccal and deposit anesthesia as the needle is advanced lingually.

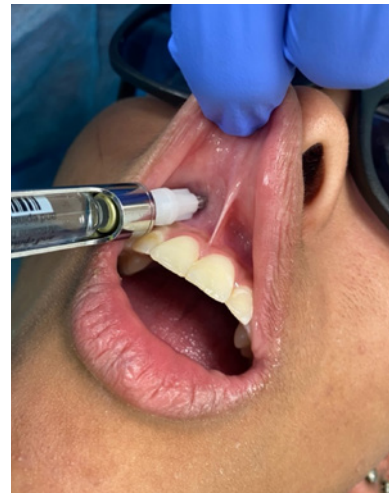- The needle is withdrawn and recapped.
- Wait 3-5 minutes before commencing treatment. The patient should exhibit numbness in the area of administration and absence of pain during treatment.

### **Anesthetization of the Maxillary Primary Molars and Premolars**

The areas anesthetized are the pulps of the maxillary first primary molars (primary and early mixed dentition) and the first and second premolars and mesiobuccal root of the first permanent molar in the permanent dentition, as well as the buccal periodontal tissues and bone over these teeth. The injection is contraindicated if infection or inflammation is present in the area of administration.

#### **Technique:**

- A 25- or 27- gauge, short needle is acceptable.
- The area of insertion for the first primary molar is in between the apices of the roots of the tooth at the height of the mucobuccal fold. The area of insertion for the premolars is in an area between the two teeth.
- Retract the cheek so the tissue of the mucobuccal fold is taut.
- Apply topical anesthetic.
- Orient the needle bevel toward the bone.
- Penetrate the mucous membrane and slowly advance the needle until its tip is above the area between the apices of the first molar or above the apex of the second premolar.
- Aspirate.
- Slowly deposit 1/2-2/3 of a cartridge of solution.
- The needle is withdrawn and recapped.
- Wait 3-5 minutes before commencing dental treatment. If the patient complains of pain, it may be necessary to supplement anesthesia with a posterior superior alveolar nerve block.

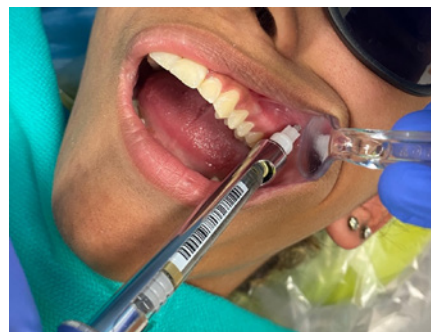

**Figure 11.** Local Infiltration of the Maxillary Primary and Permanent Incisors and Canines

- A rare complication is formation of a hematoma at the injection site. If this occurs apply pressure with gauze over the site of swelling for a minimum of 60 seconds.

### **Posterior Superior Alveolar Nerve Block**

For reasons already described, the posterior superior alveolar nerve block is used to anesthetize the second primary molar in the primary and mixed dentitions and the permanent molars in the mixed and permanent dentitions. The mesiobuccal root of the first permanent molar is not consistently innervated by the posterior superior alveolar nerve. Complete anesthesia of the tooth may need to be supplemented by a local infiltration injection (Figure 12).



**Figure 12.** Posterior superior alveolar nerve block

**Technique:**

- A 25 or 27 gauge short needle is acceptable.
- The area of insertion is the height of the mucobuccal fold above and distal to distobuccal root of the last molar present in the arch.
- Retract the cheek so the tissue of the mucobuccal fold is taut.
- Apply topical anesthetic.
- Orient the needle bevel toward the bone.
- Insert the needle into the height of the mucobuccal fold over the last molar.
- Advance the needle slowly in an:
  - Upward (superiorly at a 45 degree angle to the occlusal plane).
  - Inward (medially toward the midline at a 45 degree angle to the occlusal plane).
  - Backward (posteriorly at a 45 degree angle to the long axis of the molar) to a depth of 10-14mm.
- Aspirate.
- Slowly deposit ½-1 cartridge of solution (aspirate several times while injecting).
- The needle is withdrawn and recapped.
- Wait 3-5 minutes before commencing with dental treatment. If anesthesia is incomplete, supplement with a supraperiosteal or PDL injection.

**Anesthetization of the Palatal Tissues**

Palatal tissue anesthesia is necessary for procedures involving manipulation of the palatal tissues, i.e., extractions, gingivectomy and labial frenectomy. Unfortunately, it is one of the most traumatic and painful procedures experienced by a dental patient during treatment. The following techniques should aid in reducing patient discomfort and in a small number of cases eliminate it entirely. Malamed recommends that the clinician forewarn the patient that there might be discomfort, so they are mentally prepared. If the experience is atraumatic, the patient bestows the “golden hands” award on the clinician. If pain is experienced, the clinician can console the patient with “I’m sorry. I told you it might be uncomfortable” (avoid the “hurt” word).

The steps in atraumatic administration of anesthesia in all palatal areas are:

- Provide adequate topical anesthesia (at least 2 minutes) in the injection area. The

applicator should be held in place by the clinician while applying sufficient pressure to cause blanching.

- Use pressure anesthesia at the injection site before and during needle penetration and solution deposition. The pressure is maintained with a cotton applicator with enough pressure to cause blanching.
- Maintain control over the needle. The use of an ultra-short needle will result in less deflection and greater control. A finger rest will aid in stabilizing the needle.
- Inject the anesthetic solution slowly. Because of the density of the palatal soft tissues and their firm adherence to the hard palate there is little room to spread during solution deposition. Slow injection reduces tissue pressure and results in a less traumatic experience.

**Nasopalatine Nerve Block**

The nasopalatine nerve innervates the palatal tissues of the six anterior teeth. If the needle is inserted into the nasopalatine foramen, it is possible to completely anesthetize the six anterior teeth. However, this technique is painful and not used routinely. The indication for a nasopalatine injection is when palatal soft tissue anesthesia is necessary for restorative therapy on more than two teeth (subgingival placement of matrix bands) and for periodontal and surgical procedures involving the hard palate. More often, this technique is used for surgical removal of the supernumerary tooth in the palatal region. Local infiltration is indicated for treatment of one or two teeth. It is contraindicated when there is infection or inflammation in the area of the injection site.

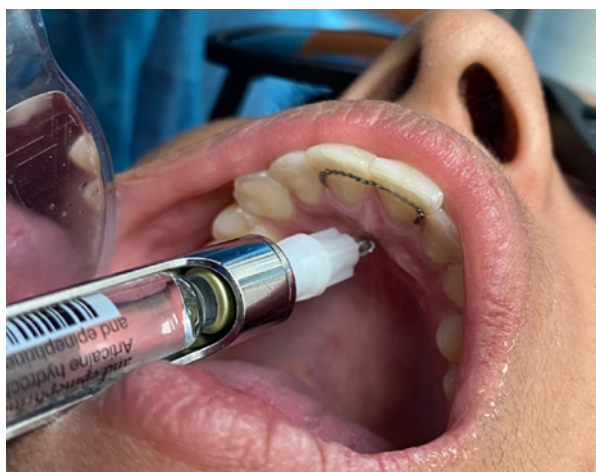There are two techniques: single penetration and multiple penetration. The single penetration consists of a single penetration of the mucosa directly into the incisive foramen relying on pressure anesthesia and slow deposition of anesthetic solution for pain management. Some clinicians feel this technique is still traumatic, especially for the pediatric patient and suggest a multiple penetration technique to minimize pain. The suggested technique is after buccal anesthesia is achieved with local infiltration, anesthetic solution is injected into the interdental papilla penetrating from the labial



and diffusing solution palatally. The palatal tissue is sufficiently anesthetized to proceed with an atraumatic nasopalatine block (Figure 13).

#### **Technique (single penetration)**

- A 25 or 27 gauge short or ultra-short needle may be used.
- The area of insertion is the palatal mucosa just lateral to the incisive papilla (located in the midline behind the central incisors).
- The path of insertion is approaching the incisive papilla at a 45 degree angle with the orientation of the bevel toward the palatal tissue.
- Clean and dry the tissue with sterile gauze.
- Apply topical anesthetic lateral to the incisive papilla for two minutes.
- After two minutes move the cotton applicator directly onto the incisive papilla. Apply sufficient pressure so there is blanching.
- Place the bevel of the needle against the blanched soft tissue at the injection site.
- Apply enough pressure to slightly bow the needle. Deposit a small amount of anesthetic.
- Straighten the needle and penetrate the tissue with the needle.
- Continue to apply pressure with the cotton applicator while injecting.
- Slowly advance the needle toward the incisive foramen while injecting until bone is contacted (about 5mm).
- Withdraw the needle 1mm and aspirate.



**Figure 13.** Nasopalatine nerve block

- If negative, slowly deposit no more than a ¼ cartridge of anesthetic.
- The needle is withdrawn and recapped.
- Wait 2-3 minutes before commencing with treatment.

#### **Technique (multiple penetration)**

- A 25 or 27 gauge short or ultra-short needle is recommended.
- There are 3 points of insertion:
  - The labial frenum between the maxillary central incisors.
  - The interdental papilla between the maxillary central incisors.
  - The palatal soft tissue lateral to the incisive papilla.
- First injection: If labial anesthesia has not been achieved with labial local infiltration of the area, the following injection is performed. If the area is anesthetized, proceed to the second injection.
  - The path of insertion is into the labial frenum with the orientation of the bevel of the needle toward the bone.
  - Clean and dry area with sterile gauze.
  - Apply topical anesthetic for 1 minute.
  - Retract the upper lip to improve visibility.
  - Insert the needle into the frenum and deposit 0.3ml anesthetic solution over 15 seconds. The tissue may balloon. Anesthesia of the tissue should develop immediately.
  - Withdraw the needle.
- Second injection:
  - Hold the needle at right angles to the papilla. The orientation of the bevel is not relevant.
  - Retract the lip to improve visibility.
  - Insert the needle into the papilla just above the crest of bone.
  - Direct it toward the incisive papilla on the palatal side of the interdental papilla while slowly injecting anesthetic solution. Do not penetrate through the palatal tissue.
  - When blanching is noted in the incisive papilla, aspirate.
  - If negative administer 0.3ml of anesthetic solution over 15 seconds.
  - Withdraw the syringe.
- Third injection:
  - Proceed as above for the single penetration injection; however, application of topical anesthetic and pressure anesthesia is unnecessary.

Palatal anesthesia in the canine may be inadequate due to overlapping fibers from the greater palatine nerve. To correct this, it may be necessary to supplement the anesthesia with local infiltration.

### **Greater Palatine Nerve Block**

The greater palatine nerve block is useful for anesthetizing the palatal soft tissues distal to the canine. It is less traumatic than the nasopalatine nerve block because the palatal tissue in the area of the injection site is not as anchored to the underlying bone. It is indicated when palatal soft tissue anesthesia is necessary for restorative treatment on more than two teeth (insertion of subgingival matrix bands) and periodontal and oral surgery. It is contraindicated when there is infection or inflammation around the injection site.

#### **Technique:**

- A 25 or 27 gauge short needle may be used.
- Locate the greater palatine foramen.
  - Place a cotton swab at the junction of the hard palate and the maxillary alveolar process.
  - Starting in the region of the maxillary first molar (or second primary molar in the primary dentition) apply pressure with the cotton swab while moving posteriorly.
  - The swab will fall into the depression created by the greater palatine foramen.
- Prepare the tissue at the injection site, 1–2mm anterior to the greater palatine foramen.
- Clean and dry the area with a sterile gauze.
- Apply topical anesthetic with a cotton applicator for two minutes.
- Move the cotton applicator posteriorly so it is directly over the greater palatine foramen and apply sufficient pressure to blanch the tissue for 30 seconds.
- Direct the syringe into the mouth from the opposite side of the mouth from the injection site at a right angle to the target area with orientation of the needle bevel toward the palatal soft tissue.
- Place the bevel of needle gently against the blanched tissue and apply enough pressure to slightly bow the needle.
- Deposit a small volume of anesthetic.
- Straighten the needle and allow the needle to penetrate the mucosa, while depositing a small amount of anesthetic solution.

- Slowly advance the needle approximately 8mm until palatine bone is contacted.
- Withdraw 1mm and aspirate.
- If negative, inject ¼ cartridge of anesthetic solution over 30 seconds.
- Withdraw the needle and recap.
- Wait 2-3 minutes before commencing treatment.

Palatal anesthesia in the area of the first premolar may be inadequate due to overlapping fibers from the nasopalatine nerve. To correct this it may be necessary to supplement the anesthesia with local infiltration.

### **Local Infiltration of the Palate**

Local infiltration of the palate provides anesthesia of the terminal branches of the nasopalatine and greater palatine nerves. The soft tissues in the immediate area of the injection site are anesthetized.

The indications for local infiltration are for achieving hemostasis during surgical procedures and when pain control of localized areas is necessary such as application of rubber dam or subgingival placement of matrix bands on no more than two teeth. It may supplement inadequate areas of anesthesia from nasopalatine and greater palatine alveolar blocks. It is contraindicated when there is infection or inflammation in the injection area. It can be a traumatic injection for the patient.

#### **Technique:**

- A 25 or 27 gauge short or ultra-short needle may be used.
- The area of insertion is the attached gingiva, 5-10mm from the free gingival margin in the estimated center of the treatment area.
- Approach the injection site at a 45-degree angle with the orientation of the needle bevel toward the palatal soft tissues.
- Clean and dry the injection area with sterile gauze.
- Apply topical anesthetic for two minutes with a cotton applicator.
- Move the cotton applicator adjacent to the injection site and apply sufficient pressure to blanch the tissue for 30 seconds.
- Place the bevel of the needle against the blanched soft tissue and apply enough pressure to slightly bow the needle.

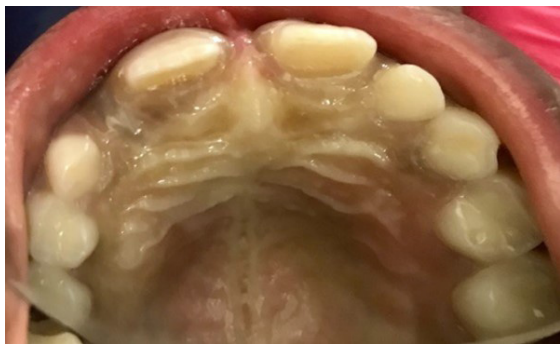- Inject a small amount of anesthesia and allow the needle to straighten and permit the bevel to penetrate mucosa.
- Continue to apply pressure with the cotton applicator while injecting small amounts of anesthetic.
- Advance the needle until bone is contacted (3-5mm) and inject 0.2-0.3ml of anesthetic solution.
- Withdraw and recap the needle.
- If a larger area needs to be anesthetized, reinsert the needle at the periphery of the previously anesthetized tissue and repeat the procedure.
- Treatment may be commenced immediately.

A multiple penetration technique may be used. Following the steps as described previously, after buccal or labial anesthesia is achieved, interpapillary injection is performed to attain palatal tissue anesthesia observed by blanching of the mucosa (Figure 14). It is to be noted that palatal infiltration is the most painful injection technique due to close approximation of palatal mucosa to the periosteum of the bone.

## Supplemental Injection Techniques

### Periodontal Ligament Injection (Intraligamentary Injection)

The periodontal ligament injection has been used for a number of years as either a method of obtaining primary anesthesia for one or two teeth or as a supplement to infiltration or block techniques. The technique's primary advantage is that it provides pulpal anesthesia for 30 to 45 minutes without an extended period of soft tissue anesthesia, thus being extremely useful



**Figure 14.** Blanching of the palatal mucosa following infiltration

when bilateral treatment is planned. It is useful in pediatric or disabled patients when there is concern of postoperative tissue trauma to the lip or tongue. However, its use should be avoided in primary teeth with a developing permanent tooth bud as there have been reports of enamel hypoplasia in permanent teeth following PDL injection. Because it is injected in a site with limited blood circulation it can be used in patients with bleeding disorders.

The PDL technique is simple, requires only a small amount of anesthesia and produces instant anesthesia. An ultra-short needle is placed in the gingival sulcus on the mesial surface and advanced along the root surface until resistance is met. In multi-rooted teeth injections are made mesially and distally. If lingual anesthesia is needed the procedure is repeated in the lingual sulcus. Approximately 0.2ml of anesthetic is injected.

Considerable effort is needed to express the anesthetic solution placing a great deal of pressure on the anesthetic cartridge with the possibility of breakage. There are syringes specifically designed to enclose the cartridge and provide protection from breakage. Since so little anesthetic solution is necessary, it is recommended that when using a conventional syringe, expressing half the contents of the cartridge prior to injection will reduce the pressure exerted on the walls of the cartridge and reduce the likelihood of breakage.<sup>3</sup>

### Computer-Controlled Anesthetic Delivery System

"The Wand" (Milestone Scientific, Livingston, NJ) is a computer-controlled local anesthetic delivery system. The system consists of a conventional local anesthetic needle inserted into a disposable pen-like syringe. A foot-controlled microprocessor controls the delivery of the anesthetic solution through the syringe at a constant flow rate, volume and pressure. It has been reported that block, infiltration, palatal, and periodontal injections are more comfortable with the Wand than with conventional injection techniques.<sup>6</sup> Recently, computer-controlled intraosseous local anesthetic delivery system (Soan, NuSmile, Houston, TX) has been introduced in the market that has gained popularity.

## Complications of Local Anesthesia

### Anesthetic toxicity (overdose)

While rare in adults, young children are more likely to experience toxic reactions because of their lower weight. Most adverse drug reactions occur within 5-10 minutes of injection. Overdose of local anesthetics are caused by high blood levels of anesthetic as a result of an inadvertent intravascular injection or repeated injections. Local anesthetic overdose results in excitation followed by depression of the central nervous system and to a lesser extent of the cardiovascular system.

Early subjective symptoms of the central nervous system include dizziness, anxiety and confusion and may be followed by diplopia, tinnitus, drowsiness and circumoral numbness or tingling. Objective signs include muscle twitching, tremors, talkativeness, slowed speech and shivering followed by overt seizure activity. Unconsciousness and respiratory arrest may occur.

The initial cardiovascular system response to local anesthetic toxicity is an increase in heart rate and blood pressure. As blood plasma levels of the anesthetic increase, vasodilatation occurs followed by depression of the myocardium with subsequent fall in blood pressure. Bradycardia and cardiac arrest may follow.

Local anesthetic toxicity is preventable by following proper injection technique, i.e., aspiration during slow injection. Clinicians should be knowledgeable of maximum dosages based on weight. If lidocaine topical anesthetic is used it should factor into the total administered dose as it can infiltrate into the vascular system. After injection the patient should be observed for any possible toxic response as early recognition and intervention are the keys to a successful outcome.

### Allergic reactions

Although allergic reactions to injectable amide local anesthetics are rare, patients may exhibit a reaction to the bisulfite preservative added to anesthetics containing epinephrine. Patients with a sulfa allergy should not receive Articaine.

Patients may also exhibit allergic reactions to benzocaine topical anesthetics. Allergies can manifest in a variety of ways including urticaria, dermatitis, angioedema, fever, photosensitivity and anaphylaxis.

### Paresthesia

Paresthesia is the persistence of anesthetic symptoms beyond the expected duration. It can be caused by trauma to the nerve by the needle during injection. It can also be caused by hemorrhage in and around the nerve. Reports of paresthesia are more common with articaine and prilocaine and thus nerve block should be avoided in children with these local anesthetics. The tongue and lips are the most common areas affected. Most cases resolve in 8 weeks without treatment.

### Postoperative soft tissue injury

Accidental biting or chewing of the lip, tongue or cheek is a problem seen in very young pediatric mentally or physically disabled patients. Soft tissue anesthesia lasts longer than pulpal anesthesia and may be present for up to 4 hours after local anesthesia administration. The most common area of trauma is the lower lip and to a lesser extent the tongue, followed by the upper lip.

### **Several preventive measures can be followed:**

- Select a local anesthetic with a duration of action that is appropriate for the length of the planned procedure.
- Advise the patient and accompanying adult about the possibility of injury if the patient bites, sucks or chews on the lips, tongue and cheek. They should delay eating and avoid hot drinks until the effects of the anesthesia are totally dissipated.
- Reinforce the warning with patient stickers and by placing a cotton roll or rolled up gauze ("Bite on the ghost") in the mucobuccal fold if anesthesia symptoms persist.
- The management of soft tissue trauma involves reassuring the patient and parent (it's okay if the tissue turns white), allowing up to a week for the injury to heal, and lubricating the area with petroleum jelly or antibiotic ointment to prevent drying, cracking and pain.<sup>7</sup>

In May 2008 the FDA approved OraVerse (Novalar Pharmaceuticals, Inc., San Diego, CA) (phentolamine mesylate) as the first pharmaceutical agent indicated for the reversal of soft tissue anesthesia (anesthesia of the lip and tongue) resulting from an intraoral injection of a local anesthetic containing a vasoconstrictor. Phentolamine mesylate is a non-selective, competitive,  $\alpha$ -adrenergic antagonist that reverses the effects of extravasation of adrenergic agonists such as epinephrine. A submucosal injection of phentolamine mesylate after an injection of local anesthetic with vasoconstrictor enhances the clearance of the local anesthetic, by increasing blood flow in the injection area and accelerating recovery from soft tissue anesthesia. Studies have shown a 55.6 percent reduction in median time for return of normal lip sensation and a 60 percent reduction in median time for return of normal tongue sensation. Use in pediatric patients less than 3 years of age or <15 kg (33 lbs) has

not been established and thus its use is not recommended for patients in this category. In pediatric patients weighing between 15 kg and 30 kg, the maximum dose of phentolamine mesylate recommended is ½ cartridge (0.2 mg).

The phentolamine mesylate should be administered following the dental procedure using the same location(s) and technique(s) (infiltration or block injection) employed for the administration of the local anesthetic.<sup>8</sup>

### **Conclusion**

A clinician's ability to administer an effective, safe and atraumatic local anesthesia injection to a child or an adult is a major factor in creating a patient with a lifelong acceptance of dental treatment. The clinician should strive to learn and use appropriate behavior guidance techniques, and possibly the latest modalities of local pain control to create a pleasant and comfortable dental experience for the patient.

## Course Test Preview

To receive Continuing Education credit for this course, you must complete the online test. Please go to: [www.dentalcare.com/en-us/ce-courses/ce325/start-test](http://www.dentalcare.com/en-us/ce-courses/ce325/start-test)

### 1. Which of the following local anesthetic belongs to ester group?

- A. Lidocaine
- B. Mepivacaine
- C. Prilocaine
- D. Benzocaine

### 2. Which of the following amides is used as a topical anesthetic?

- A. Lidocaine
- B. Mepivacaine
- C. Prilocaine
- D. Articaine

### 3. Local anesthetic molecules have access to the nerve membrane at the \_\_\_\_\_.

- A. nasopalatine process
- B. palatine process
- C. nodes of Ranvier
- D. Hering-Breuer reflex

### 4. Which of the following term best relates to local anesthetic?

- A. Vasoconstrictors
- B. Vasodilators
- C. Highly alkaline
- D. Hemostatic agents

### 5. Vasoconstrictors are added to local anesthesia:

- A. To counteract the vasodilatory action
- B. To fasten the removal of local anesthetic
- C. To decrease the potential of local anesthetic
- D. To improve the comfort

### 6. Which of these amides provide the longest duration of action during a mandibular block?

- A. Lidocaine
- B. Articaine
- C. Mepivacaine
- D. Bupivacaine

### 7. Which of these anesthetics provides the longest duration of action during a maxillary infiltration?

- A. Procaine
- B. Lidocaine
- C. Tetracaine
- D. Mepivacaine



- 8. The maximum dosage for lidocaine 2% with 1:100,000 epinephrine is 2.0 mg/lb. What is the maximum number of cartridges of anesthetic solution that can be safely administered to a 30 pound patient?**
- A. 1.1 cartridges
  - B. 1.67 cartridges
  - C. 2.25 cartridges
  - D. 3.0 cartridges
- 9. Which statement is true regarding the local anesthetic?**
- A. Its action does not include depressant effects on the central nervous system
  - B. Its action does not include depressant effects on the cardiovascular system
  - C. Local anesthetics are bio transformed in the kidney and excreted in liver
  - D. Local anesthetics are bio transformed in the liver and excreted in kidneys
- 10. A patient presents with a documented allergy to procaine (an ester). Which of the following anesthetics should be avoided?**
- A. Injectable lidocaine with epinephrine
  - B. Topical lidocaine
  - C. Novocaine
  - D. Injectable lidocaine without epinephrine
- 11. Which anesthetic is contraindicated in a child under 2 years?**
- A. Injectable lidocaine
  - B. Topical lidocaine
  - C. Topical benzocaine
  - D. Injectable articaine
- 12. A patient presents with a documented allergy to bisulfites. Which of the following anesthetics should be avoided?**
- A. Lidocaine 2% with 1:100,000 epinephrine
  - B. Topical lidocaine
  - C. Topical benzocaine
  - D. Prilocaine 4% plain
- 13. A teenage patient presents for treatment admits to using cocaine daily. Which of the following anesthetics should be avoided?**
- A. Lidocaine 2% with 1:100,000 epinephrine
  - B. Topical lidocaine
  - C. Topical benzocaine
  - D. Prilocaine 4% plain
- 14. A clinician is about to load a cartridge of local anesthetic solution into a syringe and notices that the rubber stopper is flush with the lip of the glass cylinder. The dentist should:**
- A. Use the cartridge as intended.
  - B. Push the rubber stopper into the glass cylinder using the handle of a mouth mirror.
  - C. Discard the cartridge.
  - D. Heat the cartridge to room temperature.

**15. For most injections the bevel of the needle:**

- A. Should be oriented toward soft tissue.
- B. Should be oriented toward bone.
- C. The orientation is of no consequence.
- D. Should be at a maximum angle with the long axis of the needle.

**16. Which of the following needle gauge has the smallest internal diameter?**

- A. 21 gauge
- B. 25 gauge
- C. 27 gauge
- D. 30 gauge

**17. Needles should not be bent except for:**

- A. Infiltration injections
- B. Intrapulpal injections
- C. Block injections
- D. Intraosseous injections

**18. Topical anesthetics are effective up to a depth of:**

- A. 1.0 – 2.0 mm
- B. 2.0 – 3.0 mm
- C. 3.0 – 4.0 mm
- D. 4.0 – 5.0 mm

**19. The correct position of a patient in the dental chair during local anesthetic administration is:**

- A. The head and heart parallel to the floor and the feet slightly elevated.
- B. The head and heart parallel to the floor and the feet slightly lower than the rest of the body.
- C. The patient in the Trendelenburg position.
- D. The patient sitting upright.

**20. The temperature of anesthetic solution during administration should be:**

- A. As cold as possible without freezing
- B. Between room and body temperature
- C. Above 105 degrees Fahrenheit
- D. Of no significance to the patient's comfort

**21. When administering a local anesthetic injection to a child:**

- A. The child should be asked to close their eyes and open their mouth.
- B. The child should be shown the uncapped syringe and told it will only hurt a little.
- C. The assistant passes the uncapped syringe behind the patient's head.
- D. It doesn't matter what you say or do the child is going to cry.

**22. In a pediatric patient the mandibular foramen is:**

- A. Situated a lower level and more posterior than in an adult.
- B. At the same height as an adult.
- C. Higher and more anterior than in an adult.
- D. Lower and more anterior than in an adult.

**23. In studies comparing the effectiveness of mandibular infiltration to mandibular block in primary teeth it was found that:**

- A. The two techniques were equally effective for all dental treatment.
- B. The two techniques were equally effective for all restorative treatment, but the mandibular block was more effective for pulpotomies and extractions than mandibular infiltration.
- C. The two techniques were equally effective for all restorative treatment, but the mandibular infiltration was more effective for pulpotomies and extractions than the mandibular block.
- D. The mandibular block was more effective for all procedures than mandibular infiltration.

**24. The middle superior alveolar nerve block is effective in completely anesthetizing:**

- A. All teeth distal to the maxillary cuspid
- B. The permanent molars
- C. The maxillary first primary molars
- D. The maxillary second primary molars

**25. Phentolamine Mesylate (Ora Verse) is not recommended for use in children aged:**

- A. Less than 3 years
- B. 3 to 6 years
- C. 6 to 9 years
- D. Over 9 years.

## References

1. American Academy of Pediatric Dentistry. Use of local anesthesia for pediatric dental patients. *The Reference Manual of Pediatric Dentistry*. Chicago, Ill.: American Academy of Pediatric Dentistry; 2024:386-93.
2. U.S. Food and Drug Administration. Risk of serious and potentially fatal blood disorder prompts FDA action on oral over-the-counter benzocaine products used for teething and mouth pain and prescription local anesthetics. May 31, 2018. Accessed 25 September 2021.
3. Malamed SF. *Handbook of Local Anesthesia*, 7th edition, Mosby. 2019.
4. Coté CJ, Wilson S. American Academy of Pediatric Dentistry, American Academy of Pediatrics. Guidelines for Monitoring and Management of Pediatric Patients Before, During, and After Sedation for Diagnostic and Therapeutic Procedures. *Pediatr Dent* 2019;41(4):E26-E52.
5. Council on Clinical Affairs, American Academy of Pediatric Dentistry. Guideline on Use of Local Anesthesia for Pediatric Dental Patients. *Pediatr Dent*. 2015 Sep-Oct;37(5):71-7. PMID: 26531078.
6. Gibson RS, Allen K, Hutfless S, Beiraghi S. The Wand vs. traditional injection: a comparison of pain related behaviors. *Pediatr Dent*. 2000 Nov-Dec;22(6):458-62. PMID: 11132503.
7. Wright GZ, Kupietzky A. *Behavior Management in dentistry for Children*, 2nd Ed. John Wiley & Sons. Ames, IA, 2014, pp 107-124.
8. Hersh EV, Lindemeyer R, Berg JH, et al. Phase Four, Randomized, Double-Blinded, Controlled Trial of Phentolamine Mesylate in Two- to Five-year-old Dental Patients. *Pediatr Dent*. 2017 Jan 15;39(1):39-45.

## Acknowledgements

The author would like to thank the Residents and staff members of the Department of Pediatric Dentistry at Virginia Commonwealth University for their assistance in preparation of this presentation. Injection techniques were simulated, and no patients or clinicians were harmed or traumatized.

## About the Authors

### Jayakumar Jayaraman, BDS, MDS, FDSRCS, MS, PhD



Dr. Jayaraman is a Board certified Pediatric Dentist with clinical and research training from India, Hong Kong, England and the United States. He obtained master's degrees in Pediatric Dentistry from the University of Hong Kong and the University of Texas Health San Antonio. Dr. Jayaraman also received his Diploma in Pediatric Dentistry and Fellowship at the Royal College of Surgeons of Edinburgh, United Kingdom where he also serves as an Examiner. For the past 15 years he has taught Pediatric Dentistry and supervised research projects for pre-doctoral, post-doctoral and PhD students in different countries. His research involves topics in Evidence-Based Dentistry, Human Biology & Anthropology.

Dr. Jayaraman has published over 80 peer-reviewed scientific articles and reviewed articles for several leading pediatric, and multi-disciplinary journals. He serves as a member of Evidence Based Dentistry Committee and Consultant for Council of Clinical Affairs of the American Academy of Pediatric Dentistry. Dr. Jayaraman is currently Associate Professor of Pediatric Dentistry at Virginia Commonwealth University, Richmond, VA.

Email: [jayakumar83@hotmail.com](mailto:jayakumar83@hotmail.com)