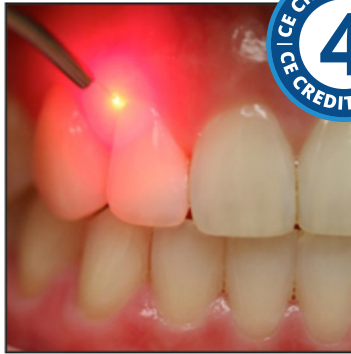

Lasers in Dentistry: Minimally Invasive Instruments for the Modern Practice



Course Author(s): Steven R. Pohlhaus, DDS

CE Credits: 4 hours

Intended Audience: Dentists, Dental Hygienists, Dental Students, Dental Hygiene Students

Date Course Online: 06/11/2012

Last Revision Date: 12/15/2025

Course Expiration Date: 12/14/2028

Cost: Free

Method: Self-instructional

AGD Subject Code(s): 10, 135, 250

Online Course: www.dentalcare.com/en-us/ce-courses/ce394

Disclaimer: Participants must always be aware of the hazards of using limited knowledge in integrating new techniques or procedures into their practice. Only sound evidence-based dentistry should be used in patient therapy.

Conflict of Interest Disclosure Statement

- The author is a laser trainer for Fotona, LLC.

Introduction - Lasers in Dentistry

Lasers have been used in dentistry for over 30 years. Recent developments in technology and differing wavelengths are creating a host of innovative treatments using various dental lasers. The modern practitioner needs to be familiarized with these devices and understand the possibilities and limitations of each device. Lasers in Dentistry: Minimally Invasive Instruments for the Modern Practice course will be designed to help educate the dentists and dental hygienists on lasers and clear the confusion regarding the various wavelengths available.

Course Contents

- Overview
- Learning Objectives
- Glossary
- History of Dental Lasers
- Laser Physics
 - Stimulated Emission
 - Thermal and Physical Implications of Pulsed Versus Continuous Emissions
- Tissue Interactions and Biological Effects
- Types of Dental Lasers
 - Erbium Lasers
 - Nd:YAG Lasers
 - Diode Lasers
 - CO₂ Lasers
- Laser Safety
- Laser Procedures
 - Laser Assisted Caries Diagnosis and Management
 - Restorative Dentistry
 - Surgical Applications of Dental Lasers
 - Periodontal Pocket Therapy
 - Laser Biopsy
 - Gingivectomy
 - Frenectomy
 - Flapless Crown Lengthening
 - Crown Lengthening with Minimally Invasive Flap Design
- Oral Surgery
- Lasers in Pediatric Dentistry
- Endodontic Applications
- Photobiomodulation (Biostimulation)
- Conclusion
- Course Test
- References
- About the Author

Overview

Shortly after the invention of the first ruby laser in 1960, researchers began investigating lasers potential use in dentistry. Dental lasers are now well-established in the dental armamentarium and their future potential is even greater. Recent developments in technology and differing wavelengths are creating a host of innovative treatments using various dental lasers. The modern practitioner needs to be familiarized with these devices and understand the possibilities and limitations of each device. This course is designed to help educate clinicians and to clear the confusion regarding the various wavelengths available.

Every discipline of dentistry can benefit from the use of these modern devices. There are currently five predominant types of lasers available for dental professionals: diode, Nd:YAG, Er:YAG, Er,Cr:YSGG, and CO₂.

Practitioners who want to integrate laser technology into their patient care face the daunting task of trying to sort through all the information available to make the right decision. Each device and wavelength available offer specific capabilities and limitations. A proper understanding of dental lasers' potential is not possible without a basic understanding of laser physics and biological interactions.

Learning Objectives

Upon completion of this course, the dental professional should be able to:

- Understand basic laser physics.
- Describe the concept of stimulated emission and what is an active medium.
- Differentiate between the concepts of energy versus power.
- Describe the difference between average power and peak power.
- Understand the three different laser emission modes and their role in peak power and thermal effects on target tissue.
- Understand the impact of pulse duration on peak power and thermal effects on target tissue.
- Define thermal relaxation.
- State the four types of tissue interaction.
- Define chromophore.
- Know the tissue temperatures that result in hyperthermia, coagulation, denaturation, vaporization, and carbonization.
- Describe the four major categories of dental lasers in use today.
- State the three safety practices required for all laser types.
- Understand the role of laser fluorescence in caries diagnosis and management.
- Know which types of lasers can be used on hard tissue.
- Understand the basic principles of hard tissue ablation and laser restorative techniques.
- Describe the various soft tissue surgical techniques.
- Understand laser assisted irrigation and its

- role in endodontics.
- State uses of photobiomodulation in dentistry.

Glossary

ablation – The process of removing tissue with a laser through vaporization or mechanical disruption.

absorption – Specific molecules in the tissue known as chromophores absorb the photons. The light energy is then converted into other forms of energy to perform work.

active medium – The laser component that produces laser light when stimulated. Dental lasers use crystals, gas, or semiconductors as their active media.

beam transfer hardware – Mirrors, optical fibers, or hollow wave guide hardware that carries the laser beam from the machine to the handpiece.

chromophore – The tissue component that absorbs the laser energy and converts it into thermal energy.

coherence – The tendency of laser light waves to travel with their peaks and valleys in unison.

continuous wave mode – A form of laser emission when the laser is on continuously.

divergence – The tendency of the laser beam to spread outward once it exits the handpiece. Divergence varies depending on the specific laser and hardware used.

energy density – The amount of laser energy in an area of exposed tissue.

Er,Cr:YSGG – Erbium, Chromium - doped Yttrium Scandium Gallium Garnet crystal.

Er:YAG – Erbium-doped Yttrium Aluminum Garnet crystal.

free running pulsed mode – A form of laser emission where laser light is emitted in discrete pulses with specific, measurable temporal characteristics.

gated wave mode – A form of laser emission where the beam is blocked part of the time by a shutter device creating a pulsed laser emission.

laser – Light Amplification by Stimulated Emission of Radiation.

millijoule – Measurement of energy.

monochromatic – In laser science refers specifically to the fact that lasers produce a single wavelength of light.

Nd:YAG – Neodymium-doped Yttrium Aluminum Garnet crystal.

optical pumping – Flash lamp stimulation of an active medium.

output coupler – A semi-transparent mirror in the resonator that the laser beam passes through into the beam transfer hardware.

photobiomodulation – The process whereby laser energy is used to stimulate positive clinical outcomes such as pain relief and improved healing.

power – Rate of doing work, measured in Watts.

pulse duration – The amount of time a laser pulse is on, measured in microseconds.

reflection – When the laser beam bounces off the surface with no penetration or interaction at all.

resonator – The mirrored chamber surrounding the active medium that helps to amplify the laser light produced.

scattering – The tendency of laser light to bounce in multiple directions once it enters tissue.

stimulated emission – The process whereby the active medium is stimulated by an external source of light or electricity to produce laser light.

thermal relaxation – The ability of tissue to absorb and dissipate heat produced by pulsed dental lasers.

transmission – When laser energy can pass through superficial tissues to interact with deeper areas.

watt – Power measurement of energy produced over time.

History of Dental Lasers

In 1916 Albert Einstein wrote to a friend “A splendid light has dawned on me about the absorption and emission of radiation.” Einstein never created a laser, but at that time he theorized the concept of stimulated emission, which is the scientific basis for the creation of laser light. The first ruby laser was developed in 1960 and many other lasers were created rapidly thereafter. Dental researchers began investigating lasers’ potential and Stern and Sognaes reported in 1965 that a ruby laser could vaporize enamel.³ The thermal effects of continuous wave lasers at that time would damage the pulp.⁴ Other wavelengths were studied over the ensuing decades for both hard and soft tissue applications.

Practitioners and researchers began to find clinical oral soft tissue uses of medical CO₂ and Nd:YAG lasers until in 1990 when the first pulsed Nd:YAG laser designed specifically for the dental market was released. The year 1997 saw the FDA clearance of the first true dental hard tissue Er:YAG laser and the Er,Cr:YSGG a year later. Semiconductor based diode lasers emerged in the late 1990s as well. Recently a CO₂ laser was approved for use on tooth structure.

Laser Physics

Stimulated Emission

The word laser is an acronym standing for “Light Amplification by Stimulated Emission of Radiation.” A laser beam is created from a substance known as an active medium, which when stimulated by light or electricity produces photons of a specific wavelength. Lasers are characteristically monochromatic, unidirectional, coherent, and emitted from a

stimulated active medium. Monochromaticity means that a laser beam is made of a single wavelength of light, and all dental lasers are found in the visible or infrared portion of the electromagnetic spectrum. Once a laser beam is produced it will travel in one direction (unidirectional), though the divergence of the beam varies by type of laser and the associated transmission hardware. Coherence is the property that not only is a laser a single wavelength but all the peaks and valleys of each wave travel in unison.

The active media in dentistry can be solid state, gas, or semiconductor. Solid state lasers are a crystal matrix host doped with the light emitting, excitable atoms; such as erbium laced yttrium, aluminum, and garnet (Er:YAG). CO₂ is a popular laser where the active medium is sealed in an air tight chamber. Diode lasers have a semiconductor that when stimulated with electricity, laser light is emitted.

Stimulated emission is a phenomenon that occurs within the active medium. For example, in solid state Er:YAG lasers the erbium is stimulated by light from a flashlamp with a process known as optical pumping. As an erbium atom absorbs a photon, its electrons are elevated to higher energy level. When the electrons return to a lower energy state, two identical photons are emitted and these photons can further stimulate more atoms in a chain reaction, resulting in amplification of the light produced. Mirrors surrounding the active medium called a resonator further increase this light energy. One of the mirrors called the output coupler is less than one hundred percent reflective. Light leaks from the output coupler, and these are the photons that form the laser beam. Once the beam is created it is carried to the target tissue by various types of beam transfer hardware. Mirrors in articulated arms and optical fibers are common examples of this hardware.

The laser beam is collimated and exits in the handpiece as a column of light. The beam will diverge at various rates depending on the device, the handpiece, and the tip used. Once the beam reaches the tissue it will have a specific spot size depending on the distance

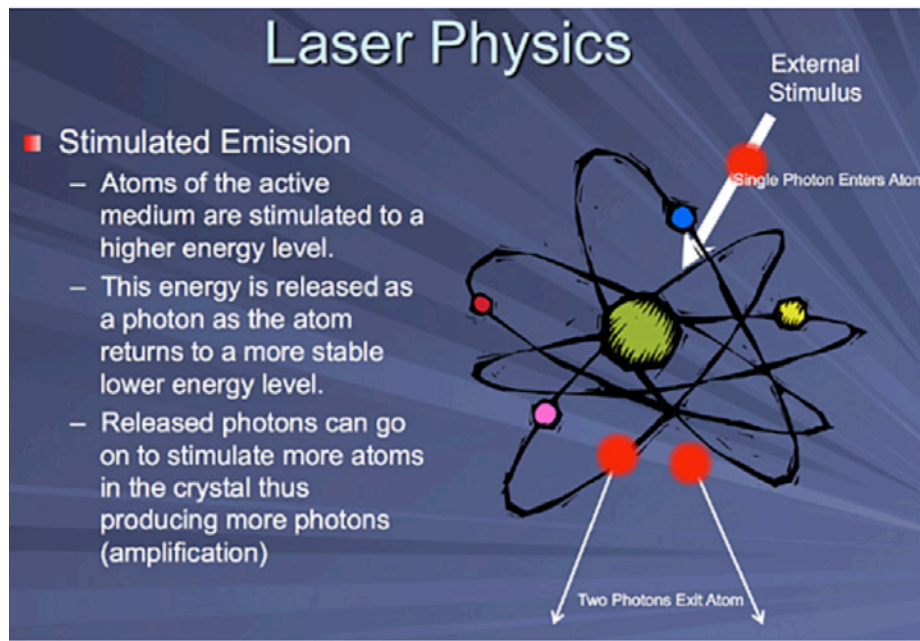


Figure 1. Stimulated Emission.

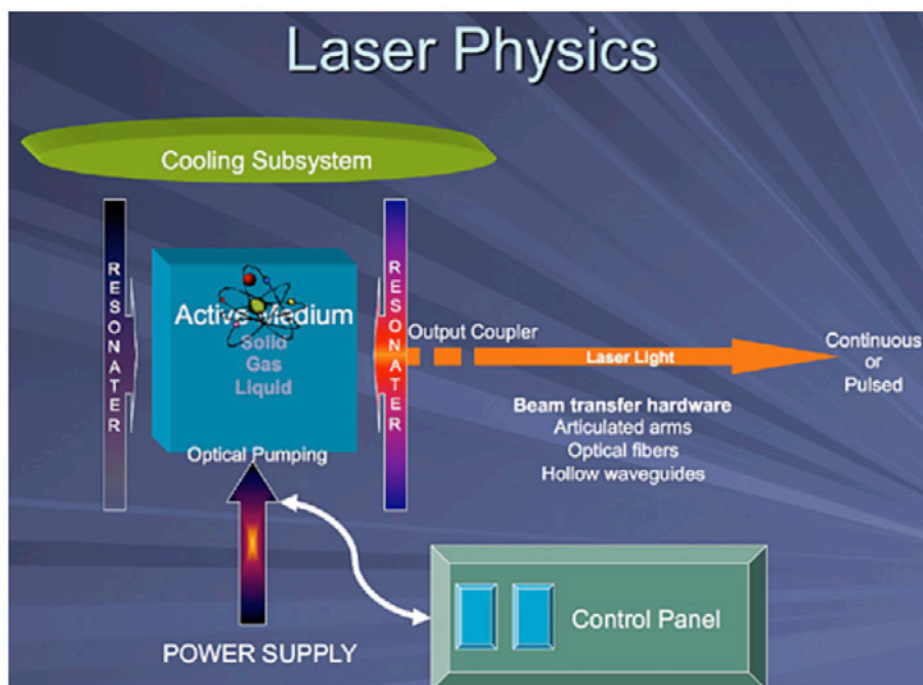


Figure 2. Diagram of the basic components of dental lasers.

from the handpiece and its specific divergence. The energy density refers to the actual amount of energy reaching the tissue within the spot size. This energy density varies considerably depending on the parameters of energy, divergence, and distance.

Thermal and Physical Implications of Pulsed Versus Continuous Emissions

Energy is the ability to work and is measured in Joules. The measuring unit for most dental laser applications is the millijoule (mJ), and this is a parameter that is controlled by the operator.

Power is the rate of doing work, or energy used over a period of time and is measured in Watts (W). One Watt equals one Joule per second. These are typically the watts displayed on the machines' control panels. A laser beam can be emitted either as a continuous beam or in a pulsed fashion.

The pulse rate per second is measured in Hertz (Hz). The wattage displayed on the laser unit is a product of the Millijoule (energy) per pulse times the number of pulses per second (hertz). Peak Power refers to the power level in each individual laser pulse and this measurement is not visible to the operator on most devices, yet it is the most important variable dictating how the laser beam will interact with the target tissue.

Continuous wave emission mode means the laser is on the whole time it is turned on. In these lasers peak power equals the wattage output displayed. There are two basic forms of pulsed laser modes: gated wave and free running pulsed. A gated wave pulse is usually created with a shutter that blocks the laser

beam from reaching the handpiece and target tissue at varying speeds. This pulse form is sometimes referred to as "chopped." The laser is on constantly, but the shutter device blocks the light from transmitting. "Superpulsed" lasers are a form of gated lasers with extremely short pulse durations.

Free running pulsed lasers are not on constantly but emit photons in powerful bursts of energy measured in millionths of seconds. To better understand these concepts one can use an example of a flashlight. When a flashlight is turned on it is in continuous wave mode, moving one's hand back and forth across the beam is gated wave mode, and turning it on and off repeatedly is free running pulsed mode. Each of these temporal emission modes has important characteristics when the laser energy interacts with tissues that need to be understood well.

Peak power can be a difficult concept to understand but its importance cannot be overstated. Each pulse has a fixed amount of energy, usually the millijoules displayed on

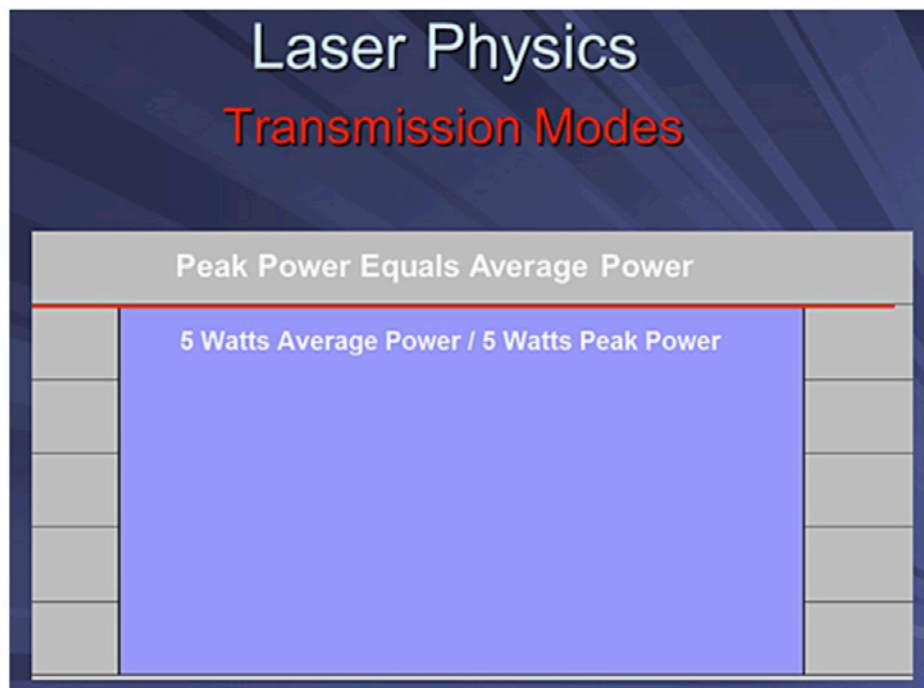


Figure 3. Peak power equals average power. A laser running in continuous mode has equal peak power and average power. Average power is what is displayed on the control panel. Peak power is not shown but can be calculated.

Laser Physics

Transmission Modes

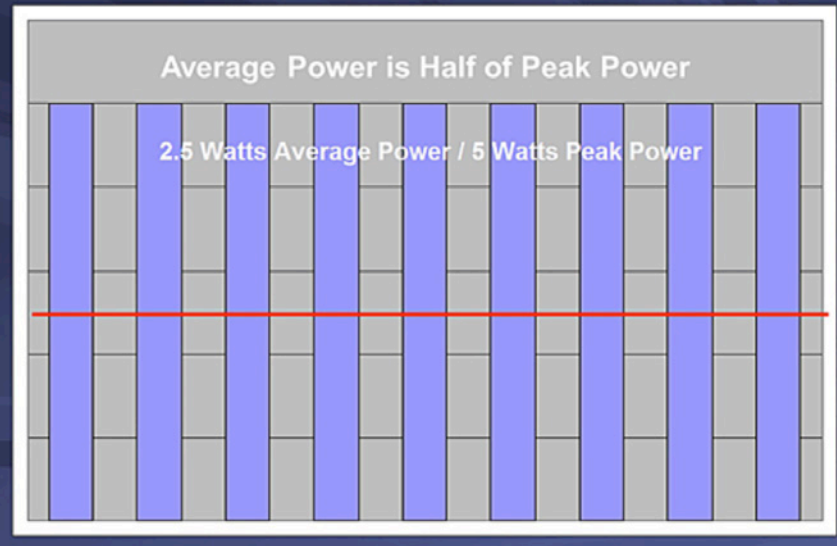


Figure 4. Average power is half of peak power. In a simple gated wave laser average power is half peak power. Here a blinking shutter blocks the laser beam half the time.

Laser Physics

Transmission Modes

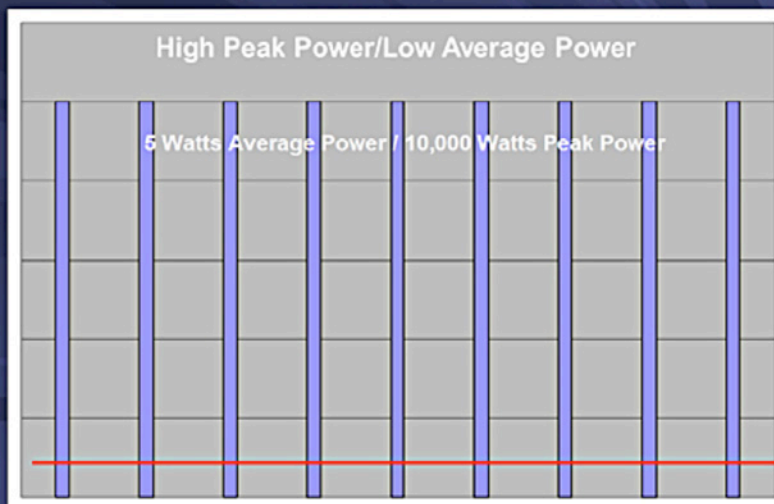


Figure 5. High peak power/low average power. Average power is a tiny fraction of peak power in free running pulsed mode. These lasers flash off and on like a strobe light in short bursts of energy from 50 to 1000 millionths of a second (microseconds). In this example a laser displaying 5 watts running at ten hertz with a fifty microsecond pulse will have peak power of 10,000 watts per pulse. This powerful burst of energy allows for efficient tooth and bone ablation with minimal thermal effects.

the unit. As shorter pulses are used this same energy is effectively squeezed into a smaller space, which increases the peak power of the pulse. One can think of a rubber band around a wrist as an analogy. If the rubber band is lifted three inches, it will have a fixed amount of energy in it. Now if the rubber band is slowly returned to the wrist, it will not hurt a bit. If it is let go, the energy is released in a much shorter time and it will sting and make a popping sound. Yet the actual energy expended is identical. Hard tissue dental lasers can have peak powers in the thousands of watts, and these short bursts of extreme power allow for the efficient cutting of enamel, dentin, and bone.

The thermal implications of the three pulse modes are profound. Thermal relaxation refers to various tissues' inherent ability to dissipate heat. In continuous mode there is no thermal relaxation at all, and potentially damaging heat can build in the tissue quickly. Gated wave mode presents basically a half on/half off exposure to laser energy and the ability of the tissue to absorb the heat is limited. Superpulsed lasers improve on the standard gated mode's thermal effects through sophisticated pulse time control. Thermal relaxation occurs the most when free running pulsed lasers are used. Each pulse is temporally very short, anywhere from 50 to one thousand millionths of a second depending on which device and settings are used. There is adequate time between each pulse to allow the tissue to absorb and dissipate the heat to minimize thermal damage.

This lack of tissue heating results in the lowered post-operative discomfort and predictable healing seen after many laser procedures. It also contributes to the ability to perform many operative dentistry procedures and even some soft tissue ones without local anesthesia. An excellent analogy for free running pulsed lasers is if a finger is moved rapidly back and forth through a candle flame it will not burn as the tissue can absorb and dissipate the momentary high heat exposure. If the same "pulsing" finger is moved slowly through the flame it will get burned eventually (gated mode). Placing the finger in the flame

and holding it there will cause rapid thermal damage (continuous mode).

Tissue Interactions and Biological Effects

Once a laser beam is produced it is aimed at tissue to perform a specific task. As the energy reaches the biological interface one of four interactions will occur: reflection, transmission, scattering, or absorption.

- **Absorption** – Specific molecules in the tissue known as chromophores absorb the photons. The light energy is then converted into other heat to perform work.
- **Reflection** – The laser beam bounces off the surface with no penetration or interaction at all. Reflection is usually an undesired effect, but a useful example of reflection is found when Erbium lasers reflect off titanium allowing for safe trimming of gingiva around implant abutments.
- **Transmission** – The laser energy can pass through superficial tissues to interact with deeper areas. Retinal surgery is an example; the laser passes through the lens to treat the retina. The deeper penetration seen with Nd:YAG and diode lasers is an example of tissue transmission as well.
- **Scattering** – Once the laser energy enters the target tissue it will scatter in various directions. This phenomenon is usually not helpful but can help with certain wavelengths biostimulative properties.

Absorption is the most important interaction. Each wavelength has specific chromophores that absorb their energy. This absorbed energy is converted into thermal and and/or mechanical energy that is used to perform the work desired. Near infrared lasers like diodes and Nd:YAGs are mostly absorbed by pigments such as hemoglobin and melanin. Erbium and CO₂ lasers are predominantly absorbed by water and hydroxyapatite. The shorter, near infrared wavelengths of diodes and Nd:YAG lasers also penetrate tissue more deeply than the longer, mid infrared wavelengths of the erbium and CO₂ lasers.

There are five important types of biological effects that can occur once the laser photons enter the tissue: fluorescence, photothermal, photodisruptive, photochemical, and photobio-

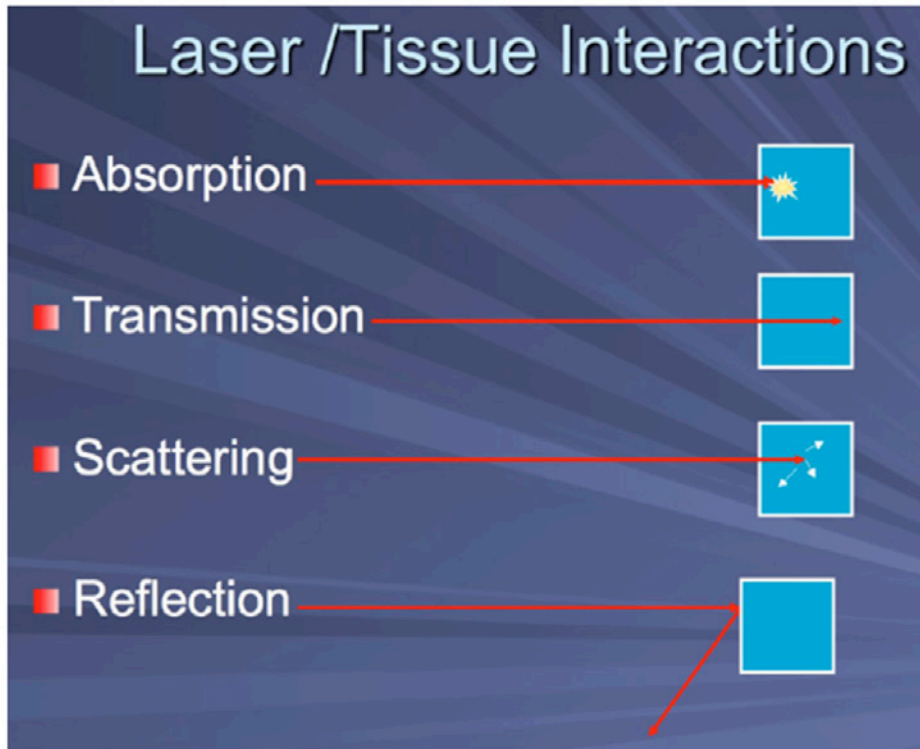


Figure 6. The four tissue interactions.

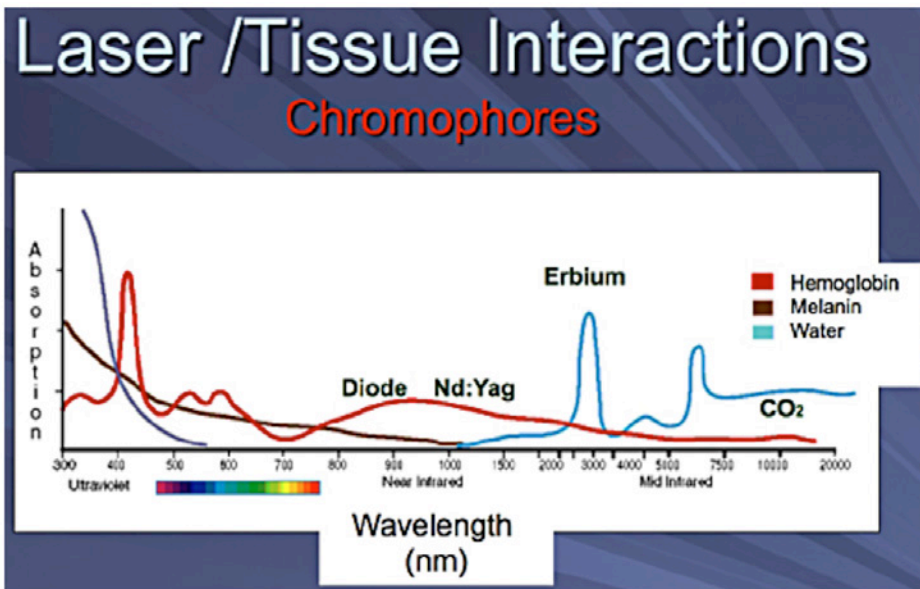


Figure 7. The wavelengths of the four most common dental lasers are shown where they occur in the electromagnetic spectrum. All are in the non-ionizing infrared part of the spectrum. Absorption patterns of the chromophore water, melanin, and hemoglobin are superimposed on the graph. This absorption is what converts light energy into thermal and/ or mechanical energy to do work.

modulation.

- **Fluorescence** is when a second wavelength of light is emitted from tissue molecules after exposure to laser light. An example in dentistry is when actively carious tooth structure is exposed to the 655nm visible wavelength of the Diagnodent diagnostic device. The amount of fluorescence is related to the size of the lesion, and this information is useful in diagnosing and managing early carious lesions.
- **Photothermal** effects occur when the chromophores absorb the laser energy and heat is generated. This heat directly vaporizes the tissue and is used to incise or remove tissues. Photothermal interactions predominate when most soft tissue procedures are performed with dental lasers. Photothermal ablation is also at work when CO₂ lasers are used on teeth as hard tissue is vaporized during removal. Heat is generated during these procedures and great care must be taken to avoid thermal damage to the tissues.
- **Photodisruptive** effects (or **photoacoustic**) can be a bit more difficult to understand. Hard tissues are removed through a process known as photodisruptive ablation. Short-pulsed bursts of laser light with extremely high power interact with water in the tissue causing rapid thermal expansion of the water molecules. This causes a thermo-mechanical acoustic shock wave that is capable of disrupting enamel and bony matrices quite efficiently. Erbium lasers' high ablation efficiency results from these micro-explosions of superheated tissue water in which their laser energy is predominantly absorbed. Thus, tooth and bone are not vaporized but pulverized instead through the photomechanical ablation process. This shock wave creates the distinct popping sound heard during erbium laser use. Thermal damage is very unlikely as almost no residual heat is created when used properly, particularly when the concept of thermal relaxation is considered.
- **Photochemical** reactions occur when photon energy causes a chemical reaction. These reactions are implicated in some of the beneficial effects found in biostimulation discussed below.
- **Photobiomodulation** refers to lasers

ability to speed healing, increase circulation, reduce edema, and minimize pain. Many studies have exhibited effects such as increased collagen synthesis, fibroblast proliferation, increased osteogenesis, enhanced leukocyte phagocytosis, and the like with various wavelengths. The exact mechanism of these effects is not clear, but it is theorized they occur mostly through photochemical and photobiological interactions within the cellular matrix and mitochondria. Biostimulation is used dentally to reduce postoperative discomfort and to treat maladies such as recurrent herpes and aphthous stomatitis. Low Level Laser Therapy (LLLT) and Biostimulation are other terms used to describe this phenomenon.

When a dental laser is employed, it can be used in contact mode or non-contact mode. The laser tip directly touches the target tissue in contact mode. In non-contact mode the laser is pointed at a distance from the target tissue anywhere from a few millimeters, such as in operative dentistry, or up to several centimeters when performing biostimulation.

When a laser heats oral tissues certain reversible or irreversible changes can occur:

- Hyperthermia – below 50 degrees C
- Coagulation and Protein Denaturation – 60+ degrees C
- Vaporization – 100+ degrees C
- Carbonization – 200+ degrees C

Irreversible effects such as denaturation and carbonization result in thermal damage that cause inflammation, pain and edema.

Types of Dental Lasers

The dental lasers in common use today are Erbium, Nd:YAG, Diode, and CO₂. Each type of laser has specific biological effects and procedures associated with them. A solid understanding of each of these categories of devices is imperative for any clinician hoping to pursue laser use in their practice.

Erbium Lasers

Erbium lasers are built with two different crystals, the Er:YAG (yttrium aluminum garnet crystal) and Er,Cr:YSGG (chromium sensitized

yttrium scandium gallium garnet crystal). They do have different wavelengths, Er:YAG has 2940 nm and Er,Cr:YSGG has 2780 nm. Though similar, there is a significant water absorption difference between these two wavelengths. Er:YAG wavelength is at the peak of water absorption in the infrared spectrum whereas the Er,Cr:YSGG exhibits approximately one third less absorption. The Er,Cr:YSGG has also been shown to have significantly deeper thermal penetration in tooth structure as well. In general terms they behave similarly and will simply be referred to as erbium lasers.

The erbium lasers are hard and soft tissue capable and have the most FDA clearances for a host of dental procedures. Their primary chromophore is water, but hydroxyapatite absorption occurs to a lesser degree. Photothermal interactions predominate in soft tissue procedures and photodisruptive in hard tissue. Thermal relaxation is excellent and very little collateral thermal damage occurs in tissues when proper parameters are followed.

Tooth preparation is quite efficient with erbium devices and many procedures can be done without local anesthesia. Smear layer is virtually eliminated and the laser has a significant disinfecting effect on the dentin and enamel to be restored. Bone cutting with erbium lasers results in minimal thermal and mechanical trauma to adjacent tissues. Studies have demonstrated the atraumatic effect and excellent healing response following erbium resection of bone.¹² Very short laser pulses of 50 to 100 microseconds are typically used for hard tissue procedures.

Erbium lasers are excellent soft tissue devices as well. The main parameters that differ from hard tissue uses are much longer pulse durations (300-1000 microseconds) and less or no water spray. Though slightly more thermal than the hard tissue settings, there still is quite a bit of thermal relaxation and minimal heat penetration into underlying tissues. Consequently, clinicians routinely observe rapid healing with minimal postoperative pain when soft tissue procedures are done with erbium lasers. They can be used anywhere a scalpel is employed including periodontal

procedures, gingival contouring, biopsies, frenectomies, pre-prosthetic procedures and the like. Erbium lasers can also be used to safely scale root surfaces during periodontal procedures which has the added benefit of root surface decontamination.²⁵

Nd:YAG Lasers

Nd:YAG lasers were the first types of true pulsed lasers to be marketed exclusively for dental use in 1990. They are a near infrared wavelength of 1064 nm. This wavelength is absorbed by pigment in the tissue, primarily hemoglobin and melanin. Photothermal interaction predominates and the laser energy can penetrate deeply into tissues. Contact and non-contact mode are both utilized depending on the procedure being performed. Nd:YAG also have excellent biostimulative properties. Nd:YAG lasers have the unique capacity to safely coagulate blood, a phenomenon used postoperatively with extractions and soft tissue procedures. . This effect is maximized when the pulse duration is set at 650 microseconds.

These lasers are primarily used for periodontal treatments. Their proclivity for pigmented tissue allows for effective debridement and disinfection of periodontal pockets. Bacterial decontamination in tissues treated with Nd:YAG laser energy also contributes to resolution of periodontal infection. As noted earlier they stimulate fibrin formation with longer pulse duration settings and this phenomenon is utilized to biologically seal treated pockets and act as a scaffold for reattachment. The ability to form fibrin is also utilized when forming clots in extraction sites which can help prevent alveolitis and enhance osteogenesis. Nd:YAG lasers can also be used for multiple soft tissue procedures such as gingivectomy, frenectomy, impression troughing, and biopsy. The deep penetration and the near infrared wavelength of these lasers also make them ideal for photobiomodulation procedures.

Diode Lasers

Diode lasers are becoming quite popular due to their compact size and relatively affordable pricing. A specialized semiconductor that produces monochromatic light when

stimulated electrically is common to all diode lasers. A simple laser pointer is an example of a diode laser. Diode lasers can be used in both contact and non-contact mode and can function with continuous wave or gated pulse modes. They are not capable of free running pulsed mode. Diode lasers are invisible near infrared wavelengths and current machines range from 805–1064 nm. One exception is the Diagnodent caries diagnostic laser which uses a visible red wavelength of 655 nm.

Diode lasers are soft tissue only. The chromophores are pigments such as hemoglobin and melanin, similar to the Nd:YAG absorption spectrum. However, most surgical procedures with diodes are not as a result of laser photons interacting with tissue. Diode laser fibers are “initiated” by burning articulating paper on the tip. This initiation causes the light energy to be absorbed by the burnt material on the tip, effectively making it a hot piece of quartz. The laser energy cuts indirectly by heating up the fiber optic tip. Diode lasers do not have enough peak power to efficiently cut tissue on their own without initiation. If one defines “laser dentistry” as light interacting with tissue, then diode procedures are not laser dentistry ones.

They are quite effective for a host of intraoral soft tissue procedures such as gingivectomy, biopsy, impression troughing, and frenectomy. Diode lasers also exhibit bactericidal capabilities and can be used for adjunctive periodontal procedures. They also are used for laser assisted tooth whitening. Diode lasers have excellent photobiomodulation properties as well.

CO₂ Lasers

CO₂ Lasers have been available in medicine since the early 1970s and have been used in dentistry for more than 25 years. They are a 10,600 nm infrared wavelength, which is highly absorbed by water. Articulated arms or hollow waveguides are used to transmit CO₂ laser beams and quartz optical fibers cannot be used. The CO₂ gas is in a chamber with nitrogen and helium and the active medium is pumped with an electrical current. CO₂ lasers are very efficient and exhibit excellent

hemostasis. The traditional 10,600 nm CO₂ lasers are currently for soft tissue uses only. They are continuous wave lasers that can be operated in gated wave modes, including what are termed “superpulsed”. It is important to note that the superpulsed mode is not a free running pulsed mode. These superpulsed gated modes offer improved surgical control with less charring of tissue.

CO₂ lasers are excellent tools for incising tissue for multiple purposes. Incisional and excisional biopsies, frenectomy, gingivectomy, pre prosthetic procedures, and the like are all achieved with excellent hemostasis. Sutures are rarely needed and the controlled thermal effects and sealing of nerve endings often makes for a very comfortable post-operative experience for the patient. This wavelength is also very effective for ablation and vaporization of leukoplakia and dysplasia.

A hard tissue capable CO₂ laser became available recently. This laser’s CO₂ molecule uses an oxygen isotope that creates a beam at 9300 nm. This wavelength has a high absorption affinity for hydroxyapatite that allows for efficient vaporization of tooth structure. Its water absorption is much lower than Erbium lasers so hydroxyapatite absorption and vaporization predominates when cutting enamel, dentin, and bone. Hard tissue ablation with the 9300 nm CO₂ laser is a photothermal event, not photoacoustic. As a result, much higher temperatures are generated, and much higher pulse rates are needed to cut.

Laser Safety

Proper safety procedures must be put in place by any practice implementing laser use. A laser safety officer needs to be appointed by the clinic whose job it is to implement and monitor safety protocols. The manufacturer of each device is obliged to train the providers the important safeguards needed for each device. Common safety practices include:

- **Eye Protection** – The patient, clinical staff and any observers must wear protective eyewear specific for the wavelength being used.
- **Plume Control** – Laser procedures create

a plume that may contain hazardous chemicals and microflora. Standard dental high-speed evacuation properly used is adequate to control the plume. Good quality masks need to be worn by the clinicians. N95 masks offer excellent protection.

- **Sharps** – Scored laser tips of quartz fibers are considered sharps and need to be disposed of as such.
- **Warning Sign** – Warning signs need to be in a visible place and access to the operatory limited.

Laser Procedures

There is not a discipline in dentistry where lasers are not helpful. Examples in each discipline will be presented including the following:

- Laser assisted caries diagnosis and management
- Restorative dentistry
- Surgical applications of dental lasers
- Oral diagnosis/oral medicine
- Oral surgery
- Periodontics – gingivectomy, crown lengthening, periodontitis treatment
- Pediatric – restorative, frenectomy

- Endodontics
- Photobiomodulation

Laser Assisted Caries Diagnosis and Management

The Diagnodent caries detection laser is a portable, battery powered diode laser. Its 655 nm visible wavelength causes active caries to fluoresce. The amount of fluorescence is measurable and is correlated to the size and direction of the lesion. When combined with Caries Management by Risk Assessment (CAMBRA) it can be a very useful tool for detecting and managing early caries.¹³

The laser gives a reading of zero to 99. A general guideline is that occlusal lesions above 30 likely need restoration and those from ten to 30 are potentially reversible. The Diagnodent is an excellent tool for measuring the effectiveness of non-surgical interventions such as increased fluoride exposure, dietary changes, and the like.⁶ It also is excellent at detecting “hidden caries” in pits and fissures. Occlusal lesions in a fluoridated population can often be quite advanced before cavitation can be detected with an explorer. Laser

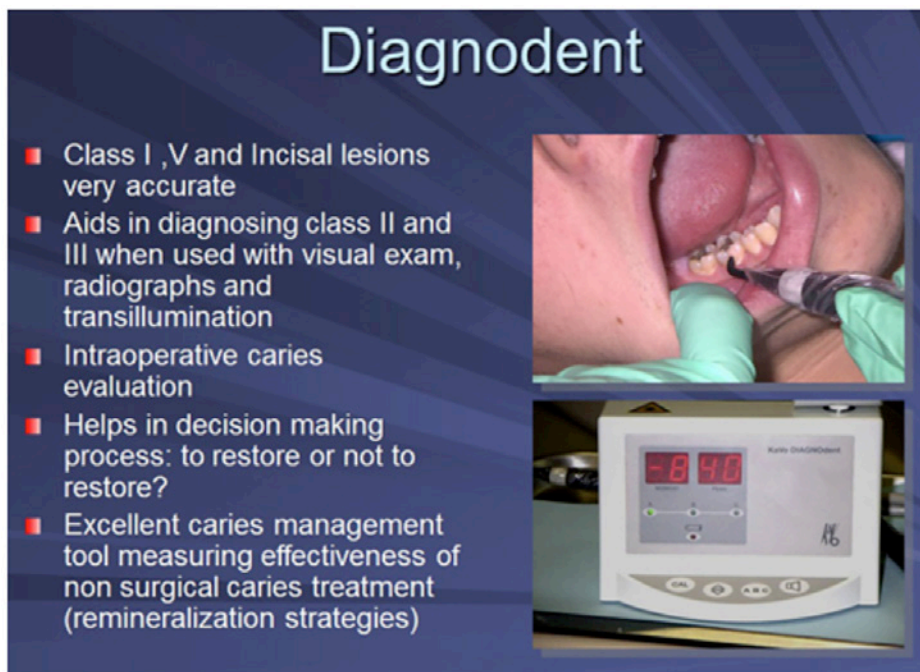


Figure 8. Diagnodent. Diagnodent caries diagnostic device. Active caries fluoresces when exposed to 655 nm visible laser light. The amount of fluorescence is measurable and is correlated with the size of the lesion.

diagnosis can help solve this vexing problem for the modern dentist when paired with risk assessment and high magnification visualization.

The Diagnodent's primary indication is for detecting class I, class V, and incisal caries. It can also be useful when paired with transillumination for detecting permanent class III and primary class 2 lesions. Experienced clinicians have found they can greatly reduce the need for radiographs to detect these particular lesions. Laser caries detection can also be used intraoperatively to check minimally restorative preparations for complete decay removal.

Restorative Dentistry

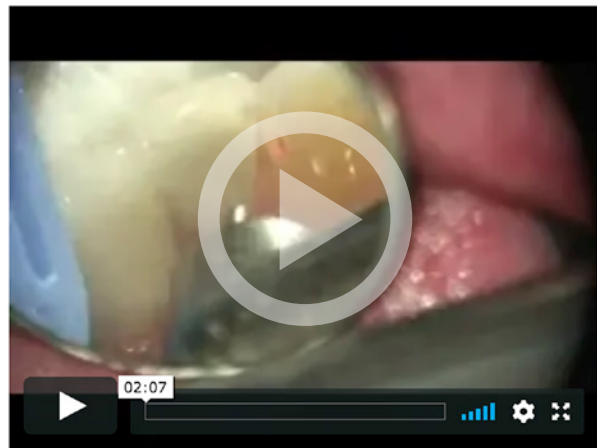Er:YAG and Er,Cr:YSGG lasers are FDA approved for cutting tooth, bone and soft tissue. Their extremely short pulses and high peak power allow for efficient enamel and dentin photoacoustic ablation. Erbium lasers can prepare all classes of restorations. Many restorations can be accomplished without local anesthesia. Experienced laser practitioners report needing anesthesia only ten to 20% of the time, usually for amalgam removal, larger lesions, or particularly sensitive teeth.

Advantages of using erbium laser for operative dentistry include:

- Precise ablation allows for minimally invasive preparations
- Smear layer removal
- Disinfection of preparations
- Eliminates the noise, heat, and vibration of high speed rotary instrumentation
- Reduced need for local anesthesia
- Selective caries removal due to carious dentin's higher water content and softer consistency

Surgical Applications of Dental Lasers

All four major wavelengths of dental lasers can be used as soft tissue surgical devices. The primary chromophores for diode and Nd:YAG lasers are pigments such as hemoglobin and melanin. Diode lasers when used surgically use the indirect heat generated by the pigment initiated on to the fiber tip. The erbium and CO₂ lasers are mostly absorbed by water. All these



Video 1. A Class III lesion prepared with an Er:YAG laser. This patient was not anesthetized and was comfortable throughout the procedure.

Source: Dr. Mark Collona.

[Click on image to view video online.](#)

lasers use photothermal effects to incise tissue whereby photons absorbed are converted to heat energy to do work. Diode and Nd:YAG lasers exhibit much deeper tissue penetration and thermal effects than the erbium lasers and the potential for tissue damage is greater. As such, proper training and an understanding of the biological effects of lasers are imperative for any provider wanting to pursue laser dentistry.

Thermal relaxation varies depending on the laser and parameters employed. Erbium lasers exhibit the greatest thermal relaxation due to their short free running pulses, low hertz, and minimal tissue penetration. Histological examination of erbium incised tissue exhibits almost no tissue damage or inflammatory response. Nd:YAG lasers also run on free running pulsed mode with pulse durations as short as 100 microseconds. However, due to their high absorption by pigment and deeper penetration they exhibit significantly greater heating of tissue and this factor needs to be respected by the practitioner. Diodes and CO₂ lasers run in continuous or gated wave mode so they have much less thermal relaxation capabilities. Recent technological advances in so called "superpulsed modes" have helped improve the thermal parameters of these lasers, but it is important to note this is not a true free running pulsed mode.

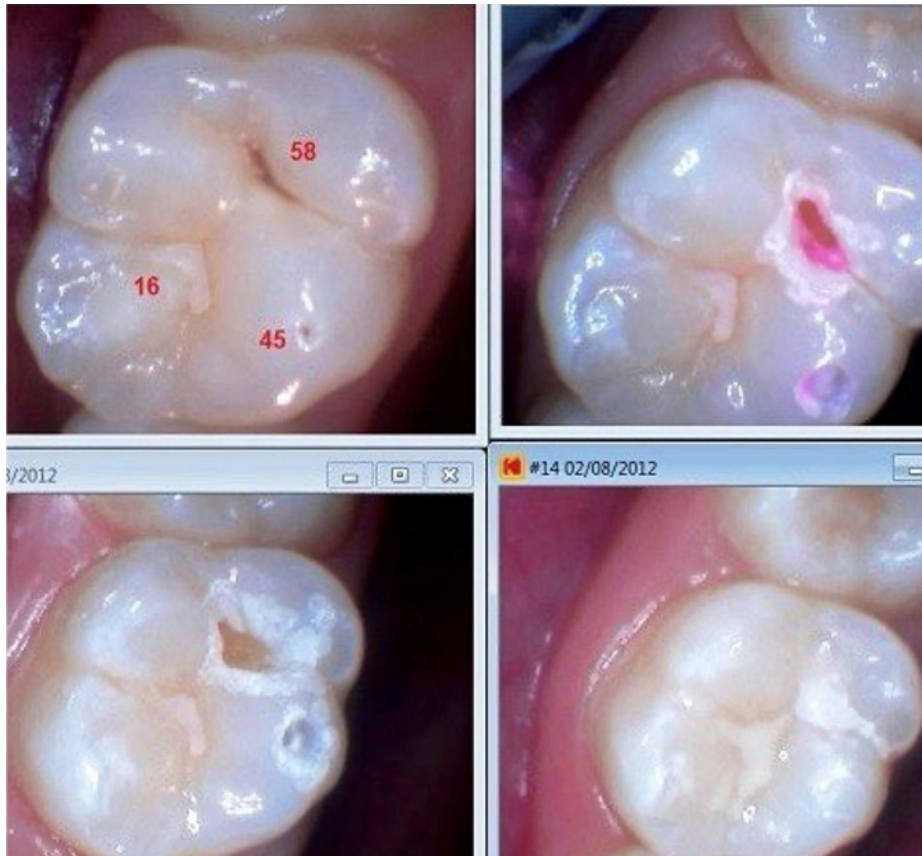


Figure 9a. Class I Composite.

1. No discernible explorer stick but Diagnodent indicated caries in distal fissure, mesiolingual cusp, and some early decay under the sealant in the mesial pit.
2. Some remaining decay revealed by caries indicator in distal fissure after initial Er:YAG laser preparation.
3. Final preparation; no anesthesia was used.
4. Final restoration, the mesial sealant was removed with the laser and resealed.

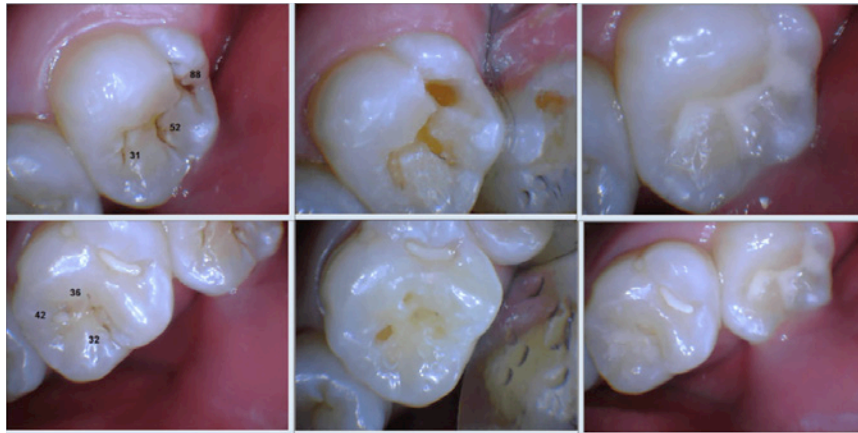


Figure 9b. Class I Composite.
The Diagnodent helps guide the clinician regarding the location and depth of the lesions. The minimally invasive preparations were restored with a Glass Ionomer (Equia Forte/Fuji).

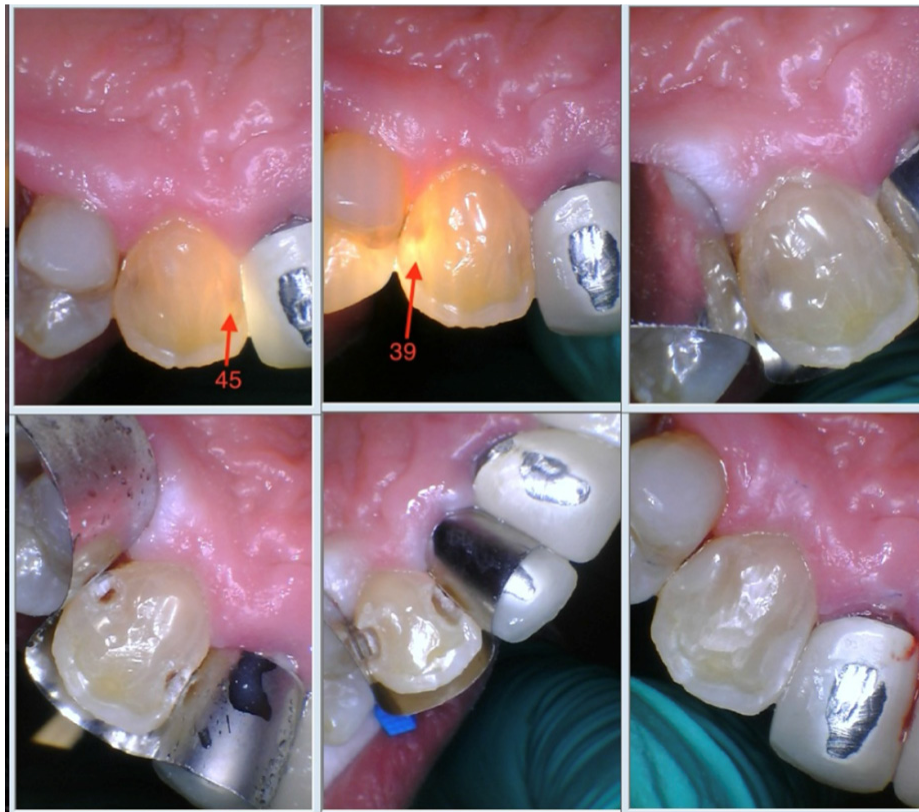

Figure 10. Class III Composite.
Diagnodent and transillumination reveal interproximal caries on tooth 11. No radiographs are needed. Preparations were done without local anesthesia using an Er:YAG laser.

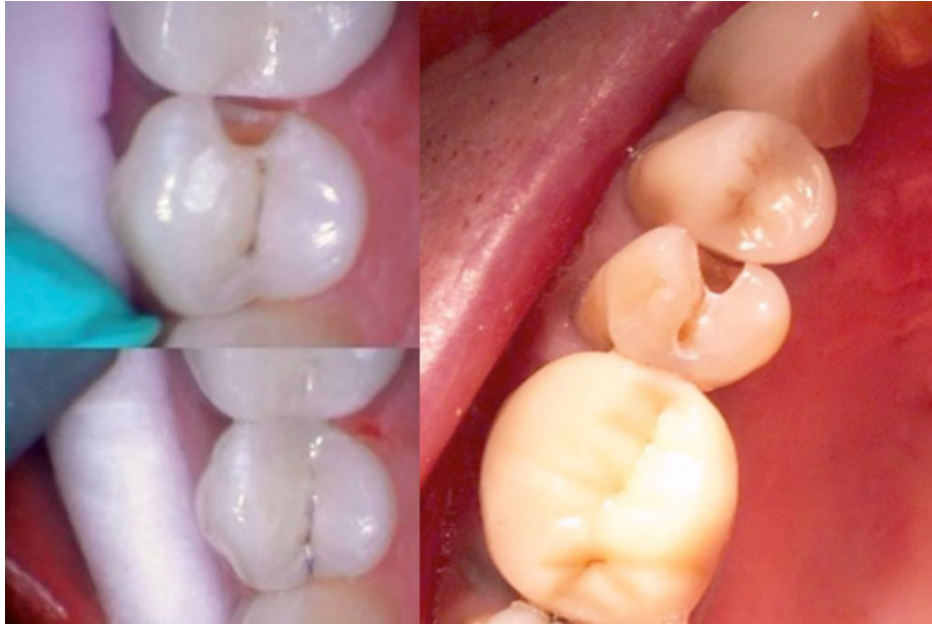

Figure 11. Class III Composite.
 Class II preparations with non-traditional outlines. Lasers allow for minimally invasive approach to all classes of restorations. Er:YAG laser was local anesthesia used these cases.

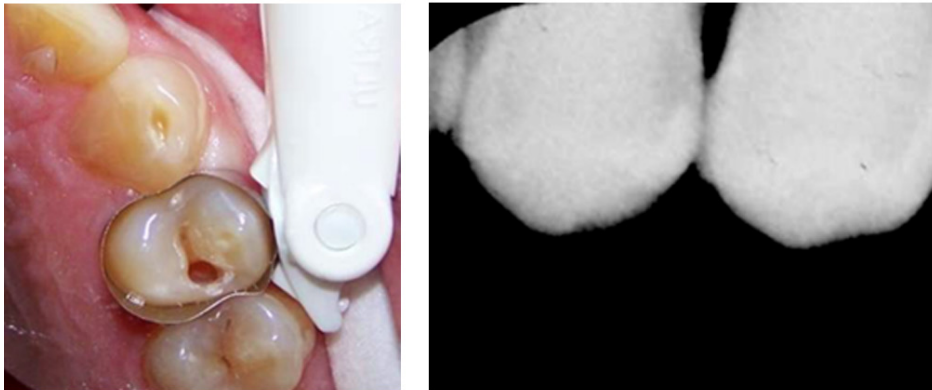

Figure 12. Class II Composite - Tunnel prep.
 Tunnel preparation with Er:YAG laser without local anesthesia. This tooth was restored with a sandwich technique with a glass ionomer base and composite occlusally.

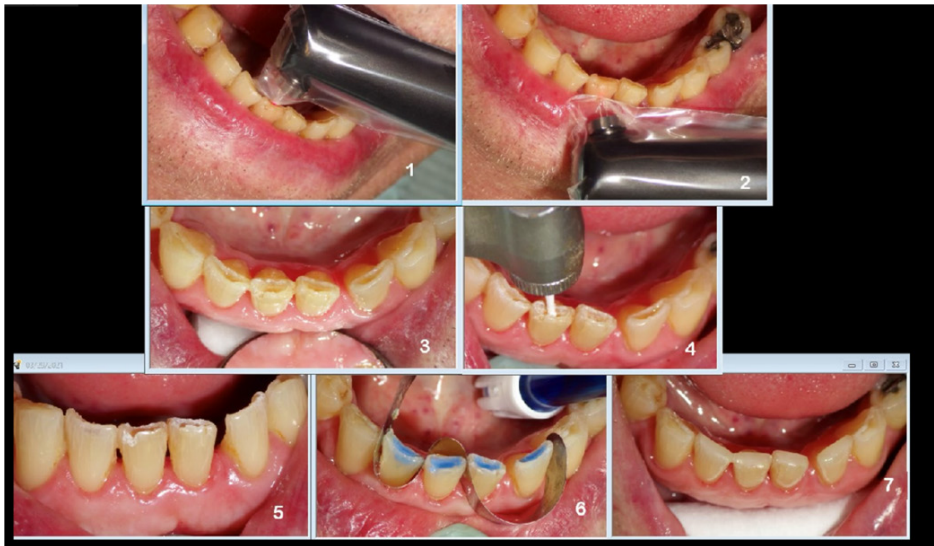

Figure 13. Incisal Composites.

Diagnodent indicate incisal dentin caries in medication induced xerostomic patient. Incisal dentin caries is a common problem in medicated patients with anterior attrition or parafunctional wear. Class VI preparations done anesthesia free with Er:YAG laser.

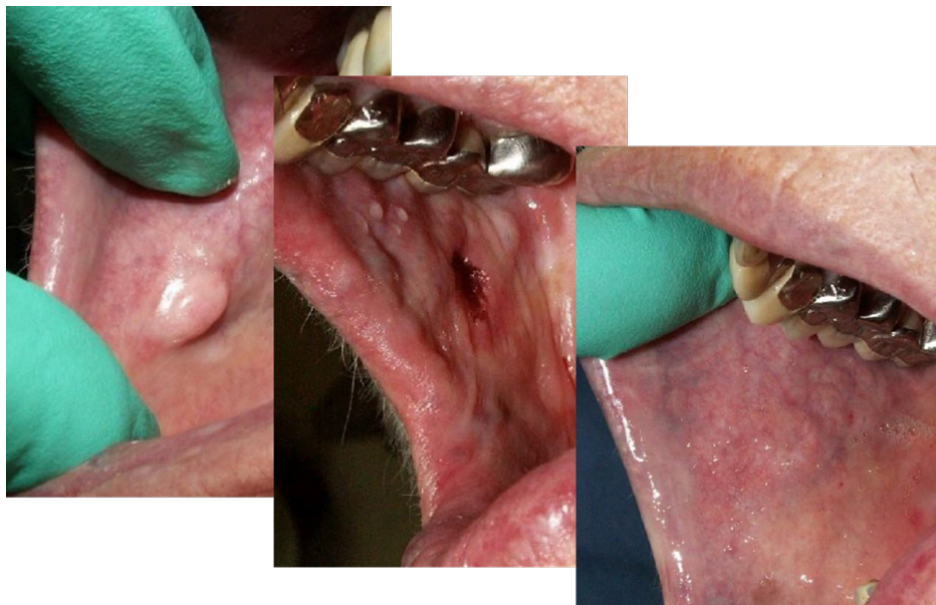


Figure 14. Oral Diagnosis - Fibroma removal.

Er:YAG laser excisional biopsy of a fibroma on the buccal mucosa. A compounded topical anesthetic was used. No sutures were placed and the patient had a comfortable postoperative course. The picture on the right is at six months follow-up exhibits healing with no scarring.

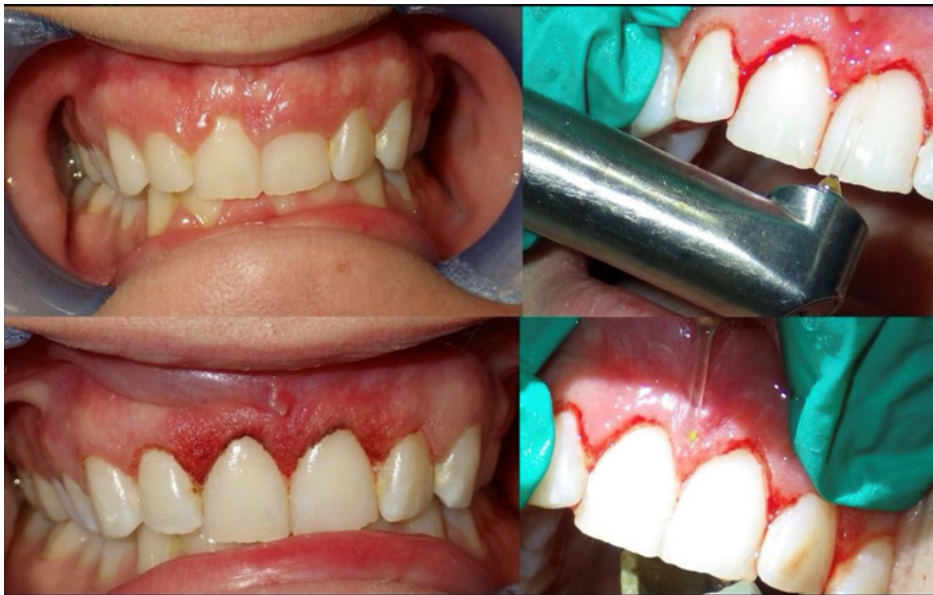

Figure 15. Gingivectomy. Excess gingiva is removed with an Er:YAG Laser. The non-thermal and precise capabilities allow for controlled sculpting of the tissue and result in minimal post-operative discomfort.

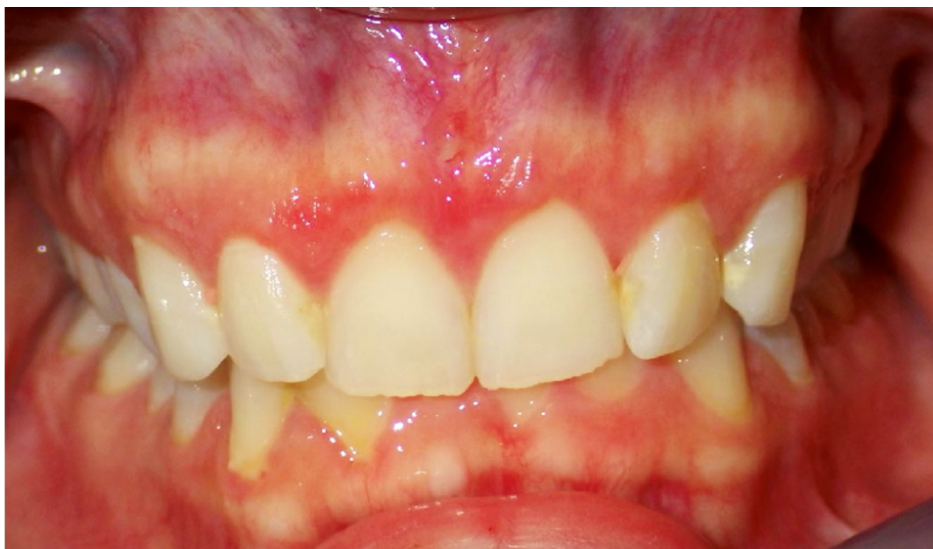

Figure 16. Gingivectomy. One week later the gingiva is completely healed.

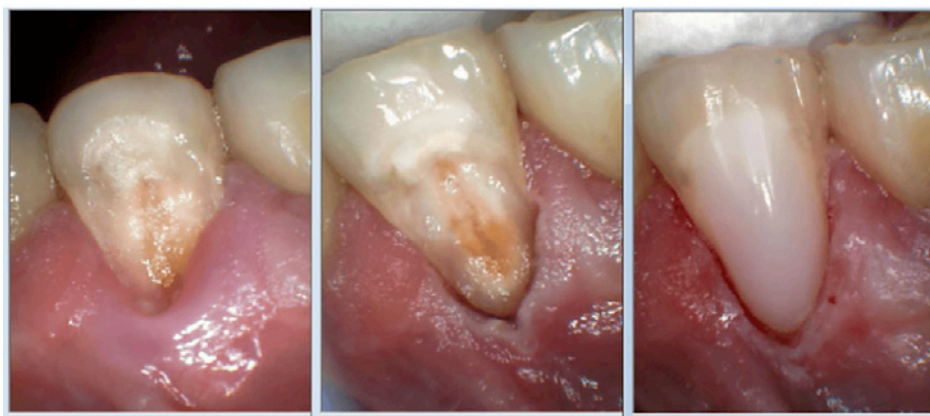


Figure 17. Crowns/Gingivectomy - Cementation.
 Gingivectomy and ClassV Restoration - An elderly patient lost a classV restoration while hospitalized. The gingiva grew into the defect significantly. The patient was on Plavix and aspirin. Er:YAG gingivectomy allowed for precise control of the gingival margin and placement of a restoration.

Er:YAG and Er,Cr:YSGG lasers are also capable of cutting bone and have FDA clearance for osseous use. Multiple studies have shown erbium irradiated bone shows minimal thermal damage, necrosis, or inflammation.¹² Clinically this relatively atraumatic cutting of bone results in rapid and comfortable healing observed by laser practitioners. Studies have shown bone cutting with Er:YAG laser to be superior to bur cuts. Er:YAG ablated bone shows no smear layer and no necrotic osteocytes adjacent to the cut.²⁶ Another interesting phenomenon is that Erbium lasers have a local photobiomodulation effect accelerating osteogenesis.²⁷ Erbium lasers have been shown to effectively decontaminate implant surface without damaging titanium and are useful in treating peri-implantitis.²²

Periodontal Pocket Therapy

All four major dental laser wavelengths have been used for the treatment of periodontal disease. Diodes, Er:YAG, Nd:YAG, and CO₂ devices from various manufacturers have received FDA clearance for sulcular debridement, defined as removal of diseased or inflamed soft tissue in the periodontal pocket to improve clinical indices including gingival index, gingival bleeding index, probe depth, attachment level and tooth mobility. In 2004 Millennium Dental received FDA clearance for the Nd:YAG LANAP® Procedure (Laser Assisted New Attachment Procedure –

cementum-mediated new periodontal ligament attachment to the root surface in the absence of long junctional epithelium). Nd:YAG and erbium lasers have been the most studied and utilized wavelengths in periodontal therapy. Nd:YAG lasers are useful in periodontal care because of their affinity for pigment allows for selective debridement of diseased sulcular epithelium. The Nd:YAG wavelength is also bactericidal, biostimulative, and has the ability to stimulate fibrin formation with the proper parameters. Erbium lasers have been shown to be effective at scaling and root planning, effective pocket decontamination, and can replace scalpels when incisions are needed. One notable advantage to laser techniques is a predictably more comfortable post-operative experience for patients.

Laser Biopsy

All dental laser wavelengths can perform precise biopsies safely.²⁸ Smaller lesions can often be removed with a compounded topical anesthetic only. Sutures are rarely needed due to the excellent hemostasis and minimal trauma observed when lasers are used properly. Any lesion removed needs to be submitted to an oral pathologist for microscopic diagnosis. The dentist should also note what type of laser was used as there is often a tissue effect visible along the incision known as a “laser artifact.” The artifact varies depending on the thermal effects of the particular laser and settings used.

Gingivectomy

Gingivectomy is the most common procedure performed with dental lasers. All laser wavelengths can be used to precisely incise gingiva for restorative, cosmetic, and periodontal indications. Rapid healing and reduced pain are commonly seen post operatively and patients rarely need periodontal packing or sutures. The thermal effects of diodes, Nd:YAG and CO₂ lasers must be understood to avoid collateral damage, but in properly trained hands these devices are quite effective. Erbium edlasers pulsed technology, shallow penetration, and water absorption produce a minimal thermal effect and minor procedures can sometimes be

achieved with no anesthetic at all. The nearly “cold cutting” effect of erbium tissue interaction creates a remarkable post-operative course.

Frenectomy

Frenectomies are a very common laser procedure that can be accomplished effectively with any wavelength. Simple ones can often be achieved with topical anesthesia only. Hemostasis is usually excellent, particularly with the more thermal CO₂, Nd:YAG, and diodes.

Flapless Crown Lengthening Crown Lengthening with Minimally Invasive Flap Design

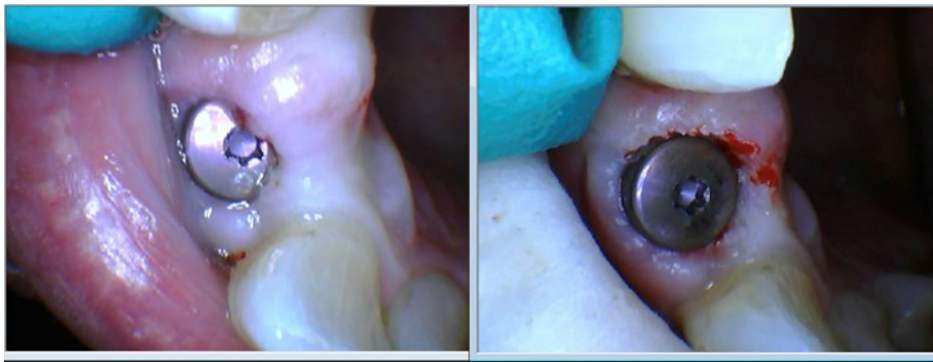
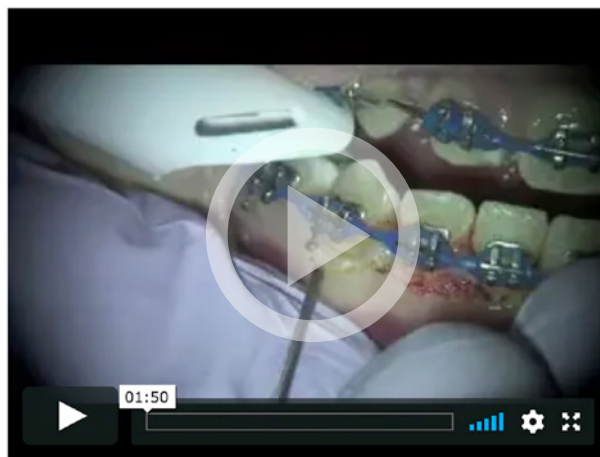
Figure 18. Implant/Gingivectomy. Fibrous gingiva growing over implant healing cap excised with Er:YAG laser at abutment placement appointment. No anesthesia was required. Erbium lasers do not interact with titanium and can be safely used around titanium implants.



Video 2. Gingivectomy with a diode laser (1064 nm XLASE).

Procedure done by Dr. Larry Kotlow, video courtesy of Technology4Medicine, LLC.

[Click on image to view video online.](#)

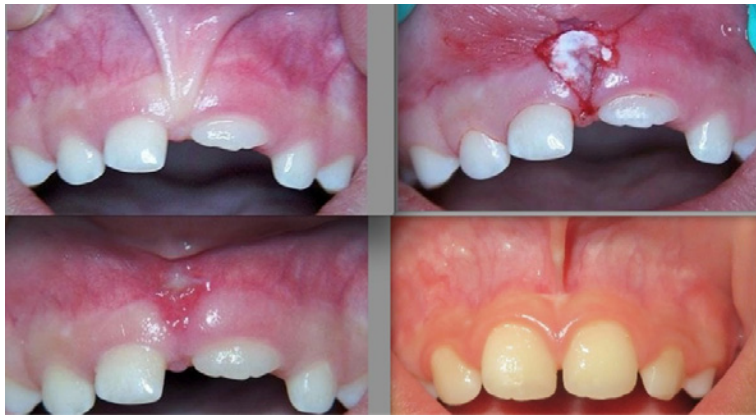

Figure 19. Frenectomy. Maxillary labial frenum is resected to aid in proper eruption of teeth 8 and 9. The lack of any scarring allows for the procedure to be done prior to orthodontics. In this case orthodontics was not needed at all.

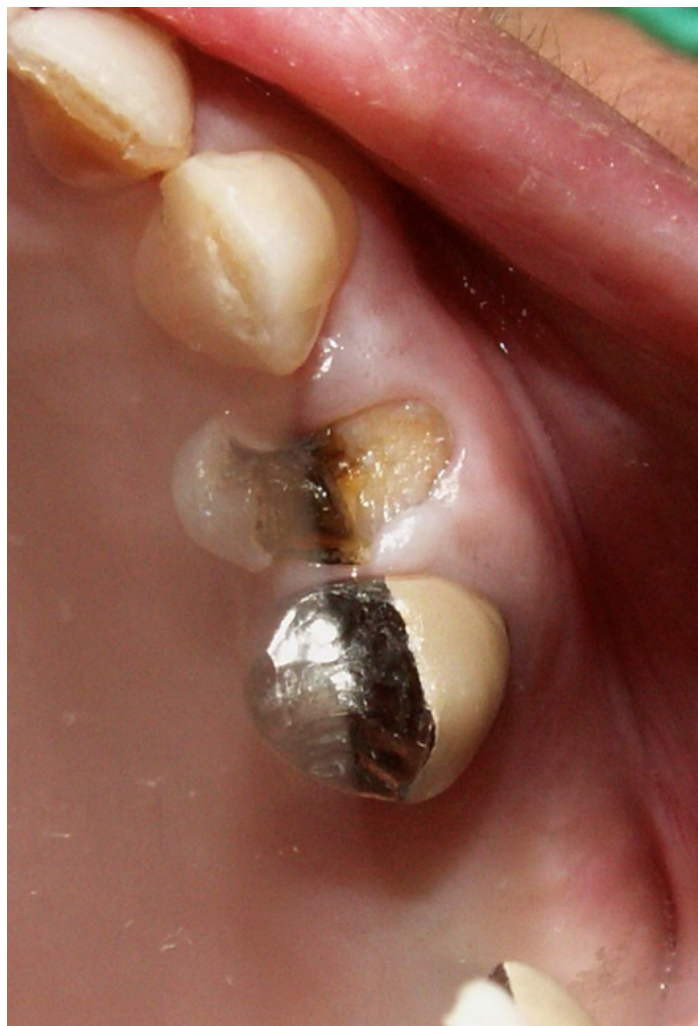

Figure 20. Crown Prep/Crown Lengthening. Fractured buccal cusp on 70-year-old female requires osseous crown lengthening due to biologic width impingement on mesial and buccal.

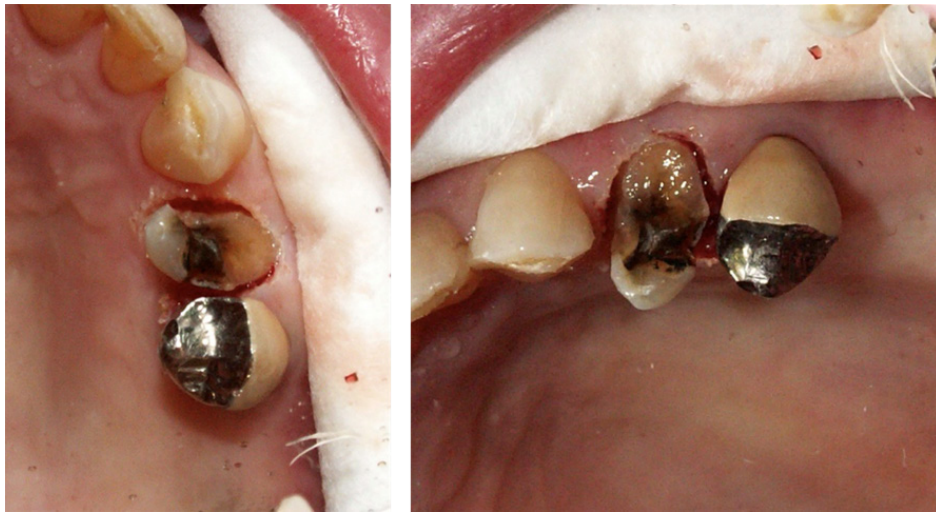

Figure 21. Crown Prep/Crown Lengthening. The hard tissue crown lengthening can be done with a minimal flap approach if two millimeters or less of bone needs to be removed. Enough bone has been removed with the Er:YAG laser to assure adequate distance from the final crown margin and osseous crest for biological width requirements.

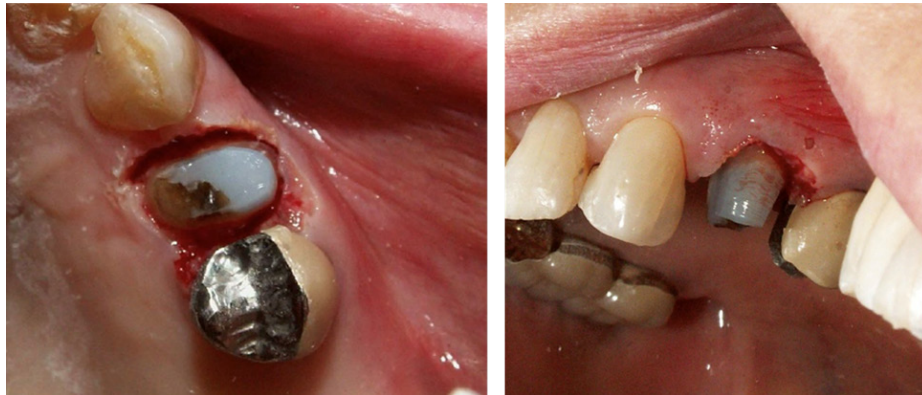


Figure 22. Crown Prep/Crown Lengthening. The tooth is built up with a high contrast composite material and prepared for the crown on the same appointment as the crown lengthening.

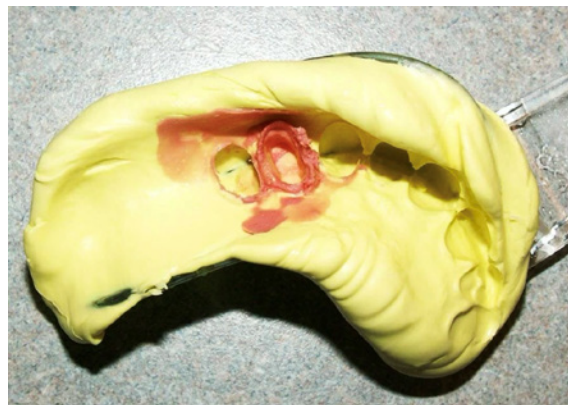

Figure 23. Crown Prep/Crown Lengthening. A final impression is taken that day as well.

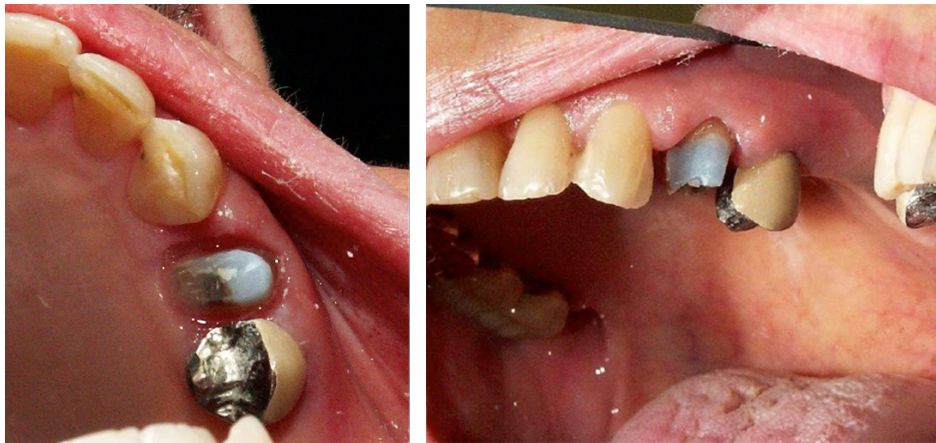

Figure 24. Crown Prep/Crown Lengthening - Two Weeks Later. The sulcular and attached gingiva are healing well at the crown delivery appointment two weeks after osseous crown lengthening. The patient reported no significant pain post-operatively.

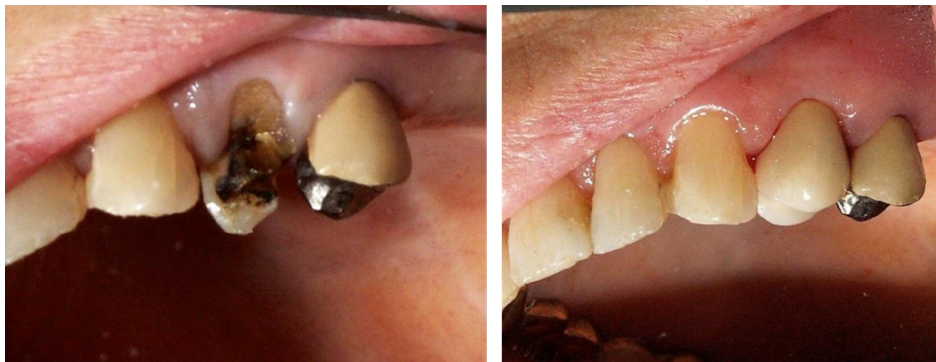

Figure 25. Crown Prep/Crown Lengthening. The crown is delivered two weeks after the osseous crown lengthening.

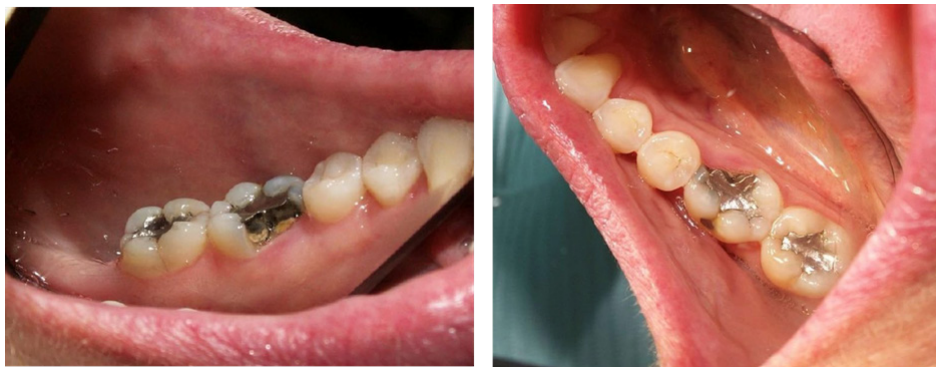

Figure 26. Build-up/Crown lengthening. Mesiolingual cusp fracture requires osseous crown lengthening. The fracture was subgingival to the level of the bone. A flap is required due to significant amount of bone needed to be removed and the width of the bone in this region.

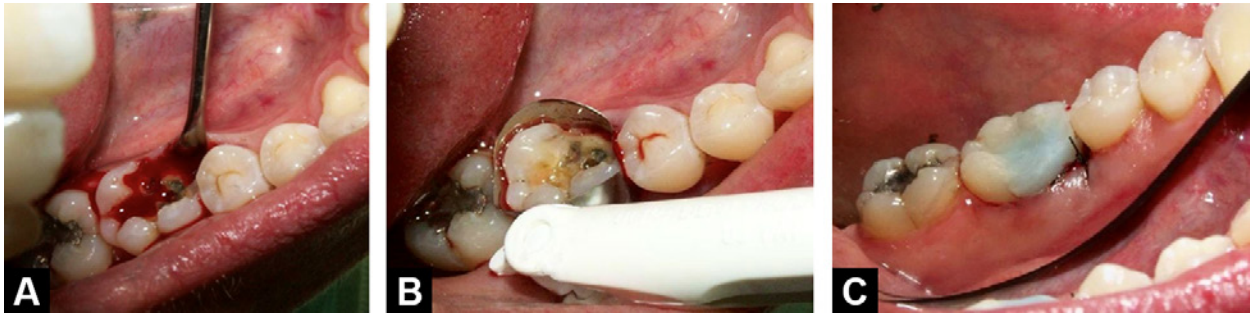

Figure 27. Build-up/Crown lengthening.
 (A) A conservative flap is laid using the Er:YAG laser in place of a scalpel. The bone is removed to the proper height and contoured. (B) A band is placed and high contrast composite buildup bonded in place. (C) A single nylon suture secures the minimally invasive flap. The final crown preparation can be done in two to four weeks.

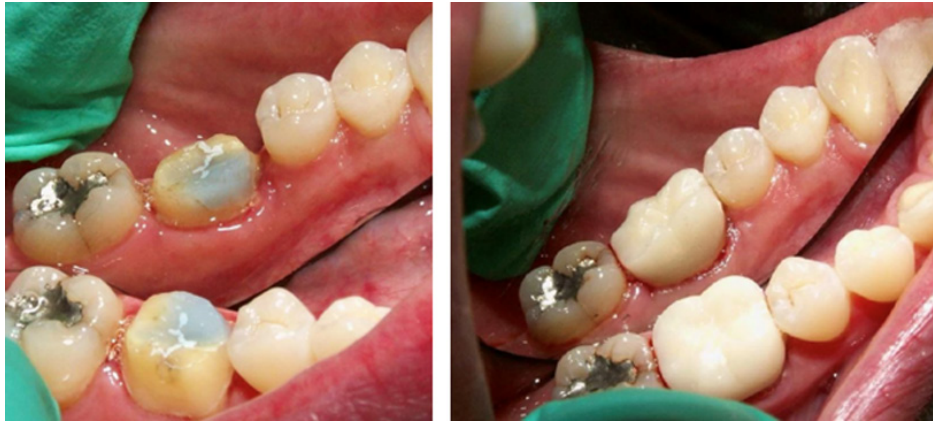

Figure 28. Build-up/Crown lengthening.
 The permanent crown is delivered four weeks after the crown lengthening procedure. The margin is three millimeters from the osseous crest and adequate ferule established.

Oral Surgery

CO₂ lasers have been popular in oral surgery due to their precise incisions and excellent hemostasis. Erbium lasers are capable of cutting bone in a less traumatic fashion and can be quite useful for the following procedures:

- Surgical Extractions with less traumatic flaps and bone removal
- Alveoplasty
- Incision and Drainage
- Operculectomies
- Treatment of peri-implantitis
- Pre-Prosthetic
 - Ridge preparation/hyperplastic tissue reduction
 - Frenectomies
 - Tuberosity reductions
 - Vestibuloplasty
 - Tori Removal

Nd:YAG and diodes have biostimulative properties that can be used to promote healing, osteogenesis, and post-operative comfort. They also have been shown to have potent inhibitory effects on bacteria and fungi.²⁹ Nd:YAG lasers can also form fibrin rapidly in an extraction site creating a quick and more durable clot. An interesting application of dental lasers is in the treatment of medication-related osteonecrosis of the jaw (MRONJ). MRONJ occurs because the drugs inhibit osteoclastic activity which is needed whenever bone is surgically manipulated. When the necrotic bone is removed with an Er:YAG laser the remaining bone is so minimally traumatized that osteoclastic needs are minimized. Nd:YAG biostimulation can be used concurrently or separately to promote bone healing as well. Recent studies have shown superior results when compared to traditional surgical approaches when lasers are used.^{11,14,15,17}

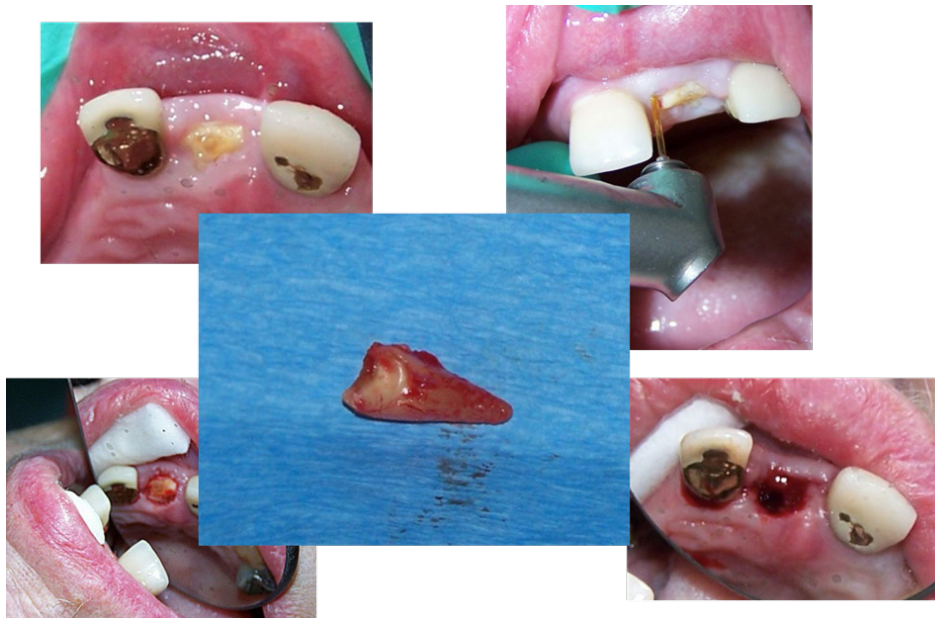

Figure 29. Oral Surgery. A 79-year-old female fractured off a crown on tooth number 9 in a car accident. The Er:YAG is used in a flapless approach to resect bone and make space in the periodontal ligament for judicious elevation. No sutures were needed.

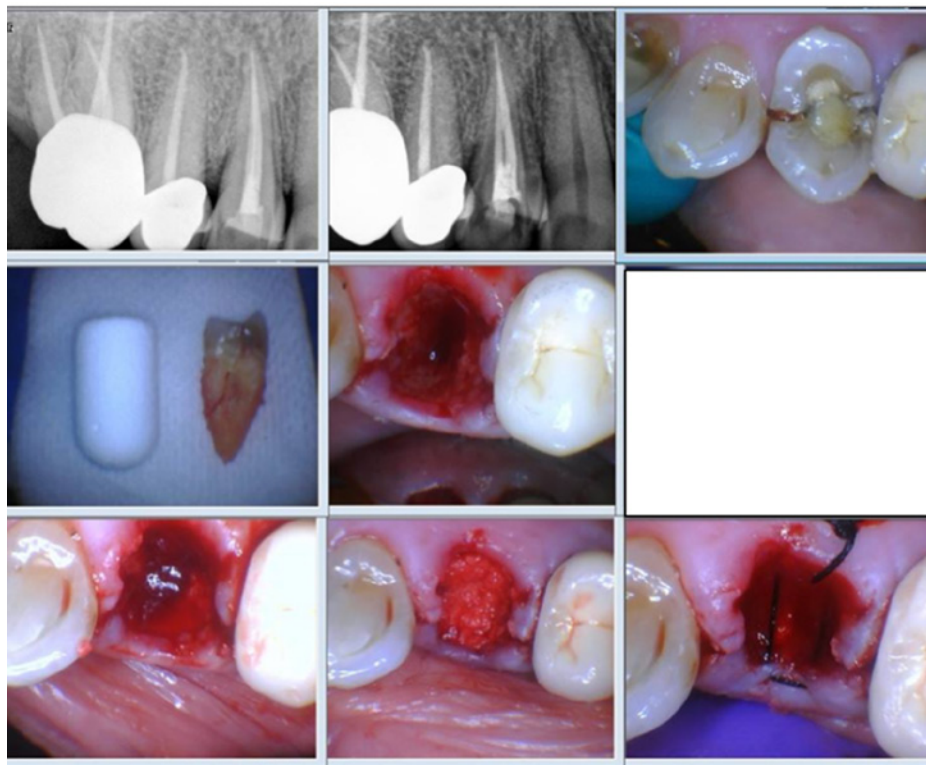


Figure 30. Er:YAG and Nd:YAG. Er:YAG and Nd:YAG Assisted Extraction of Vertical Root Fractured Premolar- The Er:YAG allows for conservative removal of alveolar bone resulting in a minimally invasive extraction via elevation. The extraction site blood is coagulated with th Nd:YAG laser prior to placement of bone graft material.

Lasers in Pediatric Dentistry

Dental lasers offer many advantages when treating children.¹⁶ All procedures previously discussed apply to pediatric treatments as well. The ability to provide care with less use of needles and high-speed handpieces makes for a less traumatic experience. Behavioral management improves when these frightening

devices are not used. Subsequent treatment appointments are often easier to manage as well when the child has a more positive experience. All previously discussed restorative and surgical procedures can be performed safely on children. Dental lasers can also aid in procedures such as pulpotomies and orthodontic surgical needs.

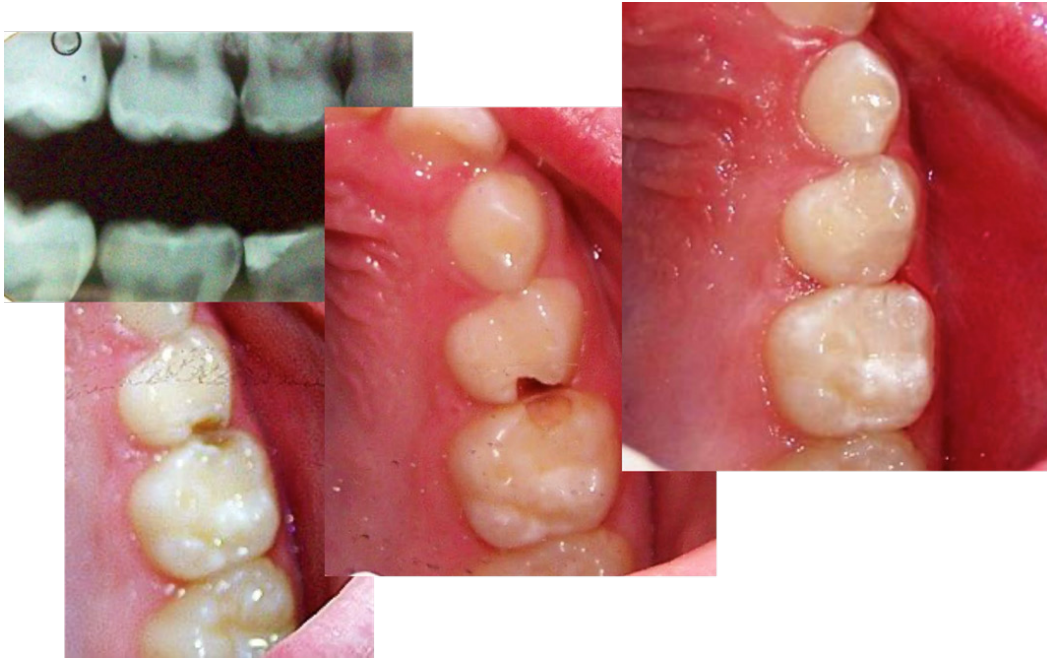


Figure 31. Restorative.
Class II caries in teeth A and B in a 7-year-old male.

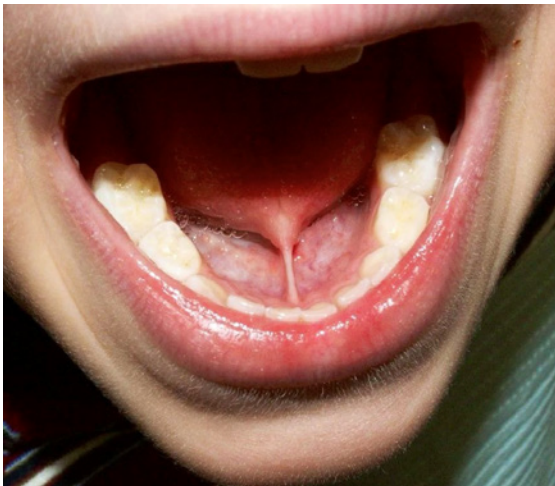

Figure 32. Frenectomy.
Four-year-old male with significant ankyloglossia and having some speech problems.

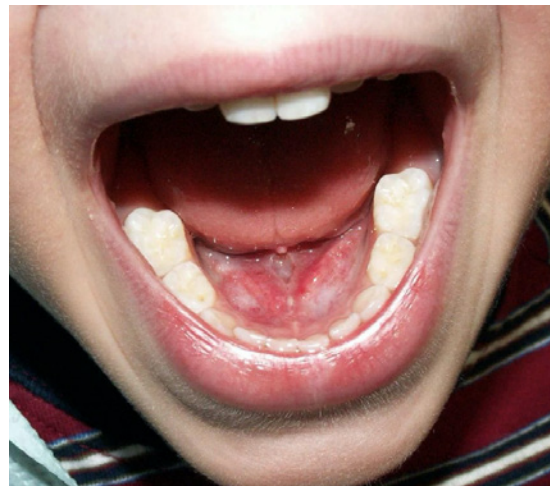

Figure 33. Frenectomy.
Immediate postoperative appearance. Topical anesthesia was used and immediate release of the frenum was achieved.

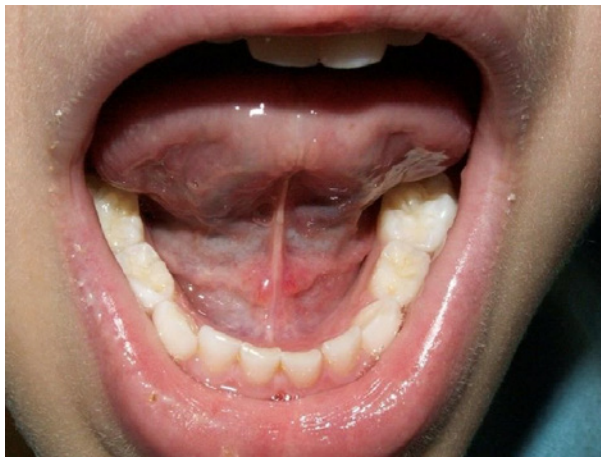
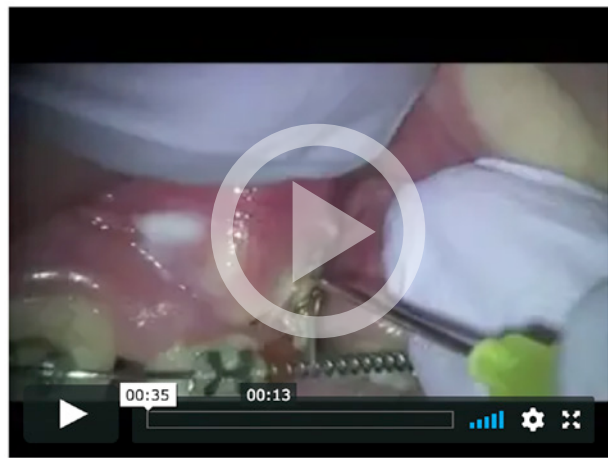
Figure 34. Frenectomy – Six months post-op. Six months follow up and no relapse of the ankyloglossia is present. His speech problem resolved quickly with speech therapy after the surgery.



Video 3. Topical anesthetic is applied and a canine is exposed with a diode laser (1064 nm XLASE).

Procedure done by Dr. Larry Kotlow, video courtesy of Technology4Medicine, LLC.

[Click on image to view video online.](#)

Endodontic Applications

Nd:YAG, Erbium Lasers and diodes have been studied extensively as an adjunct to endodontic treatment. Many of these studies have shown improved smear layer removal and disinfection in the apical third of the tooth. There is the concern of negative thermal effects within the confined space of the root canal.

A phenomenon known as Laser Assisted Irrigation (LAI) has been discovered. The extremely high peak power and affinity for water of the Er:YAG laser creates an interesting phenomenon when tips are placed in irrigant solutions. When tips are submerged in solution each pulse sends a powerful wave of acoustic energy throughout the solution. The laser is used at a setting that creates very little thermal effect. The resultant shock wave propagates throughout the complete three-dimensional root canal system, even the tiniest accessory canals. Scanning electron microscope and microbiological studies have shown extremely thorough cleansing and disinfection of the total root canal complex.^{18,19} The Laser Assisted Irrigation technique allows the dentist to instrument less aggressively and still achieves a thoroughly clean root canal system. It also goes by the acronyms PIPS (Photon Induce Photoacoustic Streaming).

A modified LAI technique called SWEEPS (Shock Wave Enhanced Emission Photoacoustic Streaming) has been recently developed. This technique uses a second variably timed pulse to enhance the shockwave of PIPS by about 30 percent.

Photobiomodulation

All four laser types discussed here have photobiomodulation properties in addition to their surgical capabilities. The terms Low Level Laser Therapy (LLLT) or biostimulation are often used to describe this phenomenon.

In dentistry photobiomodulation can be used for many things including:

- Treatment of recurrent aphthous stomatitis and traumatic ulcers.
- Reduction of oral edema.
- Post-operative analgesia following periodontic, oral surgery, and endodontic procedures.
- Treatment of recurrent intraoral and labial herpes.
- Management of inflammatory conditions such as erosive lichen planus.
- Reduce pain of orthodontics.
- Management of temporomandibular disorder.

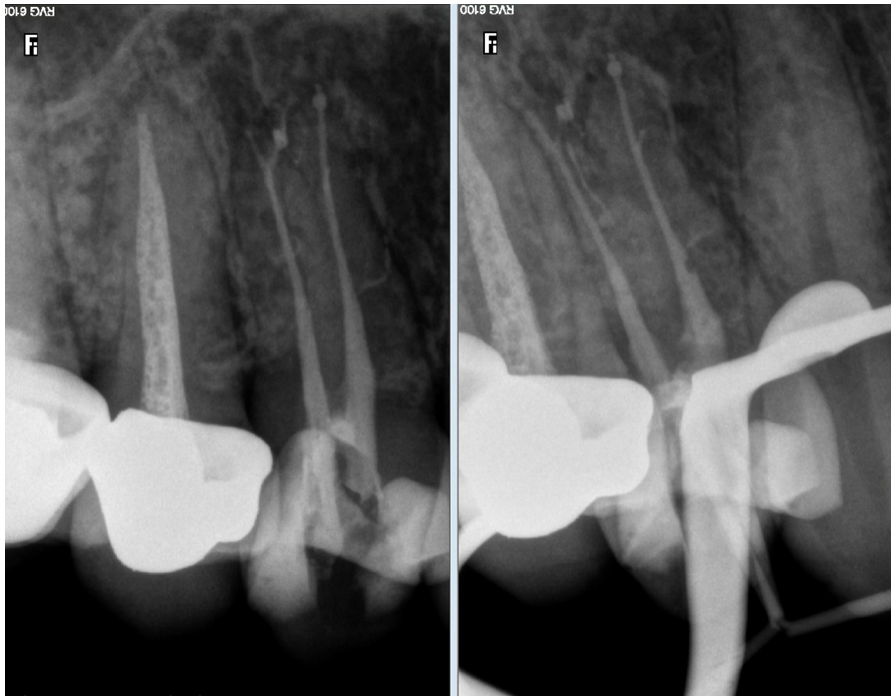


Figure 35. Endodontics.

Tooth 5 instrumented to a size 25 hand file and treated with Laser Assisted Irrigation (PIPS -Photon Induced Photoacoustic Streaming) using sodium hypochlorite, sterile water and EDTA. EndoRez cement (Ultradent Products) was used with a single gutta percha cone per canal. There are multiple lateral canals filled with cement both mid root and apically.

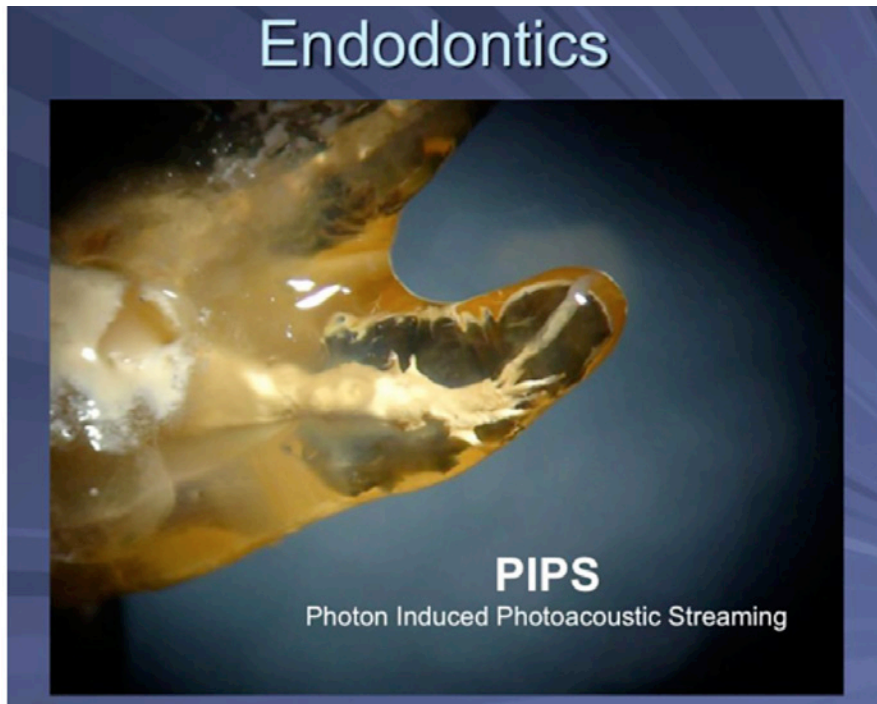


Figure 36. Photon Induced Photoacoustic Streaming (PIPS).

This molar was treated with PIPS only with no mechanical instrumentation and then sealed with EndoRez to demonstrate the effectiveness of the procedure. Multiple lateral canals were cleaned and sealed effectively.

Photo courtesy of Dr. Enrico DiVito.

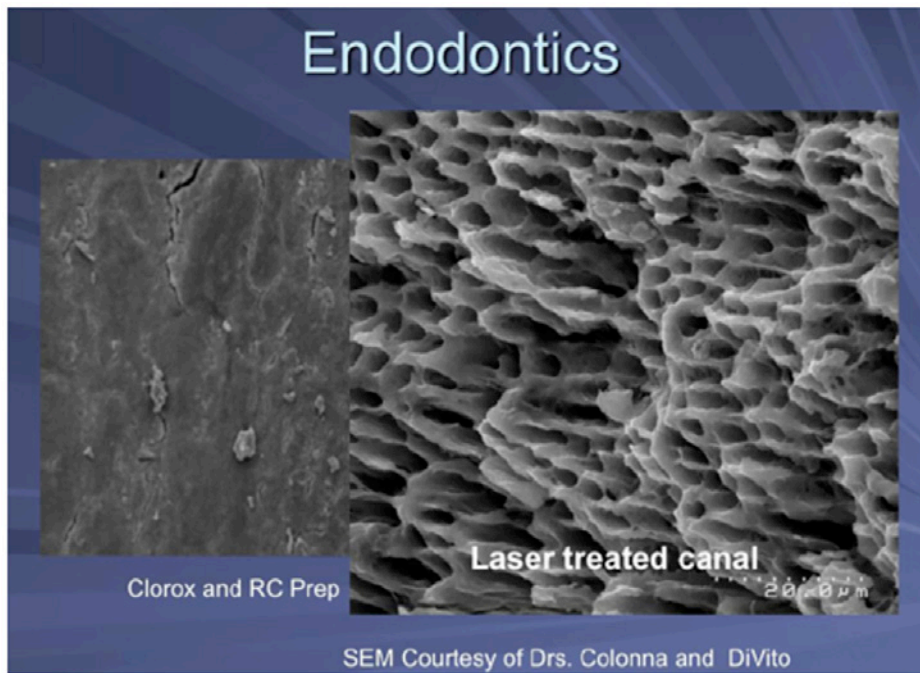


Figure 37. Laser treated canal.
 Normal instrumentation and irrigation leaves significant smear layer on the left.
 The Laser Assisted Irrigation treated dentin on the right is free of smear layer.
 Photo courtesy of Dr. Enrico DiVito.

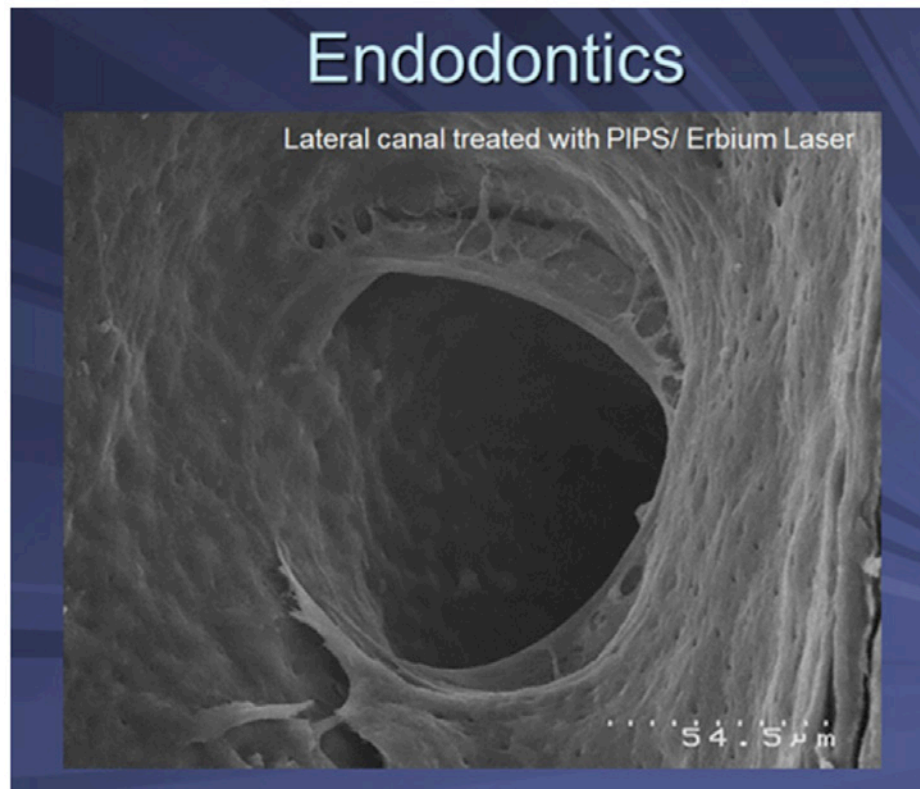


Figure 38. Treated Lateral Canal.
 A lateral canal in a laser treated tooth is free of debris.
 Photo courtesy of Dr. Enrico DiVito.

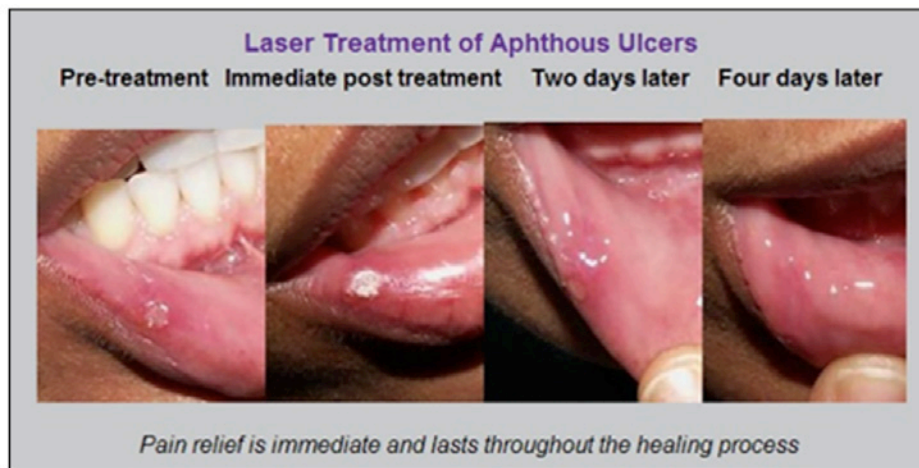

Figure 39. Laser treatment of Aphthous Ulcers. Recurrent aphthous stomatitis treated with combination therapy of Nd:YAG and Er:YAG biostimulation. The patient feels immediate pain relief and the lesion usually remains comfortable. This particular patient's aphthous ulcers usually last ten to fourteen days yet with laser treatment the ulcer heals in a matter of days.

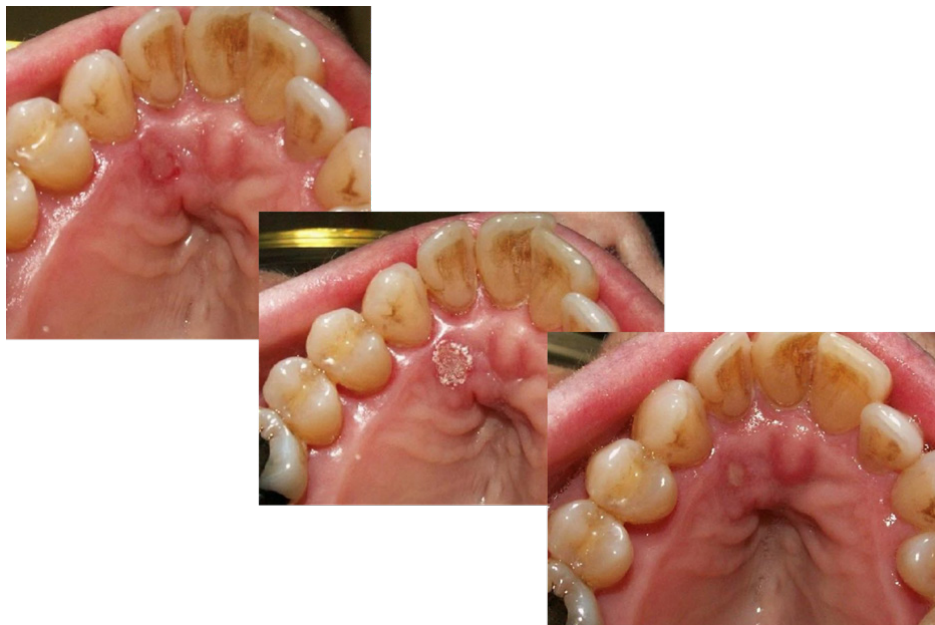

Figure 40. Oral Diagnosis - Herpes Treatment. This patient suffered from recurrent palatal herpes type I outbreaks two or three times a year. The lesion had just started when treated with dual wavelength photobiomodulation therapy with an Nd:YAG and Er:YAG laser. Her relief was immediate and at two day follow up the lesion had already re-epithelialized fifty percent.

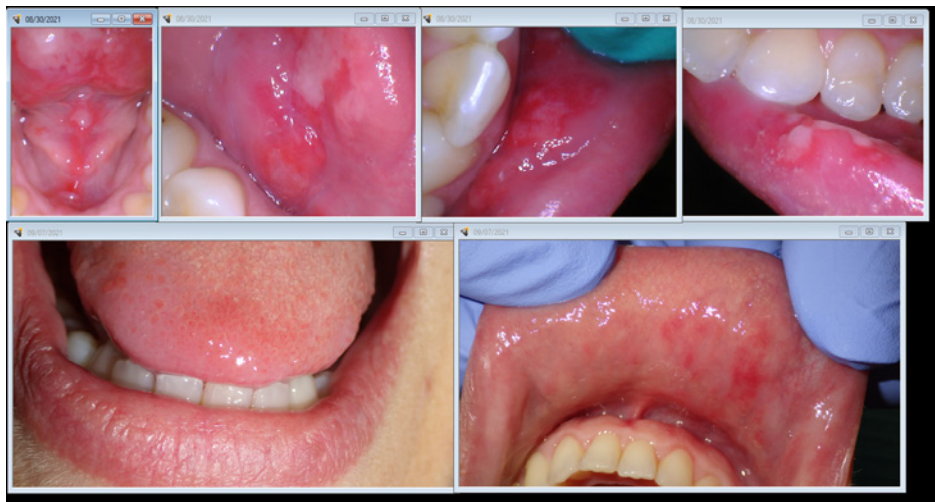
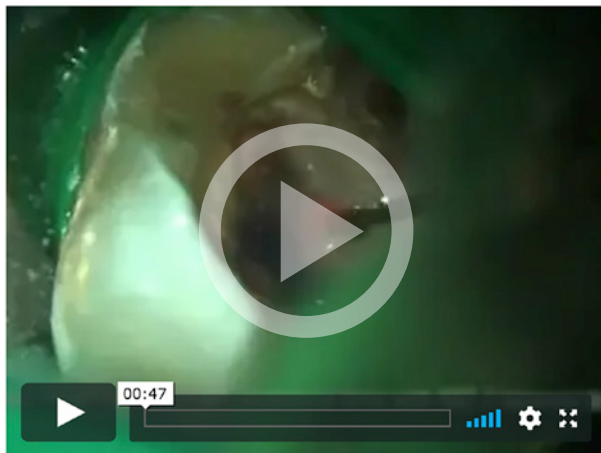
Figure 41. 33 year-old patient presented with a complaint of chronic mouth ulcers for a year. She had undergone thorough medical and rheumatology evaluations prior to her visit with no underlying medical conditions identified. The bottom images are after three Nd:YAG photobiomodulation treatments combined with a Medrol Dose-Pak. A biopsy indicate non-specific ulceration which is consistent with a clinical diagnosis of Major Aphthous Stomatitis.



Video 4. PIPS is being performed on the mesiobuccal 1 canal and debris can be seen rising up from the mesiobuccal 2 canal on this upper molar. When the resin cement is injected into the mesiobuccal one canal it can be seen coming up the mesiobuccal 2 canal via anastomoses that have been thoroughly cleaned by PIPS. This phenomenon is commonly observed in various teeth by PIPS practicing dentists. (Er:YAG laser with special PIPS tip).

Source: Dr. Mark Colonna.

[Click on image to view video online.](#)

Conclusion

Dental lasers are now well-established instruments. Ongoing research is showing the many benefits of laser therapy. The ability to perform less invasive procedures with greater patient comfort makes laser dentistry something the modern practitioner should consider. A thorough understanding of laser physics and biological effects is mandatory for any provider. Comprehensive beginner and ongoing training is imperative to use these devices effectively and safely.

Course Test Preview

To receive Continuing Education credit for this course, you must complete the online test. Please go to: www.dentalcare.com/en-us/ce-courses/ce394/start-test

1. **The first laser ever built in 1960 was _____.**
 - A. CO₂
 - B. erbium
 - C. Nd:YAG
 - D. ruby

2. **The first laser marketed to dentistry was _____.**
 - A. Er:YAG in 1995
 - B. Nd:YAG in 1990
 - C. Nd:YAG in 1987
 - D. A diode in 1991

3. **Laser is an acronym for _____.**
 - A. light amplitude by simple emission of radiation
 - B. level amplified stimulated emission of radiation
 - C. light amplification by stimulated emission of radiation
 - D. lowered amplification of static emitted radiation

4. **Dental laser beams are _____.**
 - A. monochromatic, non-coherent, and multidirectional
 - B. ionizing, monochromatic, and unidirectional
 - C. monochromatic, coherent, and unidirectional
 - D. non-ionizing, monochromatic, and emitted from a passive medium

5. **Optical Pumping is used to achieve which step in laser creation?**
 - A. Amplification
 - B. Emission
 - C. Radiation
 - D. Stimulation

6. **Laser power is _____.**
 - A. the rate of energy used and is measured in watts
 - B. the amount of energy produced and is measured in millijoules
 - C. the product of pulses per second and wattage
 - D. greatest in diode lasers

7. **The emission mode that has true pulsed bursts of laser energy is _____.**
 - A. continuous
 - B. free running pulsed
 - C. gated wave
 - D. intermittent

8. **A laser running in continuous mode's peak power is _____.**
 - A. higher than its average power
 - B. lower than its average power
 - C. the same as its average power
 - D. why it is so useful for cutting enamel and dentin

9. **Thermal relaxation refers to _____.**
A. the ability of biostimulation with lasers to relax skeletal muscle
B. the ability of biostimulation to dilate capillaries and increase blood flow
C. the ability of the active medium crystal to cool itself in free running pulsed mode
D. the tissues ability to absorb and dissipate heat to help minimize thermal damage with pulsed laser usage
10. **The actual physical work done by a laser is mostly a result of which interaction?**
A. Scattering
B. Absorption
C. Transmission
D. Refraction
11. **Which of the following statements are true?**
A. Erbium lasers primary chromophore is water and Nd:YAG lasers primary chromophores are pigments like hemoglobin or melanin.
B. CO2 lasers are primarily absorbed by hemoglobin.
C. Shorter near infrared laser wavelengths of diodes and Nd:YAG exhibit lesser tissue penetration than erbium lasers.
D. Diode lasers primary chromophore is collagen.
12. **Fluorescence of tissue stimulated by laser light is mostly important in _____.**
A. caries diagnosis
B. biostimulation
C. periodontal therapies
D. osseous surgery
13. **The primary biological effect of lasers when performing soft tissue procedures is _____.**
A. photochemical
B. photoacoustic
C. photothermal
D. photodisruptive
14. **When tissue is heated to 60 degrees C, _____.**
A. protein will begin to denature
B. tissue is vaporized
C. tissue will show signs of carbonization
D. None of the above.
15. **Erbium lasers _____.**
A. all have identical wavelengths
B. all exhibit identical water absorption
C. are hard and soft tissue capable
D. run in continuous emission mode
16. **When cutting hard tissue with an erbium laser, _____.**
A. longer pulse durations are preferable
B. minimal thermal effects are observed in adjacent tissue when used properly
C. shorter pulse durations have lower peak power
D. anesthesia is always needed when preparing teeth

17. **Nd:YAG lasers** _____.
- A. are available in multiple wavelengths
 - B. use primarily photoacoustic effects to work
 - C. are 1064 nm wavelength
 - D. exhibit minimal tissue penetration
18. **Fibrin formation with an Nd:YAG laser** _____.
- A. is maximized at a 100 microsecond pulse duration
 - B. can be utilized after an extraction to help form a clot in the socket
 - C. is useful when performing photobiomodulation
 - D. is interesting but has no clinical use
19. **Diode lasers** _____.
- A. are the most expensive of all types of dental lasers
 - B. are available in only a single wavelength
 - C. use a semiconductor stimulated by electricity to produce laser light
 - D. have hard tissue capabilities
20. **Water is the primary chromophore for diode laser wavelengths. Diode lasers run in free running pulsed mode.**
- A. Both statements are true.
 - B. The first statement is true and the second statement is false.
 - C. The first statement is false and the second statement is true.
 - D. Both statements are false.
21. **CO2 Lasers** _____.
- A. are the most recently developed of the dental lasers
 - B. do not use quartz optical fibers as their beam transfer hardware
 - C. have extensive hard tissue capabilities
 - D. are efficient at cutting tissue but exhibit poor hemostasis
22. **When using dental lasers** _____.
- A. safety glasses made specifically for the wavelength must be worn by all patients, staff, and observers
 - B. universal laser safety glasses can be used
 - C. only the patient needs to wear eye protection
 - D. no eye protection is needed when using an Nd:YAG laser
23. **The laser plume** _____.
- A. does not contain hazardous chemicals and infectious agents
 - B. necessitates the need for high speed evacuation
 - C. occurs only with diode lasers
 - D. can be controlled with a saliva ejector
24. **The Diagnodent diagnostic laser** _____.
- A. can only be used to diagnose class I caries
 - B. is 655 nm visible light
 - C. indicates all positive readings need to be restored
 - D. is not used on pediatric patients

25. When performing operative dentistry with erbium lasers enamel is removed via _____.
- A. vaporization
 - B. carbonization
 - C. photoacoustic ablation
 - D. very long pulse durations
26. Experienced erbium laser users usually _____.
- A. do not need local anesthesia for the majority of restorations
 - B. routinely remove amalgam with their lasers
 - C. only use their laser for class I and V lesions
 - D. anesthetize approximately half of the time
27. When considering soft tissue uses of lasers, _____.
- A. only diodes, Nd:YAG, and CO2 lasers can be used
 - B. the practitioner does not need to understand the differing thermal and biological effects of differing wavelengths as all soft tissue lasers behave similarly
 - C. thermal relaxation does not matter as it only occurs when cutting hard tissue
 - D. Er:YAG has the least thermal effect.
28. For cutting bone, _____.
- A. any wavelength can be used, though they differ in their effectiveness
 - B. Er:YAG and Er,Cr:YSGG lasers have FDA clearance
 - C. erbium lasers cause much more damage to bone than surgical burs
 - D. narcotic analgesics are usually need post operatively when lasers are used
29. When submitting a laser resected biopsy, _____.
- A. no special instructions are needed
 - B. only lesions suspected of being dysplastic or malignant need to be examined microscopically
 - C. the dentist should indicate on the lab form that a laser was used and what type of laser
 - D. all lasers leave identical artifacts on the specimen
30. P.I.P.S. stands for _____.
- A. Photon Induced Plasma Streaming
 - B. Photon Induced Photoacoustic Streaming
 - C. Plasma Inverted Photonic Stimulation
 - D. Photon Inversion by Plasma Stimulation

References

1. Convissar R. Principles and Practice of Laser Dentistry. Mosby, Inc., St. Louis, 2001.
2. Manni J. Dental Applications of Advanced Lasers. JGM Associates, Inc., Burlington, MA, 2004.
3. Stern RH, Sognnaes RF. Laser Effect on Dental Hard Tissues. A Preliminary Report. J South Calif Dent Assoc. 1965 Jan;33:17-9.
4. Adrian JC, Bernier JL, Sprague WG. Laser and the dental pulp. J Am Dent Assoc. 1971 Jul;83(1):113-7.
5. Lin S, Liu Q, Peng Q, et al. The ablation threshold of Er:YAG laser and Er,Cr:YSGG laser in dental dentin. Scientific Research and Essays Vol. 2010 Aug;5(16):2128-2135. Accessed October 2, 2018.
6. Barbería E, Maroto M, Arenas M, et al. A clinical study of caries diagnosis with a laser fluorescence system. J Am Dent Assoc. 2008 May;139(5):572-9.
7. Karlsson L. Caries Detection Methods Based on Changes in Optical Properties between Healthy and Carious Tissue. Int J Dent. 2010;2010:270729. Epub 2010 Mar 28.
8. Pinelli C, Loffredo Lde C, Serra MC. Effect of drying on the reproducibility of DIAGNOdent to detect caries-like lesions. Braz Dent J. 2010;21(5):405-10.
9. Wilder-Smith P, Dang J, Kurosaki T. Investigating the range of surgical effects on soft tissue produced by a carbon dioxide laser. J Am Dent Assoc. 1997 May;128(5):583-8.
10. Kim IS, Cho TH, Kim K, et al. High power-pulsed Nd:YAG laser as a new stimulus to induce BMP-2 expression in MC3T3-E1 osteoblasts. Lasers Surg Med. 2010 Aug;42(6):510-8.
11. Vescovi P, Merigo E, Meleti M, et al. Nd:YAG laser biostimulation of bisphosphonate-associated necrosis of the jawbone with and without surgical treatment. Br J Oral Maxillofac Surg. 2007 Dec;45(8):628-32. Epub 2007 May 23.
12. Sasaki KM, Aoki A, Ichinose S, et al. Scanning electron microscopy and Fourier transformed infrared spectroscopy analysis of bone removal using Er:YAG and CO₂ lasers. J Periodontol. 2002 Jun;73(6):643-52.
13. Jenson L, Budenz AW, Featherstone JD, et al. Clinical protocols for caries management by risk assessment. J Calif Dent Assoc. 2007 Oct;35(10):714-23.
14. Stübinger S, Dissmann JP, Pinho NC, et al. A preliminary report about treatment of bisphosphonate related osteonecrosis of the jaw with Er:YAG laser ablation. Lasers Surg Med. 2009 Jan;41(1):26-30.
15. Vescovi P, Manfredi M, Merigo E, et al. Surgical approach with Er:YAG laser on osteonecrosis of the jaws (ONJ) in patients under bisphosphonate therapy (BPT). Lasers Med Sci. 2010 Jan;25(1):101-13. Epub 2009 Jun 19.
16. Kotlow L. Lasers and pediatric dental care. Gen Dent. 2008 Nov-Dec;56(7):618-27.
17. Vescovi P, Merigo E, Manfredi M, et al. Nd:YAG laser biostimulation in the treatment of bisphosphonate-associated osteonecrosis of the jaw: clinical experience in 28 cases. Photomed Laser Surg. 2008 Feb;26(1):37-46.
18. Araki AT, Ibraki Y, Kawakami T, et al. Er:Yag laser irradiation of the microbiological apical biofilm. Braz Dent J. 2006;17(4):296-9.
19. DiVito EE, Colonna MP, Olivi G. The Photoacoustic Efficacy of an Er: YAG Laser with Radial and Stripped Tips on Root Canal Dentin Walls: An SEM Evaluation. J Laser Dent. 2011;(19)1:156-161. Accessed October 2, 2018.
20. Peters OA, Bardsley S, Fong J, et al. Disinfection of root canals with photon-initiated photoacoustic streaming. J Endod. 2011 Jul;37(7):1008-12. Epub 2011 May 7.
21. Vescovi P, Merigo E, Fornaini C, et al. Thermal increase in the oral mucosa and in the jawbone during Nd:YAG laser applications. Ex vivo study. Med Oral Patol Oral Cir Bucal. 2012 Feb 9.
22. Park CY, Kim SG, Kim MD, et al. Surface properties of endosseous dental implants after NdYAG and CO₂ laser treatment at various energies. J Oral Maxillofac Surg. 2005 Oct;63(10):1522-7.
23. Jawad MM, Qader STA, Zaidan AA, et al. An Overview of Laser Principle, Laser-Tissue Interaction Mechanisms and Laser Safety Precautions for Medical Laser Users. Int J Pharmacol. 2011;7(2):149-60. Accessed October 2, 2018.
24. Moritz A, Doertbudak O, Gutknecht N, et al. Nd:YAG laser irradiation of infected root canals in combination with microbiological examinations. J Am Dent Assoc. 1997 Nov;128(11):1525-30.

25. Lavu V, Sundaram S, Sabarish R, et al. Root Surface Bio-modification with Erbium Lasers - A Myth or a Reality? *Open Dent J*. 2015 Jan 30;9:79-86.
26. Lee CY, Prasad HS, Lee KL, et al. Histologic Evaluation of Bone Using the Quantum Square Pulse Er : YAG Laser : A Preliminary Study. Accessed October 2, 2018.
27. Shimohira T, Katagiri S, Ohsugi Y, Hirota T, Hatasa M, Mizutani K, Watanabe K, Niimi H, Iwata T, Aoki A. Comprehensive and Sequential Gene Expression Analysis of Bone Healing Process Following Er:YAG Laser Ablation. *Photobiomodul Photomed Laser Surg*. 2021 Feb;39(2):100-112. doi: 10.1089/photob.2020.4833. Epub 2020 Dec 21. PMID: 33347788.
28. Monteiro L, Delgado ML, Garcês F, Machado M, Ferreira F, Martins M, Salazar F, Pacheco JJ. A histological evaluation of the surgical margins from human oral fibrous-epithelial lesions excised with CO₂ laser, Diode laser, Er:YAG laser, Nd:YAG laser, electrosurgical scalpel and cold scalpel. *Med Oral Patol Oral Cir Bucal*. 2019 Mar 1;24(2):e271-e280. doi: 10.4317/medoral.22819. PMID: 30818322; PMCID: PMC6441595.
29. Grzech-Leśniak K, Nowicka J, Pajączkowska M, Matys J, Szymonowicz M, Kuroпка P, Rybak Z, Dobrzyński M, Dominiak M. Effects of Nd:YAG laser irradiation on the growth of *Candida albicans* and *Streptococcus mutans*: in vitro study. *Lasers Med Sci*. 2019 Feb;34(1):129-137. doi: 10.1007/s10103-018-2622-6. Epub 2018 Aug 25. PMID: 30145724; PMCID: PMC6343019.

Additional Resources

- No Additional Resources Available

About the Author

Steven R. Pohlhaus, DDS



Dr. Pohlhaus has been practicing laser dentistry in his private practice since 2004. He was also on Faculty at the University of Maryland Dental School in the Department of Oncology and Diagnostic Sciences for twenty years. He has lectured and trained for three different laser companies and is currently a trainer for Fotona, LLC.

Email: spohlhaus@yahoo.com