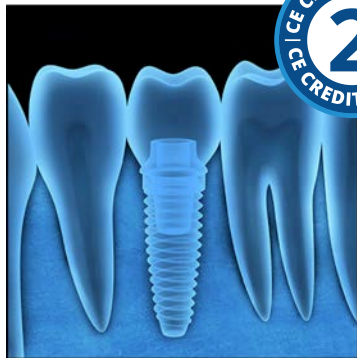


Current Concepts in Dental Implants: Clinical Assessment in the Prevention of Peri-implant Mucositis, Peri-implantitis, and Implant Failure



Course Author(s): Connie M. Kracher, PhD, MSD

CE Credits: 2 hours

Intended Audience: Dentists, Dental Hygienists, Dental Assistants, Dental Students, Dental Hygiene Students, Dental Assistant Students

Date Course Online: 08/01/2017

Last Revision Date: 03/30/2021

Course Expiration Date: 03/29/2024

Cost: Free

Method: Self-instructional

AGD Subject Code(s): 690

Online Course: www.dentalcare.com/en-us/professional-education/ce-courses/ce514

Disclaimers:

- P&G is providing these resource materials to dental professionals. We do not own this content nor are we responsible for any material herein.
- Participants must always be aware of the hazards of using limited knowledge in integrating new techniques or procedures into their practice. Only sound evidence-based dentistry should be used in patient therapy.

Conflict of Interest Disclosure Statement

- Dr. Kracher reports no conflicts of interest associated with this course. She has no relevant financial relationships to disclose.

Introduction – Substance Use Disorders

According to the American Association of Oral and Maxillofacial Surgery (AAOMS) and the American Academy of Implant Dentistry (AAID), 69% of adults 35 to 44 years of age have lost at least one permanent tooth due to dental caries, periodontitis, accidents, or failed endodontic therapy. The AAID states that more than 35 million Americans are partially edentulous or edentulous. By age 74, 26% of adults in the United States are edentulous. In recent years, the demand for dental implants has risen greatly, with a reported success rate at approximately 95-98%.^{1,3}

Course Contents

- Overview
- Learning Objectives
- Introduction
- Current Dental Implant Therapy
- Reasons Why Dental Implants Fail
- Peri-implant Anatomy and Biology
- Biomechanical Assessment
- Clinical Evaluation and Assessment
- Peri-implant Mucositis and Peri-implantitis Risk Factors
 - Patient's Health Status
 - Patient's Genetic Susceptibility and Immunology
- Surgical Placement and Post-treatment Concerns
- Post-treatment Clinical Evaluation and Care
- Patient Self-care Recommendations
 - Manual and Power Toothbrushing
 - Interdental and Antimicrobial Adjuncts
- Conclusion
- Course Test
- References / Additional Resources
- About the Author

Overview

According to the American Association of Oral and Maxillofacial Surgery (AAOMS) and the American Academy of Implant Dentistry (AAID), 69% of adults 35 to 44 years of age have lost at least one permanent tooth due to dental caries, periodontitis, accidents, or failed endodontic therapy. The AAID states that more than 35 million Americans are partially edentulous or edentulous. By age 74, 26% of adults in the United States are edentulous. In recent years, the demand for dental implants has risen greatly, with a reported success rate at approximately 95-98%.^{1,3}

Learning Objectives

Upon completion of this course, the dental professional should be able to:

- Discuss peri-implant anatomy and biology.
- Discuss the biomechanical assessment process with dental implants.
- Discuss the importance of clinical evaluation and assessment with dental implants.
- Identify risk factors relating to dental implants.
- Understand the importance of oral hygiene maintenance as it applies to the success rate for implants.

Introduction

According to the American Association of Oral and Maxillofacial Surgery (AAOMS) and the American Academy of Implant Dentistry (AAID), 69% of adults 35 to 44 years of age have lost at least one permanent tooth due to dental caries, periodontitis, accidents, or failed endodontic therapy. The AAID states that more than 35 million Americans are partially edentulous or edentulous. By age 74, 26% of adults in the United States are edentulous. In recent years, the demand for dental implants has risen greatly. The success rate of dental implants has been reported in the scientific literature to be approximately 95-98%.^{1,3} It is estimated approximately 500,000 dental implants are placed in the United States annually.⁴ Not only have placement techniques improved, but the benefits that implants provide for patients have increased as well. Dental implants improve appearance, confidence, and self-esteem. Dental implants also preserve remaining teeth, improve a person's ability to speak and masticate properly, and eliminate the need for other types of fixed and removable prostheses. Because dental implants present a significant financial investment, both the patient and the dental team's commitment to long-term care are vital to dental implant success.

Current Dental Implant Therapy

Dental implant designs and surgical techniques, healing times, and restorative procedures have continued to improve since Brand introduced titanium implants in the 1950s. Previous implant designs included the blade vents, subperiosteal, and transmandibular implants. Biomechanical issues presented a challenge, especially with multiple posterior implants. With the lack of predictability, these types of dental implants are no longer used. Most of the studies reported <50% success rate after 5 years, with pocket formations exceeding 6 mm and significant alveolar bone loss around the implants.^{2,29}

In the mid-1970s Schroeder contributed to the success of endosseous implants. This type of implant was more predictable. The procedure included preparing a hole in the bone without overheating or traumatizing the tissues. This type of procedure achieved the implant-bone apposition needed for success, as long

as micromovements at the interface of the implant and bone were prevented during early healing. Currently, most endosseous dental implants have a tapered or cylindrical, screw-type design.^{29,43} The components of dental implants include the abutment, screw, and restoration. The threaded implant design has been preferred due to primary stabilization and bone apposition. The use of tapered designs has been utilized for areas with less space between roots and in narrow anatomic regions and extraction sockets.²⁹⁻⁴⁴

Today, the majority of dental implants are made from commercially pure (CP) titanium or titanium alloys. Titanium continues to be used in dentistry because of its reactive metal properties where the implant oxidizes within nanoseconds when exposed to air. This oxide layer then becomes resistant to corrosion in its CP form. Dental implants are treated with a variety of surface characteristics that have been shown to produce a better result in the process of osseointegration⁴⁶ (Figure 1). A recent systematic review in the *Journal of Prosthetic Dentistry* conducted by Oh et al found a significantly higher survival rate for rough-surfaced implants than smooth-surfaced dental implants (90% vs. 68.7%).⁵⁶ Manufacturers use additive materials or chemicals, such as inorganic mineral coatings, biocoating with growth factors, fluoride, plasma spraying, and other particulates containing calcium-phosphates, carbonates, and sulfates.^{45,47} Additive surface

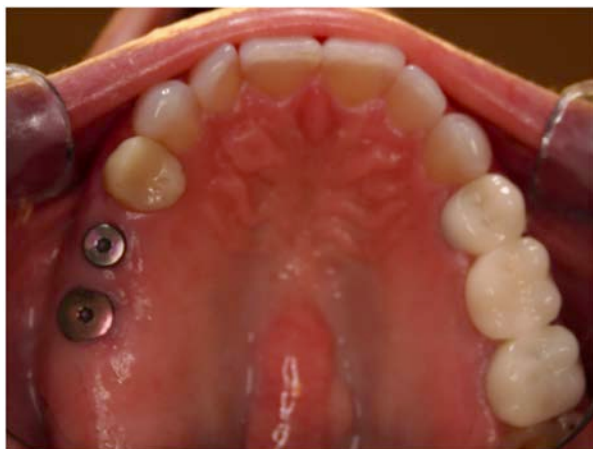


Figure 1.
Courtesy of Dr. Samuel L. Corey.

modifications have been shown to produce better results than subtractive modifications, where dental implants have rougher surfaces.³² Disadvantages of subtractive processes include an increased ion leakage and increased adherence of macrophages resulting in subsequent bone resorption.²⁹

Reasons Why Dental Implants Fail

Empirical research studies continue to correlate implant complications and failures to three factors: the implant system, patient, and dentist. Implant system failures include poor design of the implant body, insufficient number of implants, screw loosening, large microgap, abutment/implant precision, armamentarium, and implant surface. Patient factors involve variables such as genetic susceptibility, immune system, parafunctional habits, preexisting and postoperative medical conditions, self-care, recall compliance, physical impairment, and smoking.¹³ Dental practice factors may include preoperative, operative, postsurgical, and restorative. Preoperative factors include poor quality or quantity of soft and soft tissues, inadequate preliminary procedures, occlusal relationships, and treatment planning. A recent systematic review and meta-analysis in the *Journal of Periodontology* conducted by Bassir et al found early placement of dental implants (complete soft tissue coverage) had similar postsurgical clinical outcomes when compared to immediate placement after extraction and delayed placement of dental implants. However, long-term stability of hard tissues surrounding the dental implant were greater with early placement than immediate placement of dental implants.⁵⁴ Operative factors include excessive drill speed and pressures, frictional heat, insufficient irrigation, inappropriate bioengineering, trauma to anatomical structures, malposition of the implant, and wound closure. Postsurgical factors include surgical asepsis, wound care, patient medications and self-care, future implant assessment by the dental team, and most importantly the mucoperiosteal-implant seal that is needed for long-term prognosis.⁴¹

Treatment and maintenance are more complex with dental implants. The tissues around dental implants react to bacteria similarly to

the tissues around natural teeth. Pathogenic bacteria attach to dental implant surfaces leading to the potential breakdown of this biological seal surrounding the osseointegrated implant. Although the junctional epithelium attachment for dental implants is similar to natural dentition, the connective tissue interface with the dental implant has poor mechanical resistance. The lack of the connective tissue barrier around dental implants allows pathogenic bacteria access to destroy bone. This peri-implant disease process resembles periodontal disease with natural teeth. In fact, keratinized tissue is a vital outcome postoperatively, as plaque retention and pathogenic bacterial invasion will occur around titanium implant abutments. Frequent evaluation and assessment by the dental team is essential to the success of dental implant procedures.³¹ Many of the current self-care treatments for periodontal maintenance of natural teeth also can be used with dental implants, but a better understanding of these self-care practices by the patient is crucial for the health of the soft and hard tissues and the longevity of their dental implants.⁴⁹

Peri-implant Anatomy and Biology

When a dental implant comes in contact with bodily tissues and fluids, within milliseconds water, ions, and small biomolecules are absorbed. The osseointegration process can be compared to bone fracture healing. The process includes an inflammatory reaction, bone resorption, release of growth factors, and the attraction of osteoprogenitor chemotaxis cells. A differentiation of the cells into osteoblasts leads to bone formation at the dental implant surface. Extracellular matrix proteins modulate apatite crystal formation.^{29,43}

As mentioned prior, the success of the dental implant begins with the initial immobility of the implant to the bone after surgical placement for bone to form at the implant-bone interface. New bone formation follows a specific sequence. Woven bone is quickly formed between the implant and bone with collagen fibrils. The bone will grow quickly and in all directions at a rate of approximately 100 um per day. After several months, woven bone is replaced by lamellar bone with layers of

collagen fibrils and dense bone mineralization. Lamellar bone grows slowly, only a few microns per day. After approximately 18 months of healing, lamellar bone is resorbed and replaced.²⁹

There are two important stability stages. The *primary stability* is the time of the surgical placement of the dental implant. Success of a dental implant is also determined by the placement of the implant, as well as the quality and quantity of the bone available for anchorage of the implant at the surgical site e.g., cortical bone. The *secondary stability* of the implant determines the percentage of contacts between the implant and bone. This is achieved over time with healing of the implant surface, as well as the quality and quantity of the adjacent bone.²⁹ Both primary and secondary stability are crucial to the success of the dental implant (Figure 2). Posterior maxilla implants have been associated with lower success rates, compared to other sites, due to less bone density and support creating less bone-to-implant contact.²¹

Biomechanical Assessment

The importance of biomechanics with dental implants was initially underestimated. Clinical experience and research over the years has shown the significant importance of biomechanics in the success and predictability of implants. When a prosthesis is installed immediately, for example 1 day to 2 weeks, occlusal overload must be avoided.^{26-27,29} Sites such as maxillary posterior implants will likely undergo periods of less bone support in the early stages of bone apposition due to the

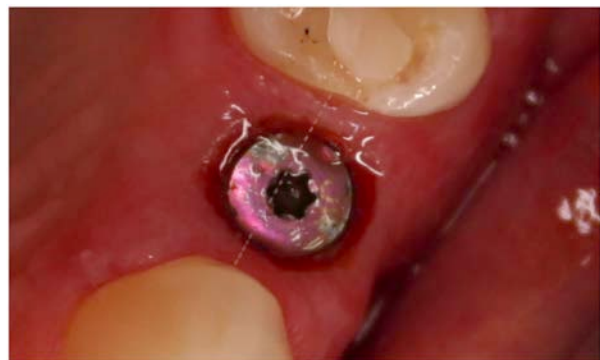

Figure 2.
Courtesy of Dr. Samuel L. Corey.

initial stage of bone resorption. However, once osseointegration is achieved, dental implants will resist forces of occlusion.

The absence of a periodontal ligament around the dental implant reduces tactile sensitivity and the patient's reflex function, as well as the implant not being able to migrate to compensate for premature occlusal contacts like natural dentition with a periodontal ligament. Implants and their rigid-attached restoration do not move. Therefore, biomechanic assessment is crucial to implant success.^{35,40}

Bone response to mechanical occlusal overload, improper implant occlusal design, or parafunctional habits may cause microfractures in the bone leading to bone loss and fibrous inflammatory tissue around the implant. Excessive forces are destructive to osseointegration and long-term success. The load-bearing capacity of implants are influenced by several factors, including the size and number of implants, the arrangement and angulation of the implants, and the quality of the bone.^{9,29}

When excessive loads persist, bone loss will continue, leading to implant failure. The percentage of bone-to-implant ratio, called the bone appositional index, is an important factor to consider when evaluating the load-bearing capacity. Less bone density and a low bone-to-implant contact provide less support and resistance to occlusal loading. For example, with the posterior maxilla, the bone appositional index is significantly less than the anterior mandible (Figure 3). The trabecular bone in the anterior mandible is typically dense with a thick cortical bone layer. However, in the posterior maxilla, the trabecular bone is less dense and the cortical bone layer is thin. The bone appositional index for implants in the posterior maxilla will typically range from 30-60%, where the index for implants in the anterior mandible typically ranges from 65-90%.³⁰⁻⁴²

Preventive treatment such as occlusal mouthguards and equilibration are considered depending on the individual patient. Other considerations in regards to anatomic location involving the posterior maxilla as the maxillary

sinus, where it can limit the dental implant length. Sinus lift surgery is used in conjunction with posterior maxilla dental implant therapy with greater success. With mandibular implants, the inferior alveolar nerve limits the length of the implants used. Augmentation and graft procedures appear to be widely accepted producing improved implant predictability.³⁸

Clinical Evaluation and Assessment

Clinicians must use comprehensive evaluation and assessment to determine if a patient is eligible for dental implants. If dental implants are placed, it is the role of each clinician to reevaluate and assess the implant patient to prevent potential implant complications. Proper evaluation and treatment planning is essential for dental implant predictability and success.

As mentioned prior, one of the most critical factors in clinical assessment is the biologic connection between the implant and bone. Healthy bone is required for successful osseointegration and long-term dental implant success.¹¹⁻¹² The alveolar bone is measured in diameter and length. The spatial relationship of the bone must be evaluated in a three-dimensional view through radiographic imaging.⁵ The quality of the bone should be evaluated. Healthy bone reflects a continuous, uniform cortical outline and a lacy, well-defined trabecular core.¹⁴ Large marrow spaces, discontinuous cortex or thin, sparse trabeculation should be evaluated, as these negative variables will contribute to poor implant stabilization.^{26-27,29} Poor bone quality may require further healing after bone augmentation to maximize implant-to-bone contact before

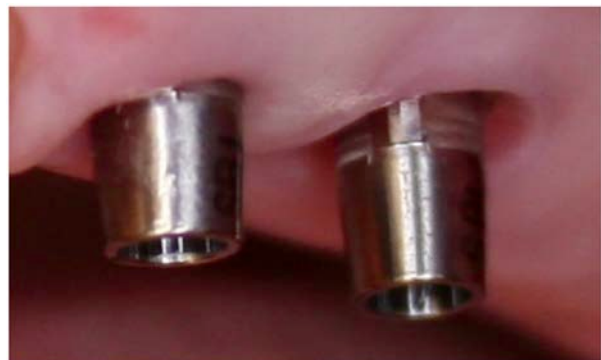

Figure 3.
Courtesy of Dr. Samuel L. Corey.

occlusal loading. A recent *Journal of Clinical Periodontology* systematic review and meta-analysis conducted by Thoma et al found lateral bone augmentation, in conjunction with dental implant placement is a sound treatment modality. However, to produce a defect height reduction, a barrier membrane and grafting material should be combined.⁵⁵

Clinical assessment of the proposed implant site will be evaluated. Adjacent teeth to the site are also evaluated. The interdental space is measured to determine placement and restoration of the implant. Depending on the implant system, the minimal mesial-distal space will be determined. For example, a 4 mm diameter dental implant placed between two teeth would need approximately 7 mm of space. For a 6 mm implant, the minimal space would be approximately 9 mm. There must be sufficient interproximal space for tissue health and patient home care. The interocclusal space needed for each of the implant components e.g., abutment, screw, and crown would vary depending on the type of components used (Figure 4). For example, the minimum interocclusal space required for an external hex-type implant is 7 mm.²⁹ Anatomic location is important, as the failure to accurately assess the location of anatomic structures can lead to unnecessary complications.

Based on the patient's parafunctional status, the evaluation of current bruxing and clenching habits and the current occlusion

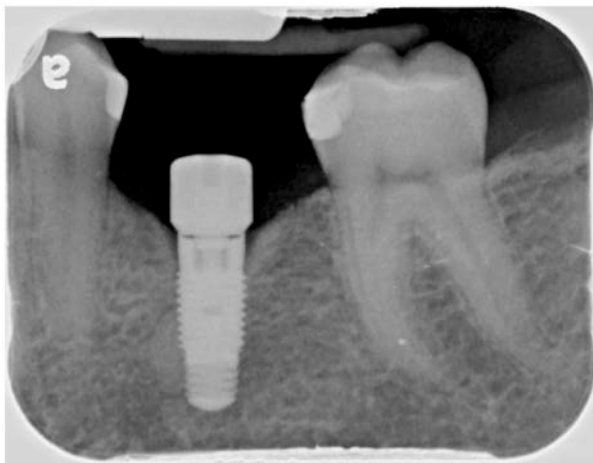

Figure 4.
Courtesy of Dr. Samuel L. Corey.

and bone levels are assessed. If needed, bone augmentation treatment e.g., localized ridge augmentation and/or sinus lift will be completed. A recent systematic review and meta-analysis conducted by Zhou et al found bruxing was a contributing factor in dental implant complications leading to implant failures.⁵³ A soft tissue evaluation may reveal future augmentation of gingival and connective tissue grafts required for keratinized mucosa during post-treatment healing. Clinical assessment should also include the etiology and duration of past tooth loss and, if there is a history of a traumatic extraction in the proposed implant site, indicating possible alveolar bone complications.

Peri-implant Mucositis and Peri-implantitis Risk Factors

Just like natural dentition, dental implants have potential risk factors that may impact the health of the periodontium. Some of the more common risk factors include patient health status and genetic susceptibility/immunology, surgical placement, and patient self-care practices.

Patient's Health Status

In conjunction with clinical assessment, the patient's current health status and successful wound healing after post-treatment implant therapy is essential for dental implant success.

Pretreatment evaluation includes a comprehensive evaluation of the patient's current medical and dental status, including systemic conditions, medications, habits (e.g., tobacco use), periodontal evaluation, and compliance with past and current preventive care. As clinicians, we know that identifying potential risk factors² during pretreatment evaluation and any risk factors that develop after post-treatment will reduce potential complications for the dental implant patient. In a recent retrospective clinical study conducted by Hakam et al at the University of Florida College of Dentistry found patients who were prescribed antidepressants were at a higher rate of implant failure than non-users. The researchers also found that patients were at the greatest risk of implant failure when they were prescribed serotonin-norepinephrine reuptake

inhibitors (SNRI) and tricyclic antidepressants (TCA), as opposed to patients prescribed selective serotonin reuptake inhibitors (SSRI), atypical antidepressants (AA), and monoamine oxidase inhibitors (MAOI) antidepressants.⁵⁷ In a recent systematic review and meta-analysis Naseri et al found that patients who smoked >20 cigarettes a day had greater implant failure than patients who did not smoke. The researchers concluded an elevation in dental implant failures with the number of daily cigarettes consumed by patients.⁵⁰ Another recent meta-analysis conducted by Kim et al found two factors that affected dental implant failure: smoking and residual bone height.⁵¹ Medical and systemic issues, such as patients diagnosed with poorly-controlled diabetes, bone metabolic diseases such as osteoporosis, radiation therapy, bisphosphate therapy, immunosuppression medications, and immunocompromising diseases are risk factors that will be discussed with the patient.^{18,40} A recent systematic review by Bazli et al found osteoporosis, smoking, and head and neck radiotherapy were higher risk factors in dental implant failure.⁵² Behavioral conditions that may interfere with treatment and post-treatment care include tobacco use, substance abuse, and parafunctional habits. Current infection such as periodontal disease or other pathologies of the oral cavity will provide a current comprehensive evaluation of the patient used to determine if the patient is an appropriate candidate for dental implants or another type of prosthesis.⁴⁸

Patient's Genetic Susceptibility and Immunology

Clinicians know that an individual's exposure to specific pathogenic bacteria and their immunoinflammatory response determine disease susceptibility. We also know that the role of an individual's genetic predisposition e.g., inherited variation in DNA and other risk factors create a complex combination of variables that determine if and when a disease affects our patients. These variables also determine how the disease will progress and how the patient will respond to dental treatment.

The host response to the bacterial challenge from dental biofilm plays a major role in the initiation and destruction of the periodontium.²

The interaction between the host-microbes are dynamic, where the microbial composition of biofilm and the host immune response vary widely with each individual. Our body's own innate immune response to infections is what contributes to destruction of the periodontium. Elevated levels of immunoglobulins can increase localized destruction of the periodontal tissues through the body's self-reactive antibodies.¹⁰ For example, specific immunoglobins are linked to both periodontal disease and systemic diseases e.g., cardiovascular and rheumatoid arthritis. Inflammation arises primarily in response to infection. Our body's inflammatory response contributes too many disease processes including periodontal disease. The introduction and activity of biological mediators e.g., cytokines and matrix metalloproteases (MMP) contributes to disease progression. Collectively, MMPs, such as MMP-13 are capable of damaging the extracellular matrix. The complex network of cytokines can play an important role in periodontal pathogens and alveolar bone resorption.² These types of mediators are biological markers and are used in diagnostic salivary testing.

Peri-implant mucositis is an inflammatory change of the peri-implant soft tissues with no alveolar bone loss. Peri-implantitis is an inflammatory response around an osseointegrated implant resulting in loss of soft tissue and bone. Gingivitis most likely progresses around the implant due to the unreliability of the perimucosal seal and the lack of fiber barriers between the dental implant and the soft tissue of the sulcus. Peri-implant plaque accumulation can result in peri-implant mucositis and peri-implantitis. Peri-implantitis inflammation is confined to the soft tissue, with progressive crestal bone loss and is reported to affect up to 80% of dental implant patients.² Risk factors for peri-implantitis includes poor oral hygiene, residual cement, current or history of periodontitis, cigarette smoking, and diabetes.¹⁵ The relationship between peri-implant mucositis and peri-implantitis is similar to gingivitis and periodontitis, respectively. However, severity and rate of disease progression appears to be more pronounced around dental implants. Peri-implant mucositis can be effectively

treated with nonsurgical mechanical therapy, However, it does not appear to be predictable and successful with peri-implantitis.^{2,22} The major difference between gingival attachment to a natural tooth and a dental implant is that the implant surface lacks cementum with connective tissue fiber inserts.

Surgical Placement and Post-treatment Concerns

Just like any type of wound healing in the body, microbial contamination jeopardizes bone healing. Strict aseptic techniques by the dental team during surgical placement is crucial to implant success. If bone is overheated or damaged during surgical preparation, it will become necrotic leading to soft tissue scar formation. The critical temperature for bone is less than 116.6 degrees F at an exposure time not to exceed one minute. Profuse irrigation with gentle, intermittent, moderate-speed drilling using sharp rotary instruments is required.²⁹ A mild inflammatory response will promote wound healing. However, a moderate inflammatory response or movement above a certain threshold e.g., above 150 um can be detrimental to implant success. Bone tissue damage and debris at the osteotomy site must be cleared by osteoclasts for normal bone healing. These cells originating from the blood can resorb bone at a rate of 50-100 um per day.²⁹ A proper vascular supply and oxygen tension are needed for bone apposition. If oxygen is poor, the stem cells may differentiate into fibroblasts forming scar tissue leading to the nonintegration of the implant and bone and implant failure.⁹

Post-treatment Clinical Evaluation and Care

A strict prophylaxis recare schedule should be established and maintained to monitor any changes. The patient is seen for comprehensive oral hygiene instructions and soft-tissue examination after the prosthesis is placed. Follow-up visits are scheduled as appropriate. At this appointment, the dental team reviews the adequacy of self-care procedures and re-evaluates the health of the peri-implant tissues. A three-month recare schedule is suggested for a one-year duration. Depending on the patient's self-care and the individual's

current periodontal status, the patient may then be placed on a six-month recare schedule after the first year. During the first two years, no more than six months should elapse between recare visits.

The early detection, prevention, and treatment of peri-implant diseases are imperative for implant success. Peri-implant maintenance includes the proper placement of the dental implant, patient preventive self-care, and professional care by the dental team. The post-treatment goal is successful healing of the soft tissues and bone layers by creating a fibrous layer interposed between the implant and bone. Continual comprehensive clinical assessment and diagnoses of the post-treatment peri-implant tissues is key. This process includes identifying any current risk factors that may affect dental implants.⁹ The recare clinical examinations include questioning the patient about any pain or concerns, review of their medical status, and the evaluation of soft tissues and dental implant. The appropriate interval for the next appointment is determined based on a new clinical examination. At recare appointments, dental implants are examined for plaque and calculus accumulation around the implant and natural dentition, signs of inflammation and edema, peri-implant soft tissue color, consistency, and contour are also evaluated. Examination also includes palpation and percussion.⁹

In patients with healthy peri-implant tissues, the probing attachment levels are consistently found coronal to the alveolar crest. This indicates the presence of direct connective tissue contact to the dental implant surface. With healthy tissues, the probing depth measurement will be approximately 1.5 mm higher above the bone level.² At inflamed sites, increased probing depths and reduced attachment levels may occur. Note that probing measurements can be inaccurate due to probe placement. The limitations in probing leads clinicians to depend on radiographic images and other forms of clinical assessment.²³⁻²⁴

Peri-implant soft tissues are similar in structure and clinical appearance as periodontal soft

tissues. The soft tissues consist of epithelial and connective tissues. Implants have a gingival/mucosal sulcus, a long junctional epithelial attachment, with connective tissue above the supporting bone. However, dental implants do not have a periodontal ligament or inserting collagen fibers. Clinically, the thickness of the peri-implant soft tissues will vary from 2 mm or more.²⁹ As with natural dentition, there is continuous epithelium around the implant with a sulcular epithelium that lines the inner surface of the gingival sulcus. The apical portion of the gingival sulcus is lined with long junctional epithelium. The zone of the supracrestal connective tissue fibers provides a seal to the outside oral environment.⁶ The bone-to-implant interface with its rigidity can lead to biomechanical issues, as well as the healing of the soft tissue-to-implant interface influence long-term success of the dental implant.²⁸

The presence of keratinized gingiva is not necessarily correlated to long-term stability. However, dental implants surrounded by nonkeratinized mucosa only may be more susceptible to peri-implant complications. Keratinized mucosa tends to be more firmly anchored to the periosteum by collagen fibers than nonkeratinized mucosa that has more elastic fibers making the tissue slightly mobile.²⁶⁻²⁷ When there is nonkeratinized tissue, patients may complain about pain while performing preventive self-care. The symptoms can be alleviated by increasing the amount of keratinized tissue around the implant with soft tissue grafting.²⁹

Soft tissues surrounding dental implants also have the same inflammatory response to plaque accumulation as natural dentition. Polymorphonuclear and mononuclear cells transmigrate through peri-implant sulcular epithelium as does natural dentition. It is expected that 1.2 mm marginal bone loss occurs the first year after implant placement and 0.1 mm per year afterwards. However, higher levels of bone loss is abnormal. Pathologic bone loss can occur along the entire dental implant or around the crestal portion of the dental implant, indicating poor osseointegration, peri-implantitis, or occlusal stress.^{26-27,29}

Dental implant movement impairs the differentiation of osteoblasts resulting in fibrous scar tissue forming between the implant and bone.²⁶⁻²⁷ It is imperative to avoid excessive forces, including occlusal loading during the early stages of healing. Multiunit implant restorations may be splinted to distribute the occlusal load maximizing implant support.² Mobility of soft tissues, due to nonkeratinized tissue surrounding the dental implant is also associated with a higher incidence of implant failure.²⁹ Occlusion should be checked at each recall appointment examination. Implant patients who brux or clench should receive an occlusal guard.

At each recare visit, the dental professional should perform a clinical assessment of peri-implant soft tissues by examining the color, surface texture, and note any bleeding and inflammation. When probing, the use of a non-metal periodontal probe will not contaminate the titanium surface, is gentle to tissue, and safe against damaging dental implant surfaces. Some clinical researchers suggest that periodontal probing be performed at infrequent intervals at one site (the same site each time) with light pressure. As with natural dentition, the dental professional must be careful not to contaminate the dental implant sulcus with bacteria from a diseased periodontal sulcus. It is recommended that the periodontal probe be dipped in chlorhexidine gluconate between periodontal probing measurements to avoid contamination.

When examining the implant, the dental professional must chart the presence of plaque and calculus deposits around the implant surfaces. The bacteria responsible for periodontitis are the same for peri-implantitis. These pathogenic bacteria are gram-negative anaerobic bacteria, including: *Bacteroides forsythus*, *actinobacillus actinomycetemcomitans*, *porphyromonas gingivalis*, and *Treponema denticola* shown to contribute to failing implant sites. After the soft tissue has been examined, the next step is to evaluate mobility of the implants, transmucosal abutments, and prosthetic superstructure. Seventy-eight percent of failing implants have excess mobility. Mastication or lack of tissue stability at the junction of the dental implant and connective

tissue can cause apical migration of the junctional epithelium which in turn causes gingival recession, alveolar bone loss, and pocketing. The occlusion should be monitored at recare appointments to detect occlusal changes. Occlusal equilibration may be needed.

One of the most important pre and post-operative tools to evaluate the health and success of the dental implant is radiographic images. It is a reliable periodontal indices for evaluating failing implants. A mobile implant may display a narrow, radiolucent space surrounding the implant-bone interface. Radiographic images can assess bone height and density and show the functional relationship between the prosthesis, implant, and abutment components. It is suggested that radiographic images, excluding the baseline radiographic image taken one week post-surgery, be taken every three months after initial placement of the implant. After the first year, radiographic images should be taken once each year. It is recommended that CBCT imaging be used for measuring cortical bone thickness, as well as being utilized in post-operative imaging. However, past studies acknowledge its limitations such as overestimating the vertical distance between the top of the implant and the crestal bone.³⁶

For dental implant plaque and calculus removal, only instruments that do not damage the implant surfaces may be used. In commercial use and form, pure is soft, non-magnetic, and passive. These metallic surfaces develop a layer of titanium oxide that does not undergo any further breakdown under physiologic situations. Damage can lead to changes in the surface chemistry of the material, resulting in corrosion. Surface roughness and corrosion facilitate plaque retention, ultimately compromising the implant. It is therefore imperative that no oral health maintenance procedure directly affect this titanium oxide surface layer.²⁵

Conventional metal curettes cause considerable changes to the implant surface. Only instruments made of plastic, graphite, nylon, or those with a Teflon[®]-coating should be in contact with the implant. The use of a dissimilar metal (such as stainless steel) on titanium may

lead to corrosion. The use of these dissimilar metals on implant surfaces have been studied in vitro, comparing the number of human gingival fibroblasts attaching to the surface of a commercially pure titanium-alloy curette. Results showed a significant reduction in the number of fibroblasts attaching to titanium implants that had been scaled with the stainless-steel curette when compared to the plastic and titanium scalers.^{33-34,39} Ultrasonic instrumentation continues to be contraindicated with dental implants. Ultrasonic scalers may severely disrupt the titanium dioxide surface, leading to a multitude of grooves and a roughened surface, which can lead to further plaque retention and a compromised implant. A study utilizing a modified ultrasonic instrument with a custom-designed delvin plastic tip showed that the standard ultrasonic instrument caused considerable scratching and gouging to the titanium implant.⁶ Shallow scratches made with the metal ultrasonic could be polished smooth, but the deeper scratches could not. The modified ultrasonic instrument produced noticeable but minimal changes that when polished did not appear to be microscopically different from the polished control. The modified ultrasonic instrument may be a promising device for maintenance of the dental implant. No definite answer can be made concerning ultrasonic use for implants at this time.^{7,22,25} Although air polishing on implant surfaces was controversial in the past, recent studies have shown air polishing to be effective and safe for maintenance procedures.

After calculus deposits have been removed, the prosthesis and abutments may be selectively polished with a rubber cup and a nonabrasive fine polishing paste. Rubber cup polishing alone appears to be the least abrasive treatment using a prophylaxis paste, commercial implant pastes, or tin-oxide. However, paste deposits will be left on the implant surfaces. A rubber point may also be used. After polishing, the implant, surfaces should be gently irrigated with water to avoid any adverse tissue healing. An antimicrobial solution should be applied to the peri-implant tissues.³⁹

If a dental implant is displaying increased probing depths, bleeding, or any other

indication of the onset of failure, a controlled drug delivery system can be applied. Applying slow-release minocycline hydrochloride spheres has shown clinical improvement within 12 months, including positive results with early cases of peri-implantitis.³⁷

Patient Self-care Recommendations

If the titanium oxide layer of the dental implant is disrupted during oral hygiene procedures, the soft tissues may be exposed to titanium metallic ions that can cause potentially cytotoxic reactions compromising the dental implant. Therefore, detailed instructions by the dental professional should be given initially to the patient and reinforced at each recare appointment to prevent trauma or infection to the tissues around the dental implant. The removal of early pathogenic bacterial accumulation on the dental implant surfaces and the elimination of the majority of plaque biofilm by the patient are crucial for long-term peri-implant success. The preventive maintenance steps for dental implants involve two distinct aspects: (1) patient self-care, and (2) clinical maintenance procedures by the dental team.

No single oral hygiene device has been shown to remove plaque from all surfaces of an implant reconstruction. While there are numerous types of manual and power brushes, flosses, and other oral hygiene products on the market, the literature substantiates the need to minimize the number of devices initially prescribed for patient self-care. Patient compliance is an essential aspect of any maintenance program and predominantly depends on the relative simplicity of a procedure, the time required, and a minimum number of recommended devices initially. Studies indicate when multiple oral hygiene devices are prescribed at one time, patients can become discouraged and as a result, may be less motivated. However, research shows additional plaque inhibition with a combination of toothbrushing, interdental aids, and antimicrobial mouthrinses. For this reason, it is important to consider appropriate combinations when making recommendations to individual patients.

Manual and Power Toothbrushing, Interdental and Antimicrobial Adjuncts

The dental professional should assist the patient in choosing a manual or power toothbrush the patient likes to successfully access all areas of the oral cavity, as long as they use a soft-bristled toothbrush. If using a manual toothbrush, the modified Bass technique should be used with a vibratory back and forth movement and very short strokes. In this modified technique, the brush is held at a 45-degree angle where the abutment post meets the gingival tissue (Figure 5).⁴⁹

Oscillating-rotating power toothbrushes (Figure 6) and sonic power toothbrushes (Figure 7) do not damage polished implant surfaces and also can be safely used to clean all surfaces of the dental implant. Many power toothbrushes are equipped with soft interchangeable bristle heads. The shorter and pointed tips are ideal for reaching proximal areas of the dental implant.⁴⁹ It's recommended the toothbrush head be dipped in a chlorhexidine gluconate solution. Research studies show a reduction in certain bacteria by 54-97% after six months of use. One oral hygiene implant study examined manual interproximal cleaning aids (Figure 8).⁶ Results demonstrated no change in surface appearance or irregularities of the dental implant.

Interproximal brushes with small brush heads (Figure 9) may also be used to clean

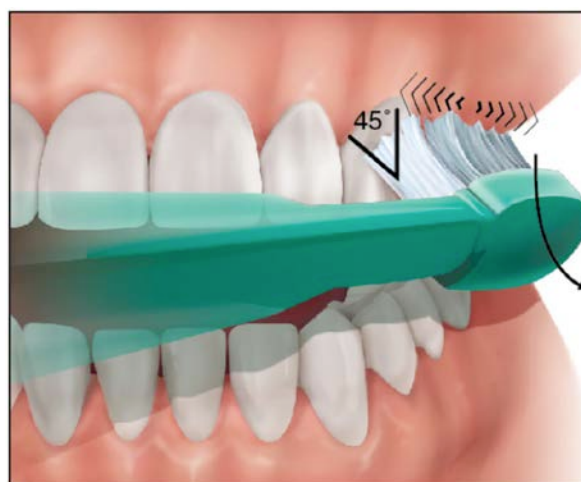

Figure 5. Modified Bass Method.

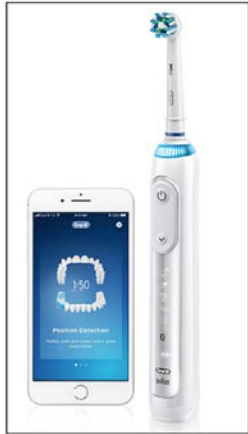

Figure 6. Oral-B®.
Courtesy of Crest + Oral-B.



Figure 7. Sonicare®.
Courtesy of Philips Sonicare.

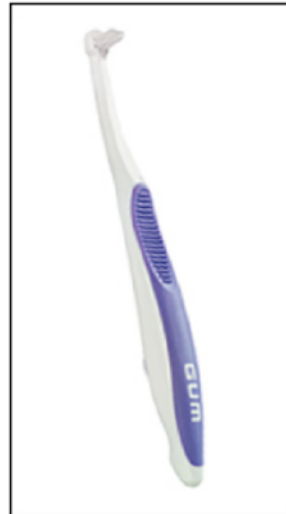

Figure 9. GUM® End-tuft Brush.
Courtesy of Sunstar Americas, Inc.

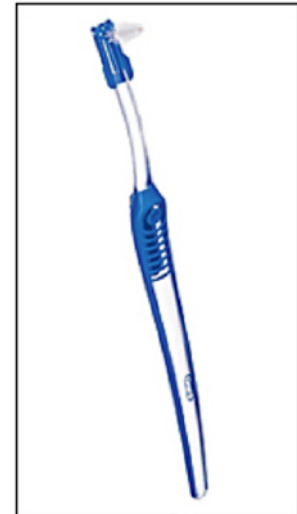

Figure 10. Oral-B® Interdental Brush.
Courtesy of Crest + Oral-B.

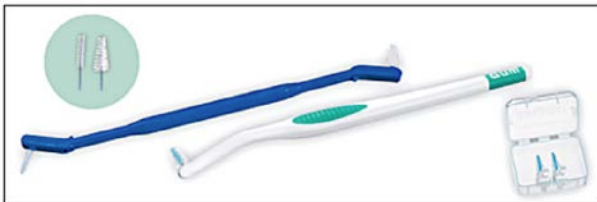

Figure 8. Proxabrush® Interdental System.
Courtesy of Sunstar Americas, Inc.

the dental implant surfaces. However, they must be plastic-coated, as metal can damage or contaminate a dental implant's titanium surface.¹⁶⁻¹⁷ An interdental brush (Figure 10) can be used to massage the gingival tissue around the dental implant to increase blood flow of the surrounding gingiva. The patient should be instructed to insert the tip interproximally and applying a gentle rotary motion.

There are many different types of interdental aids. One type of flossing aid (Figure 11) has a wide band of ribbon with one end designed for use as a threading device, can be threaded around dental implants. Another type of interdental aid is made specifically for dental implant care (Figure 12) and can be used in conjunction with chlorhexidine gluconate. Used in the manner of a "shoe-shine rag" (e.g., a side-to-side motion), the interdental aid polishes the back and sides of the dental implant. In areas with a bridge, floss may be used with a floss threader (Figure 13).

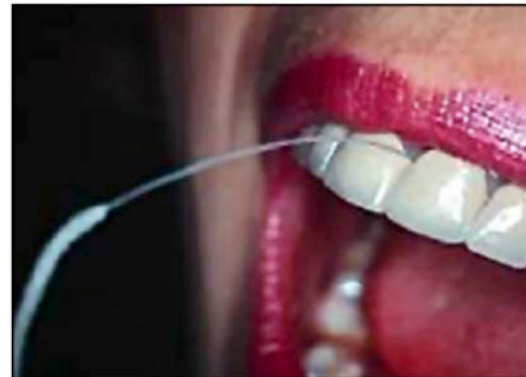

Figure 11. Oral-B® Super Floss.
Courtesy of Crest + Oral-B.

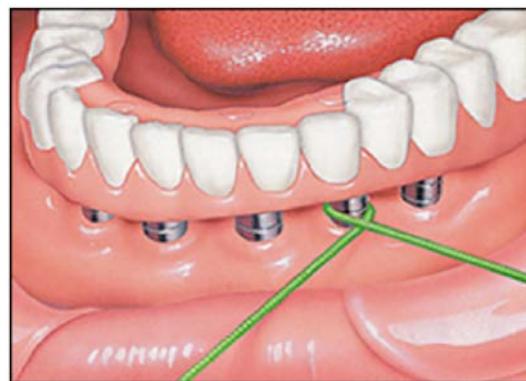


Figure 12. Postcare®.
Courtesy of Sunstar Americas, Inc.



Figure 13. Floss Threader.

The oral irrigator is a beneficial adjunct for removing plaque and debris around dental implants. However, caution must be exercised by the patient when using this device. Incorrect use and excessive water pressure can damage the biological seal. Patients must receive detailed manufacturer's instructions. It's recommended to use manufacturer's videos as well.

Specific pathogenic bacteria in dental plaque plays a major role in both adult periodontitis and peri-implantitis.⁷ The regular use of chemotherapeutic agents, such as chlorhexidine gluconate or phenolic compounds may be used as an irrigant. Chlorhexidine gluconate is a safe adjunct to other oral hygiene procedures in the maintenance of dental implants. An American Dental Association-accepted chlorhexidine gluconate mouthrinse can be effective due to its binding activity to gingival tissues and on titanium abutment surfaces. Treating soft tissue around dental implants with chlorhexidine gluconate mouthrinses will aid in fibroblastic

attachment to dental implant surfaces. The acquired pellicle acts as a chemical reservoir source, releasing chlorhexidine gluconate over a prolonged period of time in concentrations sufficient to maintain bacteriostasis.⁸ About 90% of the cultivable bacteria are inhibited for about five hours with a 0.12% concentration of chlorhexidine gluconate rinsing for 30 seconds. Because staining often accompanies long-term use of chlorhexidine gluconate rinses, it can be applied with a cotton swab around the dental implant as well. Patients should be advised that chronic chlorhexidine gluconate use also can diminish taste sensation. Studies show that chlorhexidine gluconate has no effect on the dental implant surface itself. Disclosing solutions and tablets are a valuable aid in revealing the presence of plaque to the dental implant patient. Inspection of disclosed areas assists the patient in identifying areas of plaque retention and provides immediate feedback on the effectiveness of oral hygiene procedures.

Conclusion

The early detection, prevention, and treatment of peri-implant diseases are imperative for dental implant success. Peri-implant maintenance includes the proper placement of the dental implant, patient preventive self care, and professional care by the dental team. The post-treatment goal is successful healing of the soft tissues and bone layers by creating a fibrous layer interposed between the implant and bone. Continual comprehensive clinical assessment and diagnoses of the post-treatment peri-implant tissues is key. This process includes identifying any current risk factors that may affect dental implants.

Course Test Preview

To receive Continuing Education credit for this course, you must complete the online test. Please go to: www.dentalcare.com/en-us/professional-education/ce-courses/ce514/test

- _____ is a major factor in determining long-term prognosis of the dental implant.**
 - The mucoperiosteal-implant seal
 - Using the high-speed handpiece during the procedure
 - The frequency of professional recare visits
 - Using power toothbrushes
- The peri-implant disease process resembles periodontitis. The dental implant can be compromised if the titanium oxide layer of the implant is disrupted.**
 - Both statements are true.
 - Both statements are false.
 - The first statement is true. The second statement is false.
 - The first statement is false. The second statement is true.
- Studies indicate that when multiple oral hygiene devices are prescribed at one time, the patient _____.**
 - may become discouraged and less motivated
 - may become more motivated and encouraged
 - overly zealous with home care
 - overwhelmed and stop self-care completely
- When using a manual brush the _____ is the preferred toothbrushing method for dental implants.**
 - Fones
 - Modified Bass
 - Modified Stillman
 - Charter's
- When cleaning a dental implant, interdental aid devices, including scalers and periodontal probes, must be _____.**
 - metal to remove all debris from implant
 - made from same material as the implant
 - plastic coated
 - titanium
- A mouthrinse containing _____, aids in the fibroblastic attachment to implant surfaces.**
 - chlorhexidine gluconate
 - phenolic compound
 - plant alkaloids
 - tetracycline
- Currently, the success rate of dental implants has been reported in the scientific literature to be approximately ____%.**
 - 30-35
 - 55-60
 - 70-85
 - 95-98

8. **Ultrasonic instrumentation should _____ be used with dental implants.**
A. never
B. usually
C. always
D. rarely
9. **If an implant is displaying increased probing depths, bleeding, or other indications of the onset of failure, the clinician should _____.**
A. have the patient step up home care maintenance to three times a day
B. remove the implant before more damage is done
C. apply a controlled drug delivery system
D. see the patient on a weekly basis until condition is under control
10. **A 30 second rinse of 0.12 percent concentration of chlorhexidine can inhibit ____ percent of the cultivable bacteria for approximately ____ hours.**
A. 90 / 5
B. 80 / 4
C. 70 / 3
D. 60 / 2
11. **Today, the majority of dental implants being placed in dentistry are _____.**
A. cylindrical or tapered screw-type design
B. blade vent design
C. subperiosteal design
D. transmandibular design
12. **Additive surface modifications such as inorganic mineral coatings and biocoating with growth factors have been shown to produce better results for osseointegration. Subtractive processes may cause an increased ion leakage and increased adherence of macrophages resulting in subsequent bone resorption.**
A. Both statements are true.
B. Both statements are false.
C. The first statement is true. The second statement is false.
D. The first statement is false. The second statement is true.
13. **One of the most critical factors in clinical assessment is the biologic connection between the implant and bone. Healthy bone is required for successful osseointegration and long-term dental implant success.**
A. Both statements are true.
B. Both statements are false.
C. The first statement is true. The second statement is false.
D. The first statement is false. The second statement is true.
14. **Which region of the oral cavity is more complicated due to the quality of bone and the anatomy of structures that are near the proposed implant site?**
A. Mandibular anterior
B. Mandibular posterior
C. Maxillary anterior
D. Maxillary posterior

- 15. Peri-implant soft tissues are different in structure and clinical appearance to periodontal soft tissues. Dental implants do not have a periodontal ligament or inserting collagen fibers.**
- A. Both statements are true.
 - B. Both statements are false.
 - C. The first statement is true. The second statement is false.
 - D. The first statement is false. The second statement is true.
- 16. How would you describe healthy bone tissue?**
- A. Continuous, uniform cortical outline
 - B. Lacy, well-defined trabecular core
 - C. Large marrow spaces
 - D. Thick diaphysis
 - E. A and B only.
- 17. Peri-implant mucositis is an inflammatory change of the peri-implant soft tissues with no alveolar bone loss. Peri-implantitis is an inflammatory response around an osseointegrated implant resulting in loss of soft tissue and bone.**
- A. Both statements are true.
 - B. Both statements are false.
 - C. The first statement is true. The second statement is false.
 - D. The first statement is false. The second statement is true.
- 18. If bone is overheated or damaged during surgical preparation, it can become necrotic. A proper vascular supply and oxygen tension are needed for bone apposition.**
- A. Both statements are true.
 - B. Both statements are false.
 - C. The first statement is true. The second statement is false.
 - D. The first statement is false. The second statement is true.
- 19. Which type of gingival tissue that develops during healing is a better outcome with dental implant longevity?**
- A. Keratinized
 - B. Nonkeratinized
 - C. Both A and B.
 - D. Neither A or B.
- 20. With healthy tissues, the probing depth measurement will be approximately ____ mm higher above the bone level.**
- A. .5
 - B. 1
 - C. 1.5
 - D. 3
 - E. 4

References

1. American Academy of Implant Dentistry. About Dental Implants. Accessed March 23, 2021.
2. American Academy of Periodontology. Peri-implant mucositis and peri-implantitis: a current understanding of their diagnoses and clinical implications. *J Periodontol*. 2013 Apr;84(4):436-43. doi: 10.1902/jop.2013.134001.
3. American Association of Oral and Maxillofacial Surgeons. Dental Implant Surgery. Accessed March 23, 2021.
4. American Dental Association. Implants. Accessed March 23, 2021.
5. Bauman GR, Mills M, Rapley JW, Hallmon WW. Implant maintenance: debridement and peri-implant home care. *Compendium*. 1991 Sep;12(9):644, 646, 648 passim.
6. Balshi TJ. Hygiene maintenance procedures for patients treated with the tissue integrated prosthesis (osseointegration). *Quintessence Int*. 1986 Feb;17(2):95-102.
7. Biesbrock AR, Bartizek RD, Gerlach RW, Terézhalmy GT. Oral hygiene regimens, plaque control, and gingival health: a two-month clinical trial with antimicrobial agents. *J Clin Dent*. 2007;18(4):101-5.
8. Babbush CA, Hahn JA, Krauser JT, et al. *Dental implants: The Art and Science* 2nd Edition. Maryland Heights, MO. Saunders/Elsevier. 2011.
9. Becker W, Becker BE, Newman MG, Nyman S. Clinical and microbiologic findings that may contribute to dental implant failure. *Int J Oral Maxillofac Implants*. 1990 Spring;5(1):31-8.
10. Bosshardt DD, Chappuis V, Buser D. Osseointegration of titanium, titanium alloy and zirconia dental implants: current knowledge and open questions. *Periodontol 2000*. 2017 Feb;73(1):22-40. doi: 10.1111/prd.12179.
11. Branemark PI, Zarb GA, Albrektson T. *Tissue-integrated prosthesis: osseointegration in clinical dentistry*. Chicago, IL. Quintessence. 1992.
12. Chambrone L, Preshaw PM, Ferreira JD, Rodrigues JA, Cassoni A, Shibli JA. Effects of tobacco smoking on the survival rate of dental implants placed in areas of maxillary sinus floor augmentation: a systematic review. *Clin Oral Implants Res*. 2014 Apr;25(4):408-16. doi: 10.1111/clr.12186. Epub 2013 May 7.
13. Chrcanovic BR, Albrektsson T, Wennerberg A. Periodontally compromised vs. periodontally healthy patients and dental implants: a systematic review and meta-analysis. *J Dent*. 2014 Dec;42(12):1509-27. doi: 10.1016/j.jdent.2014.09.013. Epub 2014 Oct 2.
14. Chrcanovic BR, Albrektsson T, Wennerberg A. Smoking and dental implants: A systematic review and meta-analysis. *J Dent*. 2015 May;43(5):487-98. doi: 10.1016/j.jdent.2015.03.003. Epub 2015 Mar 14.
15. Dmytryk JJ, Fox SC, Moriarty JD. The effects of scaling titanium implant surfaces with metal and plastic instruments on cell attachment. *J Periodontol*. 1990 Aug;61(8):491-6. doi: 10.1902/jop.1990.61.8.491.
16. Fox SC, Moriarty JD, Kusy RP. The effects of scaling a titanium implant surface with metal and plastic instruments: an in vitro study. *J Periodontol*. 1990 Aug;61(8):485-90. doi: 10.1902/jop.1990.61.8.485.
17. Giro G, Chambrone L, Goldstein A, et al. Impact of osteoporosis in dental implants: A systematic review. *World J Orthop*. 2015 Mar 18;6(2):311-5. doi: 10.5312/wjo.v6.i2.311. eCollection 2015 Mar 18.
18. Iacono VJ; Committee on Research, Science and Therapy, the American Academy of Periodontology. Dental implants in periodontal therapy. *J Periodontol*. 2000 Dec;71(12):1934-42. doi: 10.1902/jop.2000.71.12.1934.
19. James RA. Peri-implant considerations. *Dent Clin North Am*. 1980 Jul;24(3):415-20.
20. Javed F, Romanos GE. Role of implant diameter on long-term survival of dental implants placed in posterior maxilla: a systematic review. *Clin Oral Investig*. 2015 Jan;19(1):1-10. doi: 10.1007/s00784-014-1333-z. Epub 2014 Nov 1.
21. Kawashima H, Sato S, Kishida M, et al. Treatment of titanium dental implants with three piezoelectric ultrasonic scalers: an in vivo study. *J Periodontol*. 2007 Sep;78(9):1689-94. doi: 10.1902/jop.2007.060496.

22. Kracher CM. Peri-implant postoperative treatment considerations to prevent peri-implantitis. *World Dent Rep. Spr* 2011;3:17-19.
23. Kracher CM. *Cont Educ: Current concepts in preventive dentistry*. Dentalcare.com, 2016.
24. Louropoulou A, Slot DE, Van der Weijden F. Influence of mechanical instruments on the biocompatibility of titanium dental implants surfaces: a systematic review. *Clin Oral Implants Res.* 2015 Jul;26(7):841-50. doi: 10.1111/clr.12365. Epub 2014 Mar 19.
25. Misch CE. *Dental implant prosthetics*. 2nd ed. St. Louis, MO. Mosby. 2015.
26. Resnik RR, Misch CE. *Contemporary implant dentistry*. 4th ed. St. Louis, MO. Mosby. 2021.
27. Moraschini V, Poubel LA, Ferreira VF, et al. Evaluation of survival and success rates of dental implants reported in longitudinal studies with a follow-up period of at least 10 years: a systematic review. *Int J Oral Maxillofac Surg.* 2015 Mar;44(3):377-88. doi: 10.1016/j.ijom.2014.10.023. Epub 2014 Nov 20.
28. Newman MG, Klokkevold PR, Carranza FA, Takei HH. *Newman and Carranza's clinical periodontology*. 13th ed. St. Louis, MO. Saunders. 2019.
29. Nimmons KJ. The expanding esthetic practice: implant maintenance - Part 2. *Comp Esthetics & Restor Prac* May 2005;2-5.
30. Orton GS, Steele DL, Wolinsky LE. Dental professional's role in monitoring and maintenance of tissue-integrated prostheses. *Int J Oral Maxillofac Implants.* 1989 Winter;4(4):305-10.
31. Papaspyridakos P1, Chen CJ, Singh M, et al. Success criteria in implant dentistry: a systematic review. *J Dent Res.* 2012 Mar;91(3):242-8. doi: 10.1177/0022034511431252. Epub 2011 Dec 8.
32. Rapley JW, Swan RH, Hallmon WW, Mills MP. The surface characteristics produced by various oral hygiene instruments and materials on titanium implant abutments. *Int J Oral Maxillofac Implants.* 1990 Spring;5(1):47-52.
33. Ramaglia L, di Lauro AE, Morgese F, et al. Profilometric and standard error of the mean analysis of rough implant surfaces treated with different instrumentations. *Implant Dent.* 2006 Mar;15(1):77-82. doi: 10.1097/01.id.0000202425.35072.4e.
34. Rasmussen RA. *The Branemark System of Oral Reconstruction: A Color Atlas*. St. Louis, MO; Tokyo. Kiyaku EuroAmerica, Inc. 1992.
35. Razavi T, Palmer RM, Davies J, Wilson R, Palmer PJ. Accuracy of measuring the cortical bone thickness adjacent to dental implants using cone beam computed tomography. *Clin Oral Implants Res.* 2010 Jul;21(7):718-25. doi: 10.1111/j.1600-0501.2009.01905.x.
36. Moy PK, Pozzi A, and Beumer J. *Maintenance and follow-up in - Fundamentals of Implant Dentistry*. Vol 2. Krill DB, Faulkner RF. Quintessence Publishing. 2016.
37. Rotundo R, Pagliaro U, Bendinelli E, et al. Long-term outcomes of soft tissue augmentation around dental implants on soft and hard tissue stability: a systematic review. *Clin Oral Implants Res.* 2015 Sep;26 Suppl 11:123-38. doi: 10.1111/clr.12629.
38. Sato S, Kishida M, Ito K. The comparative effect of ultrasonic scalers on titanium surfaces: an in vitro study. *J Periodontol.* 2004 Sep;75(9):1269-73. doi: 10.1902/jop.2004.75.9.1269.
39. Schiegnitz E, Al-Nawas B, Kämmerer PW, et al. Oral rehabilitation with dental implants in irradiated patients: a meta-analysis on implant survival. *Clin Oral Investig.* 2014 Apr;18(3):687-98. doi: 10.1007/s00784-013-1134-9. Epub 2013 Nov 24.
40. Sculean A, Gruber R, Bosshardt DD. Soft tissue wound healing around teeth and dental implants. *J Clin Periodontol.* 2014 Apr;41 Suppl 15:S6-22. doi: 10.1111/jcpe.12206.
41. Singh P. *Atlas of Oral Implantology*. 3rd edition. Maryland Heights, MO. Mosby Elsevier. 2010.
42. Slagter KW, den Hartog L, Bakker NA, et al. Immediate placement of dental implants in the esthetic zone: a systematic review and pooled analysis. *J Periodontol.* 2014 Jul;85(7):e241-50. doi: 10.1902/jop.2014.130632. Epub 2014 Feb 6.
43. Torabinejad M, Goodacre C, and Sabeti M. *Principles and practice of single implant and restorations*. St. Louis, MO. Elsevier Saunders. 2014.
44. van Oirschot BA, Bronkhorst EM, van den Beucken JJ, et al. A systematic review on the long-term success of calcium phosphate plasma-spray-coated dental implants. *Odontology.* 2016 Sep;104(3):347-56. doi: 10.1007/s10266-015-0230-5. Epub 2016 Feb 17.

45. Van Orden AC. Corrosive response of the interface tissue to 316L stainless steel, titanium based alloy, and cobalt based alloys. *The Dental Implant: Clinical and Biological Response of Oral Tissues*. Littleton, MA. PSG. 1985.
46. van Velzen FJ, Ofec R, Schulten EA, et al. 10-year survival rate and the incidence of peri-implant disease of 374 titanium dental implants with a SLA surface: a prospective cohort study in 177 fully and partially edentulous patients. *Clin Oral Implants Res*. 2015 Oct;26(10):1121-8. doi: 10.1111/clr.12499. Epub 2014 Nov 5.
47. Vehemente VA, Chuang SK, Daher S, et al. Risk factors affecting dental implant survival. *J Oral Implantol*. 2002;28(2):74-81. doi: 10.1563/1548-1336(2002)028<0074:RFADIS>2.3.CO;2.
48. van Steenberghe D. Periodontal aspects of osseointegrated oral implants modum Brånemark. *Dent Clin North Am*. 1988 Apr;32(2):355-70.
49. Wilkins EM. *Clinical practice of the dental hygienist*. 12th ed. Philadelphia, PA. Lippincott Williams & Wilkins. 2016.
50. Naseri R, Yaghini J, Feizi A. Levels of smoking and dental implants failure: A systematic review and meta-analysis. *J Clin Periodontol*. 2020 Apr;47(4):518-528. doi: 10.1111/jcpe.13257. Epub 2020 Feb 7.
51. Kim JS, Choi SM, Yoon JH, Lee EJ, Yoon J, Kwon SH, Yeo CD, Ryu JS, Lee JH, You YS, Kim SG, Lee MH, Han BH. What Affects Postoperative Sinusitis and Implant Failure after Dental Implant: A Meta-analysis. *Otolaryngol Head Neck Surg*. 2019 Jun;160(6):974-984. doi: 10.1177/0194599819829747. Epub 2019 Feb 19.
52. Bazli L, Nargesi khoramabadi H, Modarresi Chahardehi A, et al. Factors influencing the failure of dental implants: a systematic review. *Journal of Composites and Compounds*. 2020 2(2):18-25. doi: 10.29252/jcc.2.1.3. Accessed March 23, 2021.
53. Zhou Y, Gao J, Luo L, Wang Y. Does Bruxism Contribute to Dental Implant Failure? A Systematic Review and Meta-Analysis. *Clin Implant Dent Relat Res*. 2016 Apr;18(2):410-20. doi: 10.1111/cid.12300. Epub 2015 Mar 2.
54. Bassir SH, El Kholy K, Chen CY, Lee KH, Intini G. Outcome of early dental implant placement versus other dental implant placement protocols: A systematic review and meta-analysis. *J Periodontol*. 2019 May;90(5):493-506. doi: 10.1002/JPER.18-0338. Epub 2018 Dec 5.
55. Thoma DS, Bienz SP, Figuero E, Jung RE, Sanz-Martín I. Efficacy of lateral bone augmentation performed simultaneously with dental implant placement: A systematic review and meta-analysis. *J Clin Periodontol*. 2019 Jun;46 Suppl 21:257-276. doi: 10.1111/jcpe.13050.
56. Oh SL, Shiau HJ, Reynolds MA. Survival of dental implants at sites after implant failure: A systematic review. *J Prosthet Dent*. 2020 Jan;123(1):54-60. doi: 10.1016/j.prosdent.2018.11.007. Epub 2019 Apr 23.
57. Hakam AE, Vila G, Duarte PM, Mbadu MP, Ai Angary DS, Shuwaikan H, Aukhil I, Neiva R, da Silva HDP, Chang J. Effects of different antidepressant classes on dental implant failure: A retrospective clinical study. *J Periodontol*. 2021 Feb;92(2):196-204. doi: 10.1002/JPER.19-0714. Epub 2020 Aug 14.

Additional Resources

- No Additional Resources Available

About the Author

Connie M. Kracher, PhD, MSD



Dr. Kracher is an Associate Professor of Biology and Director of University Research and Innovation at Purdue University Fort Wayne. Dr. Kracher is a national Key Opinion Leader (KOL) for several R&Ds, consultant for national dental organizations, and has presented for the American Dental Association, American Dental Education Association, and the World Dental Federation. Dr. Kracher is a member of several professional organizations, including the American Association of Dental Research.

Email: kracher@ipfw.edu

Acknowledgements

The author wishes to thank Dr. Samuel L. Corey, DDS, Fort Wayne, Indiana for providing radiographs and images for this course.