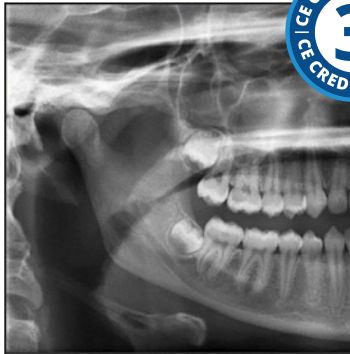


## Radiographic Selection Criteria



**Course Author(s):** Gail F. Williamson, Professor Emerita

**CE Credits:** 3 hours

**Intended Audience:** Dentists, Dental Hygienists, Dental Students, Dental Hygiene Students

**Date Course Online:** 02/03/2020

**Last Revision Date:** 02/01/2023

**Course Expiration Date:** 02/01/2026

**Cost:** Free

**Method:** Self-instructional

**AGD Subject Code(s):** 731

**Online Course:** [www.dentalcare.com/en-us/ce-courses/ce584](http://www.dentalcare.com/en-us/ce-courses/ce584)

**Disclaimer:** Participants must always be aware of the hazards of using limited knowledge in integrating new techniques or procedures into their practice. Only sound evidence-based dentistry should be used in patient therapy.

### Conflict of Interest Disclosure Statement

- The author reports no conflicts of interest associated with this course.

### Introduction – Radiographic Guidelines

The guidelines for prescribing radiographic examinations will be presented and discussed to assist dentists in the appropriate selection of patients for radiographic examinations.

## Course Contents

- Overview
- Learning Objectives
- Introduction
- Informed Consent
- Radiographic Examination of the New Patient
  - Child with Primary Dentition
  - Child with Transitional Dentition
  - Adolescent with Permanent Dentition prior to the Eruption of Third Molars
  - Adult Dentate Patient
  - Adult Edentulous Patient
- Radiographic Examination of the Recall Patient
  - Clinical Caries and Evidence of High-risk Factors for Caries
  - No Clinical Caries and No Evidence of High-risk Factors for Caries
- Radiographic Examination of the Patient with Active Periodontal Disease or a History of Periodontal Treatment
- Radiographic Assessment of Growth and Development and/or Assessment of Dental/Skeletal Relationships
  - Child with Primary and Transitional Dentition
  - Adolescents with Permanent Dentition
  - Adult Dentate, Partially Edentulous or Edentulous Patient
- Patients with Other Circumstances
- Patient Scenarios
- Radiation Exposure Reduction
  - Patient Dose Reduction
  - Operator Dose Reduction
- Summary
- Course Test
- References
- About the Author

## Overview

The guidelines for prescribing radiographic examinations will be presented and discussed to assist dentists in the appropriate selection of patients for radiographic examinations. Clinicians must use clinical judgment to determine the type, frequency, and extent of each radiographic examination. Radiographic imaging should be individualized for each patient and should never be based on administrative or arbitrary requirements such as insurance needs or a fixed time

schedule. The goal of applying radiographic guidelines is to eliminate unnecessary exposures in adherence to the ALARA (As Low As Reasonably Achievable) Principle while maximizing diagnostic yield. The guideline recommendations are based on findings from the scientific literature.

## Learning Objectives

**Upon completion of this course, the dental professional should be able to:**

- Discuss the rationale for using selection criteria for prescribing radiographic examinations for dental patients.
- Describe the importance of informed consent for radiographic examinations.
- Identify situations in which dental radiographs are not indicated nor justified.
- Outline the selection criteria guidelines for the new patient in the following categories: primary dentition, transitional dentition, adolescent, dentate adult, and edentulous adult.
- Discuss the selection criteria guidelines for the recall patient in the following categories including high and low risk factors for caries: child with primary dentition, child with transitional dentition, adolescents, adult dentate patients.
- Select the appropriate radiographic survey for patients with active periodontal disease or a history of periodontal treatment.
- Select the appropriate radiographic survey for the evaluation of growth and development in the following categories: child with primary dentition, child with transitional dentition, adolescents.
- Given a patient scenario, identify the historical factors, clinical signs, symptoms, risk factors and then, recommend an individualized radiographic examination based on selection criteria.
- Discuss methods to reduce radiation exposure to dental patients.
- Identify ways to limit occupational exposure to dental radiation workers.

## Introduction

Radiographic selection criteria were developed to assist the dentist in making informed decisions about diagnostic imaging for patients under their care. The guidelines are

intended to serve as an adjunct to the dentist's professional judgment following a clinical examination, consideration of the patient's medical and dental histories and assessment of the patient's signs, symptoms and susceptibility to environmental factors that may impact oral health.<sup>1</sup> The recommendations are based on evidence from the scientific literature.<sup>1</sup> The information may facilitate the determination of the type and frequency of a radiographic examination when indicated. A radiographic examination should only be prescribed by the dentist when it is expected that the additional diagnostic information will affect the delivery of patient care.<sup>1</sup> The intended goal is to optimize patient treatment while at the same time limit radiation exposure.

There have been several iterations of the selection criteria guidelines. The guidelines were originally developed in 1987<sup>2</sup> by a panel of dental experts and the U.S. Food and Drug Administration (FDA) with subsequent updates by the American Dental Association (ADA) and the FDA in 2004<sup>3</sup> and in 2012.<sup>1</sup> The most recent document, *Dental Radiographic Examinations: Recommendations for Patient Selection and Limiting Radiation Exposure*, will be the focus of this discussion.<sup>1</sup> The general framework of the guidelines includes these major categories:

- type of encounter - new or recall
- patient age designation – child, adolescent, adult
- stage of dental development – primary, transitional, permanent dentitions and partially/completely edentulous
- vulnerability to risk factors – caries, periodontal disease
- growth and developmental monitoring/assessment of dental or skeletal relationships
- other circumstances

The last category takes into consideration such circumstances as proposed or existing implants, dental and craniofacial pathoses, restorative and/or endodontic needs, treated periodontal disease and caries remineralization, although it is not limited to these entities alone.

Recommendations applicable to all of the categories above include the use of intraoral or extraoral imaging for the evaluation of

dentoalveolar trauma; examination of all radiographic images for evidence of caries, alveolar bone loss, developmental anomalies and occult disease; a thorough clinical examination, consideration of the patient history, review of prior radiographs, caries risk assessment and consideration of the general and dental health needs of the patient before proceeding with a radiographic imaging examination. Radiographic screening of the patient for detecting disease prior to a clinical examination should not be performed.<sup>1</sup>

In addition, the dentist can consider indicators such as caries risk as well as historical findings and positive clinical signs and symptoms to determine the need for dental imaging (Table 1).

The guidelines for selecting patients for dental radiographic examinations are not intended to be used as standards of care, requirements or regulations, but rather as a resource for the dentist before prescribing a radiographic examination if indicated.<sup>1</sup> The ethical principles underlying radiation protection include justification (benefit vs. risk decision), optimization (use of all reasonable means to reduce unnecessary radiation exposure) and dose limitation (ensure that no individuals are exposed to unacceptable high radiation doses).<sup>4-6</sup>

The guidelines focus on conventional dental imaging including intraoral and common extraoral projections such as panoramic and cephalometric imaging. The current document excludes cone beam computed tomography (CBCT), a three-dimensional imaging modality, which is being used increasingly in dentistry for specific diagnostic tasks. The American Academy of Oral and Maxillofacial Radiology (AAOMR) has developed several position papers regarding CBCT that can be consulted for further information<sup>7-10</sup> and the ADA has developed a statement on the use of CBCT and the National Council on Radiation Protection and Measurements has addressed the use of CBCT in dentistry.<sup>6,11</sup>

### Informed Consent

Informed consent is a critical concept in health care grounded in the ADA Code of Professional Conduct<sup>12</sup> and the ethical principles of patient autonomy, veracity, non-maleficence,

**Table 1. Historical and Clinical Situations Indicative of the Possible Need for Radiographs.<sup>1</sup>**

Clinical Indicators	
Positive Historical Findings	Positive Clinical Signs and Symptoms
<ol style="list-style-type: none"> <li>1. Previous periodontal or endodontic treatment</li> <li>2. History of pain or trauma</li> <li>3. Familial history of dental anomalies</li> <li>4. Postoperative evaluation of healing</li> <li>5. Remineralization monitoring</li> <li>6. Presence of implants, previous implant related pathosis or evaluation for implant placement</li> </ol>	<ol style="list-style-type: none"> <li>1. Clinical evidence of periodontal disease</li> <li>2. Large or deep restorations</li> <li>3. Deep carious lesions</li> <li>4. Malposed or clinically impacted teeth</li> <li>5. Swelling</li> <li>6. Evidence of dental and/or facial trauma</li> <li>7. Teeth mobility</li> <li>8. Sinus tract/fistula</li> <li>9. Clinically suspected sinus pathosis</li> <li>10. Growth abnormalities</li> <li>11. Oral involvement in known or suspected systemic disease</li> <li>12. Positive neurologic findings in the head and neck</li> <li>13. Evidence of foreign objects</li> <li>14. Pain and/or dysfunction of the temporomandibular joint(s)</li> <li>15. Facial asymmetry</li> <li>16. Abutment teeth for fixed or removable partial prosthesis</li> <li>17. Unexplained bleeding</li> <li>18. Unexplained teeth sensitivity</li> <li>19. Unusual eruption, spacing or migration of teeth</li> <li>20. Unusual tooth morphology, calcification or color</li> <li>21. Unexplained absence of teeth</li> <li>22. Clinical tooth erosion</li> <li>23. Peri-implantitis</li> </ol>

beneficence and justice.<sup>12,13</sup> Informed consent describes both the legal and ethical standard by which to judge the professionally correct relationship between the patient and the health care provider.<sup>13</sup> The health care provider must truthfully impart the necessary information about the proposed procedure so that the patient can make an informed decision about accepting or declining care. This implies a mutual sharing of information between the practitioner and the patient with opportunity for discussion and questions. An ideal relationship is interactive and requires respect for autonomy and choice for both parties involved.<sup>13</sup>

To provide valid legal consent,<sup>13</sup> the patient must:

- be legally capable or competent of choice,
- be informed by the provider about the procedure or care under consideration, including each available course of action in the dentist's professional judgment including no action, and the respective likely outcome, and
- choose or consent voluntarily.

Consent may be implied by an action such as a nod of the head but a verbal or expressed consent is preferable because it more clearly

communicates the patient's actual intent or agreement to proceed with the proposed procedure.

When a minor is under the dentist's care, the child's parents have the legal right to choose and consent to the proposed dental care for their child as do court-appointed guardians for their wards.<sup>13</sup>

The guidelines indicate that the dentist should be prepared to discuss the benefits and risks associated with radiographic examinations with patients and/or their parents or guardians.<sup>1</sup> There are several resources available to assist the dentist in facilitating the conversation about radiation risk.<sup>14-17</sup>

## Radiographic Examination of the New Patient

For new patients being evaluated for oral diseases, the recommendations for radiographic imaging are organized by age and the type of dentition. The radiographic examination, if indicated, should be individualized for each patient taking into consideration the previously discussed parameters and the patient's clinical presentation. Table 2 outlines the recommendations at a glance. Subsequent discussion of each category follows the table.

**Table 2. Radiographic Examination of the New Patient.<sup>1</sup>**

New Patient Recommendations				
Child with Primary Dentition	Child with Mixed Dentition	Adolescent with Permanent Dentition	Adult Dentate Partially Dentate	Adult Edentulous
Individualized exam: selected periapicals or occlusals if indicated	Individualized exam: bitewings & panoramic	Individualized exam: bitewings & panoramic	Individualized exam: bitewings & panoramic	Individualized exam based on clinical signs & symptoms
Bitewings if contacts are closed	Or bitewings & selected periapicals	Or bitewings & selected periapicals	Or bitewings & selected periapicals	
		Full mouth survey if indicated	Full mouth survey if indicated	

### Child with Primary Dentition

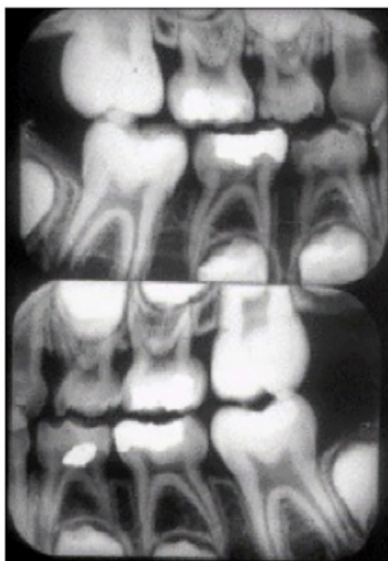The necessity of radiographic imaging for the new child patient with a primary dentition is dependent on the patient's clinical presentation and the clinician's ability to visually inspect the proximal surfaces of the teeth. If the new child patient presents with no evidence of disease and open proximal contacts, a radiographic examination may not be necessary at the present time.

However, once the proximal contacts are closed, radiographic bitewing imaging for caries assessment is warranted. A selected periapical or anterior occlusal radiographic examination may be indicated to evaluate tooth development, dentoalveolar trauma, or suspected pathoses. Periapical and bitewing radiographic imaging may be necessary to assess pulpal pathosis in primary molars.

### Child with Transitional Dentition

For new patients with a mixed or transitional dentition, it is important to consider risk factors for dental caries. Caries incidence varies among children and higher caries patterns are associated with some racial and ethnic groups and lower-income families.<sup>1,18,19</sup> As such, posterior bitewings are indicated (Figure 1).

Although atypical, if clinical evidence of periodontal disease is observed in this age group, selected periapical and bitewing radiographs are indicated to determine the



**Figure 1.** Child Bitewing Survey.

extent of periodontitis and alveolar bone involvement.

Periapical or panoramic imaging is useful for the purposes of evaluating tooth development. Panoramic imaging also is useful to assess craniofacial trauma. Intraoral imaging is preferred over panoramic imaging in the evaluation of dentoalveolar trauma, root shape, root resorption and pulpal pathosis.

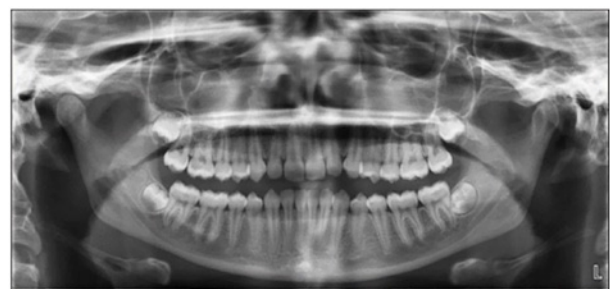Occlusal imaging may be used independently or in combination with panoramic imaging in the following situations:

- an unsatisfactory panoramic image is due to an abnormal incisor relationship.
- for localization of tooth position.
- the clinical examination provides a reasonable expectation of pathosis.

### Adolescent with Permanent Dentition prior to the Eruption of Third Molars

There are a variety of factors that can influence the incidence of caries in the adolescent new patient that may result in increased risk. Among these are variations in dietary habits and inattention to daily oral hygiene practices. These same factors may impact periodontal health. Posterior bitewings and selected periapical images may be useful in these instances. If the patient presents with clinical evidence of generalized oral disease or with a history of extensive prior dental treatment, a full mouth survey is preferred.

Panoramic imaging can be utilized to assess tooth development, particularly the third molar teeth, to determine their presence, position and degree of development (Figure 2). Occlusal and/or periapical images can be used to determine the position of an unerupted or supernumerary tooth.



**Figure 2.** Panoramic Image Third Molar Evaluation.

Depending on the patient's clinical presentation or situation, an individualized radiographic examination comprised of posterior bitewings and selected periapical images or posterior bitewings and a panoramic image is indicated. As previously mentioned, when generalized oral disease or extensive prior dental treatment is observed, a full mouth survey is recommended.

### Adult Dentate Patient

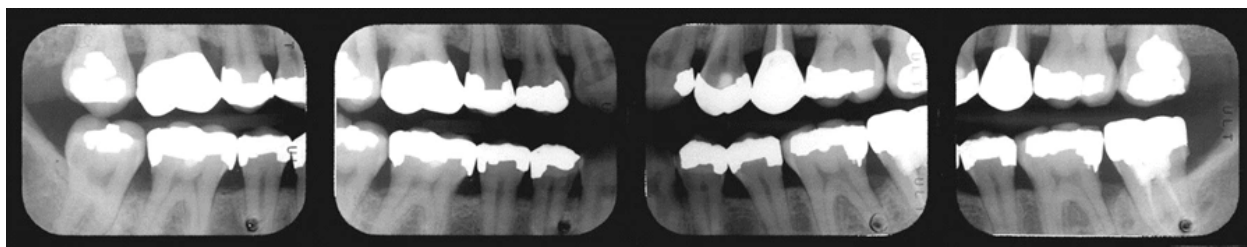
Like other new patients in this category, adult dentate or partially edentulous patients need to be evaluated for proximal and recurrent carious lesions as caries risk and their associated risk factors may change over time. Posterior bitewings can be used for this purpose (Figure 3).

Periodontal disease and root caries increase with age.<sup>1,20,21</sup> Previous experience with periodontal disease and its treatment are

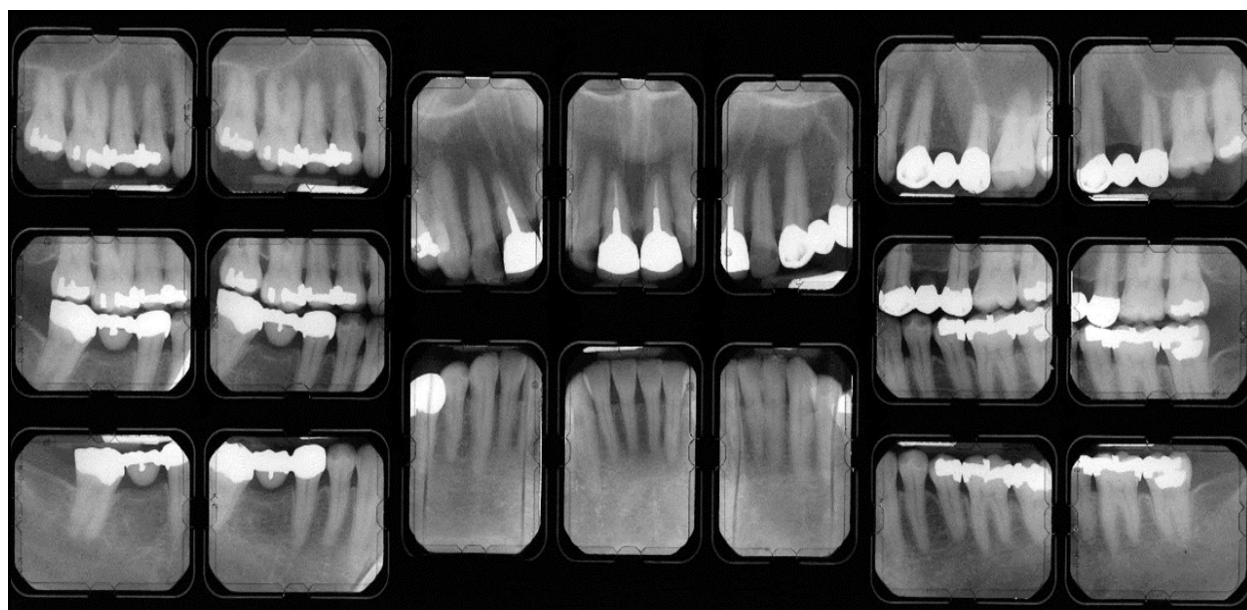important to explore if the new adult patient does not present with signs or symptoms of active disease.<sup>1</sup> Selected intraoral imaging may be necessary to assess the patient's current periodontal status.

Panoramic imaging may be useful in conjunction with posterior bitewings if periapical pathosis or unerupted teeth are suspected, partially erupted teeth are observed, carious lesions are present or clinical facial swelling is evident.<sup>22</sup>

In summary, an individualized radiographic examination comprised of posterior bitewings and selected periapical images or posterior bitewings and a panoramic image are recommended when indicated. If the patient presents with clinical evidence of generalized oral disease or a history of extensive dental treatment, a full mouth survey is preferred (Figure 4).



**Figure 3.** Posterior Bitewing Radiographs



**Figure 4.** Full Mouth Series of Radiographs

### Adult Edentulous Patient

For the edentulous new patient, an individualized radiographic examination based on patient clinical signs, symptoms and the proposed treatment plan is recommended.<sup>1</sup> Several studies which focused on treatment outcomes indicated that there is little evidence to warrant screening radiographic imaging for the new edentulous patient.<sup>1,23,24</sup>

For those edentulous new patients who present for the initial assessment of oral prosthetic treatment, a radiographic prescription was deemed appropriate.<sup>1</sup> The radiographic examination recommended in this instance may consist of the following possible surveys: full mouth periapical images or a combination of panoramic, occlusal or other extraoral imaging. This is especially important when implant therapy is planned for the edentulous new patient as radiographic imaging is important in the diagnosis, prognosis and treatment of the patient.<sup>1,8</sup>

### Radiographic Examination of the Recall Patient

Bitewing radiography, primarily for the purpose of detecting interproximal caries, is the only time-based type of radiographic examination included in the guidelines. The recommended intervals are based on research regarding the rate of caries progression through tooth structure and factors that indicate the patient may be at increased risk for caries. Risk factors associated with caries development include poor oral hygiene, high frequency sucrose exposure, and low fluoride intake. The ADA provides further information on caries risk in their document, [Caries Risk Assessment and Management](#),<sup>25</sup> and assessment form resources are available to facilitate risk determination in children, [Caries Risk Assessment Form \(Age 0-6\)](#)<sup>26</sup> and [Caries Risk Assessment Form \(Age >6\)](#).<sup>27</sup>

Table 3 summarizes the radiographic recommendations for recall patients with clinical caries or those who are at increased

**Table 3. Radiographic Examination of the Recall Patient Based on Caries Risk.<sup>1</sup>**

Recall Patient Recommendations Based on Caries Risk					
Recall Patient	Child with Primary Dentition	Child with Mixed Dentition	Adolescent with Permanent Dentition	Adult Dentate Partially Dentate	Adult Edentulous
With Clinical Caries or Increased Caries Risk	Bitewings at 6 to 12 month intervals if contacts are closed	Bitewings at 6 to 12 month intervals if contacts are closed	Bitewings at 6 to 12 month intervals if contacts are closed	Bitewings at 6 to 18 month intervals	Not Applicable
With No Clinical Caries or Low Caries Risk	Bitewings at 12 to 24 month intervals if contacts are closed	Bitewings at 12 to 24 month intervals if contacts are closed	Bitewings at 18 to 36 month intervals	Bitewings at 24 to 36 month intervals	Not Applicable

risk for caries. In addition, the recall patient who presents with no clinical caries or who is at low risk for caries is also addressed.

### **Clinical Caries and Evidence of High-risk Factors for Caries**

#### ***Children with Primary and Transitional Dentition***

The recall child patient with either a primary or transitional dentition who presents with evidence of clinical caries, may have proximal caries. Identification of additional risk factors suggest proximal caries may be present as well. If the proximal contacts are closed, bitewing radiographic imaging is the only means of detecting the carious lesions. In such circumstances, a posterior bitewing examination is recommended at 6-to-12 month intervals. Usually two posterior bitewings are adequate to examine the proximal surfaces of the teeth, one on each side.

#### ***Adolescents***

Similarly, the recall adolescent patient with a permanent dentition who presents with evidence of clinical caries and/or risks factors for caries, may have proximal caries present. A posterior bitewing examination is recommended at 6-to-12 month intervals when proximal contacts are closed. Usually two to four posterior bitewings are adequate to examine the proximal surfaces of the teeth, one or two on each side.

#### ***Adult Dentate, Partially Edentulous, Edentulous Patient***

Adult recall patients either dentate or partially edentulous who present with clinical caries or increased risk factors for such, should be examined radiographically for new or recurrent carious lesions. The time interval should be determined based on caries risk assessment. A posterior bitewing radiographic examination is recommended at 6-to-18 month intervals. The patient's caries risk may change so the recall interval may need to be adjusted over time. For the adult edentulous recall patient, no radiographic examination is indicated without evidence of disease.

### **No Clinical Caries and No Evidence of High-risk Factors for Caries**

#### ***Child with Primary and Transitional Dentition***

The recall child patient with either a primary or transitional dentition who presents with no evidence of clinical caries or no increased risk factors for caries, may have proximal caries. As previously mentioned, increased caries risk has been demonstrated in specific subgroups of children<sup>18,19</sup> and these data should be taken into consideration when determining the frequency of the radiographic examination. A posterior bitewing examination is recommended at 12-to-24 month intervals if the proximal surfaces of the teeth cannot be examined clinically. The interval recommendation is based on the rate of caries progression in primary and transitional dentitions. Children receiving routine dental care are more likely to be at a lower risk for caries.<sup>1</sup>

#### ***Adolescents***

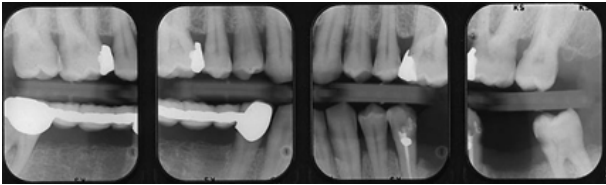
The recall adolescent patient with a permanent dentition who presents with no evidence of clinical caries or no increased risk factors for caries, may have proximal caries. As such, proximal carious lesions can only be identified through radiographic means. The radiographic recommendation consists of posterior bitewings at 18-to-36 month intervals. The time frame is based on the rate of caries progression in this age group while taking into consideration the caries susceptibility of young permanent teeth.

#### ***Adult Dentate, Partially Edentulous, Edentulous Patient***

The recall adult dentate or partially edentulous patient who receives regular care and presents with no signs and symptoms of oral disease have a low caries risk. Caries risk factors may change over time, and this must be taken into consideration when evaluating the adult recall patient. The recommended radiographic examination is posterior bitewings at 24-to-36 month intervals. Radiographic examination of the recall adult edentulous patient is not indicated.

**Radiographic Examination of the Patient with Active Periodontal Disease or a History of Periodontal Treatment**

The determination regarding radiographic examination of the recall child, adolescent or adult patient with clinical evidence of periodontal disease or a history thereof, is based on the expectation that the information obtained will be critical to proper diagnosis and treatment. A clinical examination of the periodontium should be performed as well as documentation of the clinical signs and symptoms of periodontal disease in order to effectively determine the type and frequency of the radiographic examination. Professional judgment and case-by-case evaluation is necessary to determine the appropriate survey. The recommended survey may consist of, but is not limited to, selected periapical and bitewing images where periodontal disease other than nonspecific gingivitis is clinically evident.<sup>1</sup> See Table 4 for a summary of the radiographic recommendations.



**Figure 6. Vertical Posterior Bitewing Images**

**Radiographic Assessment of Growth and Development and/or Assessment of Dental/Skeletal Relationships**

During various stages of life, assessment of patient growth and development and/or assessment of dental or skeletal relationships may be indicated. This could include eruption patterns of primary or permanent teeth or skeletal relationships to correct malocclusion. Table 5 summarizes the recommendations outlined for new or recall child, adolescent and adult dentate or partially edentulous patients in this category.

**Table 4. Radiographic Examination of the Recall Patient Based on Periodontal Disease.<sup>1</sup>**

Recall Patient Recommendations Based on Periodontal Disease					
Recall Patient	Child with Primary Dentition	Child with Mixed Dentition	Adolescent with Permanent Dentition	Adult Dentate Partially Dentate	Adult Edentulous
With Periodontal Disease	Clinical judgment for need & type of images	Clinical judgment for need & type of images	Clinical judgment for need & type of images	Clinical judgment for need & type of images	Not Applicable
	May include selected periapicals and/or bitewings as indicated	May include selected periapicals and/or bitewings as indicated	May include selected periapicals and/or bitewings as indicated	May include selected periapicals and/or bitewings as indicated	

**Table 5. Radiographic Examination of New or Recall Patients to Monitor Growth and Development or to Assess Dental or Skeletal Relationships.<sup>1</sup>**

New or Recall Patient Recommendations to Monitor Growth and Development or to Assess Dental or Skeletal Relationships					
New or Recall Patients	Child with Primary Dentition	Child with Mixed Dentition	Adolescent with Permanent Dentition	Adult Dentate Partially Dentate	Adult Edentulous
To Monitor Growth & Development or to Assess Dental or Skeletal Relationships	Clinical judgment for need & type of images for assessment type	Clinical judgment for need & type of images for assessment type	Clinical judgment for need & type of images for assessment type  Panoramic or periapicals for 3rd molars	Usually not indicated	Usually not indicated

#### **Child with Primary and Transitional Dentition**

Radiographic examination to assess growth and development of the child patient with a primary dentition prior to eruption of the first permanent tooth is not likely to be productive without identification of clinical signs or symptoms.<sup>1</sup> Any clinical findings that infer radiographic evaluation is needed should be determined on an individual basis. Following eruption of the first permanent tooth, a radiographic examination may be conducted for growth and development assessment. Usually it is not necessary to repeat such an examination unless subsequent clinical signs and symptoms are identified. Cephalometric imaging may be useful for growth and development evaluation or assessment of dental and skeletal relationships when indicated.

Clinical judgment should be used to determine the need and type of radiographic imaging to evaluate or monitor dentofacial growth and

development or assessment of dental and/or skeletal relationships for the child patient.

#### **Adolescents with Permanent Dentition**

There are several instances in which radiographic examination of the new or recall adolescent patient may be in order to assess growth and development or evaluate dental and skeletal relationships. These include the assessment of malocclusion which should be determined on an individual basis and/or evaluation of third molar teeth.<sup>1</sup> Third molar evaluation can be accomplished radiographically by selected periapical or panoramic imaging.

In summary, clinical judgment should be used to determine the need and type of radiographic imaging to evaluate or monitor dentofacial growth and development or assessment of dental and/or skeletal relationships for the adolescent patient. For the assessment of third molar teeth, panoramic or periapical radiography is indicated.

## Adult Dentate, Partially Edentulous or Edentulous Patient

No radiographic examination is indicated for adult patients for the purposes of growth and development unless indicated by clinical signs and symptoms suggestive of such abnormalities.<sup>1</sup>

## Patients with Other Circumstances

There are a variety of treatment needs that may warrant radiographic examination. Examples include, but are not limited to, implantology, restorative and/or endodontic treatment, dental or craniofacial anomalies/pathoses, treated periodontal disease and caries remineralization.<sup>1</sup> The type of imaging necessary in each circumstance will vary. Therefore, the dentist must use clinical judgment to determine the need and type of imaging that is best suited for the specific circumstance as indicated in the Table 6.

## Patient Scenarios

### Patient Scenario 1

An eight-year-old male patient, David, arrives for a new patient appointment accompanied by his mother. Review of the patient's dental and medical histories are noncontributory. Further discussion with David's mother indicates that the family lives outside the city limits and drinks non-fluoridated well water. It has

been a year or two since her son has seen a dentist due to a new employment opportunity and subsequent family relocation. David has had several new permanent teeth erupt. The mother reports that she had several missing permanent teeth as a child and wonders if her son has any missing permanent teeth. The clinical evaluation of David's oral cavity demonstrates evidence of poor oral hygiene, occlusal carious lesions in the 1st molar teeth, and marginal gingivitis.

- What positive historical findings were reported?
- What are the clinical signs & symptoms presented in this case?
- What are the risk factors for caries?
- Given the guidelines for a new child patient with a transitional dentition, what radiographic examination is recommended?

### Patient Scenario 1 Key

- What positive historical findings were reported?  
Family history of dental anomalies
- What are the clinical signs & symptoms presented in this case?  
Marginal gingivitis
- What are the risk factors for caries?  
Non-fluoridated water, poor oral hygiene, irregular dental care, clinical caries

**Table 6. Examination of Patients with Other Circumstances.<sup>1</sup>**

Recommendations for Patients with Other Circumstances					
All Patient Categories	Child with Primary Dentition	Child with Mixed Dentition	Adolescent with Permanent Dentition	Adult Dentate Partially Dentate	Adult Edentulous
With Other Circumstances	Clinical judgment for need & type of images for assessment or monitoring	Clinical judgment for need & type of images for assessment or monitoring	Clinical judgment for need & type of images for assessment or monitoring	Clinical judgment for need & type of images for assessment or monitoring	Clinical judgment for need & type of images for assessment or monitoring

- Given the guidelines for a new child patient with a transitional dentition, what radiographic examination is recommended? Posterior bitewings with panoramic examination or posterior bitewings and selected periapical images

### **Patient Scenario 2**

Monica, an 18-year-old female patient, arrives for her recall appointment. At her last recall visit one year ago, four bitewings were taken to evaluate for interproximal caries. No clinical or radiographic caries were found at that time and her periodontal status was good. Her chief complaint is discomfort and swelling behind the second molar teeth. The third molars are not erupted but she thinks they might be trying to come in. She is planning to attend an out-of-state college in a few months. Today your patient interview and oral examination reveal excellent general and oral health with the exception of inflammation and slight swelling in the third molar areas. No clinical carious lesions were found.

- What positive historical findings were reported?
- What are the clinical signs & symptoms presented in this case?
- What are the risk factors for caries?
- Given the guidelines for a recall adolescent patient with a permanent dentition, what radiographic examination is recommended?

### **Patient Scenario 2 Key**

- What positive historical findings were reported?  
No positive historical findings
- What are the clinical signs & symptoms presented in this case?  
Inflammation and slight swelling in third molar areas
- What are the risk factors for caries?  
Low caries risk - regular care, no radiographic caries found at last recall one year ago, no clinical caries
- Given the guidelines for a recall adolescent patient with a permanent dentition, what radiographic examination is recommended?  
Panoramic examination or 4 periapical image examination to evaluate third molars

### **Patient Scenario 3**

A 37-year-old male patient, Raphael, presents as a new adult patient. He has just acquired a new sales position with a local company. During the patient interview and review of his dental/medical history, he reports taking oral medication for diabetes mellitus. He states that it has been several years since his last medical or dental visit. The last dental treatment he received was for a root canal. His job requires a great deal of traveling by car and eating on the go. He is aware that he needs to eat better and brush his teeth more often. Observations from the clinical examination include fair oral hygiene, evidence of periodontitis with generalized mild and localized moderate bone loss, large amalgam restorations in first molar teeth, a crown on tooth 15 and deep occlusal lesions on teeth 12, 18, 29.

- What positive historical findings were reported?
- What are the clinical signs & symptoms presented in this case?
- What are the risk factors for caries?
- Given the guidelines for a new adult dentate patient, what radiographic examination is recommended?

### **Patient Scenario 3 Key**

- What positive historical findings were reported?  
Previous endodontic treatment
- What are the clinical signs & symptoms presented in this case?  
Clinical evidence of periodontal disease; large amalgam restorations in 3, 14, 19, 30; deep occlusal carious lesions on 12, 18, 29
- What are the risk factors for caries?  
Irregular dental care, fair oral hygiene, poor diet, clinical caries present
- Given the guidelines for a new adult dentate patient, what radiographic examination is recommended?  
Full mouth survey

## **Radiation Exposure Reduction**

### **Patient Dose Reduction**

It is well-established that x-radiation is detrimental and, when delivered with enough

intensity, a known carcinogen.<sup>4,5,25</sup> However, the degree of biologic effects from low-dose diagnostic imaging is less certain.<sup>4-6,28,29</sup> Therefore, it is prudent to keep patient exposure to ionizing radiation low, especially considering that the effects are cumulative.

Attending to the ALARA (As Low As Reasonably Achievable) Principle is the ethical and professional responsibility and obligation of dental health care providers. There are many ways to minimize radiation exposure to dental patients. First and foremost is the determination of whether, or not, a radiographic examination is indicated, and if so, what type and with what frequency. The previous discussion has addressed these questions.

There are several other methods that, collectively, can serve to minimize exposure to dental patients. These radiation dose reduction measures are outlined in Table 7.

#### **Image Receptors**

Digital receptors for intraoral and extraoral radiographic imaging including the charge-coupled device (CCD), complementary metal oxide semiconductor (CMOS) or photostimulable phosphor plate detectors. These devices can be used in place of traditional film to reduce radiation dose to patients. If film is used for intraoral radiographic imaging, F speed film should be used instead of D speed film to achieve

a greater dose reduction. For film-based panoramic or cephalometric extraoral radiography, rare-earth intensifying screens with matching high-speed film systems should be used.<sup>6</sup>

#### **Receptor Holders**

For intraoral imaging regardless of receptor type, a holding device is recommended to help facilitate placement and alignment of the collimated x-ray beam. Disposable bite blocks and/or bitewing tabs as well as heat-sterilizable bite blocks and instrument pieces are available. Dental professionals should not hold the receptor or patient during exposure. In unusual situations in which patient restraint is necessary, the parent, guardian or caregiver who is provided an appropriate protective shield, can restrain the patient or maintain the holder in position during exposure.<sup>6</sup>


#### **X-ray Beam Collimation**

X-ray beam collimation serves to limit the amount of primary and scatter radiation delivered to the patient during intraoral imaging. Rectangular collimation is preferred over round collimation because it reduces radiation dose to the patient significantly, approximately fivefold.<sup>6,30</sup> Receptor holding devices with rings have insets to facilitate rectangular collimation alignment. Several commercial devices are available to convert from round to rectangular collimation (Figure 7). In addition, rectangular collimation

**Table 7. Methods to Limit Patient Radiation Exposure.<sup>1</sup>**

- ✓ Limit the number of acquired images to the minimum necessary
- ✓ Use the fastest receptor compatible with the diagnostic task
- ✓ Use receptor holders designed to align the collimated beam for intraoral imaging
- ✓ Collimate the beam to the size of the receptor when possible
- ✓ Use protective aprons and thyroid collars as appropriate
- ✓ Use proper receptor exposure and processing (when applicable) techniques

has the added benefits of improving image geometry and reducing scatter radiation which degrades the resultant image.<sup>4</sup> This is especially applicable to intraoral digital receptors because they are more sensitive to scatter radiation than film.<sup>31</sup>



**Figure 7.** Rectangular Collimators.

### **Patient Shielding**

The thyroid gland, given its anatomic location, is often in the path of the x-ray beam during intraoral imaging. The thyroid is one of the most sensitive organs to radiation-induced tumors and is particularly sensitive in children.<sup>6</sup> A thyroid collar (Figure 8) should be used on all patients during intraoral radiography which significantly reduces exposure to the gland.



**Figure 8.** Thyroid collar.

An AAOMR report indicates that the gonadal dose from dental radiography is considered to be negligible such that the use of the lead apron can be considered optional unless

required by law.<sup>32</sup> The National Council on Radiation Protection and Measurements (NCRP) states that lap apron shielding is not necessary if all of the safety recommendations outlined in Report 177 are employed.<sup>6</sup> This recommendation includes the use of rectangular collimation of the primary beam which is less common than round collimation in dentistry.<sup>33,34</sup> Given that caveat, a lap apron should be used when the NCRP recommendations are not fully implemented.

When not in use, patient shields should be hung on hangers or other devices designed for proper storage or laid flat. Periodically, these devices should be inspected for damage and replaced as needed.<sup>6</sup>

### **Exposure and Processing Techniques**

The optimal operating kilovoltage range for intraoral x-ray machines is 60 to 70 kVp.<sup>6</sup> Consult the manufacturer's operating manual to determine the appropriate exposure time for each area of the mouth per the type of receptor being used to image the patient. Technique charts should be used to indicate proper exposure settings for intraoral and extraoral radiographic imaging systems with adjustable settings.<sup>1</sup> The clinician should make appropriate exposure adjustments when imaging children versus adult patients. X-ray machines should be evaluated regularly at intervals as mandated by state regulation.

If film-based imaging systems are used, it is important that optimal processing techniques are utilized to avoid retakes related to darkroom and/or processing issues. There are several quality assurance measures that can be utilized to test solution chemistry, darkroom conditions, film storage and cassette integrity to ensure that quality film-based images are produced.<sup>6,32</sup>

### **Operator Dose Reduction**

Radiographic examinations are typically delegated to qualified (as mandated by state law) auxiliary personnel; dental assistants and dental hygienists. Qualified dental radiation workers are to comply with annual occupational whole-body radiation dose limits (Table 8). Occupational radiation dosimeters

should be utilized by radiation workers who may receive an annual dose greater than 1 mSv and pregnant personnel operating x-ray equipment regardless of anticipated occupational exposure.<sup>1,6</sup>

Other methods to limit occupational exposure are listed in Table 9. Dental personnel should stand behind a protective barrier that permits observation of the patient during exposure. If a barrier is not present, the clinician should stand at a 6 feet/2 meters distance from the x-ray source and at a position greater than a right

angle (90-135° angle) to the primary beam. If a handheld x-ray unit is used for intraoral imaging, the device must be used according to the manufacturer's guidelines. The parameters of usage include:<sup>1</sup>

1. holding the unit at mid-torso height,
2. orienting the ring shield properly,
3. and keeping the position-indicating device (PID) as close to the patient as possible.
4. If the ring shield is not used during exposure, the operator should wear a lead apron.

**Table 8. Occupational Whole-Body Dose Limits.<sup>28</sup>**

Occupational Whole-Body Dose Limits		
Type	International Units	Traditional Units
Annual	50 mSv	5 rem
Embryo-fetus (term)	5 mSv	0.5 rem

**Table 9. Limiting Operator Radiation Exposure.<sup>1</sup>**

- ✓ Proper education, training and/or certification/licensure per State regulations
- ✓ Use of barrier protection techniques and/or distance and position rule during patient exposures
- ✓ Adherence to annual occupational radiation dose limits
- ✓ Use of personal dosimeters when indicated (operator annual dose > 1 mSv or if pregnant)
- ✓ If handheld x-rays units are used for intraoral imaging, adherence to manufacturer instructions for safe use

## Summary

The selection criteria guidelines were developed to promote the appropriate use of x-radiation when conducting radiographic examinations in dentistry. Radiographic examinations are important for the proper diagnosis and treatment of dental patients as well as to monitor dentofacial development and the progress or prognosis of therapy.<sup>1</sup> Prior to determining the need, type or frequency of a radiographic examination, the dentist should conduct a clinical examination, consider the patient's dental and medical histories, evaluate any signs and symptoms of oral disease and consider environmental

factors that may impact the patient's oral health. The dentist should only prescribe a radiographic examination when the expected additional diagnostic information will affect care.

The recommendations provided in the guidelines are based on research from the published scientific literature and take into consideration risk factors that may impact the incidence of oral disease at various life stages. In addition, methods to minimize exposure to both patients and dental radiation workers are necessary to facilitate adherence to the ALARA Principle.

## Course Test Preview

To receive Continuing Education credit for this course, you must complete the online test. Please go to: [www.dentalcare.com/en-us/ce-courses/ce584/test](http://www.dentalcare.com/en-us/ce-courses/ce584/test)

- 1. The prescription of the need, type and frequency of a radiographic examination should be determined by the \_\_\_\_\_.**
  - A. Dental assistant
  - B. Dental hygienist
  - C. Office manager
  - D. Dentist
- 2. Each of the following is necessary to complete prior to prescription of a radiographic examination EXCEPT one. Which is the exception?**
  - A. Determine if insurance will cover the survey
  - B. Clinical examination of the patient's oral cavity
  - C. Review of the patient's dental and medical health history
  - D. Consideration of risk factors that impact vulnerability to oral disease
- 3. Which selection is an example of a positive clinical sign or symptom?**
  - A. Previous endodontic treatment
  - B. Presence of dental implants
  - C. Unusual migration of teeth
  - D. History of facial trauma
- 4. Which type of radiographic examination is not addressed in the current guidelines?**
  - A. Cone beam CT
  - B. Selected periapical images
  - C. Bitewing radiography
  - D. Cephalometric imaging
- 5. Legal consent requires each of the following EXCEPT one. Which is the exception?**
  - A. The patient is provided information about treatment options.
  - B. Involuntarily patient consent to treatment.
  - C. Likely treatment outcomes are explained.
  - D. The patient is capable of choice.
- 6. If no radiographs are recommended for the new child patient with a primary dentition, what would be the basis for that decision?**
  - A. Patient in subgroup with high caries rate.
  - B. Open contacts allowed visual inspection.
  - C. Risk factors for caries were identified.
  - D. Clinical carious lesions were detected.
- 7. For the new adolescent patient, what evidence would suggest that a full mouth radiographic examination is indicated?**
  - A. Oral disease is present throughout the mouth.
  - B. Daily oral hygiene self-care habits are good.
  - C. Sealants are present in the molar teeth.
  - D. Periodontium appears to be healthy.

8. **The radiographic imaging prescription for the new adult edentulous patient should be determined by \_\_\_\_\_.**
- A. identification of caries risk factors
  - B. conducting a screening radiographic exam
  - C. growth and development assessment needs
  - D. the presence of clinical signs and symptoms
9. **The only time-based type of radiographic examination recommended in the guidelines is \_\_\_\_\_.**
- A. panoramic radiography
  - B. selected periapical imaging
  - C. posterior bitewing imaging
  - D. full mouth radiographic survey
10. **What is the recommended bitewing interval for the recall patient with a transitional dentition who presents with clinical caries?**
- A. 3 to 6 months
  - B. 6 to 12 months
  - C. 12 to 24 months
  - D. 18 to 36 months
11. **What type of radiographic examination is recommended for the recall adult dentate patient at low risk for caries?**
- A. Occlusal projections
  - B. Selected periapicals
  - C. Posterior bitewings
  - D. Panoramic image
12. **For the recall patient with evidence of localized areas of active periodontal disease, the most likely recommended radiographic examination would be \_\_\_\_\_.**
- A. selected periapicals and/or bitewings
  - B. full mouth periapical and bitewing survey
  - C. cone beam computed tomographic examination
  - D. combined occlusal and panoramic radiographic imaging
13. **Which radiographic survey would be indicated to assess growth and development of the third molar teeth in the new or recall adolescent patient?**
- A. Cephalometric imaging
  - B. Panoramic radiography
  - C. Occlusal radiography
  - D. Posterior bitewings
14. **What is the primary basis to determine the appropriate radiographic examination to evaluate the need and type of imaging to assess dental and skeletal relationships?**
- A. Absence of signs and symptoms
  - B. Active periodontal disease
  - C. Caries risk factors
  - D. Clinical judgment

- 15. Review and consider patient scenario 1. Each of the following indicators suggest that David is at an increased risk of caries EXCEPT one. Which is the exception?**
- A. Familial history of missing permanent teeth
  - B. Drinks non-fluoridated well water
  - C. Poor oral hygiene was observed
  - D. Clinical evidence of caries
- 16. Review and consider patient scenario 3. Which radiographic examination is recommended given the patient information presented in this case?**
- A. Survey determined by clinical judgment
  - B. Posterior bitewings and a panoramic
  - C. Selected periapicals and bitewings
  - D. Full mouth radiographic survey
- 17. The primary reason rectangular x-ray beam collimation is recommended for intraoral imaging is because it\_\_\_\_\_.**
- A. significantly reduces exposure to the patient
  - B. produces more scatter or secondary radiation
  - C. can be used with either film or digital receptors
  - D. results in fewer image errors and fewer retakes
- 18. Which patient safety measure should be employed regardless of age or gender for intraoral radiographic procedures?**
- A. D speed film
  - B. Wall barrier
  - C. Thyroid collar
  - D. 90 kVp setting
- 19. The use of personal dosimeter monitoring is indicated if the radiation worker \_\_\_\_\_.**
- A. Is pregnant
  - B. Practices safety rules
  - C. Receives < 1 mSv annually
  - D. Is in the offices 5 days/week
- 20. What is the annual dose limit for occupational whole-body radiation exposure?**
- A. 5 mSv
  - B. 10 mSv
  - C. 25 mSv
  - D. 50 mSv

## References

1. ADA Council on Scientific Affairs, FDA. Dental radiographic examinations: Recommendations for patient selection and limiting radiation exposure. Rev. 2012. Accessed January 27, 2020.
2. Joseph LP. The Selection of Patients for X-ray Examinations: Dental Radiographic Examinations. Rockville, Md.: U.S. Department of Health and Humans Services, Center for Devices and Radiological Health. 1987. HHS Publication No. FDA 88-8273.
3. ADA Council on Scientific Affairs, FDA. The selection of patients for x-ray examinations. Rev. 2004 Accessed January 27, 2020.
4. White SC, Pharoah MJ. Oral radiology : principles and interpretation, 7th ed. St. Louis, Mo. Mosby/Elsevier. 2014.
5. White SC, Mallya SM. Update on the biological effects of ionizing radiation, relative dose factors and radiation hygiene. Aust Dent J. 2012;57 Suppl 1:2–8. doi:10.1111/j.1834-7819.2011.01665.x.
6. National Council on Radiation Protection and Measurements. Radiation protection in dentistry and oral & maxillofacial imaging. NCRP Report No. 177, Bethesda, MD. 2019 Dec 19.
7. Carter L, Farman AG, et al. American Academy of Oral and Maxillofacial Radiology executive opinion statement on performing and interpreting diagnostic cone beam computed tomography. Oral Surg Oral Med Oral Pathol Oral Radiol Endod. 2008;106(4):561–562. doi:10.1016/j.tripleo.2008.07.007.
8. Tyndall DA, Price JB, Tetradis S, et al. Position statement of the American Academy of Oral and Maxillofacial Radiology on selection criteria for the use of radiology in dental implantology with emphasis on cone beam computed tomography. Oral Surg Oral Med Oral Pathol Oral Radiol. 2012;113(6):817–826. doi:10.1016/j.oooo.2012.03.005.
9. American Academy of Oral and Maxillofacial Radiology. Clinical recommendations regarding use of cone beam computed tomography in orthodontics. [corrected]. Position statement by the American Academy of Oral and Maxillofacial Radiology [published correction appears in Oral Surg Oral Med Oral Pathol Oral Radiol. 2013 Nov;116(5):661]. Oral Surg Oral Med Oral Pathol Oral Radiol. 2013;116(2):238–257. doi:10.1016/j.oooo.2013.06.002.
10. Special Committee to Revise the Joint AAE/AAOMR Position Statement on use of CBCT in Endodontics. AAE and AAOMR Joint Position Statement: Use of Cone Beam Computed Tomography in Endodontics 2015 Update. Oral Surg Oral Med Oral Pathol Oral Radiol. 2015;120(4):508–512. doi:10.1016/j.oooo.2015.07.033.
11. American Dental Association Council on Scientific Affairs. The use of cone-beam computed tomography in dentistry: an advisory statement from the American Dental Association Council on Scientific Affairs. J Am Dent Assoc. 2012;143(8):899–902. doi:10.14219/jada.archive.2012.0295.
12. ADA Council on Ethics, Bylaws and Judicial Affairs. Principles of ethics and code of professional conduct with official advisory opinions revised to November 2018. Accessed January 27, 2020.
13. Ozar DT, Sokol DJ. Dental ethics at chairside : professional principles and practical applications, 2nd ed. Washington, DC. Georgetown University Press. 2002.
14. American Academy of Oral & Maxillofacial Radiology. About Dental X-rays. Accessed January 27, 2020.
15. Ludlow JB, Davies-Ludlow LE, White SC. Patient risk related to common dental radiographic examinations: the impact of 2007 International Commission on Radiological Protection recommendations regarding dose calculation. J Am Dent Assoc. 2008;139(9):1237–1243. doi:10.14219/jada.archive.2008.0339.
16. The Image Gently Alliance. What Parents Should Know about the Safety of Dental Radiology. Accessed January 27, 2020.
17. American Academy of Pediatric Dentistry. Ad Hoc Committee on Pedodontic Radiology. Guideline on prescribing dental radiographs for infants, children, adolescents, and persons with special health care needs. Pediatr Dent. 2012;34(5):189–191.
18. CDC. Children's Oral Health. 2019 May 14. Accessed January 27, 2020.
19. CDC. Disparities in Oral Health. 2016 May 17. Accessed January 27, 2020.

20. Ritter AV, Shugars DA, Bader JD. Root caries risk indicators: a systematic review of risk models. *Community Dent Oral Epidemiol*. 2010;38(5):383–397. doi:10.1111/j.1600-0528.2010.00551.x.
21. Hugoson A, Sjödin B, Norderyd O. Trends over 30 years, 1973–2003, in the prevalence and severity of periodontal disease. *J Clin Periodontol*. 2008;35(5):405–414. doi:10.1111/j.1600-051X.2008.01225.x.
22. Rushton VE, Horner K, Worthington HV. Routine panoramic radiography of new adult patients in general dental practice: relevance of diagnostic yield to treatment and identification of radiographic selection criteria. *Oral Surg Oral Med Oral Pathol Oral Radiol Endod*. 2002;93(4):488–495. doi:10.1067/moe.2002.121994.
23. Masood F, Robinson W, Beavers KS, et al. Findings from panoramic radiographs of the edentulous population and review of the literature. *Quintessence Int*. 2007;38(6):e298–e305.
24. Bohay RN, Stephens RG, Kogon SL. A study of the impact of screening or selective radiography on the treatment and postdelivery outcome for edentulous patients. *Oral Surg Oral Med Oral Pathol Oral Radiol Endod*. 1998;86(3):353–359. doi:10.1016/s1079-2104(98)90185-8.
25. ADA. Caries Risk Assessment and Management. 2018 Dec 14. Accessed January 27, 2020.
26. ADA. Caries Risk Assessment Form (Age 0-6). 2011. Accessed January 27, 2020.
27. ADA. Caries Risk Assessment Form (Age >6). 2011. Accessed January 27, 2020.
28. Bushong SC. Radiologic science for technologists: Physics, biology, and protection, 10th ed. St. Louis, MO. Elsevier-Mosby. 2013.
29. Scarfe WC. Radiation risk in low-dose maxillofacial radiography. *Oral Surg Oral Med Oral Pathol Oral Radiol*. 2012;114(3):277–280. doi:10.1016/j.oooo.2012.07.001.
30. Gibbs SJ. Effective dose equivalent and effective dose: comparison for common projections in oral and maxillofacial radiology. *Oral Surg Oral Med Oral Pathol Oral Radiol Endod*. 2000;90(4):538–545. doi:10.1067/moe.2000.109189.
31. Parks ET, Williamson GF. Digital radiography: an overview. *J Contemp Dent Pract*. 2002;3(4):23–39. Published 2002 Nov 15.
32. White SC, Heslop EW, Hollender LG, et al. Parameters of radiologic care: An official report of the American Academy of Oral and Maxillofacial Radiology. *Oral Surg Oral Med Oral Pathol Oral Radiol Endod*. 2001;91(5):498–511. doi:10.1067/moe.2001.114380.
33. Nakfoor CA, Brooks SL. Compliance of Michigan dentists with radiographic safety recommendations. *Oral Surg Oral Med Oral Pathol*. 1992;73(4):510–513. doi:10.1016/0030-4220(92)90335-n.
34. Bohay RN, Kogon SL, Stephens RG. A survey of radiographic techniques and equipment used by a sample of general dental practitioners. *Oral Surg Oral Med Oral Pathol*. 1994;78(6):806–810. doi:10.1016/0030-4220(94)90100-7.

### Additional Resources

- National Council on Radiation Protection and Measurements. Radiation protection in dentistry and oral & maxillofacial imaging. NCRP Report No. 177, Bethesda, MD. 2019 Dec 19.

## About the Author



### **Gail F. Williamson, Professor Emerita**

Gail F. Williamson is Professor Emerita of Dental Diagnostic Sciences, Department of Oral Pathology, Medicine and Radiology at Indiana University School of Dentistry in Indianapolis, Indiana. Prof. Williamson has received numerous awards for teaching excellence during her academic career including the 2013 Outstanding Teacher of the Year Award from the Indiana University School of Dentistry and the 2018 Gordon J. Christensen Lecturer Recognition Award from the Chicago Dental Society. She is a co-author of several Radiology textbooks and author/co-author of multiple book chapters, journal articles and continuing education monographs. She has held numerous positions in several professional organizations including the American Academy of Oral and Maxillofacial Radiology and the American Dental Education Association. She presents continuing education courses on topics in oral and maxillofacial radiology nationally.

Email: [gwilliam@iu.edu](mailto:gwilliam@iu.edu)