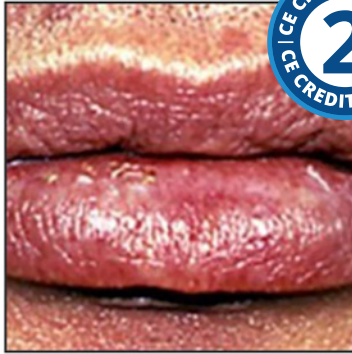

Actinic Cheilosis: Etiology, Epidemiology, Clinical Manifestations, Diagnosis, and Treatment



Course Author(s): Michael A. Huber, DDS, David Leonard Ojeda Diaz, DDS

CE Credits: 2 hours

Intended Audience: Dentists, Dental Hygienists, Dental Assistants, Dental Students, Dental Hygiene Students, Dental Assistant Students

Date Course Online: 05/11/2012

Last Revision Date: 02/10/2025

Course Expiration Date: 02/09/2028

Cost: Free

Method: Self-instructional

AGD Subject Code(s): 730

Online Course: www.dentalcare.com/en-us/ce-courses/ce400

Disclaimers:

- P&G is providing these resource materials to dental professionals. We do not own this content nor are we responsible for any material herein.
- Participants must always be aware of the hazards of using limited knowledge in integrating new techniques or procedures into their practice. Only sound evidence-based dentistry should be used in patient therapy.

Conflict of Interest Disclosure Statement

- Dr. Huber is a member of the dentalcare.com Advisory Board.
- Dr. Ojeda Díaz reports no conflicts of interest associated with this course.

Introduction – Actinic Cheilosis

This continuing education course presents the etiology, epidemiology, clinical manifestations, diagnosis, and treatment of actinic cheilosis.

Course Contents

- Overview
- Learning Objectives
- Introduction
- Etiology and Epidemiology
- Clinical Manifestations
- Diagnosis
- Prevention
- Therapeutic Strategies
- Conclusion
- Course Test
- References
- About the Author

Overview

Actinic cheilosis is a chronic degenerative disorder primarily of the lower lip caused by long-term exposure to sunlight. It is premalignant and usually occurs in fair-skinned men over 40 years of age. Reducing exposure to sunlight is the single most important measure in preventing actinic cheilosis. Diagnosis is predicated on histological examination of biopsy specimens. Topical chemotherapy may be used in early lesions. Prophylactic ablation or vermilionectomy may be performed in cases where malignant transformation has not yet occurred. The treatment of malignancy is primarily surgical.

Learning Objectives

Upon completion of this course, the dental professional should be able to:

- Discuss the etiology and epidemiology of solar cheilosis.
- Recognize the clinical manifestations of solar cheilosis.
- Diagnose solar cheilosis.
- Develop preventive and treatment management strategies for patients with solar cheilosis.

Introduction

Exposure to sunlight leads to the development of sunburn, premature aging of the skin, cataracts, immune suppression, and skin cancer. Actinic keratosis (AK) of the skin represents an early stage of a continuum that may ultimately progress to squamous cell carcinoma (SCC). Actinic cheilosis (AC) is the labial equivalent of AK. The term actinic cheilitis is often used; however, actinic or solar cheilosis is more accurate because this sun-

induced neoplastic disease is primarily non-inflammatory.¹

The lip vermilion exists only in man and is bounded by the keratinized skin and mucous membrane of the inner labia.² The epidermis is characterized by a highly developed stratum lucidum and a very thin stratum corneum. Hair and sweat glands are absent but dermal papillae are abundant, leading to the rich vascular supply that imparts the characteristic red color (vermilion). In dark-complected individuals, the red hue is camouflaged by increased melanin deposits.³

AC is a precancerous condition found primarily on the lower lip of light-skinned individuals. Given the high risk for the progression of AC to SCC of the lip vermilion and the high rate of discordance between clinical and histologic findings, a biopsy is indicated in the presence of clinically discernable degenerative changes.¹ Prevention, early diagnosis, effective therapeutic intervention, and close long-term follow-up are paramount.

Etiology and Epidemiology

The etiologic factors associated with AC are the same as those associated with AK and cutaneous SCC, namely the cumulative effect of exposure to ultraviolet radiation (UVR), skin phenotype, genetic predisposition, increasing age, male gender, outdoor occupation and leisure activities, geographic latitude of residence, failure to use lip-protective agents, and host immune status.^{1,4} The risk associated with smoking, alcohol consumption, and poor oral hygiene is unclear.¹

Chronic exposure to UVR is the most important cause of AC.^{1,5-10} UVR is generally divided into 3 categories: UV-A (wavelength 315-400 nm), UV-B (wavelength 280-315 nm), and UVC (wavelength 100-280 nm). The atmosphere efficiently filters out most UVR and only about 5% of solar radiation reaches the earth's surface (96.65% UV-A, 3.35% UV-B, insignificant UV-C).⁸ UV-B radiation reaches the epidermal cell layer to induce very specific mutational changes which serve to both initiate and promote dysplastic changes in the epidermis. UV-B radiation is principally responsible for carcinogenic risk, but UV-A radiation penetrates

to reach the underlying dermis to also contribute to the risk.^{7,8,11,12} AK and AC serve as clinical dose-meters for chronic UVR exposure.¹³

UV-B directly damages the DNA at adjacent pyrimidines resulting in double cytosine (CC) to double thymidine transition mutations.^{6,8,14} This mutation is so specific that it is referred to as the “UV signature” or “UV fingerprint.”^{6,14-16} The characteristic UV-B mutations target tumor suppressor genes, the most notable being p53.^{8,10,11,17} Normal p53 acts to allow repair of damaged DNA or induce apoptosis (controlled cell death) when the DNA damage is nonrepairable.^{6,8,11,16}

UVR-induced mutations to the p53 gene lead to impaired tumor suppressor activity. Other UVR-induced molecular alterations affect the normal activity of cyclooxygenases, signal transducer and activator of transcription proteins, fibroblast growth factor, cytokeratin, and cytotoxic killer cells.¹ While these effects contribute to the molecular evolution of AC to SCC, their reliability as clinical markers with predictive or staging value remains unclear.^{1,11}

Since AC occurs more frequently in light-complected than darker-complected individuals, skin phenotype (Table 1) is an important predisposing factor determining the risk for AC.^{4,8,12,13,18,19} The increased melanin in the lip vermilion of dark-complected individuals appears to provide increased protection from the harmful effects of UVR.^{4,11} It is of note that SCC of the lower lip occurs 30 times more frequently in white than in black individuals.⁴

Table 1. Skin Phenotypes.¹⁸

Skin type I: burns easily, never tans
Skin type II: burns easily, tans minimally
Skin type III: burns moderately, tans gradually
Skin type IV: burns minimally, tans well
Skin type V: rarely burns, tans profusely
Skin type VI: deeply pigmented, never burns

Individuals whose poor sun exposure habits began early in life are at greatest risk for developing AC.^{13,20} Lip cancer is most frequently diagnosed among people aged 65–74 and men are afflicted more frequently than women.²¹ It has been postulated that women are at lesser risk because they experience less chronic sun exposure and are more likely to use a lip protective agent such as lipstick or sunblock.¹

While the association between tobacco use and AC is unclear, the habit of leaving a cigarette on the lip has been reported to increase the risk of labial SCC.^{10,22} Immune competency, specifically scenarios of immunosuppression, appears to profoundly increase the risk of developing AC and SCC of the lip.²²⁻²⁶

The true incidence of AC is unknown; however, the likelihood that AC will progress to SCC of the lip vermilion is 2.5 times higher than the risk of AK progressing to cutaneous SCC.²⁷⁻²⁸ SCC of the lip tends to be more severe in those patients who develop AC at a younger age and in those with severe clinical and histologic evidence of inflammatory infiltrates at the time of diagnosis.¹ The progression of AC to SCC of the lip may take 2 to 3 decades.²⁹

The incidence of SCC of the lip in the United States has declined from 2.8 per 100,000 in 1975 to stabilize at 0.7 per 100,000 in 2008.²¹ The 5 years survival rate for lip cancer is 90.3%. It should be noted, that approximately 15% of the patients with SCC of the lower lip will develop a second primary on the lip vermilion.^{28,30}

Clinical Manifestations

UVR-induced damage to the lip may be acute, resulting in sunburn, blistering or peeling; chronic exposure leads to AC, primarily of the lower lip.^{1,2,12,21,22,31} In its early stages, AC presents as a dry, scaly unobtrusive “chapped lip.” Palpation provides a sense of rubbing the fingers over sandpaper.³² At later stages small nodules; marked parallel fissuring; mottled, opalescent white or gray plaques; erosion or ulceration along with crusting; as well as loss of definition of the lip vermilion are noted.^{1,32-34}

The clinical appearance of AC does not always correlate directly with underlying histological

changes and an apparently suspicious lesion may prove to be benign, while a perceived benign lesion may in fact represent severe dysplasia or even SCC.¹ Waxing and waning of erythematous or ulcerative areas with evidence of induration and pain are ominous signs.^{35,36} Figures 1-8 document the progression of labial UVR damage from acute sunburn to primary and recurrent invasive SCC.

Diagnosis

The working diagnosis of AC is usually straightforward. It evolves from correlating a thoroughly discerned history with clinical findings in an at-risk patient. The presence of concurrent AK on sun-exposed areas (face, neck, bald scalp, ears) reinforces the clinical impression. Several other conditions affecting the lip may mimic AC and should be considered in the differential diagnosis. Table 2 provides a comprehensive list of differential diagnoses and associated characteristics.^{2,3,36-50}

Because of the progressive nature of AC, the presence of a chronic lesion on the lip vermilion mandates a biopsy.¹ The spectrum of histological findings associated with clinical AC include hyperkeratosis, parakeratosis/orthokeratosis, epithelial atrophy, vasodilation, inflammatory infiltrates, solar elastosis, atypia, dysplasia, SCC-in-situ (SCIS) and invasive SCC.^{1,7,33,35,36,51-59} In one study, 10% of the patients had mild, 28% had moderate, and 62% had severe biopsy-proven dysplasia.³⁴

Prevention

Given the strong etiologic link between UVR and AC, reducing exposure to sunlight or other forms of UVR is the single most important measure in preventing AC.⁶⁰ General protection guidelines published by the American Cancer Society include avoiding sun exposure when UV rays are strongest (between 10 AM and 4 PM); wearing protective clothing; wearing a hat that shades the neck, face and ears; wearing sunglasses that block UV rays; and properly (liberally) using a broad spectrum sunscreen with a sun protection factor (SPF) of 30 or higher.⁶¹

The SPF of a sunscreen product is determined using a calibrated artificial UV radiation source to induce minimal erythema on skin protected by the application of 2 mg/cm² of the test sunscreen.⁶² SPF is the ratio of UV radiation dose required to induce minimal erythema on protected skin versus the dose required to induce the same degree of erythema on unprotected skin.^{62,63} UV-B radiation is 1,000 - 10,000 times more carcinogenic than UV-A radiation.^{64,65}

Sunscreens are divided into two types: inorganic and organic and there are currently 17 agents approved for use in the United States.⁷ Inorganic sunscreens contain zinc or titanium dioxide and act to physically block, reflect, or scatter UV radiation.^{7,66} Organic agents have variable absorptive spectra and sunscreen manufacturers typically combine several agents to produce a broad spectrum product capable of blocking both UV-A and UV-B.^{7,64,67} Table 3 lists selected FDA-accepted sunscreen agents, their allowable concentrations, and their UVR spectrum.

For the prevention of AC, the product chosen should be formulated for use on the lip and provide broad-spectrum protection against both UV-B and UV-A radiation.^{7,66,67} Table 4 lists some commercially available broad-spectrum lip sunscreens/sunblocks. As product lines and formulations are subject to change, clinicians and consumers should always check the product label. If a lip balm is not available, a broad-spectrum liquid or gel sunscreen applied to the lips may prove effective.⁶⁷

Regardless of the product chosen, sunscreens should be applied liberally 15-30 minutes prior to exposure to UVR.^{61,66} They should be reapplied liberally after any vigorous activity that may wash or rub away the product.^{61,68} Finally, and perhaps more importantly, the patient should be educated that the purpose of sunscreens is to provide protection against UV radiation when one needs to be outside, but that the ultimate goal of prevention is to reduce elective sun exposure.

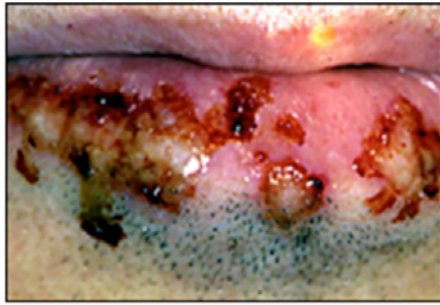

Figure 1. Blistering secondary to acute exposure to UVR.

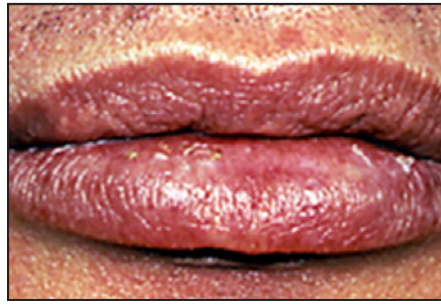

Figure 2. Solar cheilosis presenting as a dry, scaly, unobtrusive "chapped lip."

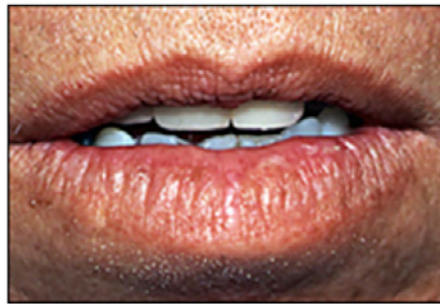

Figure 3. Solar cheilosis characterized by marked parallel folds and loss of elasticity.

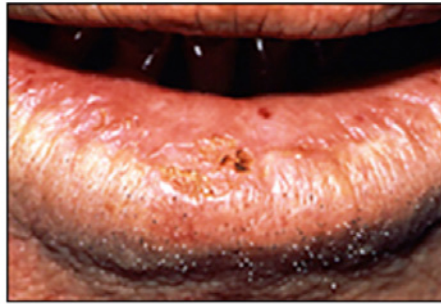

Figure 4. Isolated areas of crusting and loss of definition of the vermilion border - biopsy-proven moderate dysplasia.

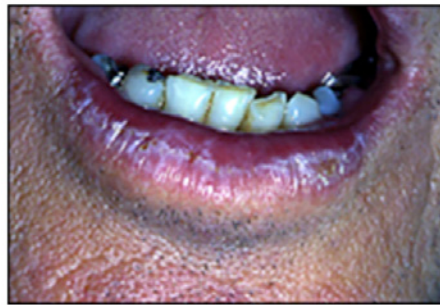

Figure 5. White/gray opalescent plaques of the vermilion - biopsy proven severe dysplasia.

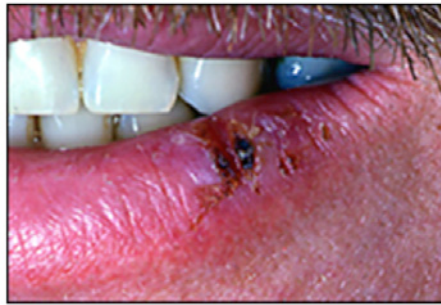

Figure 6. Waxing and waning erythematous ulceration with induration - biopsy-proven carcinoma-in-situ.

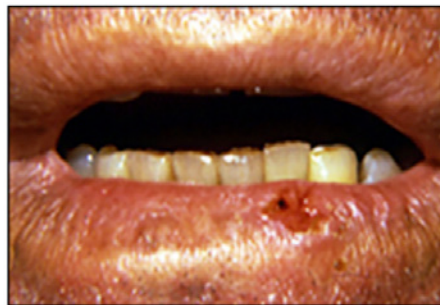

Figure 7. Persistent ulceration with induration and recent onset of pain - biopsy-proven invasive SCC.

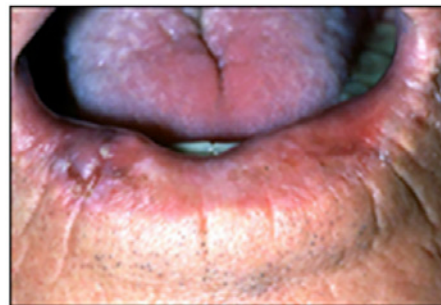

Figure 8. Biopsy-proven recurrent SCC with ulceration and induration 10 years after excision of primary SCC.

Table 2. Differential Diagnoses Associated with Actinic Cheilosis.

Condition	Characteristics
Chronic cheek biting/chewing	Factitial shaggy lesions are commonly observed on buccal mucosa, lateral tongue, lips. Historical clues and direct observation for habit.
Exfoliative cheilitis ^{2,3}	Unusual condition, typically affects young women, often attributed to factitial self-induced trauma. Hyperkeratosis and desquamation are limited to lip vermillion, possible yellow hyperkeratotic or thick hemorrhagic crusts, no underlying physiologic disorder noted. Proposed psychogenic cause.
Contact dermatitis ^{2,3}	Any age involved, scaling and erythema may be limited to lip vermillion, both upper and lower lips typically involved. Careful history necessary to elucidate possible causes. Irritant - Extremes of dry, cold, windy, hot, humid may lead to sloughing. Allergic - Possible causes include toothpaste (flavorings, preservatives), tartar control toothpastes (pyrophosphate compounds) and lipsticks and lip balms (oxybenzone, lanolin, preservatives). Phototoxic - Numerous medications (tetracyclines, sulfamethoxazole, chlorothiazide, bupropion, ibuprofen, diuretics, many others). Psoralens in citrus fruits may react with UV light to induce cheilitis.
Lichen planus ^{37,38}	Common mucocutaneous disorder, female predominance, 4th - 6th decade, may wax and wane, variable discomfort. Characteristic lacy striations, papules, plaques. Histological : Dense subepithelial band-like infiltrate of T-cells, basal cell layer liquefaction, disruption of the basement membrane.
Lichenoid drug reaction ³⁹	Clinical appearance is indistinguishable from LP. Careful historical analysis is necessary necessary to determine inciting drug. Diagnosis validated by lesion resolution after discontinuance of suspected agent (and reappearance on reexposure to inciting agent). Histological : Essentially identical to LP.
Candidiasis (angular cheilitis)	Most typically noted at commissures, mixed red/white lesions with ulceration or crusts. White curds or plaques that wipe off leaving an erythematous base. Histological : Evidence of candidal hyphae and spores noted on specimen (smears, tissue biopsy).
Cheilitis glandularis ^{40,41}	Rare, chronic inflammatory conditions manifesting minor salivary gland hypersecretion and ductal ectasia. Lips are swollen, nodular, and everted and associated minor salivary gland secretion is thick and sticky. The cause is unknown. Histological : Nonspecific with possible glandular hyperplasia and ductal ectasia.
Erythema multiforme ^{42,43}	Characteristic abrupt onset with pain. Most common in adolescents/young adults and frequently associated with prior HSV outbreak. Variable oral presentation with intraoral bullae and erosions, often with crusting lesions on lips and cutaneous target lesions. Histological : Nonspecific evidence of inflammation; immunofluorescent staining for perivascular IgM, IgG, C3 may be noted, but are nonspecific.
Pemphigus vulgaris ^{44,45}	Median age of onset 50+ with slight female predominance. Oral lesions (blisters, erosions, and ulcers) occur in over 85% of cases and often precede occurrence of cutaneous lesions. Typical sites affected are buccal mucosa, tongue, floor of mouth, and palate. Histological : Suprabasilar splitting and clefting. Characteristic immunofluorescent staining of intercellular deposits of IgG and C3 throughout the epithelium.
Discoid lupus erythematosus ⁴⁶	Five- 20% of cases progress to SLE. Positive ANA titers are unusual. Typical oral lesions presents as a red atrophic center with peripheral border of radiating hyperkeratotic striae. Histological : Granular or homogenous bands of immunoglobulin (IgG and IgA) in the BMZ
Graft Versus Host Disease ⁴⁷	History of allogeneic stem cell transplantation. Clinical appearance is similar to LP. Frequent involvement of salivary gland tissues leads to xerostomia. Histological : Virtually identical to LP
Systemic lupus erythematosus ⁴⁶	Oral lesions are often painless and occur in about 19% of cases. Positive ANA titers in 95% - 100% of cases. Variable oral presentation (discoid, plaques, ulcers, lichen planus-like lesions). Histological : Granular or homogenous bands of immunoglobulin (IgG and IgA) in the BMZ
Plasma cell cheilitis ⁴⁸	Rare inflammatory disorder manifesting glistening red lower lip, fissuring, ulceration, tenderness. Histological : Band-like infiltrate of plasma cells in upper dermis
Cheilitis granulomatosa (Miescher's cheilitis) ^{49,50}	Rare idiopathic condition manifesting episodic nontender enlargement of one or both lips. Lips may feel soft, firm or nodular. Onset typical in young adults with no racial or gender predilection. Many consider it a monosymptomatic form of Melkerson-Rosenthal syndrome. Histological : Lymphedema and noncaseating granulomas noted in lamina propria.

Table 3. Some FDA Accepted Sunscreen Agents.^{7,67}

Ingredient	Maximum FDA approved % Concentration	Maximum (nm) Absorption	UV Coverage Spectrum
Inorganic UV filters			
Zinc Oxide	25	Variable *	UV-B, UV-A
Titanium dioxide	25	Variable *	UV-B, UV-A
Organic UV filters			
Aminobenzoates			
para-Aminobenzoic acid	15	283	UV-B
Padimate O (octyl dimethyl PABA)	8	311	UV-B
Cinnamates			
Cinoxate (2-ethoxyethyl p-methoxycinnamate)	3	289	UV-B
Octinoxate (octyl methoxycinnamate)	7.5	311	UV-B
Salicylates			
Trolamine salicylate ** (triethanolamine salicylate)	12	260-355	UV-B
Homosalate (homomenthyl salicylate)	15	306	UV-B
Octisalate (octyl salicylate)	5	307	UV-B
Others			
Octocrylene (2-ethylhexyl 2-cyano-3, 3- diphenylacrylate)	10	303	UV-B, UV-A
Ensulizole (phenylbenzimidazole sulfonic acid)	4	310	UV-B
Benzophenones			
Oxybenzone (benzophenone-3)	6	288, 325	UV-B, UV-A
Dioxybenzone (benzophenone-8)	3	352	UV-B, UV-A
Sulisobenzene (benzophenone-4)	10	366	UV-B, UV-A
Dibenzoylmethanes			
Avobenzene (butyl methoxydibenzoylmethane, Parsol 1789)	3	360	UV-B, UV-A
Anthralates			
Meradimate (menthyl anthranilate)	5	340	UV-A
Camphors			
Ecamsule (terephthalylidene dicamphor sulfonic acid, Mexoryl SX)	3	345	UV-B, UV-A
* Spectral absorption depends of particle size.			
** Exhibits both inorganic and organic blocking properties.			

Table 4. Some Commercially Available Lip Balms.⁶⁸

Product	Manufacturer	SPF
Sun Bum Mineral Sunscreen Lip Balm	Sun Bum	30
Jack Black Intense Therapy Lip Balm	Jack Black	25
eItaMD UV Lip Balm	CP Skin Health Group	36
Cay Skin Isle Lip Balm SPF 30	Cay Skin	30
Coppertone SPORT Sunscreen Lip Balm	Coppertone	50
Neutrogena Revitalizing Lip Balm	Neutrogena	20
MDSolarSciences Hydrating Sheer Tinted Lip Balm SPF 30	MDSolarSciences	30
Blistex Five Star Lip Protection	Blistex	30
Banana Boat Ultra Sport Sunscreen Lip Balm	Banana Boat	50
Supergoop! PLAY Lip Balm SPF 30	Supergoop!	30
Aquaphor Lip Protectant Plus Sunscreen SPF 30	Aquaphor	30
Vacation Chardonnay Lip Oil SPF 30	Vacation	30
Burt's Bees All Weather SPF 15 Lip Balm	Burt's Bees	15
Nivea Smoothness Broad Spectrum SPF 15 Lip Care	Nivea	15
Coola Organic Liplux Lip Balm and Sunscreen	Natural Beauty Group	30
Banana Boat Sunscreen Lip Balm with Aloe Vera	Banana Boat	15

Therapeutic Strategies

The progressive nature of AC emphasizes the need for (1) prevention, (2) early diagnosis, (3) effective therapeutic intervention, and (4) close long-term follow-up. Measures to reduce UVR exposure and the consistent use of a sunscreen may occasionally result in spontaneous resolution of AC.^{15,66} Available therapeutic options include the application of topical chemicals and the use of ablative or surgical methods.^{36,69}

Importantly, clinicians must avoid treating AC on the basis of clinical findings alone.

When AC presents as a well-circumscribed nodule or papule < 5 mm in diameter it is amenable to an excisional biopsy.³⁶ Serial sections of the surgical specimen must be prepared and evaluated histologically. Alternatively, Mohs micrographic surgery (MMS), because of its excellent cosmetic yield,

may be considered. If the histologic diagnosis confirms mild to moderate dysplasia no further treatment is indicated, but the patient should be placed in a closely monitored follow-up program.

When the nodules, papules, areas of atrophy, erosions or prolonged ulcerations are > 5 mm in diameter, an incisional biopsy is indicated.³⁶ Serial sections of the specimen must be evaluated histologically. If the histologic diagnosis is mild to moderate dysplasia the area may be treated with 5% topical 5-fluorouracil or imiquimod. Despite excellent clinical remission of AC, neither of these two drugs has been shown to completely eradicate dysplasia at the microscopic level.³⁶

Alternatively, ablation with cryotherapy (liquid nitrogen applied with a cryoprobe) or electrosurgery can be useful for the treatment of focal AC. Cryotherapy requires no local anesthesia and five-year cure rates as high as 99% have been reported.³⁶ Electrosurgery requires local anesthesia and may lead to damage to adjacent tissues and scar formation. A major disadvantage of both of these techniques is that they do not yield specimens for histologic evaluation of serial sections.

AC characterized by diffuse leukoplakia or atrophy of the lip vermilion should have a single incisional biopsy of the most suspicious area, which has generally been shown to correspond to a greater degree of dysplasia. If the histologic diagnosis is mild to moderate dysplasia, field therapy with 5% topical 5-fluorouracil or imiquimod may be an option. However, CO2 laser ablation has been shown to more predictably resolve both the clinical and histological manifestations of AC.³⁶

AC with severe dysplasia is considered equivalent to or indistinguishable from SCIS and any patient with a lip lesion suspected to be malignant should be referred to an oral and maxillofacial or head & neck surgeon for further assessment. The clinical behavior of SCC of the lip falls between cutaneous SCC and intraoral mucosal SCC.⁷⁰ Cutaneous SCC is highly curable (95%), while the 5-year survival rate for oral cavity and pharynx SCC is 69.0%. The 5-year survival rate for SCC of the lip is 90.3%.²¹ Initial tumor size directly influences

the risk of nodal metastasis. The risk for nodal metastasis for T1 tumors is 3.4% - 7%, for T2 tumors 11% - 35%, and for T3 and T4 tumors 17% - 100%.⁷⁰ The most commonly involved nodes are the submandibular, followed by the submental, jugular chain, and the intraparotid groups.⁵⁸

Surgical excision is the most prudent and effective approach to the treatment of diffuse AC, as it allows for the physical removal of part or all of the lip vermilion.³⁶ The most common surgical technique is vermilionectomy or lip-shave. Unlike CO2 ablation, it has the advantage of providing specimens for histological evaluation of serial sections. The advantage of CO2 laser ablation when compared to scalpel vermilionectomy is that it results in fewer esthetic side effects.

When scalpel vermilionectomy is performed, the orbicularis oris muscle is conserved and closure is obtained by advancing and suturing the labial mucosa to the skin to create a new lip line. The technique can also be combined with a wedge procedure to simultaneously eliminate SCIS or a small SCC. Side effects are common and may include the presence of hairs near the newly established lip line, paresthesia, and scarring, which may result in restriction of labial motion.³⁶

Conclusion

AC represents the early clinical manifestations of a continuum that may ultimately develop into SCC of the lip. It shares the same etiology with AK and cutaneous SCC of the skin. Thus, labial SCC differs from other forms of intraoral SCCs. The only proven method of reducing the risk of developing AC is to reduce exposure to the harmful effects of UV radiation. Patients should be advised to avoid unnecessary sun exposure and to consistently use a broad-spectrum sunscreen when outdoors.

The issue of how to effectively diagnose AC is a major clinical challenge. A combined diagnostic-therapeutic approach may offer the best solution to this dilemma. Complete surgical excision is the favored treatment modality. Lesions that are not amenable to surgical excision must have a random biopsy followed by the most effective treatment to eradicate the disease. Surgical specimens must undergo serial sectioning and histologic evaluation.

Course Test Preview

To receive Continuing Education credit for this course, you must complete the online test. Please go to: www.dentalcare.com/en-us/ce-courses/ce400/start-test

1. All of the following statements are correct relative to actinic cheilosis, except for one. Which one is the exception?

- A. The major etiologic factor associated with AC is ultraviolet radiation, principally UV-C.
- B. Factors predisposing to AC include skin phenotype, male sex, outdoor occupation, rural living, and host immune status.
- C. AK and AC serve as clinical dose-meters for chronic UVR exposure.
- D. Risk increases with age.

2. All of the following statements are correct relative to the carcinogenic effects of UV-A and UV-B, except for one. Which one is the exception?

- A. UV-B damages DNA at adjacent pyrimidines resulting in double cytosine to double thymidine transition mutations.
- B. UV-B induced mutations are so specific that they are frequently referred to as the "UV signature" or "UV fingerprint."
- C. UV-B mutations target tumor suppressor genes (impair tumor suppressor activity), the most notable being p53.
- D. UV-A appears to have no impact of carcinogenic risk.

3. All of the following statements are correct relative to the relationship between actinic cheilosis, gender, and skin phenotype, except for one. Which one is the exception?

- A. AC occurs more frequently in light-complected than dark-complected individuals.
- B. Melanin appears to be ineffective in protecting against SSC.
- C. Susceptible individuals whose sun exposure habits began early in life are at increased risk of developing AC.
- D. It has been postulated that women are at lesser risk of developing AC because they experience less chronic exposure to sun than men and they are more likely to use some form of lip protection.

4. All of the following statements related to AC are correct, except for one. Which one is the exception?

- A. While the association between tobacco use and AC is unclear, the habit of leaving a cigarette on the lip has been reported to increase the risk of labial SCC.
- B. Since 2008, the incidence of SCC of the lip has remained steady at about 0.7/100,000.
- C. SCC of the lip is most frequently diagnosed among people aged 65–74.
- D. SCC of the lower lip tends to be more severe when it occurs in the elderly patient.

5. All of the following statements are correct relative to the various stages of AC associated with chronic exposure to UVR, except for one. Which one is the exception?

- A. Chronic exposure to UVR results in sunburn, blistering, and peeling of the lip vermilion.
- B. Chronic exposure to UVR initially leads to AC characterized by dry, scaly unobtrusive "chapped lips."
- C. Palpation provides a sense of rubbing the fingers over sandpaper.
- D. AC may appear mottled, opalescent, with white or gray slightly elevated plaques.

- 6. All of the following statements are correct relative to the relationship between actinic cheilosis and squamous cell carcinoma, except for one. Which one is the exception?**
- A. The clinical appearance of AC does not always correlate directly with the underlying histological changes.
 - B. Waxing and waning of erythematous or hemorrhagic area and ulcerations of relatively long duration are ominous signs.
 - C. Induration, redness, ulcerations, and the onset of pain are generally suggestive of malignant transformation.
 - D. The clinical appearance of AC is predictive of the development of squamous cell carcinoma.
- 7. All of the following statements are correct relative to the diagnosis of AC, except for one. Which one is the exception?**
- A. The working diagnosis of AC is usually derived by correlating history with clinical findings.
 - B. The presence of concurrent AK on sun-exposed areas (face, neck, bald scalp, ears) reinforces the clinical impressions.
 - C. The clinical appearance of AC is so specific, there are few conditions to consider in the differential diagnosis.
 - D. The progressive nature of AC to squamous cell carcinoma emphasizes the importance of biopsy to establish a definitive diagnosis.
- 8. General protection guidelines published by the American Cancer Society to minimize actinic damage include all of the following, except for one. Which one is the exception?**
- A. Avoiding sun-exposure when UV rays are the strongest, i.e., before 10 AM and after 4 PM.
 - B. Covering-up exposed skin.
 - C. Wearing a hat that shades the neck, face, and ears; wearing sunglasses.
 - D. Using a sunscreen with a sun protection factor (SPF) of 30 or higher.
- 9. All of the following statements are correct with respect to sunscreens, except for one. Which one is the exception?**
- A. There are 22 sunscreen agents approved for use in the U.S..
 - B. Sunscreens can be divided into two types based on their ingredients, i.e., inorganic or organic.
 - C. Sunscreens that contain zinc or titanium oxide act to physically block, reflect, or scatter UVR.
 - D. Organic agents have variable absorptive spectra and sunscreen manufacturers typically combine several agents to produce a broad spectrum product capable of blocking both UV-A and UV-B.
- 10. All of the following statements are correct relative to lip balms, except for one. Which one is the exception?**
- A. For the prevention of AC, the product should be formulated for use on the lip
 - B. The lip balm should provide broad-spectrum protection against both UV-A and UV-B.
 - C. If a lip balm is not available, a broad-spectrum cream-formulation sunscreen is preferred.
 - D. Regardless of the sunscreen chosen, it should be applied 15-30 minutes prior to sun exposure and reapplied after any activity that may wash or rub it away.

- 11. All of the following statements are correct with respect to a squamous cell carcinoma presenting as a well-circumscribed nodule or papule less than 5 mm in diameter, except for one. Which one is the exception?**
- A. It is amenable to an excisional biopsy.
 - B. Histologic evaluation is not necessary.
 - C. Mohs micrographic surgery (MMS), because of its excellent cosmetic yield, may be considered.
 - D. If the histologic diagnosis confirms mild to moderate dysplasia no further treatment is indicated, but the patient should be placed in a closely monitored follow-up program.
- 12. All of the following statements are correct with respect to AC, presenting as a nodule, papule, area of atrophy, erosion or prolonged ulceration >5 mm in diameter, except for one. Which one is the exception?**
- A. An incisional biopsy is indicated.
 - B. Serial sections of the specimen must be evaluated histologically.
 - C. If the histologic diagnosis is mild to moderate dysplasia the area may be treated with 5% topical 5-fluorouracil or imiquimod.
 - D. Treatment with topical agents has been shown to result in excellent clinical remission of AC and to completely eradicate dysplasia at the microscopic level.
- 13. All of the following statements are correct with respect to cryotherapy (liquid nitrogen applied with a cryoprobe) or electrotherapy in the treatment of AC, except for one. Which one is the exception?**
- A. Ablation with cryotherapy (liquid nitrogen applied with a cryoprobe) or electrotherapy can be useful for the treatment of focal AC.
 - B. A major advantage of both these techniques is that they yield specimens for histologic evaluation of serial sections.
 - C. Cryotherapy requires no local anesthesia and five-year cure rates as high as 99% have been reported.
 - D. Electrotherapy requires local anesthesia and may lead to damage to adjacent tissues and scar formation.
- 14. All of the following statements are correct with respect to AC characterized by diffuse leukoplakia or atrophy of the lip vermilion, except for one. Which one is the exception?**
- A. The least frequently recommended therapy is vermilionectomy.
 - B. If the histologic diagnosis is mild to moderate dysplasia, field therapy with 5% topical 5-fluorouracil or imiquimod may be an option.
 - C. CO2 laser ablation has been shown to more predictably resolve both the clinical and histological manifestations of AC than topical chemotherapy.
 - D. The most frequently recommended therapy is vermilionectomy.
- 15. All of the following statements are correct with respect to AC associated with severe dysplasia, except for one. Which one is the exception?**
- A. Ablative therapy with cryotherapy or electrotherapy is a recommended first line approach to management.
 - B. AC with severe dysplasia is considered equivalent to or indistinguishable from squamous cell carcinoma-in-situ (SCIS).
 - C. Vermilionectomy or lip-shave is the most prudent and effective approach to the treatment of diffuse AC, as it provides specimens for histologic evaluation of serial sections.
 - D. Scalpel vermilionectomy can be combined with a wedge procedure to simultaneously eliminate SCIS or a small SCC.

- 16. All of the following statements are correct with respect to clinically highly suspicious lesions thought to be SCIS or SCC, except for one. Which one is the exception?**
- A. Clinically highly suspicious lesions thought to be SCIS or SCC must promptly be referred to a head-and-neck surgeon to maximize prognostic outcome.
 - B. The risk of nodal metastasis increases in direct proportion to tumor size.
 - C. Initial tumor size has little bearing on nodal metastasis.
 - D. The most commonly involved nodes associated with SCIS or SCC are the submandibular.

References

1. Jadotte YT, Schwartz RA. Solar cheilosis: An ominous precursor Part I. Diagnostic insights. *J Am Acad Dermatol*. 2012 Feb;66(2):173-84; quiz 185-6. doi: 10.1016/j.jaad.2011.09.040.
2. Picascia DD, Robinson JK. Actinic cheilitis: a review of the etiology, differential diagnosis, and treatment. *J Am Acad Dermatol*. 1987 Aug;17(2 Pt 1):255-64.
3. Rogers RS 3rd, Bekic M. Diseases of the lips. *Semin Cutan Med Surg*. 1997 Dec;16(4):328-36.
4. de Visscher JG, van der Waal I. Etiology of cancer of the lip. A review. *Int J Oral Maxillofac Surg*. 1998 Jun;27(3):199-203.
5. Fu W, Cockerell CJ. The actinic (solar) keratosis: a 21st-century perspective. *Arch Dermatol*. 2003 Jan;139(1):66-70.
6. Leffell DJ. The scientific basis of skin cancer. *J Am Acad Dermatol*. 2000 Jan;42(1 Pt 2):18-22.
7. Mancebo SE, Hu JY, Wang SQ. Sunscreens. Review of health benefits, regulations, and controversies. *Dermatol Clin* 2014;32:427-438.
8. Valejo Coelho MM, Matos TR, Apetato M. The dark side of the light: mechanisms of photocarcinogenesis. *Clin Dermatol*. 2016 Sep-Oct;34(5):563-70. doi: 10.1016/j.clindermatol.2016.05.022.
9. de Visscher JG, Schaapveld M, Otter R, et al. Epidemiology of cancer of the lip in The Netherlands. *Oral Oncol*. 1998 Sep;34(5):421-6.
10. Ostwald C, Gogacz P, Hillmann T, et al. p53 mutational spectra are different between squamous-cell carcinomas of the lip and the oral cavity. *Int J Cancer*. 2000 Oct 1;88(1):82-6.
11. Clydesdale GJ, Dandie GW, Muller HK. Ultraviolet light induced injury: immunological and inflammatory effects. *Immunol Cell Biol*. 2001 Dec;79(6):547-68.
12. Schober-Flores C. The sun's damaging effects. *Dermatol Nurs*. 2001 Aug;13(4):279-86.
13. Salasche SJ. Epidemiology of actinic keratoses and squamous cell carcinoma. *J Am Acad Dermatol*. 2000 Jan;42(1 Pt 2):4-7.
14. Sarasin A. The molecular pathways of ultraviolet-induced carcinogenesis. *Mutat Res*. 1999 Jul 16;428(1-2):5-10.
15. Armstrong BK, Krickler A. The epidemiology of UV induced skin cancer. *J Photochem Photobiol B*. 2001 Oct;63(1-3):8-18.
16. Ortonne JP. From actinic keratosis to squamous cell carcinoma. *Br J Dermatol*. 2002 Apr;146 Suppl 61:20-3.
17. Crosthwaite N, Teale D, Franklin C, et al. p53 protein expression in malignant, pre-malignant and non-malignant lesions of the lip. *J Clin Pathol*. 1996 Aug;49(8):648-53.
18. U.S. Food and Drug Administration. Radiation-Emitting Products. Your skin. Accessed January 24, 2022.
19. de Gruijl FR, van Kranen HJ, Mullenders LH. UV-induced DNA damage, repair, mutations and oncogenic pathways in skin cancer. *J Photochem Photobiol B*. 2001 Oct;63(1-3):19-27.
20. Perea-Milla López E, Miñarro-Del Moral RM, Martínez-García C, et al. Lifestyles, environmental and phenotypic factors associated with lip cancer: a case-control study in southern Spain. *Br J Cancer*. 2003 Jun 2;88(11):1702-7.
21. SEER Cancer Stat Facts: Lip Cancer. National Cancer Institute. Bethesda, MD. Accessed January 29, 2025.
22. Dreno B. Skin cancers after transplantation. *Nephrol Dial Transplant*. 2003 Jun;18(6):1052-8.
23. Hodgson TA, Greenspan D, Greenspan JS. Oral lesions of HIV disease and HAART in industrialized countries. *Adv Dent Res*. 2006 Apr 1;19(1):57-62.
24. Engels EA, Pfeiffer RM, Fraumeni JF Jr, et al. Spectrum of cancer risk among US solid organ transplant recipients. *JAMA*. 2011 Nov 2;306(17):1891-901. doi: 10.1001/jama.2011.1592.
25. Adami J, Gäbel H, Lindelöf B, et al. Cancer risk following organ transplantation: a nationwide cohort study in Sweden. *Br J Cancer*. 2003 Oct 6;89(7):1221-7.
26. Lindelöf B, Sigurgeirsson B, Gäbel H, et al. Incidence of skin cancer in 5356 patients following organ transplantation. *Br J Dermatol*. 2000 Sep;143(3):513-9.

27. Krouse RS, Alberts DS, Prasad AR, et al. Progression of skin lesions from normal skin to squamous cell carcinoma. *Anal Quant Cytol Histol*. 2009 Feb;31(1):17-25.
28. Baker SR. Risk factors in multiple carcinomas of the lip. *Otolaryngol Head Neck Surg* (1979). 1980 May-Jun;88(3):248-51.
29. Cataldo E, Doku HC. Solar cheilitis. *J Dermatol Surg Oncol*. 1981 Dec;7(12):989-95.
30. Wurman LH, Adams GL, Meyerhoff WL. Carcinoma of the lip. *Am J Surg*. 1975 Oct;130(4):470-4.
31. Lindelöf B, Sigurgeirsson B, Gäbel H, et al. Incidence of skin cancer in 5356 patients following organ transplantation. *Br J Dermatol*. 2000 Sep;143(3):513-9.
32. Muse ME, Crane JS. Actinic cheilitis. 2021 Aug 9. In: *StatPearls* [Internet]. Treasure Island (FL): StatPearls Publishing; 2021 Jan
33. Cavalcante AS, Anbider AL, Carvalho YR. Actinic Cheilitis: Clinical and Histological Features. *J Oral Maxillofac Surg*. 2008 Mar;66(3):498-503. doi: 10.1016/j.joms.2006.09.016.
34. de Oliveira Miranda AM, de Miranda Ferrari T, Campos Leite T, et al. Actinic Cheilitis: Clinical Characteristics Observed in 75 Patients and a Summary of the Literature of This Often Neglected Premalignant Disorder. *Int J Clin*. 2014 Dec;21(5):1337-1344. doi: 10.4236/ijcm.2014.521171. Accessed January 29, 2025.
35. Markopoulos A, Albanidou-Farmaki E, Kayavis I. Actinic cheilitis: clinical and pathologic characteristics in 65 cases. *Oral Dis*. 2004 Jul;10(4):212-6.
36. Jadotte YT, Schwartz RA. Solar cheilosis: an ominous precursor part II. Therapeutic perspectives. *J Am Acad Dermatol*. 2012 Feb;66(2):187-98; quiz 199-200. doi: 10.1016/j.jaad.2011.09.039.
37. Huber MA. Oral lichen planus. *Quintessence Int*. 2004 Oct;35(9):731-52.
38. van Tuyll van Serooskerken AM, van Marion AM, de Zwart-Storm E, et al. Lichen planus with bullous manifestation on the lip. *Int J Dermatol*. 2007 Nov;46 Suppl 3:25-6.
39. Nissalo S, Hietanen J, Malmström M, et al. Disorder-specific changes in innervation in oral lichen planus and lichenoid reactions. *J Oral Pathol Med*. 2000 Sep;29(8):361-9.
40. Nico MM, Nakano de Melo J, Lourenço SV. Cheilitis glandularis: a clinicopathological study in 22 patients. *J Am Acad Dermatol*. 2010 Feb;62(2):233-8. doi: 10.1016/j.jaad.2009.06.038. Epub 2009 Dec 11.
41. Reiter S, Vered M, Yarom N, et al. Cheilitis glandularis: clinico-histopathological diagnostic criteria. *Oral Dis*. 2011 Apr;17(3):335-9. doi: 10.1111/j.1601-0825.2010.01762.x. Epub 2010 Oct 28.
42. Ayangco L, Rogers RS 3rd. Oral manifestations of erythema multiforme. *Dermatol Clin*. 2003 Jan;21(1):195-205.
43. Mockenhaupt M. The current understanding of Stevens-Johnson syndrome and toxic epidermal necrolysis. *Expert Rev Clin Immunol*. 2011 Nov;7(6):803-13; quiz 814-5. doi: 10.1586/eci.11.66.
44. Bickle K, Roark TR, Hsu S. Autoimmune bullous dermatoses: a review. *Am Fam Physician*. 2002 May 1;65(9):1861-70.
45. Dagistan S, Goregen M, Miloglu O, et al. Oral pemphigus vulgaris: a case report with review of the literature. *J Oral Sci*. 2008 Sep;50(3):359-62.
46. Orteu CH, Buchanan JA, Hutchison I, et al. Systemic lupus erythematosus presenting with oral mucosal lesions: easily missed? *Br J Dermatol*. 2001 Jun;144(6):1219-23.
47. Hasséus B, Jontell M, Brune M, et al. Langerhans cells and T cells in oral graft versus host disease and oral lichen planus. *Scand J Immunol*. 2001 Nov;54(5):516-24.
48. Farrier JN, Perkins CS. Plasma cell cheilitis. *Br J Oral Maxillofac Surg*. 2008 Dec;46(8):679-80. *Br J Oral Maxillofac Surg*. 2008 Dec;46(8):679-80. doi: 10.1016/j.bjoms.2008.03.009. Epub 2008 Apr 24.
49. El-Hakim M, Chauvin P. Orofacial granulomatosis presenting as persistent lip swelling: review of 6 new cases. *J Oral Maxillofac Surg*. 2004 Sep;62(9):1114-7.
50. van der Waal RI, Schulten EA, van der Meij EH, et al. Cheilitis granulomatosa: overview of 13 patients with long-term follow-up—results of management. *Int J Dermatol*. 2002 Apr;41(4):225-9.

51. Cockerell CJ. Histopathology of incipient intraepidermal squamous cell carcinoma (“actinic keratosis”). *J Am Acad Dermatol*. 2000 Jan;42(1 Pt 2):11-7.
52. Yantsos VA, Conrad N, Zabawski E, et al. Incipient intraepidermal cutaneous squamous cell carcinoma: a proposal for reclassifying and grading solar (actinic) keratoses. *Semin Cutan Med Surg*. 1999 Mar;18(1):3-14.
53. McCombe D, MacGill K, Ainslie J, et al. Squamous cell carcinoma of the lip: a retrospective review of the Peter MacCallum Cancer Institute experience 1979-88. *Aust N Z J Surg*. 2000 May;70(5):358-61.
54. Fernández-Angel I, Rodríguez-Archilla A, Aneiros Cachaza J, et al. Markers of metastasis in lip cancer. *Eur J Dermatol*. 2003 May-Jun;13(3):276-9.
55. Guney E, Yigitbasi OG. Functional surgical approach to the level I for staging early carcinoma of the lower lip. *Otolaryngol Head Neck Surg*. 2004 Oct;131(4):503-8.
56. Rodolico V, Barresi E, Di Lorenzo R, et al. Lymph node metastasis in lower lip squamous cell carcinoma in relation to tumour size, histologic variables and p27Kip1 protein expression. *Oral Oncol*. 2004 Jan;40(1):92-8.
57. Zitsch RP 3rd, Lee BW, Smith RB. Cervical lymph node metastases and squamous cell carcinoma of the lip. *Head Neck*. 1999 Aug;21(5):447-53.
58. de Visscher JG, van den Elsaker K, Grond AJ, et al. Surgical treatment of squamous cell carcinoma of the lower lip: evaluation of long-term results and prognostic factors—a retrospective analysis of 184 patients. *J Oral Maxillofac Surg*. 1998 Jul;56(7):814-20.
59. Bilkay U, Kerem H, Ozek C, et al. Management of lower lip cancer: a retrospective analysis of 118 patients and review of the literature. *Ann Plast Surg*. 2003 Jan;50(1):43-50.
60. Meves A, Repacholi MH, Rehfues EA. Global Solar UV Index: a physician’s tool for fighting the skin cancer epidemic. *Int J Dermatol*. 2003 Oct;42(10):846-9.
61. American Cancer Society. Skin Cancer Prevention and Early Detection. How do I protect myself from UV rays? Accessed January 29, 2025.
62. Electronic Code of Federal Regulations. §201.327 Over-the-counter sunscreen drug products; required labeling based on effectiveness testing. Accessed January 29, 2025.
63. Rosen CF. Topical and systemic photoprotection. *Dermatol Ther*. 2003;16(1):8-15.
64. Young AR. Are broad-spectrum sunscreens necessary for immunoprotection? *J Invest Dermatol*. 2003 Oct;121(4):ix x.
65. Moyal DD, Fournanier AM. Broad-spectrum sunscreens provide better protection from solar ultraviolet-simulated radiation and natural sunlight-induced immunosuppression in human beings. *J Am Acad Dermatol*. 2008 May;58(5 Suppl 2):S149-54. doi: 10.1016/j.jaad.2007.04.035.
66. Sambandan DR, Ratner D. Sunscreens: an overview and update. *J Am Acad Dermatol*. 2011 Apr;64(4):748-58. doi: 10.1016/j.jaad.2010.01.005. Epub 2011 Feb 3.
67. The Skin Cancer Foundation. The Skin Cancer Foundation’s Guide to Sunscreens. Accessed January 24, 2022.
68. Gruber L, Zitz S. 15 Best Lip Balms with SPF in 2024, According to Dermatologists. *Prevention*. Accessed January 29, 2025.
69. Lai M, Pampena R, Cornacchia L, et al. Treatment of actinic cheilitis: A systemic review of the literature. *J Am Acad Dermatol*. 2020;83:876-87.
70. Bota JP, Lyons AB, Carroll BT. Squamous Cell Carcinoma of the Lip-A Review of Squamous Cell Carcinogenesis of the Mucosal and Cutaneous Junction. *Dermatol Surg*. 2017 Apr;43(4):494-506. doi: 10.1097/DSS.0000000000001020.

Additional Resources

- No Additional Resources Available

About the Authors

Michael A. Huber, DDS

Professor




Department of Comprehensive Dentistry
The University of Texas Health Science Center at San Antonio, School of
Dentistry, San Antonio, Texas

Dr. Michael A. Huber is a 1980 graduate from the University of Texas Health Science Center at San Antonio Dental School, San Antonio, Texas. Upon graduation, he embarked upon 22-year career serving in the United States Navy Dental Corps. He received a Certificate in Oral Medicine from the National Naval Dental Center, Bethesda, Maryland in 1988 and is diplomate of the American Board of Oral Medicine. From 1996-1998, he served as Chairman, Department of Oral Medicine and Maxillofacial Radiology; Director, Graduate Program in Oral Medicine, National Naval Dental Center, Bethesda, Maryland; and as Specialty Leader for Oral Medicine to the Surgeon General of the United States Navy, Washington, DC. In 2002, Dr. Huber returned to his alma mater to teach both pre-doctoral and graduate dental students. He is a recipient of the 2014 UTHSCSA Presidential Teaching Excellence Award, the 2018 Diamond Pin Award from the American Academy of Oral Medicine, and the 2019 UT Regents Outstanding Teaching Award. He is a Past President of the American Academy of Oral Medicine. Dr. Huber retired from his full-time faculty position in the summer of 2020, but continues to support the School of Dentistry's mission of teaching excellence as an Adjunct Professor. He is a member of the dentalcare.com Advisory Board and currently serves as a member of the National Commission on Recognition of Dental Specialties and Certifying Appeals Board.

Email: huberm@uthscsa.edu

David Leonard Ojeda Diaz, DDS



Clinical Assistant Professor of Oral Medicine
Department of Comprehensive Dentistry
The University of Texas Health Science Center at San Antonio School of Dentistry

Dr. David Ojeda Díaz received his DDS from the Santa Maria University School Dentistry, Caracas, Venezuela in 2008. He then entered a combined training program in Oral Surgery and Oral Pathology at the Xaverian University School of Dentistry, Bogota, Colombia. Upon graduation in 2011, he began private practice and actively participated in the Venezuelan Academy of Oral Medicine. In 2014 he began a one year Oral Medicine & Orofacial Pain fellowship at the New York University College of Dentistry. In 2017 Dr. Ojeda Díaz completed a two year residency program in Oral Medicine at the University of Pennsylvania. Dr. David Ojeda Díaz joined the Department of Comprehensive Dentistry, UT Health School of Dentistry as a full time faculty member in August of 2017. Dr. Ojeda Diaz is a member of the American Academy of Oral Medicine and has published articles and book chapters related to Oral Medicine and Orofacial Pain.

Email: ojedadiaz@uthscsa.edu