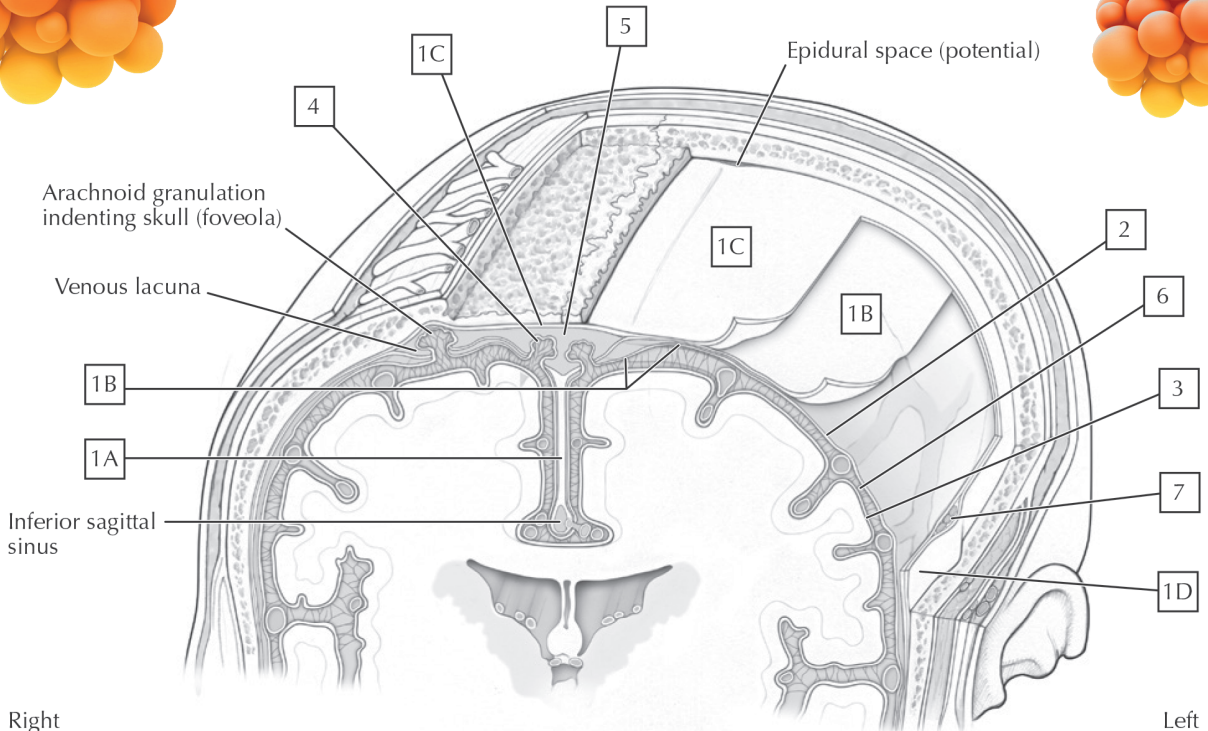
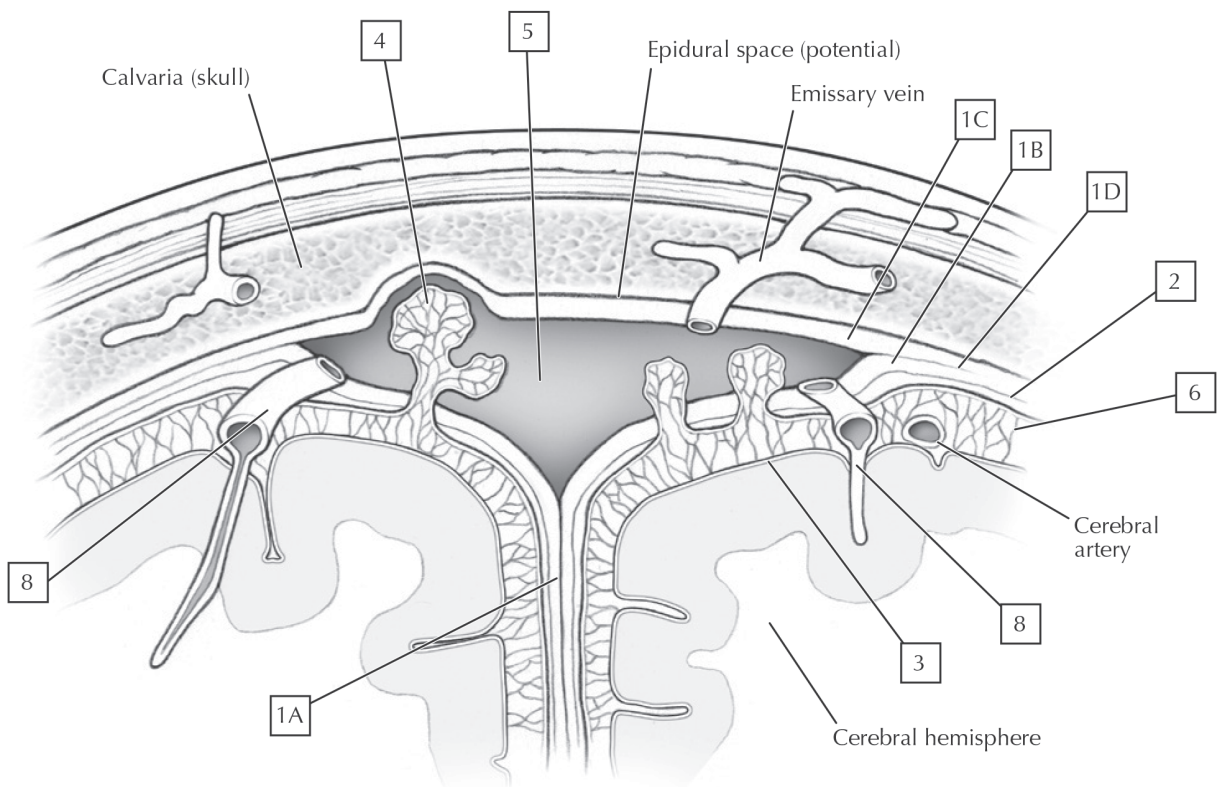


COLOUR BETTER WITH NETTER



A. Scalp, skull, meningeal, and cerebral blood vessels



B. Meninges and superficial cerebral veins