

Koplik spots are white lesions seen on buccal mucosa of which viral infection?

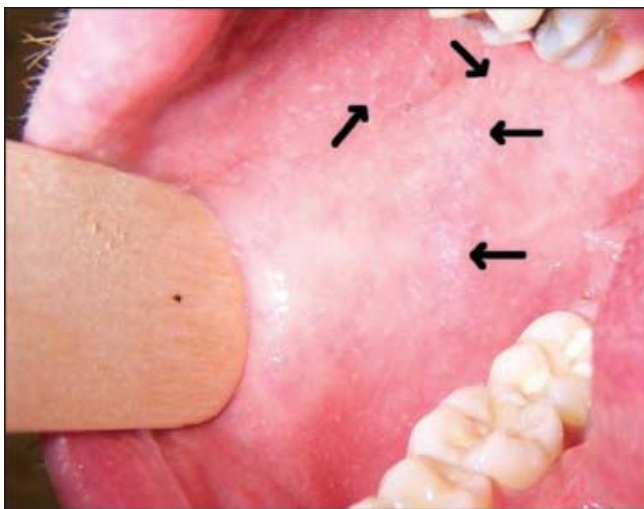
- A) Parvovirus B19
- B) Rubella
- C) Varicella
- D) Rubeola
- E) Epstein Bar Virus

MCQ / ClinicalKey AnswerCard

Rubeola, also known as measles virus has an incubation period of 7-18 days before the development of a classical prodrome: Cough, fever, coryza and fever. Shortly after the characteristic erythematous, maculopapular rash appears spreading over 3-4 days from the head, then over the trunk and to the limbs

Koplik spots seen on the inside of the mouth, may herald the outbreak of the rash by 24-48hrs.

As measles is a notifiable public health condition, investigations should be prompted if there is the characteristic rash and fever for 3 days, along with one of the prodrome features



[ClinicalKey Link](#)  
[ClinicalKey Student](#)