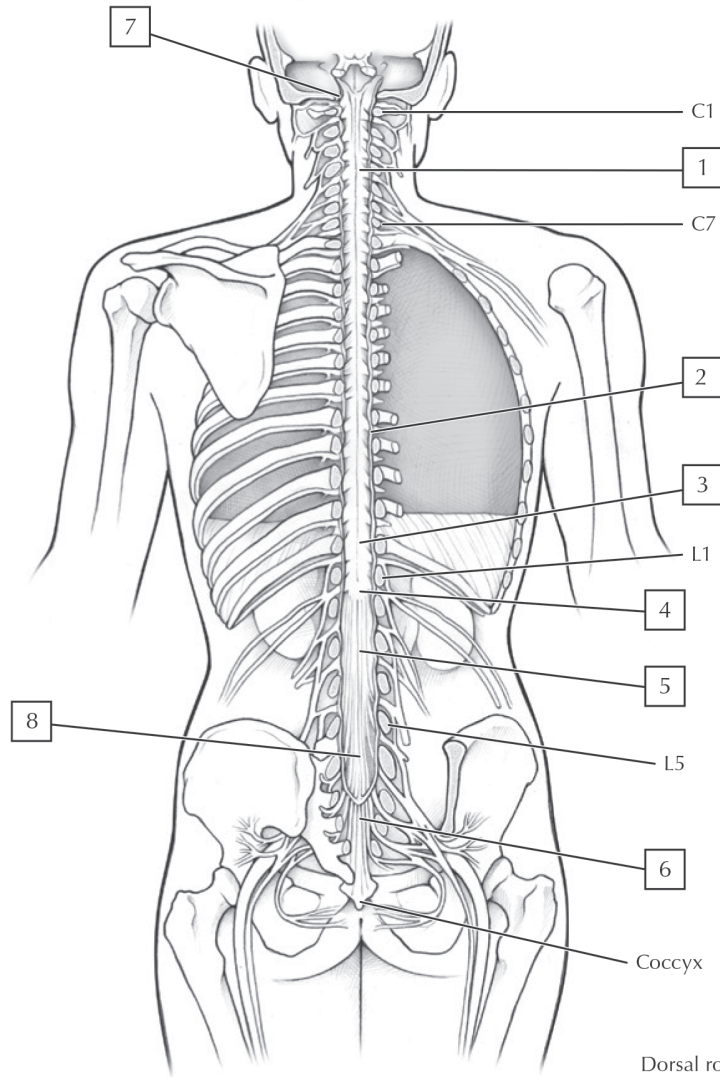
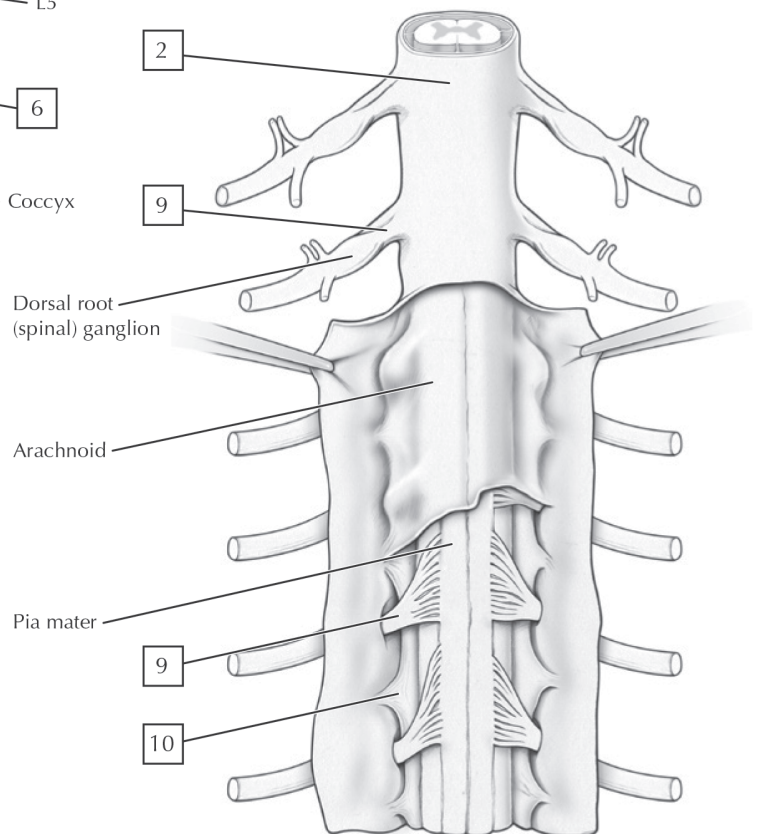


COLOUR BETTER WITH NETTER



A. Spinal cord gross anatomy in situ



B. Meninges and spinal roots